

LETTERS TO THE EDITOR

Central serous chorioretinopathy may be a manifestation of the primary antiphospholipid syndrome

EDITOR,—Central serous chorioretinopathy is thought to be an idiopathic disease and such cases are not usually investigated for an underlying cause. Bullous exudative retinal detachment is a recognised complication of central serous chorioretinopathy (CSR).¹ There are a number of reports of exudative retinal detachments occurring in the context of generalised coagulopathies.^{2,3} We present a patient with central serous chorioretinopathy who on further investigation was found to have the primary antiphospholipid syndrome.

CASE REPORT

A 42 year old white man presented in December 1992 with difficulty in reading and a grey "circle" in his right central field of vision of 6 weeks' duration. His past medical history consisted of widespread burns requiring skin grafting and complicated by septicaemia 20 years previously. Apart from two short courses of antimalarial tablets within the past 6 years, he had been taking no other medication. He was a non-smoker, but had been a heavy drinker. Corrected visual acuity was 6/9 N12 right eye, 6/9 N5 left eye. Funduscopy revealed bilateral retinal pigment epithelial (RPE) disturbances with no dye leakage on fluorescein angiography. Over subsequent months, transient serous elevation of the neurosensory retina at the right macula was noted. In October bilateral pigment epithelial detachments were noted with visual acuities of right eye 6/24 N10, left eye 6/60 N48. A trial of oral prednisolone seemed to halt the

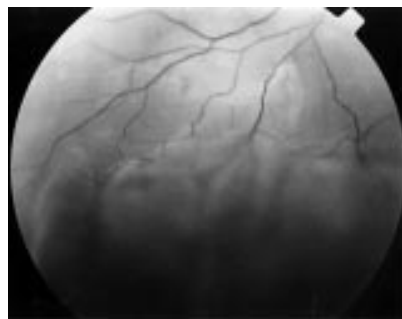


Figure 1 Right fundus showing inferior exudative retinal detachment.

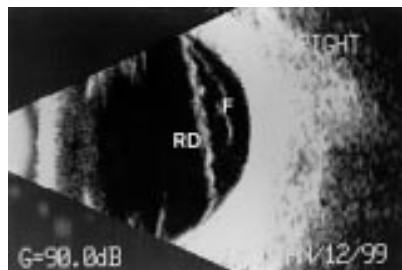


Figure 2 B-scan ultrasonograph of right eye showing retinal detachment (RD) with probable subretinal fibrosis (F).

deterioration in vision and subsequently the patient was given 1 g daily of intravenous methylprednisolone for 3 days. A subsequent autoimmune screen revealed a positive lupus anticoagulant test (Russell viper venom with Cephalin 1.61 (0.95-1.05), Russell viper venom with platelets 1.12 (0.95-1.05)) and the presence of anticardiolipin antibodies (anticardiolipin IgG 46.3 gpl units (0-13.3)). Antinuclear antibodies were weakly positive at 1:20 with a homogeneous/speckled pattern but anti-double stranded DNA, complement, extractable nuclear antigens and rheumatoid factor were negative. Steroids were stopped and the patient was given aspirin.

On subsequent review the patient had developed a large bullous inferior exudative retinal detachment in the right eye (Fig 1). B-scan ultrasound revealed retinal detachment with presumed subretinal fibrosis (Fig 2). Eventually the retinal detachment resolved spontaneously with the patient taking aspirin alone. Visual acuity is currently right eye 1/60, left eye 6/36. The patient manages N8 with a reading loupe.

COMMENT

Idiopathic CSR tends to be a self limiting disease⁴ which can be complicated by the development of exudative retinal detachments.¹ The exact aetiology of CSR remains obscure. Indocyanine green angiography findings suggest that perfusion changes in the choriocapillaris may be responsible.⁵ Occlusive ocular vascular disease involving the retinal and choroidal vessels has been reported in up to 8% of patients with raised anticardiolipin antibodies.⁶ Serous detachment of the macula has been reported with the primary antiphospholipid antibody syndrome; however, other ocular and systemic features were always noted.²

The presence of antiphospholipid antibodies (anticardiolipin and lupus anticoagulant) can result in abnormalities of coagulation leading to venous and arterial thrombosis although exactly why this happens is not fully understood. Putative mechanisms include inhibition of antithrombin and activated protein C dependent anticoagulant systems, inhibition of fibrinolysis, and interference with the anticoagulant properties of β_2 glycoprotein I.⁷

We postulate that some cases of presumed idiopathic CSR may reflect thrombosis of the choroidal circulation secondary to the primary antiphospholipid antibody syndrome. Further studies are warranted to prove or disprove this hypothesis.

M T J COSTEN

Southampton Eye Unit, Tremona Road, Southampton
SO16 6YD

J A OLSON

Eye Department, Aberdeen Royal Infirmary, Aberdeen
AB25 2ZN

Correspondence to: Mr Costen

MTJRAC@aol.com

Accepted for publication 13 January 2000

- 1 Gass JD, Little H. Bilateral bullous exudative retinal detachment complicating idiopathic central serous chorioretinopathy during systemic corticosteroid therapy. *Ophthalmology* 1995;102:737-47.
- 2 Castanon C, Amigo M-C, Banales JL, et al. Ocular vaso-occlusive disease in primary antiphospholipid syndrome. *Ophthalmology* 1995;102:256-62.
- 3 Jabs DA, Hanneken AM, Shachat AP, et al. Choroidopathy in systemic lupus erythematosus. *Arch Ophthalmol* 1988;106:230-4.
- 4 Gilbert CM, Owens SL, Smith PD, et al. Long-term follow-up of central serous chorioretinopathy. *Br J Ophthalmol* 1984;68:185-20.
- 5 Piccolino FC, Borgia L. Central serous chorioretinopathy and indocyanine green angiography. *Retina* 1994;14:231-42.
- 6 Asherson RA, Merry P, Acheson JF, et al. Antiphospholipid antibodies: a risk factor for occlusive ocular vascular disease in systemic lupus erythematosus and the "primary" antiphospholipid syndrome. *Ann Rheum Dis* 1989;48:358-61.
- 7 Greaves M. Thrombosis series: antiphospholipid antibodies and thrombosis. *Lancet* 1999;353:1348-53.

Acute retinal necrosis following chickenpox in a healthy 4 year old patient

EDITOR,—Originally described by Urayama *et al.*,¹ acute retinal necrosis (ARN) is part of a continuous spectrum of necrotising herpetic retinopathies where the clinical expression is determined by the immune status of the host.^{2,3} We report a case of unilateral ARN complicated by retinal detachment following chickenpox. This is unusual in its severity and an extremely rare occurrence in this age group. To our knowledge, this patient represents the youngest case of chickenpox associated ARN.

CASE REPORT

A previously healthy 4 year old boy presented with total retinal detachment secondary to ARN of his left eye 6 weeks after an uncomplicated chickenpox infection. He was attending his local ophthalmologist soon after chickenpox, having been initially referred by an optometrist, where he was treated for anisometropic amblyopia. His visual acuity at that time was 6/18 right eye and 5/60 left eye, and no detachment was noted. However, 4 weeks later, visual acuity in his left eye had dramatically reduced to perception of light secondary to a retinal detachment, and he was transferred to the vitreoretinal service.

Examination revealed a dense relative afferent pupillary defect (RAPD) and panuveitis in the left eye. There was a 250° giant retinal tear, peripheral retinal necrosis, and a pale optic disc (Figs 1 and 2). The retina was completely detached. The right eye was normal.

The patient underwent left vitrectomy with silicone oil tamponade and 360° endophotocoagulation. Vitreous polymerase chain reaction (PCR) was negative for herpes simplex virus (HSV) and varicella zoster virus (VZV) but positive for cytomegalovirus (CMV). A repeat CMV PCR on the same vitreous sample was negative. Magnetic resonance imaging did not show any evidence of intracranial calcification suggestive of CMV or VZV. He had IgM to VZV only. A full immunological survey was normal. This included a normal CD4 count of $1.4 \times 10^9/l$ (range $1.2-2.0 \times 10^9/l$).

He was treated with systemic aciclovir and topical steroid and mydriatic following surgery. Although the operation was anatomically successful and the retinitis had resolved, acuity remained at perception of light due to optic atrophy and was unchanged at 7 months. His right eye remained normal throughout. Prophylactic treatment to the fellow eye with systemic aciclovir 400 mg by mouth twice daily is planned for 12 months.

COMMENT

Uncomplicated primary VZV infection (chickenpox) presents initially as maculopapular and later vesicular dermal eruptions without any ocular or CNS manifestations. ARN is a rare consequence this infection in the immuno-

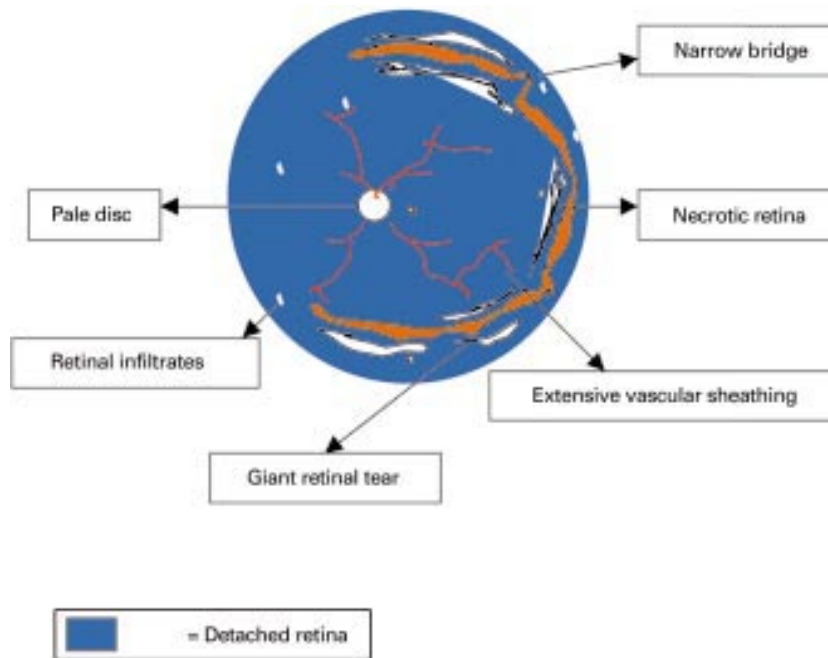


Figure 1 Fundus drawing of left eye. Note the giant retinal tear within the necrotic retina.

competent. Previous case reports by Matsuo *et al*^{4,5} and Culbertson⁶ suggest that chickenpox associated ARN has good visual prognosis irrespective of the immune status. None of their patients had retinal detachments. However, this case had an unusually severe retinitis culminating in a total retinal detachment and a poor visual prognosis.

Determining the specific cause of ARN is important as it has implications as to the choice of antiviral therapy. CMV associated ARN has been reported in healthy individuals.^{7,8} This case had no risk factors, clinical feature, or serological markers of CMV infection. The first vitreous PCR for CMV DNA was thus falsely positive, as confirmed by a repeat PCR test. Since HSV studies were also negative and he had classic features of chickenpox, backed by serology; the ARN was attributed to primary VZV infection. A retinal biopsy was not performed in this case because of a clear history of chickenpox infection, although it would have been strongly considered had the patient exhibited bilateral progressive disease.

The mode of retinal infection is unclear. Possible routes include direct haematogenous

spread to the retina, or indirectly to the brain with subsequent transneural spread to the eye shortly after the primary episode.⁹

The length of therapy is controversial. Treatment in the acute phase and prophylaxis for the fellow eye is by systemic aciclovir. However, since aciclovir is only effective against actively replicating virus, and cannot eradicate latent virus, any protective effect is debatable.⁹ Indeed, delayed involvement of the fellow eye may be as long as 34 years after the initial episode.¹⁰

Zoster related ARN remains largely a disease of adults despite the fact that a majority of patients acquiring chickenpox are in the paediatric age group. Before this case, only two patients aged 6 years and 13 years were reported.^{6,10} Since chickenpox associated ARN is extremely rare in children, it would not be justified to treat them prophylactically. However the physician should be aware of the possibility of ARN soon after chickenpox infection. Early detection of ARN and prompt treatment are required to reduce the risk of severe visual loss.

W H LEE

S J CHARLES

Vitreo-Retinal Service, Royal Eye Hospital,
Oxford Road, Manchester M13 9WH

Correspondence to: Mr Weng H Lee
whlee@appleonline.net

Accepted for publication 13 January 2000

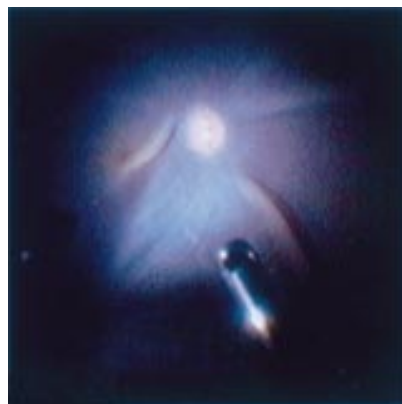


Figure 2 Perioperative photograph of left eye showing total retinal detachment.

- 1 Uryuyama A, Yamada N, Sasaki T, *et al*. Unilateral acute uveitis with periarteritis and retinal detachment. *Jpn J Ophthalmol* 1971;25:607-19.
- 2 Guex-Crosier Y, Rochat C, Herbot P. Necrotising herpetic retinopathies. *Ocular Immunol and Inflamm* 1997;5:259-65.
- 3 Holland GN and executive committee of american uveitis society. Standard diagnostic criteria for acute retinal necrosis. *Am J Ophthalmol* 1994;117:663-7.
- 4 Matsuo T, Nakayama T, Koyama T. A proposed mild type of acute retinal necrosis syndrome. *Am J Ophthalmol* 1988;105:579-83.
- 5 Matsuo T, Koyama M, Matsuo N. Acute retinal necrosis as a novel complication of chickenpox in adults. *Br J Ophthalmol* 1990;74:443-4.

- 6 Culbertson WW, Brod RD, Flynn HW, *et al*. Chickenpox associated acute retinal necrosis. *Ophthalmology* 1991;98:1641-6.
- 7 Bagliro E, Leuenberger PM, Krause KH. Presumed bilateral CMV induced optic neuropathy in an immunocompetent person. *J Neuro-Ophthalmol* 1996;16:14-7.
- 8 Freeman WR, Stern WH, Gross JG, *et al*. Pathologic observations made by retinal biopsy. *Retina* 1990;10:195-204.
- 9 Palay DA, Steinberg P, Davis J, *et al*. Decrease in risk of bilateral acute retinal necrosis by acyclovir therapy. *Am J Ophthalmol* 1991;112:250-5.
- 10 Falcone PM, Brockhurst RJ. Delayed onset of bilateral acute retinal necrosis: a 34 year interval. *Ann Ophthalmol* 1993;25:373-4.

Globe perforation with frameless spectacles

EDITOR.—Glasses are perceived to be a protective eye shield; however, when lenses shatter severe ocular injuries may result. Several reports discuss the relation of spectacle design to their safety, both the lens and the frame contributing spectacle stability.¹⁻⁴ A trend for thin or absent frames may place some patients at increased risk of serious ocular injury. We present the case of a car driver who sustained a perforated globe when glass frameless spectacles fractured during a low impact collision.

CASE REPORT

A 37 year old woman wearing, glass, frameless spectacles (Rodenstock R244C), collided with a lamp-post at around 15 mph (24 km/h). She was driving a small hatchback car and the impact was sufficient to damage the bonnet and windscreen. The car was not fitted with air bags but the driver and passenger were wearing three point seat belts. The driver's head fell forwards hitting the steering wheel and fracturing her spectacles (Fig 1). The force was not sufficient to bruise her face. A shard from the spectacles lacerated the patient's left eye.

When the patient was seen in casualty a 14 mm, trans-cornea laceration was noted, which extended into sclera (Fig 2). The cut was clean and linear with no loss of corneal tissue. A total hyphaema was present with a brisk haemorrhage from the wound. Further examination at surgery revealed a clean laceration with loss of the crystalline lens and two thirds of the inferior iris; no intraocular foreign body was found. Primary repair was undertaken, prolapsed iris and vitreous were removed. The wound was closed with 10/0 nylon to the cornea and 6/0 Vicryl to the sclera. The patient's postoperative recovery was covered with systemic antibiotics, topical steroids, and cycloplegics.

Following surgery the patient regained hand movement vision. Ultrasonography initially showed choroidal detachment and vitreous haemorrhage. The choroidal effusions settled over 10 days. Postoperative pressure spikes were controlled with Iopidine (apraclonidine

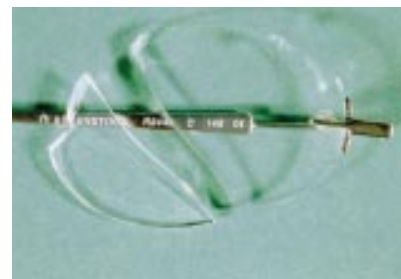

Figure 3 The frameless spectacles; fractured by a low velocity accident.

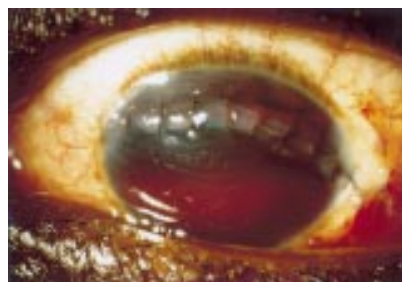

Figure 2 The patient's left eye following primary repair; note the "clean cut" caused by the broken glass.

0.1% twice daily), timolol (0.25% twice daily), Alphagan (brimonidine, 2% twice daily) drops, and oral acetazolamide (250 mg four times daily).

At 2 weeks after injury a three port pars planar vitrectomy was performed to clear the visual axis of haemorrhage, and the retina was found to be relatively undamaged. Following this procedure the IOP was controlled with Iopidine (0.1% twice daily) and timolol (0.25% twice daily) and the patient recovered to counting fingers vision which was maintained at 6 months.

COMMENT

The issue of ocular damage from spectacle wear has been highlighted by the widespread introduction of airbags as a safety feature in modern cars.⁵ The incidence of such injuries is difficult to estimate; however, there are at least 140 reported in the literature.¹ Myopic patients are three times more likely to suffer globe perforation than hypermetropes² owing to mechanically weaker spectacle lenses. The male to female ratio is 7:1 and one third of these eyes become legally blind.⁶

Lenses made from polycarbonates are less likely to shatter than glass lenses^{3,4}; however, even with these lenses spectacle wear presents an additional risk for blunt and penetrating injury during car accidents.⁵ Keeney *et al* showed that the tendency of a lens to shatter is defined by its stored elastic energy and its tendency to oscillate after the impact, both higher in glass lenses,⁷ and reduced by compressing the lens with a frame.⁸ Lens breakage may be reduced by inserting a 0.1 mm posterior lip in

plastic frames or a plastic liner to metal frames. There are several case reports of penetrating ocular injuries either from the spectacle frame or from shattered glass in patients travelling a modest speeds.^{9,10} Our case demonstrates the effect of a low speed collision on frameless spectacles with glass lenses, dramatically increasing the likelihood of ocular injury from airbag activation or relatively minor collisions. Although polycarbonates are often used in the manufacture of many frameless spectacles their mechanical strength has not been reported in the literature. This case raises doubts about the safety of these spectacles, especially when made with glass lenses.

RICHARD S B NEWSOM
Southampton Eye Unit, Southampton

TOM H WILLIAMSON
St Thomas's Hospital, London

Correspondence to: Mr R S B Newsom, Southampton Eye Unit, Southampton General Hospital, Tremona Road, Southampton SO16 6YD
Accepted for publication 13 January 2000

- Keeney AH. Estimating the incidence of spectacle lens injuries. *Am J Ophthalmol* 1972;73:289-91.
- Keeney AH, Fintleman EW, Estlow BR. Refractive correction and associated factors in spectacle glass. *Trans Am Ophthalmol Soc* 1971;60:321-35.
- Classe JG. An appeal for polycarbonate [editorial] [see comments]. *J Am Optom Assoc* 1997;68:141-2.
- John G, Feist RM, White MF, *et al*. Field evaluation of polycarbonate versus conventional safety. *South Med J* 1988;81:1534-6.
- Vichnin MC, Jaeger EA, Gault JA, *et al*. Ocular injuries related to air bag inflation. *Ophthalmic Surg Lasers* 1995;26:542-8.
- Parver LM, Dannenberg AL, Blacklow B, *et al*. Characteristics and causes of penetrating injuries reported to the national eye trauma registry, 1985-1991. *Public Health Rep* 1993;108:625-32.
- Keeney AH, Renaldo D. Newly defined lens and frame factors in the reduction of eye injuries. *Eye, Ear, Nose & Throat Monthly* 1973;52:19-24.
- Keeney AH, Fintleman E, Estlow B. Refractive correction and associated factors in spectacle glass. *Arch Ophthalmol* 1972;88:2-8.
- Gault JA, Vichnin MC, Jaeger EA, *et al*. Ocular injuries associated with eyeglass. *J Trauma* 1995;38:494-7.
- Molia LM, Stroh E. Airbag injury during low impact collision [letter]. *Br J Ophthalmol* 1996;80:487-8.

Ocular ectodermal syndrome of epibulbar dermoid and cutaneous myxovascular hamartoma

EDITOR,—Ocular ectodermal syndrome is a congenital disorder manifesting classically with epibulbar dermoids and aplasia cutis congenita. Systemic abnormalities may also accompany ocular ectodermal syndrome.¹⁻⁴ We describe the case of a newborn boy who presented with unilateral epibulbar dermoid and myxovascular hamartomas of the scalp. We believe that the association of epibulbar dermoid and myxovascular hamartoma of the skin represents an unusual variant of ocular ectodermal syndrome.

CASE REPORT

A newborn boy was noted at birth to have multiple serous purple blisters on the left scalp region, measuring 0.5 cm to 2.0 cm in base (Fig 1). Anterior fontanelle asymmetry was also recognised. The skin lesions were thought to be aplasia cutis congenita and a skin biopsy was performed. Histopathological examination of the biopsied skin revealed loose connective tissue in the dermis with an apparent absence of mature collagen, multiple blood vessels with thrombi, intimal hyperplasia and chronic inflammation, and few hair follicles, most consistent with pigmented myxovascular hamartoma.

At the 2 week examination, a corneal lesion in the left eye was noted and the child was referred to the oncology service at Wills Eye Hospital for evaluation. On examination, the vision was fix light in both eyes. The anterior segment examination of the left eye revealed an elevated, pink vascular conjunctival mass in the superotemporal quadrant measuring 12.0 mm × 4.0 mm in base and extending onto the cornea. The epibulbar mass was not biopsied as it appeared consistent with a choristoma, most probably dermoid, and it demonstrated no change in appearance and no effect on visual acuity (Fig 2). The right eye and the fundi of both eyes were normal.

The patient was the product of a normal vaginal delivery and an uncomplicated pregnancy. His birth weight was 2863 g, length 49.7 cm, and occipitofrontal circumference (OFC) 43.2 cm. There was no maternal history of tobacco, alcohol, or drug use. The

Table 1 Clinical findings documented in six reported patients with the ocular ectodermal syndrome

	Toriello <i>et al</i> (1993)		Gardner and Viljoen (1994)		Evers <i>et al</i> (1994)	Present case (1998)
	Patient 1	Patient 2	Patient 3	Patient 4	Patient 5	Patient 6
Birth weight (kg)	3.17	4.7	unknown	2.74	4.09	2.86
Birth OFC* (cm) (centile)	36 (>98th)	40.5 (>98th)	unknown	34 (10-25th)	38 (>98th)	43.2 (>98th)
Postnatal macrocephaly	-	+	+/-	-	+	-
Craniofacial anomalies						
Parietal bossing	-	+	+	+	-	-
Frontal bossing	-	-	-	-	+	-
Skull defect (location)	-	-	-	+	-	+
Prominent eyes	+	-	-	+	-	-
Epicanthal folds	-	+	+	+	-	-
Flat nasal bridge	-	+	+	+	-	-
Ocular anomalies						
Epibulbar dermoid	+	+	+	+	+	+
Other findings	chorioretinal atrophy; corneal opacity; strabismus		abnormal retinal pigment epithelium; hypermetropic astigmatism; strabismus; small disc right eye; large disc left eye	esotropia		
Ectodermal anomalies						
Aplasia cutis congenita	+	+	+	+	+	-
Skin hyperpigmentation	+	+	-	-	-	-
Skin myxovascular hamartoma	-	-	-	-	-	+

*Occipitofrontal circumference.

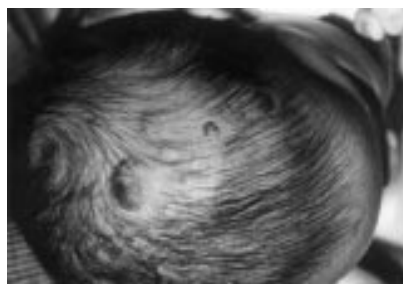

Figure 1 Small purple blistered lesions on the scalp consistent with myxomatous hamartomas.

parents were healthy, non-consanguineous, and with no history of congenital skin or ocular disorders.

Based on the systemic and ocular findings, a diagnosis of ocular ectodermal syndrome was suspected. Brain computed tomography revealed a left parietal bone defect separate from the anterior fontanelle abnormality. No other calvarial, cerebral, or ventricular system anomalies were found.

COMMENT

Aplasia cutis congenita, which is the hallmark of ocular ectodermal syndrome, is the congenital absence of skin presenting heterogeneously as an ulcerated, eroded, scarred, or blistered area with alopecia, usually on the scalp near the vertex.¹ Our patient was initially felt to have aplasia cutis congenita. However, pathological examination revealed pigmented myxovascular hamartoma of the scalp, characterised by the sporadic onset of asymmetric scalp lesions presenting with subcutaneous nodules. Our search of the literature failed to disclose any previous reports on the association of cutaneous myxovascular hamartoma and epibulbar dermoid, as described in our patient. We speculate that our case represents an extremely unusual variant of ocular ectodermal syndrome.

In addition to the epibulbar dermoid, other ocular findings in ocular ectodermal syndrome supported by the literature include corneal opacity and strabismus (Table 1).^{2,3} Besides the skin and eye findings, associated systemic findings in ocular ectodermal syndrome are numerous and can occur in several systems including the musculoskeletal system (Table 1) Cardiac anomalies in ocular ectodermal syndrome include atrial septal defect and neurological findings include psychomotor retardation, and seizures.¹⁻³ Although the skin and eye findings are both relatively innocuous,³ knowledge of the more serious associated systemic disorders, such as seizures, psychomotor retardation and various congenital defects, should be recognised.¹ In addition to the skin and ocular findings, our patient had parietal bone defect and anterior fontanelle asymmetry.

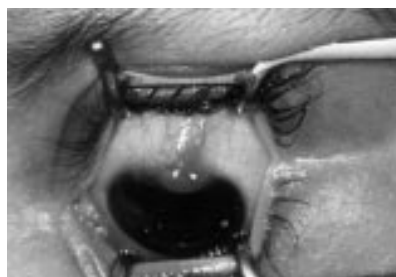

Figure 2 Oblong vascular corneoscleral dermoid in the superotemporal quadrant.

We believe that the association of atypical epibulbar dermoid and myxovascular hamartoma of the skin represents a different and extremely unusual variant of ocular ectodermal syndrome.

Supported by the Paul Kayser International Award of Merit in Retina Research, Houston, TX (J Shields) and Eye Tumor Research Foundation, Philadelphia, PA.

KAAN GÜNDÜZ
CAROL L SHIELDS
YELENA DOYCH

Oncology Service, Wills Eye Hospital,
Philadelphia, PA, USA

BRUCE SCHNALL

Pediatric Ophthalmology Service

JERRY A SHIELDS

Oncology Service

Correspondence to: Carol L Shields, MD, Oncology Service, Wills Eye Hospital, 900 Walnut Street, Philadelphia, PA 19107, USA

Accepted for publication 28 January 2000

- 1 Frieden IJ. Aplasia cutis congenita: a clinical review and proposal for classification. *J Am Acad Dermatol* 1986;14:646-60.
- 2 Toriello H, Lacassie Y, Droste P, et al. Provisionally unique syndrome of ocular and ectodermal defects in two unrelated boys. *Am J Med Genet* 1993;45:764-6.
- 3 Gardner J, Vilijoen D. Aplasia cutis congenita with epibulbar dermoids: further evidence for syndromic identity of the ocular ectodermal syndrome. *Am J Med Genet* 1994;53:317-20.
- 4 Evers MEJW, Dijkman-Neerincx RHM, Hamel BCJ. Oculo-ectodermal syndrome: a new case. *Am J Med Genet* 1994;53:378-9.
- 5 Shields JA, Shields CL. *Atlas of eyelid and orbital tumors*. Philadelphia: Lippincott, Williams and Wilkins, 1999.

Foveal translocation with secondary confluent laser for subfoveal CNV in AMD: 12 month follow up

EDITOR,—Foveal relocation surgery for the treatment of subfoveal choroidal neovascularisation (CNV) secondary to age related macular degeneration (AMD) has received significant publicity in the lay press and has given rise to some controversy reported in the *BJO*.¹ We describe the 12 month follow up of a case reported in the press in December 1998.

CASE REPORT

Mr JB, a 70 year old retired dentist was referred from another unit on 31 August 1998 with AMD and a history of poor vision for 5 years in the right eye and 5 months in the left. Refraction visual acuity was right eye 5/60 (+1.50/+1.50), left eye 6/60 (+2.25 sphere), Snellen equivalent. Figure 1A shows a subfoveal pure classic CNV of less than 1 disc area in extent in the left eye. The right eye was affected by end stage fibrotic scar. After full discussion of risk/benefit of confluent laser and the experimental nature of surgery he underwent surgery on 24 September 1998 (DW). Scleral plication was achieved by using 14 radially disposed sutures applied to the superotemporal quadrant of the globe. A three port pars plana vitrectomy was carried out and a subtotal retinal detachment was induced by subretinal infusions via three posterior retinotomies. The retina was reattached with a fluid/air exchange and the fovea was manipulated to its final position with a small bore flute needle. A radial fold formed in the upper nasal aspect of the fundus.

Figure 2A shows the retina on the 7th postoperative day with the superonasal fold and Figure 1B the midphase fluorescein angiogram (FA) showing the CNV now located superior to the fovea. On 8 October 1998 confluent laser was applied to the CNV (SPH) (Fig 2B). On 5 November 1998 refraction VA was 6/15; a small zone of persistent CNV was treated. On 8 January 1999 refraction VA was 6/12. Figure 2C shows a flattening retinal fold and Figure 1C a zone of recurrent CNV which received repeat confluent laser. On 12 February 1999 the post-laser follow up FA (Fig 1D) shows no persistent leakage; the VA had improved to 6/9. After 9 and 12 months VA was 6/18, N6 (-0.75/+0.50; +3.00 add) with no further evidence of CNV recurrence; the clinical appearance on 1 October 1999 is shown in Figure 2D.

COMMENT

At present, foveal relocation surgery is the only therapeutic option which aims to improve the vision for patients with CNV caused by AMD. The case we report gained a

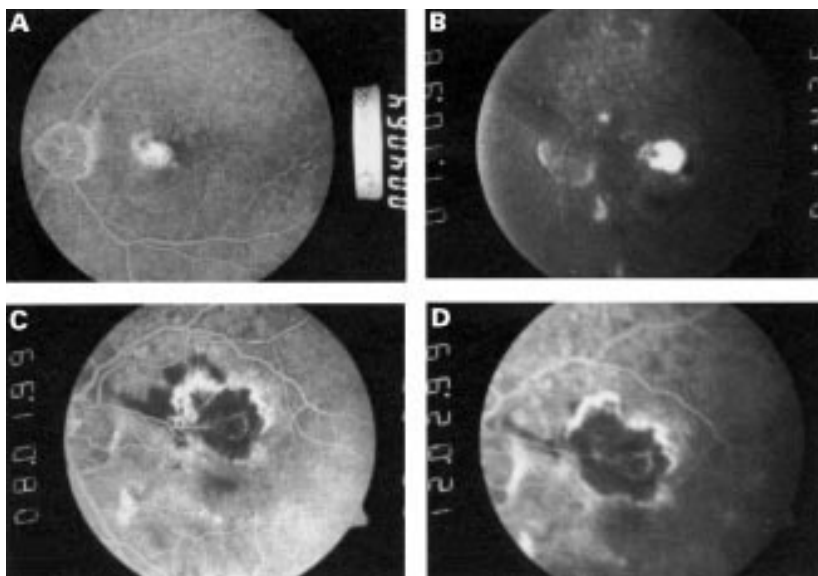


Figure 1 Fluorescein angiogram images before and after foveal relocation surgery (A) preoperatively, showing pure classic subfoveal CNV less than 1 disc area in extent; (B) 7 days postoperatively showing fovea located below CNV; (C) 5 months postoperatively showing recurrence; (D) 4 weeks after confluent laser to recurrence shown in (C) showing complete closure of CNV.

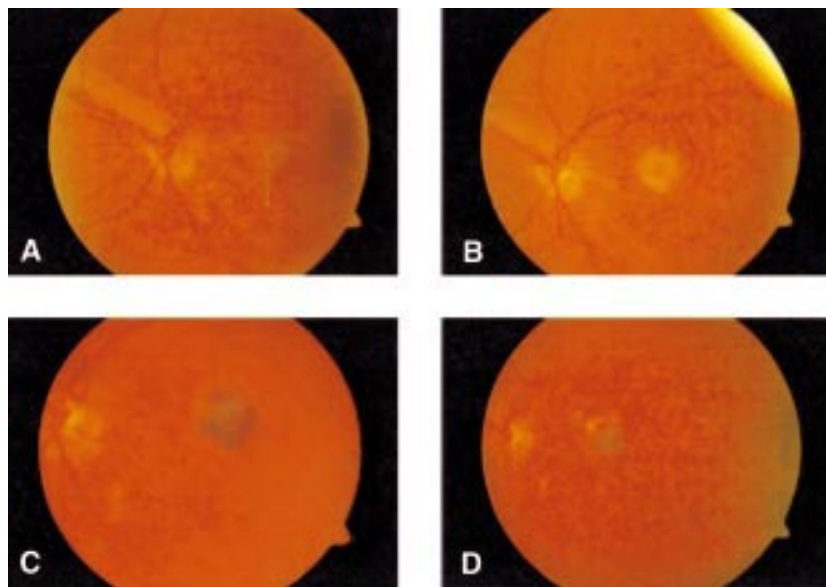


Figure 2 Colour fundus photographs of follow up after foveal relocation surgery: (A) 7 days postoperatively showing fold extending from disc into superonasal retina; (B) 1 week after (A) showing confluent laser applied to CNV and fovea located inferiorly to laser; (C) 5 months postoperative CNV recurrence with blood (VA = 6/9); (D) 12 months postoperatively (VA = 6/18).

substantial improvement of vision which was at its best 6 months postoperatively but still maintained at a good level after 12 months. The importance of close angiographic monitoring is illustrated by the development of recurrent CNV, which is not unexpected in laser treated CNV.²

Mr JB was one of the first patients to undergo foveal relocation as part of a pilot study performed with the approval of the Liverpool research ethics committee. The results and complications of a small consecutive series of patients treated without scleral plications or 360 retinotomies are reported in the *BjO*.³ The reports of our patients and those of other series in the literature clearly indicate that the vision can be made worse as well as better.³⁻⁶ Whether the overall surgical results are better than natural history remains unknown. A prospective randomised controlled trial is needed and we are in the process of mounting such a trial. We are encouraged by the fact that improvements in surgical techniques are reducing the risks of retinal detachment and proliferative vitreoretinopathy,^{3,7} and also by the long term benefit of a surgical approach to AMD as illustrated by this patient.

DAVID WONG
SIMON HARDING
IAN GRIERSON

St Paul's Eye Unit, Royal Liverpool University
Hospital, Prescot Street, Liverpool L7 8XP

Correspondence to: Mr Wong
shdwong@mail.msn.com

Accepted for publication 8 February 2000

- 1 Leaver PK. Trends in vitreoretinal surgery—time to stop and think. *Br J Ophthalmol* 1999;83:385–6.
- 2 Macular Photocoagulation Study Group. Persistent and recurrent neovascularization after laser photocoagulation for subfoveal choroidal neovascularization of age-related macular degeneration. *Arch Ophthalmol* 1994;112:489–99.
- 3 Wong D, Lois N. Foveal relocation by redistribution of the neurosensory retina. *Br J Ophthalmol* 2000;84:352–7.
- 4 Machemer R, Steinhilber UH. Retinal separation, retinotomy, and macular relocation: II. A surgical approach for age-related macular degeneration? *Graefes Arch Clin Exp Ophthalmol* 1993;231:635–41.

- 5 Wolf S, Lappas A, Weinberger AW, et al. Macular translocation for surgical management of subfoveal choroidal neovascularizations in patients with AMD: first results. *Graefes Arch Clin Exp Ophthalmol* 1999;237:51–7.
- 6 Lewis H, Kaiser PK, Lewis S, et al. Macular translocation for subfoveal choroidal neovascularization in age-related macular degeneration: a prospective study. *Am J Ophthalmol* 1999;128:135–46.
- 7 Eckardt C, Eckardt U, Conrad H. Macular rotation with and without counter-rotation of the globe in patients with age-related macular degeneration. *Graefes Arch Clin Exp Ophthalmol* 1999;237:313–25.

The teardrop sign: a rare dermatological reaction to brimonidine

EDITOR.—Brimonidine is a potent, highly selective α_2 adrenergic agonist used for the treatment of open angle glaucoma and ocular hypertension. It lowers intraocular pressure by decreasing aqueous humour production and increasing uveoscleral outflow.^{1,2} The most common ocular and periocular side effects of

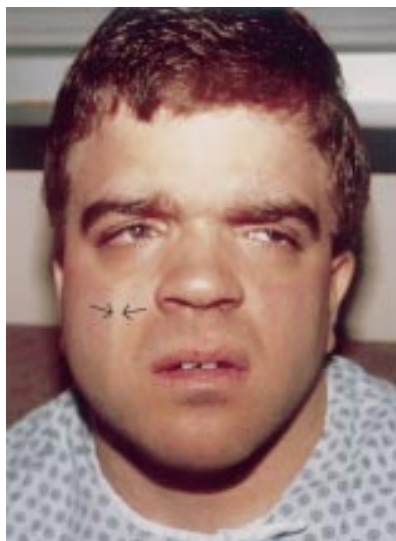

Figure 1 Linear skin blanching (arrows) after administration of brimonidine eye drops.

brimonidine include ocular hyperaemia, itching, burning, or stinging; foreign body sensation, blurred vision, allergic, toxic, or follicular conjunctivitis, and lid hyperaemia.³ The following case describes a previously unreported periocular reaction to this medication.

CASE REPORT

A 23 year old white man with cerebral palsy, autism, and chronic open angle glaucoma had been treated with brimonidine 0.2% ophthalmic solution for 5 months when erythematous cheeks were first noted. The patient's grandmother questioned the schoolteachers about his sun exposure and requested that sunblock be applied each day before outdoor activities to prevent what she thought was a sunburn. Later, after bilateral application of brimonidine eyedrops, the patient's cheeks blanched in a streak pattern where runoff of the excess eyedrop occurred (Fig 1). His cheeks became red and his conjunctiva became hyperaemic. These effects lasted throughout the day. They recurred with subsequent brimonidine administration and later resolved upon discontinuation of the drug.

To further investigate this unusual dermatological reaction, a brimonidine eyedrop was placed on the patient's cheek in a circular pattern. The contact area blanched almost immediately. The blanching intensified over a period of 30 minutes, and erythema developed in the surrounding skin. The blanching and erythema lasted approximately 20 hours before it began to fade. Complete resolution occurred by 22 hours. Another drop of brimonidine produced a similar regional blanching with surrounding erythema when placed on the patient's back.

COMMENT

Although brimonidine is almost 1000-fold more selective for the α_2 than the α_1 receptor subtype, its ability to cause vasoconstriction and reactive hyperaemia demonstrates that it has some α_1 mediated effects.¹ Brimonidine is 23–32-fold more α_2 selective than apraclonidine, and conjunctival blanching has been reported as an infrequent local effect of brimonidine, whereas it is seen in up to 85% of patients using apraclonidine.^{4,5}

Our patient demonstrated a pronounced α_1 mediated vascular reaction of the periocular skin. Brimonidine caused skin blanching and a surrounding hyperaemia that was not limited to the trail of the teardrop, but included the entire cheek. While the half life of intraocular pressure lowering effect of brimonidine is only 8–12 hours, the dermal vasoconstrictive effect of the drug persists for almost 24 hours.

Supported in part by a grant from Research to Prevent Blindness.

JENNIFER T SCRUGGS
JULIA WHITESIDE-MICHEL
MICHAEL C BRODSKY

Department of Ophthalmology, University of Arkansas
for Medical Sciences, Little Rock, Arkansas, USA

Correspondence to: Michael C Brodsky, MD,
Arkansas Children's Hospital, 800 Marshall, Little
Rock, AR, 72202, USA
brodskymichaelc@exchange.uams.edu
Accepted for publication 6 January 2000

- 1 Burke J, Schwartz M. Preclinical evaluation of brimonidine. *Surv Ophthalmol* 1996;41(suppl 1):S9–18.
- 2 Derick RJ, Robin AL, Walters TR, et al. Brimonidine tartrate: a one-month dose response study. *Ophthalmology* 1997;104:131–6.
- 3 Walters TR. Development and use of brimonidine in treating acute and chronic elevations of

intraocular pressure: a review of safety, efficacy, dose response, and dosing studies. *Surv Ophthalmol* 1996;41(suppl):S19-26.

- 4 Schuman JS, Horwitz B, Choplin NT, *et al.* A 1-year study of brimonidine twice daily in glaucoma and ocular hypertension: a controlled, randomized, multicenter clinical trial. *Arch Ophthalmol* 1997;115:147-52.
- 5 Robin AL. Short-term effects of unilateral 1% apraclonidine therapy. *Arch Ophthalmol* 1988;106:912-15.

The oil droplet sign

EDITOR.—Over the past 22 months we have collected a series of five patients with basal cell carcinomas of the lid who exhibit the oil droplet sign. The following case report is a representative example.

CASE REPORT

A 27 year old Zimbabwean male presented with a 14 month history of a progressively enlarging mass in the right lower lid.

Clinically there appeared to be a nodular basal cell carcinoma involving the lateral part of the right lower lid measuring 3.5 × 3.5 mm and involving the lid margin (Fig 1). There was no regional node involvement. On everting the lid there were multiple transparent droplets beneath the tarsal conjunctiva meas-

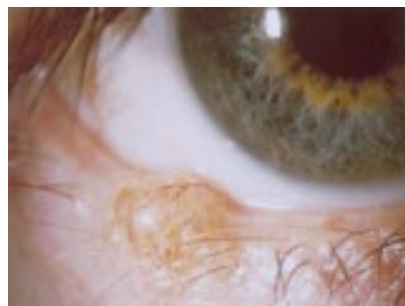

Figure 1 Photograph showing a 3.5 × 3.5 mm nodular basal cell carcinoma involving the right lower lid margin.

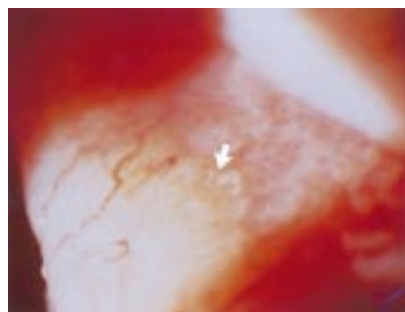


Figure 2 Photograph showing multiple lipid droplets (arrow) beneath the tarsal conjunctiva.

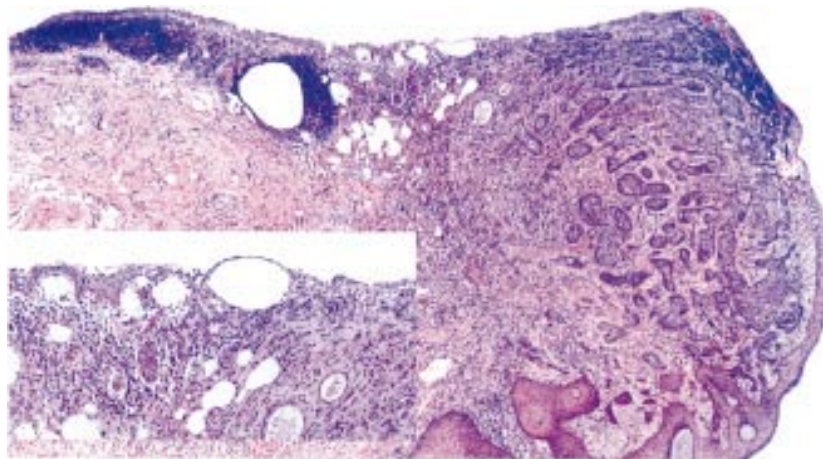


Figure 3 Photomicrograph of full thickness lid resection shows a basal cell carcinoma at the lid margin (superiorly) and along the conjunctiva (left). Lipid droplets are associated with an intense chronic inflammatory cell infiltrate (haematoxylin and eosin; original magnification ×27). The insert (from an adjacent section) shows the lipid droplets at higher magnification (×110).

uring between 0.25 and 0.50 mm in diameter (Fig 2, see arrow). The droplets lay directly over the area of tumour involvement and extended beneath the fornical conjunctiva. The droplets contained a clear or straw coloured fluid which had an oily appearance.

A full thickness wedge resection with 4 mm margins was performed. The lid was closed directly.

A light photomicrograph (Fig 3) of the full thickness lid resection shows a basal cell carcinoma at the lid margin (superiorly) and along the tarsal conjunctiva (left). Lipid droplets are associated with an intense chronic inflammatory cell infiltrate. Note one large droplet very close to the surface.

COMMENT

We have noted this sign over many years and have collected five cases over the past 22 months. To our knowledge this sign does not appear in the literature. The sign has only been noted among cases of basal cell carcinoma and has not been associated with other tumours such as squamous cell carcinomas or meibomian gland carcinomas.

We propose that the lipid droplets represent trapped meibomian gland secretions which cannot drain through obstructed or infiltrated meibomian gland ducts. It is interesting to note that the droplets appear beneath the conjunctiva rather than forming collections within the tarsus as is seen with chalazion formation. The invasion and destruction of the tarsus by tumour (as opposed to benign obstruction) may offer a route of least resistance whereby the droplets appear beneath the conjunctiva.

There are insufficient numbers of cases to state whether this is exclusively a sign associated with basal cell carcinomas or whether it may appear among the rarer tumour types. The sign is however a good indicator of an infiltrative process and may assist the clinician in the diagnostic process.

P HEYWORTH
J R O COLLIN

Moorfields Eye Hospital, London

P LUTHERT
Institute of Ophthalmology, London

Correspondence to: Mr P Heyworth, Moorfields Eye Hospital, City Road, London EC1V 2PD
susan.heyworth@virgin.net

Accepted for publication 27 January 2000

Manuscripts from all countries except the UK and the Republic of Ireland should be sent to Professor C Hoyt, Editor, *British Journal of Ophthalmology*, University of California, Department of Ophthalmology, 10 Kirkham Street, K 301, San Francisco, CA 94143-0730, USA (tel: 001 415 502-6871; fax: 001 415 514-1512).

Manuscripts from the UK and the Republic of Ireland should be sent to Professor Andrew Dick, UK Editor, *British Journal of Ophthalmology*, Division of Ophthalmology, University of Bristol, Lower Maudlin Street, Bristol BS1 2LX (tel: 0117 928-4827; fax: 0117 925-1421).



Foveal translocation with secondary confluent laser for subfoveal CNV in AMD: 12 month follow up

DAVID WONG, SIMON HARDING and IAN GRIERSON

Br J Ophthalmol 2000 84: 667
doi: 10.1136/bjo.84.6.667d

Updated information and services can be found at:
<http://bjo.bmj.com/content/84/6/667.5.full.html>

These include:

References

This article cites 7 articles, 2 of which can be accessed free at:
<http://bjo.bmj.com/content/84/6/667.5.full.html#ref-list-1>

Email alerting service

Receive free email alerts when new articles cite this article. Sign up in the box at the top right corner of the online article.

Notes

To request permissions go to:
<http://group.bmj.com/group/rights-licensing/permissions>

To order reprints go to:
<http://journals.bmj.com/cgi/reprintform>

To subscribe to BMJ go to:
<http://group.bmj.com/subscribe/>