

ORIGINAL ARTICLES—Clinical science

Sorsby fundus dystrophy without a mutation in the TIMP-3 gene

Jacqueline J M Assink, Eric de Backer, Jacoline B ten Brink, Takeya Kohno, Paulus T V M de Jong, Arthur A B Bergen, Françoise Meire

Department
Ophthalmogenetics,
The Netherlands
Ophthalmic Research
Institute, Netherlands
J J M Assink
J B ten Brink
P T V M de Jong
A A B Bergen

Department
Epidemiology and
Biostatistics, Erasmus
University Rotterdam,
Netherlands
J J M Assink
P T V M de Jong

(continued over page)

Abstract

Aims—To examine a large family with an autosomal dominant fundus dystrophy and to investigate whether or not mutations in TIMP-3 gene were involved.

Methods—A large family of 58 individuals with an autosomal dominant fundus dystrophy was examined ophthalmologically. A DNA linkage analysis in the 22q12.1-q13.2 region was performed. The TIMP-3 gene was screened for mutations in all five exons.

Results—In this large family 15 individuals were affected. All other individuals were found to be clinically unaffected. Pisciform flecks in the midperiphery and drusen-like deposits were the most typical ophthalmological finding in this family and were encountered from the fifth decade on. Chorioretinal atrophy and

neovascularisation with disciform lesions characterised the disease from the sixth decade on. Linkage analysis using an affected only analysis, showed a maximum positive lod score of 3.94 at $\theta = 0.0$ with marker D22S283. No mutations possibly causing Sorsby fundus dystrophy were found in either the exonic sequences, the promotor region, or the 3'UTR.

Conclusion—The family in this pedigree has an autosomal dominant fundus dystrophy, which is most probably Sorsby fundus dystrophy. Although, in the linkage analysis, significant positive lod scores were found with the region 22q12.1-q13.2, no causative mutations could be identified in the TIMP-3 gene.

(Br J Ophthalmol 2000;84:682-686)

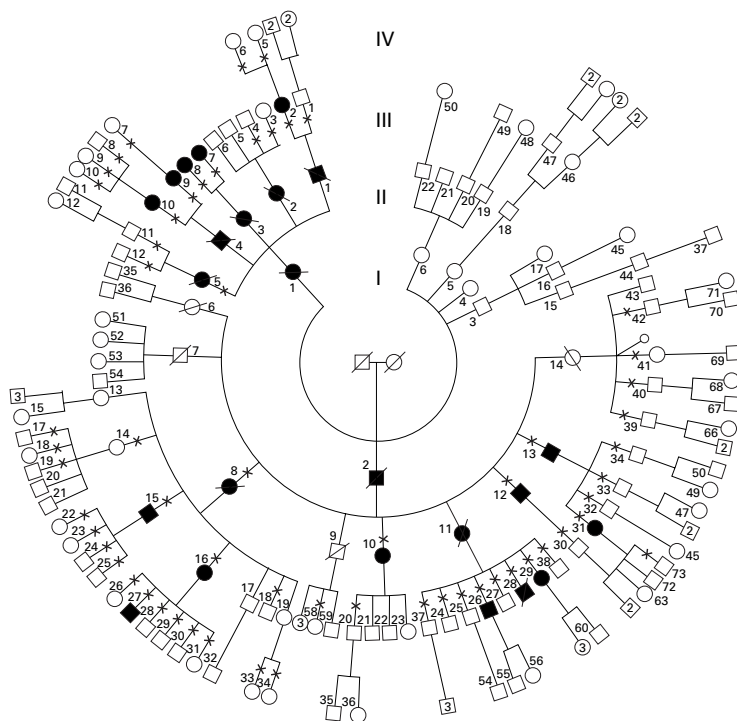


Figure 1 Pedigree of the family with Sorsby fundus dystrophy. Males are represented by squares and females are represented by circles; solid symbols represent individuals with Sorsby fundus dystrophy, open symbols represent normal individuals. A cross represents the individuals who were clinically examined and used for linkage analysis.

Sorsby fundus dystrophy is an autosomal dominant disorder in which patients lose central vision during the fourth or fifth decade of life.¹ Monogenic maculopathies, such as Sorsby fundus dystrophy, have been suggested as a possible mendelian model for the study of the genetically more complex age related macular degeneration (AMD). However, de la Paz *et al* excluded TIMP-3 gene in 38 families as a candidate gene for AMD.² Age related macular degeneration is the leading cause of permanent visual impairment among the elderly in western countries, affecting over 10% of the population aged 75 years and over.^{3,4} Identification of molecular defects underlying AMD has been hampered by the late onset of symptoms, as well as the clinical heterogeneity commonly observed in the disorder.

Sorsby *et al* described five families with a fundus dystrophy¹ that occurred in several generations in a dominant pedigree pattern. The dystrophy became manifest at about the age of 40 years, the earliest manifestations were colour vision deficits and abnormal yellow-white deposits; followed by a central macular lesion with oedema, haemorrhage, and exudates. In the subsequent years, atrophy with pigmentation of the central area and extension peripherally occurred. The choroidal vessels became exposed and appeared somewhat sclerotic. Within about 35 years after onset the

**Department
Ophthalmology,
University Hospital of
Ghent, Belgium**

E de Backer
T Kohno
F Meire

**Department
Ophthalmology,
Academic Medical
Hospital, Amsterdam,
Netherlands**
P T V M de Jong

Correspondence to:
Francoise Meire,
Department of
Ophthalmology, University
Hospital of Ghent, De
Pintelaan 185, B 9000
Ghent, Belgium
francoise.meire@rug.ac.be

Accepted for publication
14 January 2000

Table 1 Ophthalmological data of patients with Sorsby fundus dystrophy

Patient	Age (years)	Pisciform flecks		Drusen-like deposits	Chorioretinal atrophy	Disciform lesion		Visual acuity	
		Both eyes	Both eyes	Both eyes	Both eyes	RE	LE	RE	LE
II,5	60	+	+	+	-	P	-	1.0	1.0
II,8	74	np	np	+	M	-	-	0.01	0.05
II,10	78	-	-	+	M	M	-	0.01	0.01
II,12	60	-	+	-	M	M	-	<0.05	<0.05
II,13	80	-	+	+	-	-	-	0.4	0.01
III,2	50	+	-	-	-	-	-	1.0	1.0
III,7	55	+	+	+	-	M	-	1.0	0.01
	60	-	+	+	P	M	-	1.0	0.01
	63	-	+	+	RD	M	-	LP	0.01
III,8	55	+	-	-	-	-	-	1.0	1.0
III,9	46	np	np	-	-	-	-	1.0	1.0
	59	+	+	+	P	-	-	0.8	0.8
	60	+	+	+	P	-	-	0.1	0.2
	63	-	-	+	P	-	-	0.03	LP
III,10	52	+	+	-	-	-	-	1.0	1.0
III,15	49	-	+	-	M	-	-	0.01	1.0
	60	-	+	+	M	-	-	LP	0.5
III,16	59	+	+	-	-	-	-	1.0	1.0
III,26	59	+	+	-	-	-	-	1.0	1.0
III,28	54	+	+	-	-	-	-	np	np
III,29	35	+	-	-	-	-	-	1.0	1.0
III,31	48	-	+	-	-	-	-	0.6	1.0
IV,27	31	-	+	-	-	-	-	1.0	1.0

np = not performed; M = macular disciform lesion; P = peripapillary disciform lesion; RD = retinal detachment; LP = light perception; III,31 right eye amblyopia.

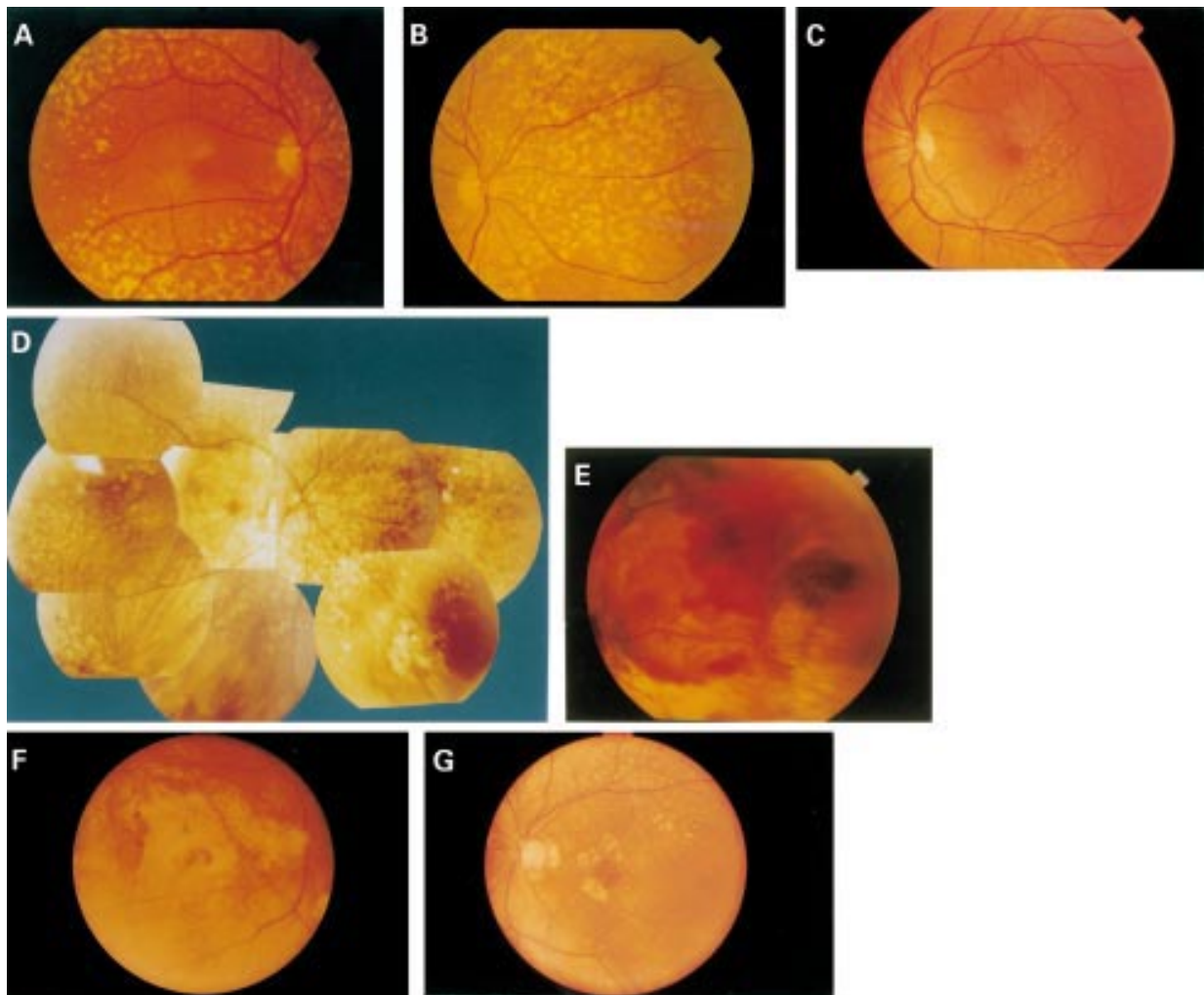


Figure 2 (A) Pisciform flecks at the posterior pole (patient III,29). (B) Flecks nasally to the pupil (patient III,29). (C) Drusen-like deposits (patient III,31). (D) Extensive chorioretinal atrophy (patient III,9). (E) Choroidal neovascularisation with haemorrhages and exudation (patient III,7). (F) Disciform lesion with fibrotic reaction extending far outside the macula (patient II,8 right eye). (G) Pisciform flecks at the arcades, atrophic patches surrounding the macula (patient II,8 left eye).

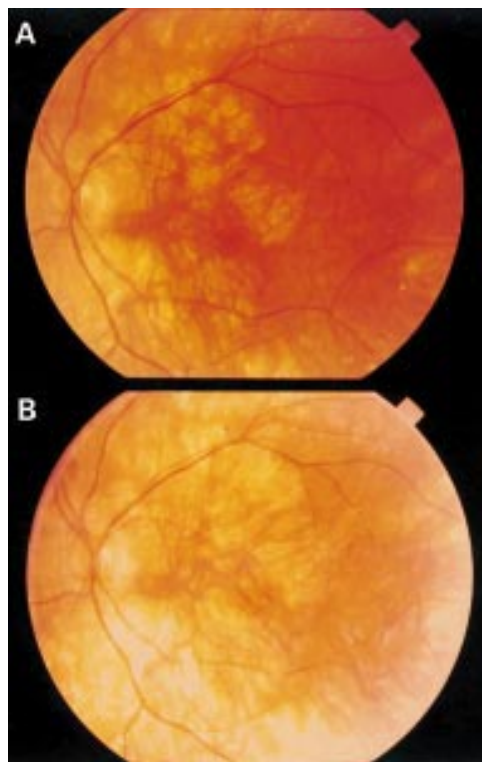


Figure 3 (A) Patient III,9 at the age of 60 years; left eye visual acuity 0.2, notice atrophy of the capillary. (B) Same patient (III,9) at the age of 63; left eye visual acuity decreased to light perception due to involvement of the macula by the choriocapillary atrophy.

entire fundus was involved. The choroidal vessels disappeared by this stage and the terminal picture was one of extensive choroidal atrophy. Night blindness was not a consistent feature.

Sorsby's observations have been extended in the descendants of the original families with Sorsby fundus dystrophy.⁵⁻⁷ Also a genealogical link between these families and an Australian family with Sorsby fundus dystrophy have been reported.^{8,9} Hamilton *et al*¹⁰ described a seven generation family with Sorsby fundus dystrophy. Later on, Weber *et al*¹¹ demonstrated linkage of the Sorsby fundus dystrophy locus with DNA markers on chromosome 22q13-qter.

In parallel, Apte *et al*¹² isolated a novel gene member of the tissue inhibitors of metalloproteinases (TIMPs), TIMP-3, and localised it to human chromosome 22q12.1-q13.2. TIMPs are natural inhibitors of matrix metalloproteinases (MMPs), which are involved in the synthesis and degradation of extracellular matrix (ECM) molecules, thereby remodelling the ECM continuously. Because of the co-

localisation of TIMP-3 and Sorsby fundus dystrophy on chromosome 22 and its pivotal physiological role in extracellular matrix remodelling, Weber *et al*¹³ studied TIMP-3 as a candidate gene for Sorsby fundus dystrophy. Point mutations in the TIMP-3 gene were demonstrated in affected members of two Sorsby fundus dystrophy pedigrees. These mutations predicted disruption of the tertiary structure and thus the functional properties of the mature protein.

In this study we examined a large family with a Sorsby fundus dystrophy to investigate whether mutations in TIMP-3 gene are involved.

Materials and methods

A large family of 58 individuals with a five generation history of fundus dystrophy was examined by indirect ophthalmoscopy (see Fig 1), followed by fluorescein and indocyanine green angiography in case fundus lesions were found on ophthalmoscopy. No genealogical link between this family and the families originally described by Sorsby was established. Informed consent was obtained from all individuals. Two patients (II,5 and II,8) were examined in our department in 1975 and 1984, respectively; both died before the start of this study. Another individual (III,28) died during the examination period and underwent ophthalmoscopy only.

Blood samples from all individuals were obtained. Standard techniques were used to extract DNA, and polymerase chain reaction (PCR) and CA repeats analyses were performed as described elsewhere.¹⁴

Because the clinical data were compatible with a dominant mode of inheritance and the diagnosis of Sorsby fundus dystrophy was proposed after examination of the individuals, a linkage analysis in the 22q12.1-q13.2 region was performed. Markers D22S275, D22S304, D22S283, and D22S274^{11,15} were used to perform a linkage analysis. We have used an affected only analysis. The data were analysed with the program package LINKAGE, version 5.1. Two point Z values were calculated with the program LINKMAP. The fixed order and genetic distances were set as follows: D22S275 - 0.07 - D22S304 - 0.066 - D22S283 - 0.168 - D22S274.

Because the linkage analysis showed significant evidence for linkage to this region, the TIMP-3 gene was screened for mutations. The likely position of TIMP-3 is between D22S275 and D22S283. We used all sequence and prim-

Table 2 Electrophysiological data of patients with Sorsby fundus dystrophy

Patient	Age (years)	Visual acuity		Dark adaptation (threshold log unit)	EOG (Arden index)		ERG response	
		RE	LE		RE	LE	photopic	scotopic
II,5	60	1.0	1.0	1.5 log U ↑	118%	111%	slight↓	severe↓
II,8	74	0.01	0.05	2 log U ↑	100%	100%	slight↓	absent
III,9	46	1.0	1.0	normal	np	np	normal	normal
	60	1.0	1.0	1 log U ↑	120%	111%	slight↓	severe↓
III,10	49	1.0	1.0	np	118%	120%	normal	normal
	56	1.0	1.0	1 log U ↑	120%	111%	slight↓	severe↓
III,15	59	0.8	0.8	1 log U ↑	np	np	severe↓	absent
	49	0.01	1.0	2 log U ↑	123%	128%	slight↓	severe↓

np = not performed.

Table 3 Two point Z values for linkage between markers on chromosome 22 and SFD

Locus	Z at $\theta =$						
	0.0	0.01	0.05	0.1	0.2	0.3	0.4
D22S275	-1.95	1.68	2.14	2.11	1.69	1.08	0.42
D22S304	3.89	3.81	3.48	3.05	2.17	1.28	0.49
D22S283	3.94	3.86	3.54	3.14	2.29	1.42	0.60
D22S274	-6.78	-3.14	-1.16	-0.41	0.10	0.15	0.05

ers available to us^{16 17} of the *TIMP-3* gene for the single strand conformational polymorphism (SSCP) of the five exons, the promoter region, and 3'UTR. SSCP analyses were performed as described elsewhere.¹⁸ Also, further analysis with sequencing, using the dideoxy nucleotide chain termination method, was performed. The direct sequences of exon 5 could not be analysed beyond doubt, therefore PCR amplified exon 5 fragments were cloned into the pCR vector (Invitrogen) of the TA cloning kit and multiple colonies were sequenced.

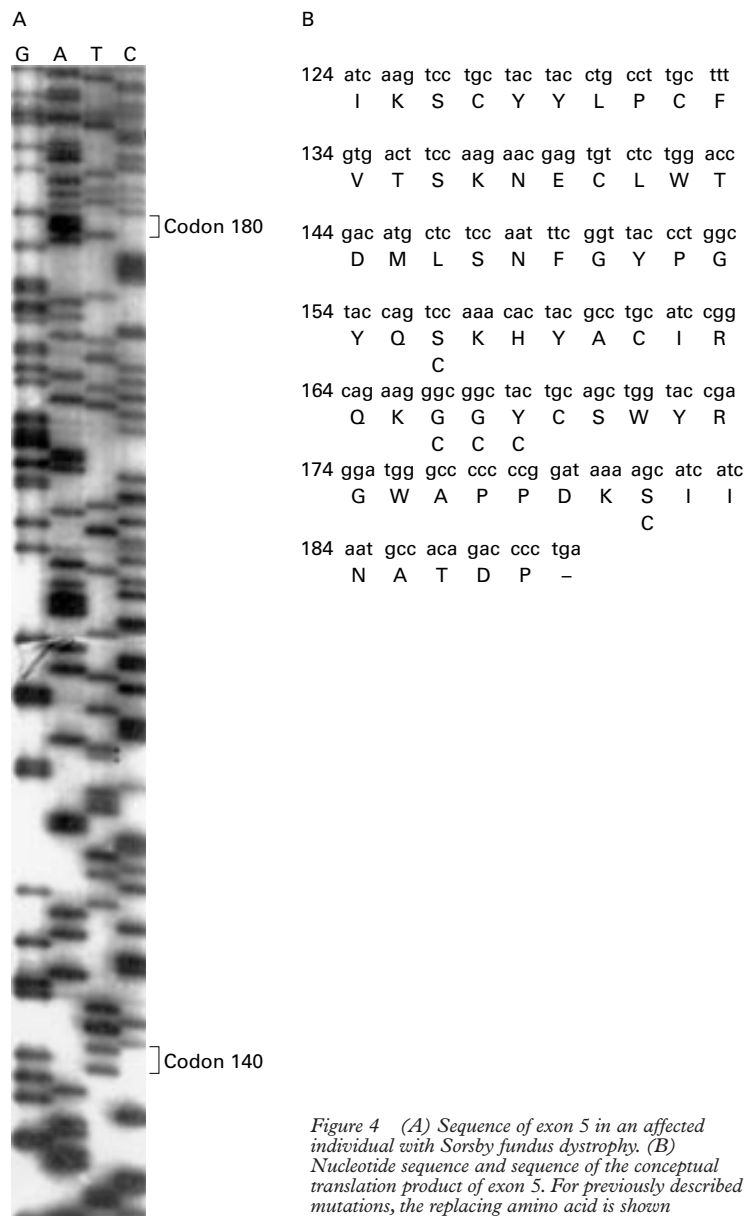


Figure 4 (A) Sequence of exon 5 in an affected individual with Sorsby fundus dystrophy. (B) Nucleotide sequence and sequence of the conceptual translation product of exon 5. For previously described mutations, the replacing amino acid is shown underneath the consensus amino acid.

Results

In this large family 15 individuals were affected with Sorsby fundus dystrophy. All other individuals were found to be unaffected. However, some of the healthy individuals have not reached the age of 40 years and therefore they might develop the disease in the coming years.

The ophthalmological data of these 15 patients are summarised in Table 1. The results of two patients, who were examined in the past, are also included in this table. The affected individuals had a large variety of ophthalmoscopic findings (see Figs 2 and 3). In early stage of the disease, in patients in the fifth and sixth decade, pisciform yellow flecks at the level of the arcades and midperiphery were the most typical findings in this family (Fig 2A, B). Most patients had, additionally, round drusen-like deposits (Fig 2C). These flecks became less apparent with age and disappeared when atrophy supervened. In the latest stage of the disease extensive chorioretinal atrophy and sclerosis was observed (Fig 2D). Macular (seven eyes) and peripapillary (three eyes) choroidal neovascularisation occurred. The onset of neovascularisation in our family was at the age of 49 years in one patient and after the age of 55 years in the others. Exudative inferior retinal detachment was observed in one patient (III,7) (Fig 2E). Pisciform flecks fluoresced like window defects when fluorescein angiography was performed in young symptomatic patients, no delayed choroidal filling was observed. Fluorescein angiography in older patients indicates chorioretinal atrophy and choroidal neovascularisation. Electrophysiology and dark adaptation tests were only performed in a small number of patients (Table 2). In all patients the electro-oculogram was abnormal in an early stage of the disease and was indicative for retinal pigment epithelium dysfunction. The dark adaptation showed a slight elevation of rod threshold. Electroretinogram remained normal until chorioretinal atrophy became manifest. Progressive atrophy was reflected by severe impairment of rod function and relatively preserved cone function. The visual acuity in the patients followed the different stages of the disease. Visual acuity decreased abruptly when central maculopathy was observed of either a disciform or an atrophic nature. Extension of geographic retinal atrophy progressed within 4 years in patient III,9 with a dramatic deterioration of the visual acuity from 0.8 in both eyes to 0.03 right eye and light perception left eye when the fovea became involved (Fig 3A, B).

The linkage analysis with the marker D22S275 revealed a maximum lod score of 2.14 at $\theta = 0.05$ and with marker D22S274 a maximum lod score of 0.15 at $\theta = 0.3$ was found. Both markers D22S304 and D22S283 revealed significantly positive lodscores of 3.89 and 3.94, respectively, at $\theta = 0.0$. The results of the linkage analysis are given in Table 3. Marker D22S275 revealed a recombination in individual III,29. Marker D22S274 revealed a recombination in individuals III,8, III,28, and IV,27.

The SSCP of the five exons, promotor region, and 3'UTR showed no changes between unaffected and affected individuals. Nevertheless, all exons of the TIMP-3 gene were sequenced in one healthy person and in at least two affected individuals. No mutations possibly causing Sorsby fundus dystrophy were found in either the exons or their splice sites. A sequence gel of exon 5 of one of the affected individuals is shown in Figure 4A.

Discussion

In this family with Sorsby fundus dystrophy, the presence of the midperipheral yellow pisciform flecks was the most typical finding. They were invariably bilateral and have not been described in previous Sorsby pedigrees. The yellow flecks may correspond to the subretinal deposits that were reported in Sorsby fundus dystrophy. Such deposits were described in Bruch's membrane by Capon *et al.*¹⁹ after a light and electron microscopic study of the eyes of a descendant of the Kempster family. A localised destruction of the pigment epithelium was the window defect on fluorescein angiography. In later stages of the disease progressive extensive peripheral and in some patients central atrophy occurred. Loss of central vision was due to disciform lesions or central geographic atrophy.

So far, six different mutations have been identified which are implicated in Sorsby fundus dystrophy. These are, besides a splice site mutation in the intron4/exon5 junction,²⁰ Tyr168Cys,¹³⁻¹⁷ Ser181Cys,^{13 21} Ser156Cys,²² Gly166Cys,²³ and Gly167Cys²⁴. It is remarkable that these five mutations were identified in a 80 bp interval at exon 5 of the TIMP-3 gene (see Fig 4B). Furthermore, these five mutations all lead to the introduction of an additional cysteine residue in the peptide sequence. In the Sorsby fundus dystrophy family described here we could not identify a mutation in this critical region of exon 5 (Fig 4A) or in the splice sites. Although linkage was found with the region 22q12.1-q13.2, no mutations were found in all five exons of the TIMP-3, including the splice sites. Also the promotor region and 3'UTR revealed no mutations.

Possible explanations for finding no mutations in these exons could be that the introns or regulatory sequences of the TIMP-3 gene contain mutations, which were not yet identified. Another explanation for this finding could be that the disease in this family might be caused by mutations in another gene located in the chromosomal vicinity of the TIMP-3 gene, similar to the heterogeneity on the X chromosome where at least two RP genes are located close to each other.²⁵ We also should consider the possibility that the disease, which is described in this paper, resembles Sorsby fundus dystrophy, but in fact is a different disease or a different type of Sorsby fundus dystrophy. An argument for this explanation could be that, although these spots may correspond to the subretinal deposits which were reported in Sorsby fundus dystrophy previously, the presence of the midperipheral yellow spots was the most typical finding in this family.

In conclusion, the family in this pedigree is suffering from an autosomal dominant fundus dystrophy, which is most probably Sorsby fundus dystrophy. In the linkage analysis significant positive lod scores were found with the region 22q12.1-q13.2. No causative mutations could be identified in the TIMP-3 gene.

The authors would like to thank Dr B H Weber for providing the primers of the TIMP-3 gene. The ophthalmological research was supported by a grant from the organisation "Les Amis des Aveugles".

- Sorsby A, Mason MEJ, Gardner N. A fundus dystrophy with unusual features. *Br J Ophthalmol* 1949;33:67-97.
- De La Paz MA, Pericak-Vance MA, Lennon F, *et al.* Exclusion of TIMP3 as a candidate locus in age-related macular degeneration. *Invest Ophthalmol Vis Sci* 1997;38:1060-5.
- Klein R, Klein BE, Linton KLP. Prevalence of age-related maculopathy. The Beaver Dam Eye Study. *Ophthalmology* 1992;99:933-43.
- Vingerling JR, Dielemans I, Hofman A, *et al.* The prevalence of age-related maculopathy in the Rotterdam Study. *Ophthalmology* 1995;102:205-10.
- Hoskin A, Sehmi K, Bird AC. Sorsby's pseudoinflammatory macular dystrophy. *Br J Ophthalmol* 1981;65:859-65.
- Capon MRC, Polkinghorne PJ, Fitzke FW, *et al.* Sorsby's pseudoinflammatory macula dystrophy: Sorsby's fundus dystrophies. *Eye* 1988;2:114-22.
- Polkinghorne PJ, Capon MRC, Berninger T, *et al.* Sorsby's fundus dystrophy: a clinical study. *Ophthalmology* 1989;96:1763-8.
- Fraser HB, Wallace DC. Sorsby's familial pseudoinflammatory macular dystrophy. *Am J Ophthalmol* 1971;71:1216-20.
- Kalmus H, Seedburgh D. Probable common origin of a hereditary fundus dystrophy (Sorsby's familial pseudoinflammatory macular dystrophy) in an English and Australian family. *J Med Genet* 1976;13:271-6.
- Hamilton WK, Ewing CC, Ives EJ, *et al.* Sorsby's fundus dystrophy. *Ophthalmology* 1989;96:1755-62.
- Weber BHF, Vogt G, Wölz W, *et al.* Sorsby's fundus dystrophy is genetically linked to chromosome 22q13-qter. *Nat Genet* 1994;7:158-61.
- Apte SS, Mattei MG, Olsen BR. Cloning of the cDNA encoding human tissue inhibitor of metalloproteinases-3 (TIMP-3) and mapping of the TIMP3 gene to chromosome 22. *Genomics* 1994;19:86-90.
- Weber BHF, Vogt G, Pruett RC, *et al.* Mutations in the tissue inhibitor metalloproteinases-3 (TIMP3) in patients with Sorsby's fundus dystrophy. *Nat Genet* 1994;8:352-6.
- Van Soest S, van den Born LL, Gal A, *et al.* Assignment of a gene for autosomal recessive retinitis pigmentosa (RP12) to chromosome 1q31-q32.1 in an inbred and genetically heterogeneous disease population. *Genomics* 1994;22:499-504.
- Gregory CY, Wijesuriya S, Evans K, *et al.* Linkage refinement localises Sorsby fundus dystrophy between markers D22S275 and D22S278. *J Med Genet* 1995;32:240-1.
- Stöhr H, Roomp K, Felbor U, *et al.* Genomic organization of the human tissue inhibitor of metalloproteinases-3. *Genome Res* 1995;5:483-7.
- Felbor U, Stöhr H, Amann T, *et al.* A second independent Tyr168Cys mutation in the tissue inhibitor of metalloproteinases-3 (TIMP3) in Sorsby's fundus dystrophy. *J Med Genet* 1996;33:233-6.
- Orita M, Iwahana H, Kanazawa H, *et al.* Detection of polymorphisms of human DNA by gel electrophoresis as single-strand conformation polymorphisms. *Proc Natl Acad Sci USA* 1989;71:534-50.
- Capon MR, Marshall J, Krafft JI, *et al.* Sorsby fundus dystrophy. A light and electron microscopic study. *Ophthalmology* 1989;96:1769-77.
- Tabata Y, Isashiki Y, Kamimura K, *et al.* A novel splice site mutation in the tissue inhibitor of the metalloproteinases-3 gene in Sorsby's fundus dystrophy with unusual clinical features. *Hum Genet* 1998;103:179-82.
- Carrero-Valenzuela RD, Klein ML, Weleber RG, *et al.* Sorsby fundus dystrophy. A family with the Ser181Cys mutation of the tissue inhibitor of metalloproteinases 3. *Arch Ophthalmol* 1996;114:737-8.
- Felbor U, Stöhr H, Amann T, *et al.* A novel Ser156Cys mutation in the tissue inhibitor of metalloproteinases-3 (TIMP3) in Sorsby's fundus dystrophy with unusual clinical features. *Hum Mol Genet* 1995;4:2415-16.
- Felbor U, Suvanto EA, Forsius HR, *et al.* Autosomal recessive Sorsby fundus dystrophy revisited: molecular evidence for dominant inheritance. *Am J Hum Genet* 1997;60:57-62.
- Jacobson SG, Cideciyan AV, Regnath G, *et al.* Night blindness in Sorsby's fundus dystrophy reversed by vitamin A. *Nat Genet* 1995;11:27-32.
- Bergen AA, Van den Born LI, Schuurman EJ, *et al.* Multipoint linkage analysis and homogeneity tests in 15 Dutch X-linked retinitis pigmentosa families. *Ophthalmic Genet* 1995;16:63-70.



Sorsby fundus dystrophy without a mutation in the TIMP-3 gene

Jacqueline J M Assink, Eric de Backer, Jacoline B ten Brink, et al.

Br J Ophthalmol 2000 84: 682-686

doi: 10.1136/bjo.84.7.682

Updated information and services can be found at:

<http://bjo.bmj.com/content/84/7/682.full.html>

References

These include:

This article cites 24 articles, 9 of which can be accessed free at:

<http://bjo.bmj.com/content/84/7/682.full.html#ref-list-1>

Article cited in:

<http://bjo.bmj.com/content/84/7/682.full.html#related-urls>

Email alerting service

Receive free email alerts when new articles cite this article. Sign up in the box at the top right corner of the online article.

Notes

To request permissions go to:

<http://group.bmj.com/group/rights-licensing/permissions>

To order reprints go to:

<http://journals.bmj.com/cgi/reprintform>

To subscribe to BMJ go to:

<http://group.bmj.com/subscribe/>