

Amniotic membrane graft for primary pterygium: comparison with conjunctival autograft and topical mitomycin C treatment

David Hui-Kang Ma, Lai-Chu See, Su-Bin Liao, Ray Jui-Fang Tsai

Abstract

Aim—To study the efficacy and safety of amniotic membrane graft as an adjunctive therapy after removal of primary pterygium, and to compare the clinical outcome with conjunctival autograft and topical mitomycin C.

Methods—80 eyes of 71 patients with primary pterygia were treated with excision followed by amniotic membrane graft. The result was compared retrospectively with 56 eyes of 50 patients receiving conjunctival autograft, and 54 eyes of 46 patients receiving topical mitomycin C. Patients were followed for at least 6 months, and the averaged follow up periods for the three groups were 13.8, 22.8, and 18.4 months, respectively.

Results—There were three recurrences (3.8%) in the amniotic membrane graft group, three recurrences (5.4%) in the conjunctival autograft group, and two recurrences (3.7%) in the topical mitomycin C group. There was no significant difference in recurrence rate among the three groups ($p = 0.879$). No major complications occurred in the amniotic membrane graft group or the conjunctival autograft group. One case of infectious scleritis due to scleral ischaemia occurred in the topical mitomycin C group.

Conclusion—This study showed that amniotic membrane graft was as effective as conjunctival autograft and mitomycin C in preventing pterygium recurrence, and can be considered as a preferred grafting procedure for primary pterygium.

(Br J Ophthalmol 2000;84:973-978)

Department of
Ophthalmology, Chang
Gung Memorial
Hospital, Taoyuan,
Taiwan
D H-K Ma
S-B Liao
R J-F Tsai

Department of Public
Health, College of
Medicine, Chang Gung
University, Taoyuan,
Taiwan
L-C See

Correspondence to:
Ray Jui-Fang Tsai, 2F 350
Section 4 Cheng Kung Road,
Taipei, Taiwan, 114
raysai@ms4.hinet.net

Accepted for publication
18 April 2000

decreasing corneal scarring following excimer laser photoablation,⁷ prevention of adhesion after trabeculectomy,⁸ and to reconstruct conjunctival defect after pterygium removal.^{9, 10} A previous study reported that amniotic membrane grafts were less effective than conjunctival autografts for pterygium surgery.⁹ However, as more is understood about the molecular mechanisms by which amniotic membrane transplantation inhibits pathological neovascularisation,¹¹⁻¹³ scar formation,¹⁴ and inflammation^{15, 16} in various ocular surface diseases, it is reasonable to hypothesise that with proper management, amniotic membrane grafts may yield better result than previously reported in reducing pterygium recurrence. We report the clinical outcome after amniotic membrane graft for primary pterygium among ethnic Chinese patients in Taiwan. The results are compared retrospectively with those patients receiving conjunctival autograft and postoperative topical mitomycin C.

Materials and methods

PATIENTS

From 1993 to 1997, 80 consecutive eyes of 71 patients with primary pterygium (M:F = 35:36, mean age 56.7 (SD 11.3), range 31-83 years) that met the inclusion criteria (see below) were enrolled prospectively in this study. To be enrolled, these patients had been questioned and medical data reviewed in detail that none had major systemic diseases such as diabetes mellitus or collagen vascular diseases, and complete ophthalmic examinations including visual acuity, intraocular pressure, slit lamp biomicroscopy, and funduscopy were performed to assure that none of them had major eye diseases such as dry eye, cicatricial pemphigoid, glaucoma, or vitreoretinal disease. In all cases in the amniotic membrane graft group, the size of the pterygium was at least 2 mm (2.0-8.0, mean 4.4 (1.4) mm) into the cornea.¹⁷ All patients had a minimum follow up of 6 months (6-43 months, mean 13.8 (10.4) months) at the time of analysis of the data. The clinical results were compared retrospectively with those patients who received conjunctival autograft and topical mitomycin C for primary pterygium between 1990 and 1993, which were also performed by the same surgeon (DHKM). For the conjunctival autograft group, there were 56 eyes of 50 patients (M:F = 19:31, mean age 56.4 (11.9) years, range 33-76 years). For the topical mitomycin C group, there were 54 eyes of 46 patients (M:F = 21:25, mean age 57.8 (12.2)

Pterygium is a common worldwide external eye disease, affecting populations especially in tropical and subtropical areas. To prevent recurrence, two major adjunctive therapies are usually performed: (1) the application of antimetabolites, and (2) conjunctival or limbal autograft. Although many other therapeutic modalities have been proposed, it requires extensive studies of efficiency and safety before a new procedure can be considered as ideal.

Recently, preserved human amniotic membrane has been advocated for the management of many ocular surface disorders,¹ such as after persistent corneal epithelial defects with ulceration,² reconstruction of ocular surface in conjunctival neoplasms or scarring,³ chemical or thermal burns,^{4, 5} advanced ocular cicatricial pemphigoid and Stevens-Johnson syndrome,⁶

Table 1 Comparison of patients' demographic data among amniotic membrane graft group, conjunctival autograft group, and topical mitomycin C group

	Amniotic membrane graft	Conjunctival autograft	Topical mitomycin C	p Value
No (eye) of patients	71 (80)	50 (56)	46 (54)	—
Sex (M:F)	35:36	19:31	21:25	0.466
Mean age (years) (SD) (range)	56.7 (11.3) (31–83)	56.4 (11.9) (33–76)	57.8 (12.2) (39–91)	0.836
Laterality (R:L)	39:41	19:37	23:31	0.350
Mean follow up (months) (SD) (range)	13.8 (10.4) (6–43)	22.8 (18.2) (6–50)	18.4 (18.3) (6–76)	0.004

years, range 39–91 years). The age and sex distribution of both groups were similar to those in the amniotic membrane graft group (Table 1). The mean follow up period for the conjunctival autograft group was 22.8 (18.2) months (6–50 months), and that for topical mitomycin C group was 18.4 (18.3) months (6–76 months).

Surgical procedures

AMNIOTIC MEMBRANE PREPARATION

The approval for the use of cryopreserved human amniotic membrane for the pterygium operation was obtained from the committee of medical ethics and human experiment of Chang Gung Memorial Hospital, Taoyuan, Taiwan. Isolation and preservation of human amniotic membrane obtained following a caesarean section have been described previously.²⁻⁹ Briefly, after thorough washing in normal saline, amniotic membrane was cut into about 3 × 3 cm pieces and put into vials containing 1:1 mixture of Dulbecco's modified Eagle's Medium (DMEM; Sigma, St Louis, MO, USA) and sterilised glycerol, and then was preserved in a refrigerator at -70°C until use. The membranes were kept frozen for 2–3 months before use. According to the rate of consumption, the duration of cryopreservation ranged from 2 to 6 months. Upon use, the membrane was thawed and soaked in normal saline containing gentamicin (3 mg/ml) for at least 3 minutes, and the jelly-like material over the stromal side was meticulously removed. During the study period, a total of four amniotic membranes were used.

PTERYGIUM EXCISION

Before surgery, written informed consent for the procedure was obtained from each patient. All of the surgeries were performed by the same surgeon (DHKM). Subconjunctival anaesthesia with 4% lignocaine (Xylocaine) containing 1:10 000 adrenaline (epinephrine) was used for most patients. Peribulbar anaesthesia was reserved for those patients who could not cooperate. For nasal pterygia, the patients were asked to look temporally. The head of pterygium was first separated at the limbus and dissected towards the central cornea with a spring scissors. After excising the head and most of the body of the pterygium, subconjunctival Tenon's tissue was separated from overlying conjunctiva, undermined, and excised extensively upward and downward towards the fornices, and medially towards but not reaching the caruncle. Caution was taken not to damage the medial rectus muscle. Caution was

applied to bleeders. The conjunctiva above and below the pterygium was trimmed to create a rectangular area of bare sclera. Residual fibrovascular tissue over the cornea was removed either by toothed forceps or by gentle scraping with a No 15 Baird-Parker blade.

AMNIOTIC MEMBRANE GRAFT

A rectangular conjunctival defect of approximately 5 × 7 to 6 × 8 mm or even larger was created. This bare scleral area was then covered with amniotic membrane, which was oriented with basement membrane side up. The amniotic membrane was sutured through the episcleral tissue to the edge of conjunctiva along the bare sclera border with seven to eight interrupted stitches of 8-0 Vicryl suture.

CONJUNCTIVAL AUTOGRAFT

The technique of conjunctival autograft has been described previously.¹⁸⁻²¹ A conjunctival graft matching the bare sclera was harvested from superotemporal bulbar conjunctiva 3 mm from the limbus. The donor site was later closed with a continuous suture of 8-0 Vicryl. The graft was then sutured to bare sclera with interrupted 8-0 Vicryl as mentioned above.

TOPICAL MITOMYCIN C

After removal of the pterygium and Tenon's tissue, the adjacent conjunctiva was fixed to the upper and lower corner of bare sclera with 8-0 Vicryl. Mitomycin C solution 0.02% made by resuspending mitomycin C powder (Kyowa Hakko Kogyo Co, Tokyo, Japan; 2 mg/vial) with 10 ml of Tear Naturale (Alcon-Couvreur, Puurs, Belgium) was applied three times daily for 1 week. The patients were cautioned that they should not use the eye drop more frequently, and the drug should be discarded after 1 week.

POSTOPERATIVE FOLLOW UP

Postoperatively, Maxitrol ointment (Alcon) twice daily to four times daily with oral indomethacin 25 mg and antacid four times daily were given, and if there was excessive irritation from the stitches, lubricants such as Tear Naturale or Balanced Salt Solution (Alcon) were given. Patients were examined at 1 week, and most of the stitches were removed at 2 weeks. Thereafter, the eye drops were changed to 0.1% fluorometholone (Ciba Vision, Hettlingen, Switzerland) four times daily then decreased to twice daily 1 month later, and then changed to 0.02% fluorometholone (Santen, Osaka, Japan) four times daily to twice daily for 3 months. Patients were followed monthly from the first month to the fourth month, then bimonthly from the fourth month to 1 year. Thereafter, regular follow ups at 3 month interval were encouraged. External ocular photographs were taken preoperatively, postoperatively at 1 month, and every 3 months. Complications such as pyogenic granuloma, inclusion cyst, or scleral thinning were recorded. Recurrence was defined as any fibrovascular growth beyond the limbus onto the cornea, and was assessed by another

Table 2 Comparison of cumulative non-recurrence rate among amniotic membrane graft group, conjunctival autograft group, and topical mitomycin C group

	No (%) of recurrences	Cumulative non-recurrence rate (%)			p Value
		6 months	1 year	2 years	
Amniotic membrane graft	3/80 (3.8%)	100%	97.7%	90.0%	0.937
Conjunctival autograft	3/56 (5.4%)	96.4%	93.4%	93.4%	
Topical mitomycin C	2/54 (3.7%)	98.2%	94.6%	94.6%	

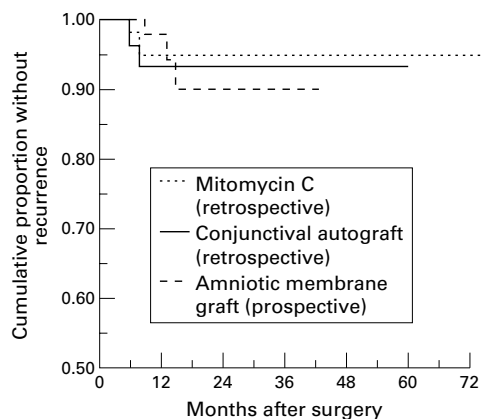


Figure 1 Kaplan-Meier survival curve of recurrence after pterygium excision followed by amniotic membrane graft, conjunctival autograft, and topical mitomycin C treatment.

observer (SBL) by slit lamp examination or by postoperative photographs.

As the recurrence rate of pterygium excision without any adjunctive therapy is unacceptably high, for ethical reasons, we did not use a control group without any adjunctive treatment.^{22 23} Comparative data from the literatures were used.

STATISTIC ANALYSIS

Eyes rather than people were used as an unit for statistical analysis, because there were only a small number (13.8%) of patients who had both eyes operated. Data were presented as mean (SD) or frequency (%). The χ^2 test was done to compare categorical data among the three groups. One way analysis of variance (ANOVA) was used to compare continuous data among the three groups. Scheffe's multiple comparison was applied for those with significant findings in one way ANOVA. Recurrence rate was computed using the Kaplan-Meier method and compared among the three groups using the log rank test. All p values reported were two sided. Statistical significance was considered when the p value was <0.05.

Table 3 Comparison of cumulative non-recurrence rate for all patients stratified by age and sex only

	No (%) of recurrence	Cumulative non-recurrence rate (%)			p Value
		6 months	1 year	2 years	
Age (years)					0.834
<50	1/48 (2.1%)	97.9%	97.9%	97.9%	
50-59	3/62 (4.8%)	100%	92.7%	92.7%	
≥60	4/80 (5.0%)	97.5%	97.5%	91.9%	
Sex					0.073
M (eye)	6/81 (7.4%)	96.2%	92.4%	92.4%	
F (eye)	2/109 (1.8%)	100%	98.2%	95.8%	

Results

The characteristics of patients in the three groups were compared in Table 1. There were no statistically significant difference regarding sex ($p = 0.466$), age ($p = 0.836$), and laterality ($p = 0.350$) among the three groups. Averaged follow up time was different in the three groups ($p = 0.004$), where the conjunctival autograft group (22.8 (SD 18.2) months) was significantly longer than that in the amniotic membrane graft group (13.8 (10.4) months) as indicated by Scheffe's multiple comparison.

Three cases (3.8%) in the amniotic membrane graft group developed recurrence which occurred at 9, 13, and 15 (mean 12.3) months postoperatively (Table 2). Three cases (5.4%) in the conjunctival autograft group developed recurrence, which occurred at 2, 3, and 4 (mean 3.0) months postoperatively. Two cases (3.7%) in the topical mitomycin C group developed recurrence, which occurred at 2 and 9 (mean 5.5) months postoperatively. There was no significant difference in the recurrence rate among the three groups ($p = 0.879$). To further consider the time of recurrence, a Kaplan-Meier curve was made. The non-recurrence rate at 2 years postoperatively for the amniotic membrane graft group was 90.0%, which was not significantly different from that for the conjunctival autograft (93.4%) and the mitomycin C groups (94.6%, $p = 0.937$) (Table 2 and Fig 1). When stratified by age regardless of operation groups, there was no significant difference in the recurrence rate among patients below 50 years (one case, 2.1%), between 50 and 59 years (three cases, 4.8%), and above 60 years (four cases, 5.0%, $p = 0.834$). Likewise, when stratified by sex only, there was no significant difference in the recurrence rate between male (six cases, 7.4%) and female patients (two cases, 1.8%, $p = 0.073$; Table 3).

Because there were 13.8% patients who had both eyes operated, we had performed the entire statistical analysis on data with one eye from each patient only (data not shown). No obvious difference between the two results was seen, indicating that the repeated observations did not alter our findings.

In the amniotic membrane graft group, one case (1.25%) of pyogenic granuloma and one case (1.25%) of iatrogenic microhyphaema were experienced. The latter was probably induced by an inadvertent deep suture at the limbus which completely resolved 3 days later. In the conjunctival autograft group, two cases of pyogenic granuloma (3.6%) and four cases (7.3%) of conjunctival inclusion cyst occurred. Two of the cysts were punctured to drain the subconjunctival fluid, and the others resolved spontaneously. One case (1.8%) in the mitomycin C group developed pyogenic granuloma, which had to be excised 1 month later. Although only one case (1.8%) in the mitomycin C group developed scleral ischaemia postoperatively, this case unfortunately suffered from infectious scleritis caused by *Pseudomonas aeruginosa* 1 year later.

Discussion

It is believed that surgical trauma and subsequent postoperative inflammation activates subconjunctival fibroblasts, and the proliferation of fibroblasts and vascular cells, and deposition of extracellular matrix (ECM) proteins in turn contribute to the pterygium recurrence.^{17 24 25} Alternatively, pterygium fibroblasts were reported to exhibit some characteristics of transformed cells such as hyperproliferation²⁶ and overexpression of matrix metalloproteinases,²⁷ which may partially explain the invasive nature of pterygium tissue.

As a natural basement membrane, amniotic membrane (AM) contains various matrix proteins²⁸ which facilitate the adhesion,^{29 30} migration,³¹ differentiation,^{32 33} and prevention of apoptosis of epithelial cells.^{34 35} The AM is also capable of binding growth factors which may help to promote wound healing.³⁶⁻³⁹ However, these characteristics of AM may not fully explain why AM graft prevents pterygium recurrence. For example, it has been shown that a supernatant of homogenised AM promotes rather than inhibits proliferation of conjunctival fibroblasts.³⁸ In addition, factors contained in AM may also change after preservation. It has been reported that after preservation at -80°C for one month, activities of transforming growth factor β (TGF β) 1 and 2, basic fibroblast growth factor (bFGF), and hepatocyte growth factor (HGF) in AM decreases by 50%.³⁸ However, recent finding indicated that preserved AM suppresses the expression of TGF β -I, TGF β -II, TGF β -III, TGF β receptor type II, and myofibroblast differentiation in corneal and limbal fibroblasts.¹⁴ Likewise, preserved AM also suppresses the signalling pathway of TGF β , CD-44, β -1 integrin, and FGFR1/flg of pterygium fibroblasts.⁴⁰ Subsequently, AM matrix inhibits ECM production and scar formation by these fibroblasts. Therefore, promotion of conjunctival epithelial wound healing and suppressing activation and ECM production by pterygium fibroblast are thought to be the major mechanisms by which an AM graft inhibits pterygium recurrence. Other possible mechanisms include inhibition of inflammation by inhibiting chemokines expression by fibroblasts¹⁵ and interleukin-1 expression by epithelial cells,¹⁶ inhibition of neovascularisation by inhibiting vascular endothelial cell growth,¹³ presence of anti-angiogenic/anti-inflammatory proteins,¹² and protease inhibitors.⁴¹ Among various protease inhibitors, tissue inhibitors of metalloproteinase (TIMPs) are remarkable in that TIMP activity in AM is preserved following cryopreservation.^{12 42} Possibly, inhibition of postoperative inflammation and inhibition of vascular cells activation and invasion by AM may also contribute to reduce pterygium recurrence.

A recurrence rate of 10.9% following AM graft for primary pterygium has been reported,⁹ together with rates of 25% to 37.5% for recurrent pterygia.^{9 10} In this study, the recurrence rate following AM graft for primary pterygium was 3.8%, which was about the same as the topical mitomycin C group

(3.7%), and was slightly better than the conjunctival autograft group (5.4%). Compared with a previous report,⁹ in this study more patients were enrolled (80 eyes *v* 46 eyes), and the average follow up period was also longer (13.8 months *v* 10.4 months). The minimal follow up period was 6 months, in contrast with only 2.5 months in the previous report.⁹ Nevertheless, the recurrence rate was still lower (3.8% *v* 10.9%), and we suggest that this was due to removal of more conjunctiva, especially the conjunctiva adjacent to pterygium at the limbus, which might also be abnormal.⁴³ The coverage of a larger area by amniotic membrane in turn may promote the proliferation and differentiation of the remaining normal limbal epithelial cells,⁴⁴ which may have an inhibitory effect on fibrovascular ingrowth.⁴⁵ However, some drawbacks exist in this study: (1) the retrospective nature of comparison with conjunctival autograft and topical mitomycin C group, (2) non-randomisation between the two control groups, and (3) lack of a grading system to describe the extent and severity of inflammation associated with pterygium.⁴⁶ Nevertheless, compared with previously reported recurrence rates following topical mitomycin C treatment (0% to 12.0%)^{47 48} and conjunctival autograft (0% to 39%),^{46 49 50} the results reported in this study were still comparable. Furthermore, during the study period the author performed only AM graft on consecutive cases; therefore, there was no personal preference in patient selection. However, a randomised and prospectively based study is still needed for more precise comparison.

Compared with the bare sclera method, conjunctival autograft is a more technically demanding procedure, surgeon factors (experience, technique, etc) may have a profound influence on the recurrence rate. Moreover, conjunctival grafts including limbus generally yield better results than those that do not, because in addition to the contact inhibition effect on residual abnormal tissue by conjunctival graft,⁵¹ the former may also contain limbal stem cells which help to restore the limbal barrier, and this in turn inhibits pterygium recurrence and retards recurrence time.^{9 51 52} In this study we used conjunctival grafts without limbus, although the recurrence rate was satisfactory, it was still less effective than the best result from grafts containing the limbus (0%, Kenyon *et al*, Tan *et al*).^{46 49}

Although topical mitomycin C was more effective than conjunctival autograft in reducing recurrence in several comparative studies,^{21 50 53 54} some vision threatening side effects such as scleral ulceration, cataract formation, and glaucoma have been reported.⁵⁵⁻⁵⁸ To avoid complications, many authors now advocate intraoperative application.^{48 59-61} In addition, mitomycin C should be very cautiously applied to those patients with conditions predisposing to poor wound healing such as dry eye, blepharitis, or herpetic keratitis. To date, there is no report of sight threatening complication following conjunctival autograft or amniotic membrane

graft. Minor complications such as conjunctival epithelial inclusion cysts occurred more frequently in the conjunctival autograft group in both this and previous studies,⁹ which may be caused by embedded conjunctival epithelium underneath the graft or recipient bed. In addition, amniotic membrane contamination is a potential risk and cannot be overlooked.

In summary, we have compared the surgical result of primary pterygium removal followed by amniotic membrane graft, conjunctival autograft, and topical mitomycin C treatment. We have shown that amniotic membrane graft was as effective as the other two methods, and was safe with no major complications. This suggests that amniotic membrane graft may be a preferred procedure for primary pterygium, and is especially suited for pterygium with diffuse conjunctival involvement or glaucoma patients waiting for filtering operations.

Presented in part at the Second Annual Meeting of the Ocular Surface and Tear Workshop, Miami, Florida, 20 April 1996.

The authors have no financial interest in the clinical uses of amniotic membrane.

The authors thank Dr Lawrence W Hirst, Department of Ophthalmology, University of Queensland, Australia for careful reading of the manuscript.

- Dua HS, Azuara-Blanco A. Amniotic membrane transplantation. *Br J Ophthalmol* 1999;**83**:748–52.
- Lee SH, Tseng SCG. Amniotic membrane transplantation for persistent epithelial defects with ulceration. *Am J Ophthalmol* 1997;**123**:303–12.
- Tseng SCG, Prabhawat P, Lee SH. Amniotic membrane transplantation for conjunctival surface reconstruction. *Am J Ophthalmol* 1997;**124**:765–74.
- Azuara-Blanco A, Pillai CT, Dua HS. Amniotic membrane transplantation for ocular surface reconstruction. *Br J Ophthalmol* 1999;**83**:399–402.
- Shimazaki J, Yang H, Tsubota K. Amniotic membrane transplantation for ocular surface reconstruction in patients with chemical and thermal burns. *Ophthalmology* 1997;**104**:2068–76.
- Tsubota K, Satake Y, Ohyama M, et al. Surgical reconstruction of the ocular surface in advanced ocular cicatricial pemphigoid and Stevens-Johnson syndrome. *Am J Ophthalmol* 1996;**122**:38–52.
- Choi YS, Kim JY, Wee WR, et al. Effect of the application of human amniotic membrane on rabbit corneal wound healing after excimer laser photorefractive keratectomy. *Cornea* 1998;**17**:389–95.
- Fujishima H, Shimazaki J, Shinozaki N, et al. Trabeculectomy with the use of amniotic membrane for uncontrollable glaucoma. *Ophthalmic Surg Lasers* 1998;**29**:428–31.
- Prabhawat P, Barton K, Burkett G, et al. Comparison of conjunctival autografts, amniotic membrane grafts, and primary closure for pterygium excision. *Ophthalmology* 1997;**104**:974–85.
- Shimazaki J, Shinozaki N, Tsubota K. Transplantation of amniotic membrane and limbal autograft for patients with recurrent pterygium associated with symblepharon. *Br J Ophthalmol* 1998;**82**:235–40.
- Kim JC, Tseng SCG. Transplantation of preserved human amniotic membrane for surface reconstruction in severely damaged rabbit corneas. *Cornea* 1995;**14**:473–84.
- Hao YX, Ma DHK, Kim WS, et al. Identification of anti-neovascularization proteins in human amniotic membrane. *Cornea* 2000;**19**:348–52.
- Kobayashi A, Inana G, Meller D, et al. Differential gene expression by human cultured umbilical vein endothelial cells on amniotic membrane. Presented at the 4th Ocular Surface and Tear Conference, Miami, FL, USA, 14 May 1999.
- Tseng SCG, Li DG, Ma X. Suppression of transforming growth factor-beta isoforms, TGF-B receptor type II, and myofibroblast differentiation in cultured human corneal and limbal fibroblast by amniotic membrane matrix. *J Cell Physiol* 1999;**179**:325–35.
- Bultmann S, You L, Spandau U, et al. Amniotic membrane down-regulates chemokine expression in human keratocytes. *Invest Ophthalmol Vis Sci* 1999;**40**:S578.
- Solomon A, Monroy D, Ji Z, et al. Suppression of epithelial expression of IL-1β by the amniotic membrane. Presented at the 4th Ocular Surface and Tear Conference, Miami, FL, USA, 14 May 1999.
- Cano-Parra J, Diaz-Llopis M, Maldonado MJ, et al. Prospective trial of intraoperative mitomycin C in the treatment of primary pterygium. *Br J Ophthalmol* 1995;**79**:439–41.
- Figueiredo RS, Cohen EJ, Gomes JAP, et al. Conjunctival autograft for pterygium surgery: how well does it prevent recurrence? *Ophthalmic Surg Lasers* 1997;**28**:99–104.
- Lewallen S. A randomized trial of conjunctival autografting for pterygium in the tropics. *Ophthalmology* 1989;**96**:1612–14.
- Lee JS, Tsai RJF, Ku WC. Comparison of autograft conjunctival transplantation and two kinds of postoperative chemical treatment for pterygium surgery. In: *Current aspects in ophthalmology*. Amsterdam: Elsevier, 1992: 415–17.
- Allan BDS, Short P, Crawford GJ, et al. Pterygium excision with conjunctival autografting: an effective and safe technique. *Br J Ophthalmol* 1993;**77**:698–701.
- Manning CA, Kloess PM, Diaz MD, et al. Intraoperative mitomycin in primary pterygium excision. *Ophthalmology* 1997;**104**:844–8.
- Sanchez-Thorin JC, Rocha G, Yelin JB. Meta-analysis on the recurrence rates after bare sclera resection with and without mitomycin C use and conjunctival autograft placement in surgery for primary pterygium. *Br J Ophthalmol* 1998;**82**:661–5.
- Cameron ME. Histology of pterygium: an electron microscopic study. *Br J Ophthalmol* 1983;**67**:604–8.
- Guler M, Sobaci G, Ilker S, et al. Limbal-conjunctival autograft transplantation in cases with recurrent pterygium. *Acta Ophthalmol* 1994;**72**:721–6.
- Chen JK, Tsai, RJF, Lin SS. Fibroblasts isolated from human pterygia exhibit transformed cell characteristics. *In Vitro Cell Dev Biol* 1994;**30A**:243–8.
- Lee SB, Li DQ, Gunja-Smith Z, et al. Increased expression and activity of MMP-1 and MMP-3 by cultured pterygium head fibroblasts. *Invest Ophthalmol Vis Sci* 1999;**40**:S334.
- Fukuda K, Chikama T, Nakamura M, et al. Differential distribution of subchains of the basement membrane components type IV collagen and laminin among the amniotic membrane, cornea, and conjunctiva. *Cornea* 1999;**18**:73–9.
- Khodadoust AA, Silverstein AM, Kenyon KR, et al. Adhesion of regenerating corneal epithelium. The role of basement membrane. *Am J Ophthalmol* 1968;**65**:339–48.
- Sonnenberg A, Calafat J, Janssen H, et al. Intergrin β4 complex is located in hemidesmosomes, suggesting a major role in epidermal cell-basement membrane adhesion. *J Cell Biol* 1991;**113**:907–17.
- Terranova VP, Lyall RM. Chemotaxis of human gingival epithelial cells to laminin. A mechanism for epithelial cell apical migration. *J Periodontol* 1986;**57**:311–17.
- Meller D, Tseng SCG. Conjunctival epithelial cell differentiation on amniotic membrane. *Invest Ophthalmol Vis Sci* 1999;**40**:878–86.
- Prabhawat P, Tseng SCG. Impression cytology study of epithelial phenotype of ocular surface reconstructed by preserved human amniotic membrane. *Arch Ophthalmol* 1997;**115**:1360–7.
- Boudreau N, Simpson CJ, Werb Z, et al. Suppression of ICE and apoptosis in mammary epithelial cells by extracellular matrix. *Science* 1995;**267**:891–3.
- Boudreau N, Werb Z, Bissell MJ, et al. Suppression of apoptosis by basement membrane requires three-dimensional tissue organization and withdrawal from the cell cycle. *Proc Natl Acad Sci USA* 1996;**93**:3500–13.
- Shinozaki N, Soda A, Shimazaki J, et al. Detection of basic fibroblast growth factor (b-FGF) from amniotic membrane. *Invest Ophthalmol Vis Sci* 1995;**36**:S131.
- Casey ML, MacDonald PC. Keratinocyte growth factor expression in the mesenchymal cells of human amnion. *J Clin Endocrinol Metab* 1997;**82**:3319–23.
- Sato H, Shimazaki J, Shinozaki N, et al. Role of growth factors for ocular surface reconstruction after amniotic membrane transplantation. *Invest Ophthalmol Vis Sci* 1998;**39**:S428.
- Koizumi N, Inatomi T, Sotozono A, et al. Growth factor mRNA and preserved protein in human amniotic membrane. *Curr Eye Res* 2000;**20**:173–7.
- Tseng SCG, Lee SB, Li DQ, et al. Suppression of TGF-β signaling in both normal conjunctival fibroblasts and pterygial body fibroblasts by amniotic membrane. *Invest Ophthalmol Vis Sci* 1999;**40**:S579.
- Na BK, Hwang JH, Kim JC, et al. Analysis of human amniotic membrane components as proteinase inhibitors for development of therapeutic agent to recalcitrant keratitis. *Trophoblast Res* 1999;**13**:453–66.
- Kim JC, Kim JS, Han TW. Amniotic membrane transplantation in corneal ulcer. Presented at the Second Meeting of the Asia Pacific Society of Cornea and Refractive Surgery, Chiba, Japan, 16 Feb 2000.
- Barraquer JL. Etiology, pathogenesis, and treatment of the pterygium. In: *Transactions of the New Orleans Academy of Ophthalmology, symposium on medical and surgical diseases of the cornea*. St Louis: CV Mosby, 1980:167–78.
- Tsai RJF. The morphological studies of organotypic cultures of ocular surface epithelium on amniotic membrane. *Invest Ophthalmol Vis Sci* 1999;**40**:S578.
- Ma DHK, Tsai RJF, Chu WK, et al. Inhibition of vascular endothelial cell morphogenesis in cultures by limbal epithelial cells. *Invest Ophthalmol Vis Sci* 1999;**40**:1822–8.
- Tan DTH, Chee S, Dear KBG, et al. Effect of pterygium morphology on pterygium recurrence in a controlled trial comparing conjunctival autografting with bare sclera excision. *Arch Ophthalmol* 1997;**115**:1235–40.
- Mahar PS, Nwokora GE. Role of mitomycin C in pterygium surgery. *Br J Ophthalmol* 1993;**77**:433–5.
- Panda A, Das GK, Tuli SW, et al. Randomized trial of intraoperative mitomycin C in surgery for pterygium. *Am J Ophthalmol* 1998;**125**:59–63.

- 49 Kenyon KR, Wagoner MD, Hettinger ME. Conjunctival autograft transplantation for advanced and recurrent pterygium. *Ophthalmology* 1985;**92**:1461-70.
- 50 Chen PP, Ariyasu RG, Kaza V, et al. A randomized trial comparing mitomycin C and conjunctival autograft after excision of primary pterygium. *Am J Ophthalmol* 1995;**120**:151-60.
- 51 Riordan-Eva P, Kielhorn I, Ficker LA, et al. Conjunctival autografting in the surgical management of pterygium. *Eye* 1993;**7**:634-8.
- 52 Rao SK, Lekha T, Sitalakshmi G, et al. Conjunctival autograft for pterygium surgery: how well does it prevent recurrence? *Ophthalmic Surgery and Lasers* 1997;**28**:875-6.
- 53 Singh G, Wilson MR, Foster CS. Long-term follow-up study of mitomycin eye drops as adjunctive treatment for pterygia and its comparison with conjunctival autograft transplantation. *Cornea* 1990;**9**:331-4.
- 54 Mahar PS. Conjunctival autograft versus topical mitomycin C in the treatment of pterygium. *Eye* 1997;**11**:790-2.
- 55 Hardten DR, Samuelson TW. Ocular toxicity of mitomycin-C. *Int Ophthalmol Clin* 1999;**39**:79-90.
- 56 Rubinfeld RS, Pfister RR, Stein RM, et al. Serious complications of topical mitomycin-C after pterygium surgery. *Ophthalmology* 1992;**99**:1647-54.
- 57 Hsiao CH, Chen JY, Huang SCM, et al. Intraoperative dissemination of infectious scleritis following pterygium excision. *Br J Ophthalmol* 1998;**82**:29-34.
- 58 Lin CP, Shih MH, Tsai MC. Clinical experiences of infectious scleral ulceration: a complication of pterygium operation. *Br J Ophthalmol* 1997;**81**:980-3.
- 59 Cardillo JA, Alves MR, Ambrosio LE, et al. Single intraoperative application versus postoperative mitomycin C eye drops in pterygium surgery. *Ophthalmology* 1995;**102**:1949-52.
- 60 Frucht-Pery J, Siganos CS, Ilsar M. Intraoperative application of topical mitomycin C for pterygium surgery. *Ophthalmology* 1996;**103**:674-7.
- 61 Lam DSC, Wong AKK, Fan DSP, et al. Intraoperative mitomycin C to prevent recurrence of pterygium after excision. *Ophthalmology* 1998;**105**:901-5.



Amniotic membrane graft for primary pterygium: comparison with conjunctival autograft and topical mitomycin C treatment

David Hui-Kang Ma, Lai-Chu See, Su-Bin Liau, et al.

Br J Ophthalmol 2000 84: 973-978

doi: 10.1136/bjo.84.9.973

Updated information and services can be found at:

<http://bjo.bmj.com/content/84/9/973.full.html>

	<i>These include:</i>
References	This article cites 53 articles, 17 of which can be accessed free at: http://bjo.bmj.com/content/84/9/973.full.html#ref-list-1
	Article cited in: http://bjo.bmj.com/content/84/9/973.full.html#related-urls
Email alerting service	Receive free email alerts when new articles cite this article. Sign up in the box at the top right corner of the online article.

Topic Collections

Articles on similar topics can be found in the following collections

[Conjunctiva](#) (171 articles)
[Ocular surface](#) (455 articles)
[Sclera and episclera](#) (26 articles)

Notes

To request permissions go to:

<http://group.bmj.com/group/rights-licensing/permissions>

To order reprints go to:

<http://journals.bmj.com/cgi/reprintform>

To subscribe to BMJ go to:

<http://group.bmj.com/subscribe/>