

## LETTERS TO THE EDITOR

### Xeroderma pigmentosum in three consecutive siblings of a Nigerian family: observations on oculocutaneous manifestations in black African children

EDITOR.—Xeroderma pigmentosum (XP), a rare autosomal recessive disorder characterised by defective DNA repair leading to clinical and cellular hypersensitivity to ultraviolet radiation, manifesting mainly as intolerance of skin and eyes to light, has been described in all races,<sup>1–3</sup> but is exceedingly rare in the negroid race, although some cases have been reported in both the American<sup>4</sup> and African black people.<sup>5</sup> We describe three consecutive siblings of a Nigerian, Fulani, family with the typical features of XP. We wish to draw attention to the clinical, phenotypic variations of this syndrome in black children of the same family living together in an area of high sunshine, and the difficulties in the management of XP patients with advanced disease and limited access to facilities in an environment where avoidance of skin exposure to intense ultraviolet rays is problematic. We believe the patients we have described constitute the first series on XP in black children in the west African subregion.

#### CASE REPORTS

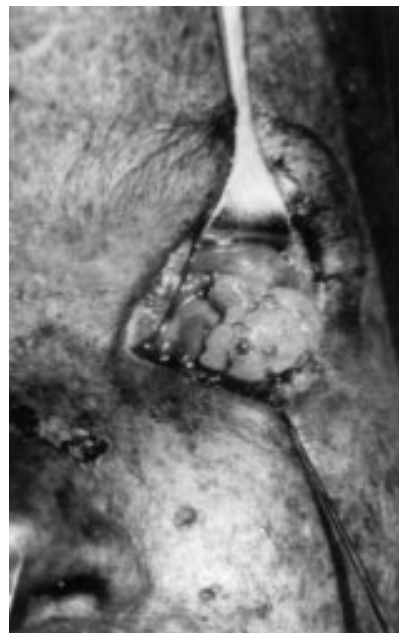##### Case 1

The proband, a 9 year old girl, was first seen at Usmanu Danfodiyo University Teaching Hospital (UDUTH), Sokoto (13.02° N, 5.14° E), Nigeria, in February 1999 with a history of the development of generalised erythema of the skin of the limbs, face, and trunk from the age of 1 week, on exposure to sunshine, with the large red spots changing into dark lesions with blistering. This was followed by the development of photophobia from the age of 1½ years, skin lesions, comprising freckles, on limbs and face, hypopigmented and hyperpigmented lesions covering both sun exposed and covered areas of the skin with onset from age 2 years, relentless worsening of vision from the age of 2 years, and development of an ulcer on the right cheek at the age of 7½ years which had become persistent. The child was a product of a consanguineous marriage; the parents were of low socioeconomic class. The proband was the fifth in birth rank, in a monogamous family consisting of nine children aged between 5 months and 19 years. Two other siblings following the proband in birth sequence, the 6th and 7th, a 7 year old boy and a 5 year old girl, respectively, were also afflicted with a similar disease process involving the skin and eyes. Both parents were unaffected. On examination, the entire skin was dry (with the exception of the soles and palms) covered with a mixture of mottled, hyperpigmented and hypopigmented, atrophic roundish and oval macules, giving the entire skin a chequered appearance, associated with generalised actinic keratoses (manifesting on black skin as palpable, rough, blackish spots covered with adherent scales). These keratotic lesions were more numerous on the face. A large reddish ulcerated plaque

(2 × 2 cm) with raised, dark, keratotic, sharply demarcated borders was seen on the right cheek and crusted ulceration on the nasal bridge was also noted. Biopsy of the ulcer on the cheek showed well differentiated squamous cell carcinoma. The following lesions were noted in the right eye. The skin of the lids was covered by similar lesions as elsewhere on the skin. The lower lid margin was ulcerated. A conjunctival mass 0.5 × 0.75 cm extended from the medial canthus to and covered the 2–5 o'clock of the limbus. The rest of the limbus was obliterated by a dark, flat lesion. The cornea was hazy because of a fibrovascular membrane on its epithelial surface making it impossible to view structures deeper to it. The left eye also showed loss of all eyelashes of the lower lid and most of those in the upper lid. A large nodular conjunctival lesion (1.5 cm × 1 cm) occupied the whole of the temporal conjunctiva and two thirds of the adjacent cornea. This lesion was pink, firm but friable (see Fig 1). The visual acuity (VA) was perception of light (PL), in the right eye and nil perception of light (NPL), in the left. Biopsy of the conjunctival mass LE showed a moderately differentiated squamous cell carcinoma. On the basis of the characteristic cutaneous and ocular lesions associated with sunshine hypersensitivity and histologically proved squamous cell carcinoma of both the skin and conjunctiva, the diagnosis in the proband was xeroderma pigmentosum in its final phase, the cancerous period.

##### Case 2

This 7 year old boy, the brother of the proband, presented with milder symptoms of XP, with slower progression. Thus, the initial generalised erythematous rash associated with exposure to sunshine became obvious from the age of 3 months; worsening of vision developed from the age of 4 years. The cuta-

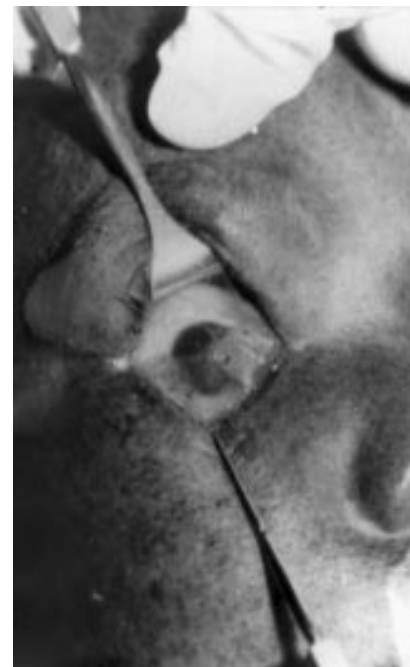

*Figure 1* Left eye of the proband demonstrating the large pink, friable conjunctival lesion, a biopsy of which showed moderately differentiated squamous cell carcinoma. Note the scaly nature of the surrounding facial skin with actinic keratotic lesions, hypopigmented and hyperpigmented areas and crusted ulceration of the nasal bridge, all typical cutaneous lesions in xeroderma pigmentosum.

neous lesions, though similar to those in the proband, were less severe. The entire skin was also dry, covered with hyperpigmented and hypopigmented atrophic roundish lesions. The actinic keratotic lesions were less numerous. There were no ulcerations and no cutaneous tumours. The ocular lesions were also milder than in the proband. In the right eye the conjunctiva was xerotic, but without areas of hypertrophy. The cornea was dull, but clear with tendency to dryness. The left eye showed total loss of lashes of the lower lid and hypertrophy of the nasal half of the conjunctiva, with raising of its edge towards the limbus. The VA (6/60 in both eyes) was better than in the proband. The ocular and cutaneous lesions were compatible with xeroderma pigmentosum in the precancerous phase

##### Case 3

This was the 5 year old sister of the proband. The onset of the disease and its severity took a middle course between that of the index case (case 1) and the second patient. The onset of erythematous skin lesions and freckles following exposure to sunshine was at age 6 weeks. Hypopigmented and hyperpigmented macules become evident by the age of 2½ years. The actinic keratoses became numerous by age 3½ years and ulceration of the upper lip was noticed at age 4½ years. The worsening of vision became obvious from the age of 3 years. Ocular examination revealed marked blepharospasm in the right eye, the conjunctiva was generally fleshy, vascular, with a tendency to bleed and covered the cornea in both its nasal half and inferotemporal quadrant. Other corneal areas were covered by a fibrovascular epithelial membrane (Fig 2). Biopsy of the conjunctival mass reveal moderately differentiated squamous cell carcinoma. In the left eye there was total loss of eyelashes of the lower lid, and a vascular fleshy overgrowth of the



*Figure 2* Case 3, right eye showing vascular, fleshy conjunctival tissues, a biopsy of which revealed features consistent with moderately differentiated squamous cell carcinoma. The facial skin demonstrates actinic keratotic lesions typical of xeroderma pigmentosum.

conjunctiva covering the whole of the nasal one third of the cornea, and also a small area of the cornea temporally at about 3 o'clock. The VA in the left eye was limited to hand movement only at 2 metres while in the right eye it was PL only. The severity of actinic keratotic lesions was midway between that of the proband and case 2. Although there were crusty skin ulcers of the upper lip, there were no obvious cutaneous tumours. On the basis of the oculocutaneous lesions, associated with sunshine hypersensitivity and the similarity of the symptomatology with that found in the other two siblings, the diagnosis of xeroderma pigmentosum was not in doubt. The disease in this patient had also advanced to the cancerous phase.

#### COMMENT

XP is generally regarded as a very serious disease in the tropics because of its pronounced sensitivity to sunlight.<sup>6</sup> There was some degree of variation in the severity and rate of progression of the disease in our patients despite their first degree relationship and the common environment characterised by high sunshine. The assertion that the severity of the skin and eye lesions relates more to the degree of skin exposure<sup>7</sup> may not explain, entirely, this variation since all the affected children live in a common environment of high sunshine. A recent Japanese study<sup>8</sup> has shown that there is correlation of the clinical manifestations and gene mutations even among patients of the same complementation group. We had no facilities in Nigeria to determine the complementation group of our patients and the individual gene mutations of these children. There are many obstacles in Nigeria to the proper management of XP patients in general and the three siblings we have described in particular. Firstly, an elaborate system of photoprotection from birth could not be carried out since there were no facilities for prenatal diagnosis of XP. Secondly, sun exposure could not be altogether avoided and only some measure of protection against the sun was provided—special glasses, clothes, and sunscreen creams. Unfortunately, the management of our patients was limited to these only. Surgical intervention could not be carried out mainly because the cost was too exorbitant for the poor parents. For these patients with advanced disease, limited access to facilities, in an environment of high sunshine, the prognosis is indeed gloomy.

HAMIDU AHMED

Department of Paediatrics, Usmanu Danfodiyo University, Teaching Hospital, PMB 2370, Sokoto, Nigeria

RAHMATU Y HASSAN

UDUTH, Sokoto, Nigeria

UMAR H PINDIGA

University of Maiduguri Teaching Hospital, Maiduguri, Nigeria

Correspondence to: Dr Ahmed

Accepted for publication 22 May 2000

1 Jung EG. Xeroderma pigmentosum. *Int J Dermatol* 1986;25:629–33.

2 Goya JL, Rao VA, Srinivasan R, et al. Oculocutaneous manifestations in xeroderma pigmentosum. *Br J Ophthalmol* 1994;78:295–7.

3 Kraemer KH, Lee M, Scotto J. Xeroderma pigmentosum—cutaneous, ocular and neurologic abnormalities in 830 published cases. *Arch Dermatol* 1987;123:241–50.

4 Wade WH Plotnick H. Xeroderma pigmentosum and squamous cell carcinoma of the tongue: identification of two black patients as members of the complementation group C. *J Am Acad Dermatol* 1985;12:15–21.

- 5 Lowenthal LJ, Trowel A. Xeroderma pigmentosum in African negroes. *Br J Dermatol* 1938;50:66.
- 6 Canizares O. Genetic disorders of the skin. In: Canizares O. *A manual of dermatology for developing countries*. 2nd ed. Oxford: Oxford University Press, 1993:278–9.
- 7 Jones KL. Xeroderma pigmentosum syndrome. In: Jones KL, ed. *Smith's recognizable patterns of human malformations*. 4th ed. Philadelphia: WB Saunders, 1988:489.
- 8 Kondoh M, Ueda M, Ichihashi M. Correlation of the clinical manifestations and gene mutations of Japanese xeroderma pigmentosum group A patients. *Br J Dermatol* 1995;133:579–85.

#### Multifocal electroretinographic and angiographic changes in pre-eclampsia

EDITOR,—Pre-eclampsia is characterised by hypertension, proteinuria and generalised oedema developed after 20 weeks' gestation. We report serial changes in multifocal electroretinography (MERG), fluorescein angiography (FA), and indocyanine green angiography (ICGA) in a patient with pre-eclampsia who developed choroidal ischaemia and serous retinal detachment.

#### CASE REPORT

A 28 year old Chinese woman, gravida II, para I, was hospitalised at 31 weeks' gestation with blood pressure of 178/98 mm Hg, 4+ proteinuria and pretibial oedema. At 34 weeks' gestation, emergency caesarean section was performed because of uncontrolled pre-eclampsia. Two days post partum, she complained of blurring of vision in the right eye. On examination, her visual acuity was right eye: 20/30, left eye: 20/15. There was no afferent pupillary defect. Anterior segment and intraocular pressure was normal. Fundal examination revealed bilateral greyish-yellow lesions at the level of retinal pigment epithelium (RPE), distributed mainly in peripapillary area and posterior pole. There was shallow inferior serous retinal detachment in

the right eye. FA and ICGA of both eyes showed early patchy hypofluorescence with delayed filling of choroid around the discs and nasal maculae, suggestive of choroidal ischaemia. Late phase showed leakage with stippled staining (Fig 1).

MERG was performed 2 weeks post partum. Stimulation used was the 103 hexagons at rate of 75 Hz using pseudorandom binary m-sequence with VERIS system (Electro Diagnostic Imaging, Inc, San Mateo, CA, USA).<sup>1</sup> Three dimensional topography and trace array of the MERG showed decreased response amplitudes in both nasal maculae and the right fovea. There was also delayed N1 and P1 implicit times and diminished response density of the nasal macula compared with the temporal macula in both eyes (Fig 2). Five weeks post partum, her visual acuity improved to 20/15 in both eyes. RPE changes corresponding to areas of delayed filling and leakage were found. FA and ICGA performed 3 months post partum were unremarkable. However, MERG showed persistent bilateral mild decrease in amplitude of the nasal macula compared with the temporal macula, despite full recovery of the right foveal peak. Visual field assessment was not performed.

#### COMMENT

In our patient, the area of decreased response amplitude and delayed latencies in MERG corresponded with the area of choroidal ischaemia detected by FA and ICGA. Additionally, it detected abnormal area in the right fovea that did not show up with FA or ICGA. When repeat FA and ICGA were unremarkable 3 months later, MERG still showed persistent abnormality in both nasal maculae. The partial recovery of MERG in our case supports the current concept of transient vasospasm in choroidal circulation in pre-eclampsia. However, the damage may not be completely reversible as previously reported.<sup>2</sup>

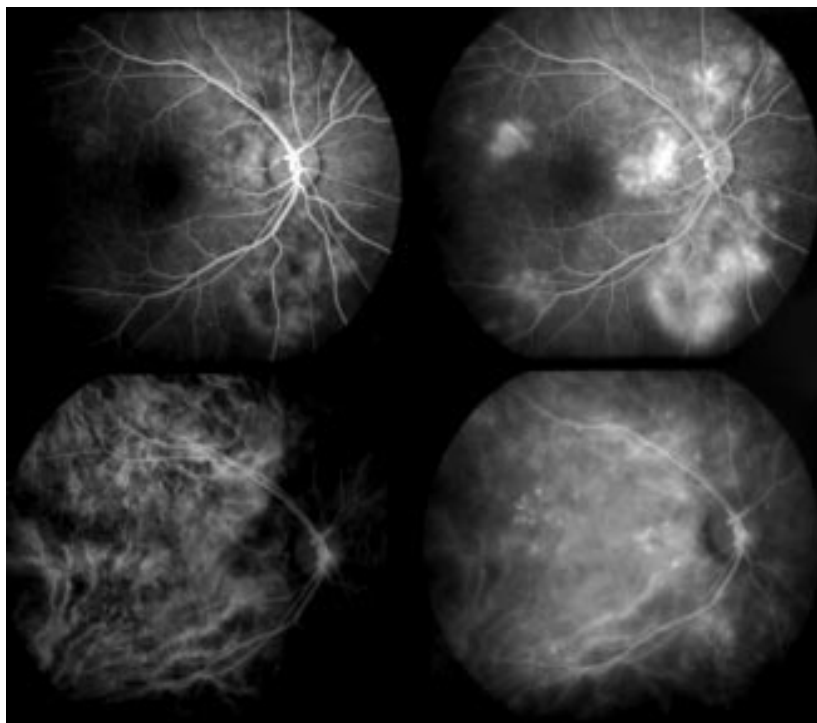
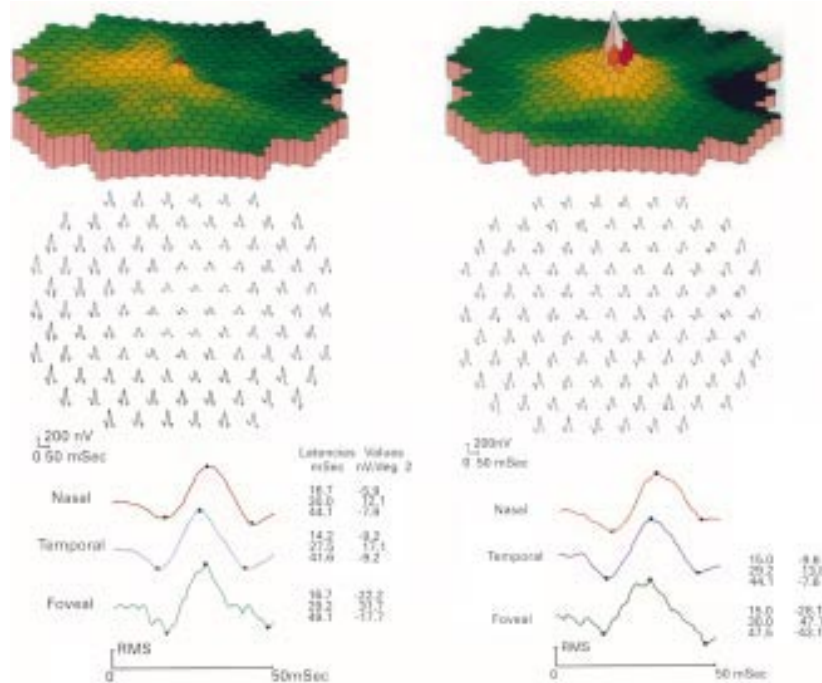


Figure 1 Right eye at 2 weeks post partum. (Top) Fluorescein angiogram shows delayed filling of choriocapillaries in the early phase and leakage with staining in the late phase. (Bottom) Similar changes in indocyanine green angiogram.



**Figure 2** Multifocal electroretinogram (MERG) of right eye. (Left) At 2 weeks post partum, trace array and three dimensional MERG topography showing decreased retinal response density in the fovea and nasal part of the macula. Average MERG responses of the temporal and nasal maculae showing prolonged N1 and P1 latencies as well as diminished response amplitude of the nasal macula compared with the temporal macula. Mean N1 and P1 latencies were 16.7 ms and 30.0 ms for the nasal macula, and 14.2 and 27.5 ms for the temporal macula, respectively. Mean P1 response amplitude for the nasal right macula is 70% of the temporal response (18.0 nV/deg<sup>2</sup> v 26.3 nV/deg<sup>2</sup>). (Right) At 3 months post partum, trace array and three dimensional MERG topography show recovery of the foveal response. However, average MERG response shows persistent mild decrease in response amplitude in the nasal macula, which is 83% of the temporal macula (19.2 nV/deg<sup>2</sup> v 23.4 nV/deg<sup>2</sup>).

The signals of MERG are thought to be derived from the outer retinal layers of cones and also the inner retinal layer including the bipolar and Muller cells.<sup>3</sup> The retinal response may be impaired secondary to RPE dysfunction and choroidal ischaemia. Similar MERG findings in central serous chorioretinopathy were reported, in which the RPE abnormality is thought to be secondary to the underlying choroidal vascular disease.<sup>4</sup> MERG has the advantage of being non-invasive and risk of breastfeeding after angiography can be avoided. It is more sensitive than FA and ICG in the evaluation of macular choroidal ischaemia in pre-eclampsia.

Proprietary and financial interest: Nil

Financial support: Supported in part by the Dr Yu-Tung Cheng Eye Foundation, Shatin, Hong Kong.

ALVIN K H KWOK  
JODIE Z L LI  
TIMOTHY Y Y LAI  
WAI-MAN CHAN  
PRAMOD BHENDE  
DENNIS S C LAM

Department of Ophthalmology and Visual Sciences, the Chinese University of Hong Kong, Prince of Wales Hospital, Hong Kong

Correspondence to: Dr Alvin K H Kwok, Department of Ophthalmology and Visual Sciences, The Chinese University of Hong Kong, Hong Kong Eye Hospital, 147K, Argyle Street, Kowloon, Hong Kong

kwokkh@ha.org.hk

Accepted for publication 16 June 2000

- 1 Sutter EE, Tran D. The field topography of ERG components in man, I: the photopic luminance response. *Vis Res* 1992;32:433–46.
- 2 Saito Y, Tano Y. Retinal pigment epithelial lesions associated with choroidal ischemia in pre-eclampsia. *Retina* 1998;18:103–8.

- 3 Si Y, Kishi S, Aoyagi K. Assessment of macular function by multifocal electroretinogram before and after macular hole surgery. *Br J Ophthalmol* 1999;83:420–4.
- 4 Marmor MF, Tan F. Central serous chorioretinopathy. Bilateral multifocal electroretinographic abnormalities. *Arch Ophthalmol* 1999;117:184–8.

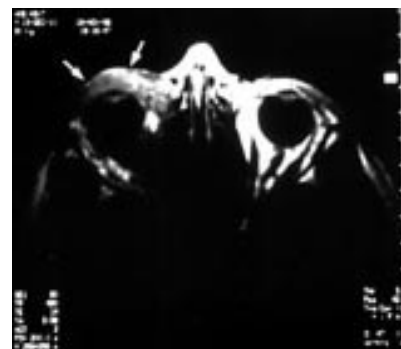### Signet ring cell carcinoma of the eccrine sweat gland in the eyelid, treated by radiotherapy alone

EDITOR,—The signet ring cell carcinoma of the eccrine sweat gland is a very rare tumour of the eyelid. Only six cases have been published up to now.<sup>1–6</sup> There is a preponderance of males; only one woman was affected. The patients' ages ranged from 47 to 78 years. This tumour shares some histological features with breast carcinoma, the metastasis of which represents the most important differential diagnosis—Indian file formations, signet ring cells, and expression of oestrogen, as well as progesterone, receptors. One significant difference is that the positive staining for those hormone receptors is found mainly in the cytoplasm in signet ring cell carcinoma, in contrast with the nuclear staining of breast carcinomas cells.<sup>7,8</sup>

Different treatment modalities have been applied in cases of eccrine sweat gland carcinoma. Our case demonstrates that tumour control can be achieved with radiotherapy alone despite extensive orbital involvement.

#### CASE REPORT

An 87 year old male patient was seen initially in our department in July 1998. He had noticed swelling of his right lower eyelid. We saw a diffuse thickening and induration of the



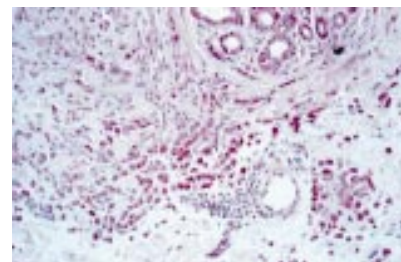
**Figure 1** The MRI scan displays diffuse tumour infiltration of the upper eyelid (arrows).

right eyelids at initial presentation in our hospital. An magnetic resonance image (MRI) showed a tumour that had infiltrated the upper (Fig 1) as well as the lower eyelid, the eyebrow, and the perioral muscles. The optic nerve was also surrounded by tumour mass. Two biopsies revealed an infiltrating tumour with Indian file formations; some of the tumour cells had a signet ring appearance with nuclei located peripherally as a result of intracytoplasmic vacuoles. The latter possessed microvilli, as could be demonstrated by electron microscopy. The cytoplasm stained positive with periodic acid Schiff (Fig 2) and with antibodies against oestrogen and progesterone receptors as well as human milk fat globulin. No hormone receptor expression was found in the nuclei. The growth fraction was 5%, determined with MIB1.

Systemic examination did not reveal any other tumour, especially no breast carcinoma and no adenocarcinoma of the gastrointestinal tract. Two treatment modalities were discussed—orbital exenteration and radiotherapy. Since the patient refused orbital exenteration radiotherapy was started in September and October 1998, and performed over 6 weeks, with a total dosage of 56 Gy. Two months later the cornea showed erosions which were treated with lubricants; the ocular motility was heavily impaired. Fourteen months after radiotherapy the lid skin was soft again without any evidence of tumour recurrence, the cornea only showed irregular epithelium, and the eye motility had returned to almost normal. Unfortunately, because of optic nerve damage by glaucoma and radiotherapy, the right eye went blind.

#### COMMENT

In most cases of signet ring cell carcinoma described in the literature, upper and lower lids of one eye were involved.<sup>1–6</sup> Three patients were initially treated by excision alone<sup>1–3</sup>; all of them had a period of survival of at least 6 years. One of these patients



**Figure 2** Signet ring cells with PAS positive intracytoplasmic vacuoles, arranged in an Indian file pattern (periodic acid Schiff; original magnification x200).

developed a recurrence after 10 years, with preauricular lymph node metastasis, as a result of which he was treated with radiotherapy (50 Gy).<sup>2</sup> He had at least 18 months of remission thereafter, but showed subclinical liver metastasis at necropsy; his death was not tumour related.<sup>4</sup> Another patient was found to have pulmonary metastases from which he finally died.<sup>3</sup>

Radiotherapy alone (35 Gy), as in our case, was applied in another patient.<sup>5</sup> He showed infiltration of the lids and the anterior orbit, and had at least 6 years of remission.<sup>4</sup> The only patient treated by orbital exenteration, radiotherapy, and tamoxifen<sup>6</sup> died as a result of liver and bone metastases within a period of less than 6 years after initial diagnosis. His pretreatment status, showing extensive orbital infiltration, was quite similar to that of the patient we are presenting here.

From the cases reported in the literature, we conclude that this tumour possesses a low to intermediate grade of malignancy. To date, 14 months after radiotherapy, our patient still shows remission. Thus, for elderly patients with extensive infiltration of orbital and adnexal tissue by an eccrine sweat gland carcinoma, we consider this conservative treatment sufficient to achieve local control.

We thank Dr T Rudolphi for providing clinical data, Dr T Wesendahl for contributing histological sections, and Professor Dr H Witschel and Dr J P Alexander for reading the manuscript.

CLAUDIA AUW-HAEDRICH

Department of Ophthalmology, University of Freiburg,  
D-79106 Freiburg, Germany

NORBERT BOEHM

Department of Pathology

CHRISTIAN WEISSENBERGER

Department of Radiology

Correspondence to: Dr Auw-Haedrich  
auw@aug.ukl.uni-freiburg.de

Accepted for publication 16 June 2000

- Rosen Y, Kim B, Yermakov VA. Eccrine sweat gland tumor of clear cell origin involving the eyelids. *Cancer* 1975;36:1034-41.
- Grizzard WS, Torczynski E, Edwards WC. Adenocarcinoma of eccrine sweat glands. *Arch Ophthalmol* 1976;94:2119-23.
- Thomas JW, Fu YS, Levine MR. Primary mucinous sweat gland carcinoma of the eyelid simulating metastatic carcinoma. *Am J Ophthalmol* 1979;87:29-33.
- Jakobiec FA, Austin P, Iwamoto T, et al. Primary infiltrating signet ring carcinoma of the eyelids. *Ophthalmology* 1983;90:291-9.
- Mc Lean IW. Primary histiocytoid carcinoma of the eyelid. Presented at the Combined Verhoeff and European Ophthalmic Pathology Meeting in Nuremberg, Germany, 1991.
- Wollensak G, Witschel H, Böhm N. Signet ring cell carcinoma of the eccrine sweat glands in the eyelid. *Ophthalmology* 1996;103:1788-93.
- Pascal RR, Santeusanio G, Sarrell D, et al. Immunohistologic detection of estrogen receptors in paraffin-embedded breast cancers: correlation with cytosol measurements. *Hum Pathol* 1986;17:350-5.
- King WJ, Greene GL. Monoclonal antibodies localize oestrogen receptor in the nuclei of target cells. *Nature* 1984;307:745-7.

### Endonasal endoscopic dacryocystorhinostomy for dacryocystocoele in a 4 month old infant

EDITOR.—Canalisation of the nasolacrimal apparatus usually occurs at the same time throughout its length. However, its distal end has been shown to be occluded by a membrane in 73% of otherwise normal stillborn fetuses at term.<sup>1</sup>

For typical dacryocystocoeles, a regimen of warm compresses and massage, with regular ophthalmological review to check for the first

signs of dacryocystitis, seems to be reasonable. Should dacryocystitis supervene, the child should be admitted to hospital for the intravenous administration of antibiotics and probing of the nasolacrimal apparatus.<sup>2</sup> Should the dacryocystocoele recur or epiphora ensue, and repeated probing does not give the result, it may be necessary to intubate the nasolacrimal apparatus<sup>3,4</sup> or perform a dacryocystorhinostomy.<sup>5</sup> In 1893, Caldwell described the first case of an endonasal operative approach to the lacrimal system.<sup>5</sup> This technique was later modified by West and supported by Mosher in 1921.<sup>7,8</sup> In spite of these attempts, the external dacryocystorhinostomy (DCR)—the technique inaugurated by Toti in 1904<sup>9</sup>—was, for a long time, the most accepted procedure for lacrimal sac surgery. The reason for this was presumably limited transnasal visualisation caused by bleeding during endonasal dacryocystorhinostomy.<sup>10</sup> In 1974, Jokinen and Karja revived the endonasal approach.<sup>11</sup> Heerman and Neues used a microscope for a transnasal approach to the lacrimal sac,<sup>12</sup> whereas McDonough and Meiring were the first to advocate endonasal endoscopic dacryocystorhinostomy (EEDCR), in 1989.<sup>13</sup>

Using new instrumentation and techniques for endoscopic sinus surgery in general, many authors have proved that EEDCR can be performed with lower morbidity in adults and with success rates equal to those achieved with the traditional external approach.<sup>14,15</sup>

#### CASE REPORT

A 4 month old girl presented with huge recurrent abscesses in the left medial canthal region (Fig 1) and a huge epiphora. Initially she was managed by conservative methods (warm compresses and massage over the swollen lacrimal sac), but the clinical appearance did not show any change. She underwent several incisions whenever the abscess severely exacerbated, threatening to perforate spontaneously. Attempts to probe the nasolacrimal canal were performed in the "silent" phases of the disease, but the probe did not pass deeper than the bottom of the lacrimal sac, suggesting the absence of the canal. Attempts to irrigate the lacrimal canals were not successful either. A lacrimal sac massage resulted in a certain amount of mucus bursting out from the inferior lacrimal punctum, indicating a blockage of the lacrimal system underneath the lacrimal sac.

Endonasal endoscopic examination showed no signs of intranasal extension.

Because of the clear clinical diagnosis of dacryocystocoele, the patient's age, and the need for additional general anaesthesia, we did not insist on a dacryocystogram or computed tomograph scanning.

At the time we decided to try to perform an endonasal endoscopic dacryocystorhinostomy (EEDCR), the girl was in one of her "silent

phases", without any clinical sign of acute exacerbation of the infection. Only moderate hemispheric bulging was seen in the medial canthal region.

We started the procedure by inserting two small, very thin (20×5 mm) gauze flakes, previously soaked in a 5% cocaine solution mixed with adrenaline (5:1 ratio) and then firmly squeezed, into the left nasal cavity. The flakes were removed after 5 minutes. A favourable vasoconstriction of the whole nasal mucosa was achieved. Then 0.5 ml of local anaesthetic (1% lignocaine with 1:100 000 adrenaline) was injected submucosally in the area just anterosuperior to the insertion of the middle turbinate. We used a paediatric endoscope of 2.7 mm in diameter and 30 degrees optics. The mucosa of this region was then removed by means of bipolar coagulation, and lacrimal bone was nicely exposed in an oval shape measuring up to 6 mm in longer diameter. The bone was drilled off and thinned out, so that the lacrimal sac became visible (the removal of the underlying lacrimal bone is more easily performed posteriorly, where it is thinner, but is more safely performed anteriorly to avoid the possibility of orbital disruption). The ophthalmological probe was inserted into the lacrimal canal and the sac itself, tenting it towards the nasal cavity. Then lacrimal sac marsupialisation was performed, using otological microsurgical scissors and punches, and a large amount of turbid tears mixed with mucopurulent discharge was obtained.

A 6 cm long nasal thin gauze ribbon package with antibiotic ointment was placed in the operated region for 3 days. After 5 days, there was no sign of dacryocystocoele or dacryocystitis on the girl's face (Fig 2). Eight months after the surgery, she is feeling fine.

#### COMMENT

Since, after 16 weeks of life, the nasolacrimal duct obstruction and dacryocystocoele did not resolve spontaneously or after conservative treatment, we performed an endonasal endoscopic dacryocystorhinostomy. As far as we know, this was the youngest child ever operated by means of EEDCR. The small anatomical dimensions of the infant nose posed a technical challenge in performing EEDCR: during the use of Richard's otological drill for bone removal, there was some difficulty in concomitant endoscopic visualisation and potential damage to the nasal mucosa from rotation of the drill shaft. We also performed a lacrimal opening of 6 mm with angled endoscopic biting forceps (the usual opening is about 10 mm).

In comparison with an external dacryocystorhinostomy, EEDCR avoids an external scar and offers very low morbidity in the immediate postoperative course. In spite of the technical problems, we think that

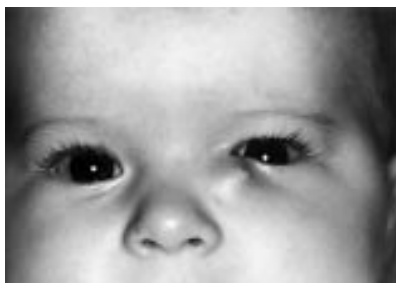

Figure 1 The appearance of the girl before the surgery.



Figure 2 The appearance on fifth day after the operation.

EEDCR, even in such a small infant, can be a good therapeutic choice in cases refractory to conservative treatment (warm compresses, massage, probing) because of its non-invasive performance and a very fast postoperative rehabilitation.

RANKO MLADINA

ORL Department, University Hospital Salata, Zagreb, Croatia

NEDA STIGLMAYER

Department of Ophthalmology, University Hospital Rebro, Zagreb, Croatia

KRSTO DAWIDOWSKY

ORL Department, University Hospital Salata, Zagreb, Croatia

TOMISLAV JUKIC

Department of Ophthalmology, University Hospital Rebro, Zagreb, Croatia

MARTIN JURLINA

BOZENA TRUPKOVIC-FOTIVEC  
ORL Department, University Hospital Salata, Zagreb, Croatia

Correspondence to: Professor Dr R Mladina, ORL Department, University Hospital Salata, 10000 Zagreb, Croatia

[prof\\_mladina@doctor.com](mailto:prof_mladina@doctor.com)

Accepted for publication 23 June 2000

- Cassady JV. Developmental anatomy of nasolacrimal duct. *Arch Ophthalmol* 1952;47:141-58.
- Sullivan TJ, Clarke MP, Morin JD, et al. Management of congenital dacryocystocele. *Aust NZ J Ophthalmol* 1992;20:105-8.
- Crawford JS. Intubation of obstructions in the lacrimal system. *Can J Ophthalmol* 1977;12:289-92.
- Pashby RC, Rathbun JE. Silicone tube intubation of the lacrimal drainage system. *Arch Ophthalmol* 1979;97:1318-22.
- Welham RAN, Hughes SM. Lacrimal surgery in children. *Am J Ophthalmol* 1985;99:27-34.
- Caldwell GW. Two new operations for obstructions of the nasal duct with preservation of the canaliculi. *Am J Ophthalmol* 1893;10:189.
- West J. A window resection of the nasal duct in cases of stenosis. *Trans Am Ophthalmol Soc* 1910;12:659.
- Mosher HP. Mosher-Toti operation on the lacrimal sac. *Laryngoscope* 1921;31:284-6.
- Toti A. Nuovo metodo conservatore dicura radicale delle sopperazioni croniche del sacco lacrimale (dacriocitorinostomia). *Clin Moderna* 1904;10:385-7.
- Cunningham MJ, Woog JJ. Endonasal endoscopic dacryocystorhinostomy in children. *Arch Otolaryngol Head Neck Surg* 1998;124:328-33.
- Jokinen K, Karja J. Endonasal dacryocystorhinostomy. *Arch Otolaryngol* 1974;100:41-4.
- Heerman J, Neues D. Intranasal microsurgery of all paranasal sinuses, the septum and the lacrimal sac with hypotensive anesthesia. *Ann Otol Rhinol Laryngol* 1986;95:631-8.
- McDonough M, Meiring JH. Endoscopic transnasal dacryocystorhinostomy. *J Laryngol Otol* 1989;103:585-7.
- Gonnering RS, Lyon DB, Fisher JC. Endoscopic laser-assisted lacrimal surgery. *Am J Ophthalmol* 1991;111:152-7.
- Woog JJ, Metson R, Puliafito CA. Holmium-YAG endonasal laser dacryocystorhinostomy. *Am J Ophthalmol* 1993;116:1-10.

### Epstein-Barr virus associated acute retinal necrosis

EDITOR.—Epstein-Barr virus (EBV) belongs to the group of herpesviruses. It may affect the eye in many different ways, most often as conjunctivitis or uveitis.<sup>1</sup> For herpes simplex virus (HSV) and for varicella zoster virus (VZV) it is well known that they can cause acute retinal necrosis (ARN), but information regarding EBV retinitis<sup>2-4</sup> is rare. To our knowledge we report the first case of a probable ARN associated with EBV infection.

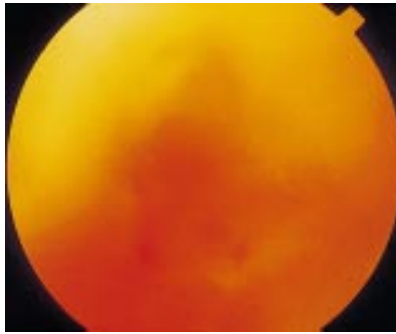


Figure 1 Funduscopy of the left eye at presentation, showing peripheral necrotising retinitis with bleeding.

### CASE REPORT

In 1997 a 32 year old homosexual man presented for the first time to the University Eye Hospital, Tübingen. For 4 weeks he had suffered from an acute retinal necrosis of the left eye. His right eye was not affected. The visual acuity of the left eye was 0.1. The anterior segment of the eye showed corneal precipitates but no cells in the anterior chamber. Owing to massive cell infiltration in the vitreous the lower part of the fundus was not visible. There was a large necrotic area with bleeding and occlusive vasculitis in the upper nasal periphery (Fig 1). The patient claimed to be healthy, apart from an EBV infection with pericarditis which had occurred when he was 17 years old. Tests for HIV and syphilis were repeatedly negative, also for Lyme disease, toxoplasmosis, hepatitis B, HSV, and VZV. There were increased titres for EBV-IgA (1:128), EBV-IgG (1:1512), EBV nuclear antigen, and EBV early antigen (1:64), a constellation typical for an acute EBV infection. After therapy with aciclovir 5 × 400 mg, prednisolone 60 mg, acetylsalicylic acid (200 mg), and topical prednisolone acetate the symptoms decreased.

After 8 weeks his visual acuity increased up to 0.5 but dropped to 0.2 after 5 months as a result of vitreous haemorrhages because of neovascularisations. After clearance of the bleeding and peripheral laser coagulation the neovascularisations resolved. The fundus showed scars but no holes in the area of the necrotic retina (Fig 2). After 25 months the visual acuity was 0.2. The anterior parts showed mild cataracta complicata. Vitreous cell infiltration still persisted and the central part of the fundus was not clearly seen. The patient showed an absolute central scotoma and atrophy of the optic nerve, without treatment.

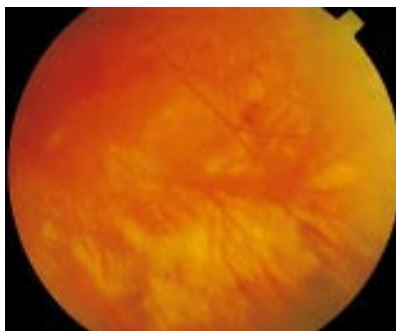


Figure 2 Funduscopy of the left eye after 6 months, showing peripheral scarring.

### COMMENT

The role of EBV in ocular diseases is still not clear, because approximately 95% of adults are positive for EBV antigen and only a few suffer from ocular disease. Previously described cases of "EBV retinitis"<sup>2-4</sup> only described inflammation of the posterior pole without scarring, which is not typical for viral retinitis. Proving an acute EBV infection usually is done with increased EBV titres. Such a constellation was found in our patient. The titres decreased during the following 12 weeks suggesting that EBV may play apart in this man's retinitis. The reported patient showed all criteria of the American Uveitis Society for ARN.<sup>5</sup>

However, it is not possible to rule out that other herpesviruses have caused the retinitis. This probably could only have been proved with a diagnostic vitrectomy or anterior chamber tap which was refused because of improvement with treatment. Serological findings showed no signs of other herpes infections.

SUSANNE KRAMER

Katharinenhospital Stuttgart, Kriegsbergstrasse 60, D-70174 Stuttgart, Germany

CHRISTOF BRUMMER

MANFRED ZIERHUT

University Eye Hospital, Department I, Schleichstrasse 12, D-72076 Tübingen, Germany

Correspondence to: Dr Manfred Zierhut, University Eye Hospital, Schleichstrasse 12, D-72076 Tübingen, Germany

[manfred.zierhut@med.uni-tuebingen.de](mailto:manfred.zierhut@med.uni-tuebingen.de)

Accepted for publication 23 June 2000

- Rickinson AB, Kieff F. Epstein-Barr virus. In: Fields BN, Knipe DM, Howley PM, eds. *Fields virology*. 3rd ed. Philadelphia: Lippincott-Raven, 1996:2397-436.
- Karpe G, Wising P. Retinal changes with acute reduction of vision as initial symptoms of infectious mononucleosis. *Acta Ophthalmol* 1948;26:19-24.
- Raymond L, Wilson C, Linnemann C, et al. Punctate outer retinitis in acute Epstein-Barr virus infection. *Am J Ophthalmol* 1987;104:424-6.
- Kelly SP, Rosenthal AR, Nicholson KG, et al. Retinochoroiditis in acute Epstein-Barr virus infection. *Br J Ophthalmol* 1989;73:1002-3.
- Holland GN. Standard diagnostic criteria for the acute retinal necrosis syndrome. Executive committee of the American Uveitis Society. *Am J Ophthalmol* 1994;117:663-7.

### Intrascleral recurrence of uveal melanoma after transretinal "endoresection"

EDITOR.—Conservation of the eye and vision in patients with juxtapapillary choroidal melanoma is still a challenge. Both plaque radiotherapy<sup>1</sup> and proton beam radiotherapy<sup>2</sup> tend to cause optic neuropathy, which is associated with disc and iris neovascularisation, vitreous haemorrhage, and neovascular glaucoma. These complications can also occur after phototherapy, which is less effective than radiotherapy at destroying the deeper parts of the tumour.<sup>3</sup> Transscleral local resection of posterior tumours is especially difficult with tumours extending close to the optic disc and is associated with an increased incidence of local tumour recurrence.<sup>4</sup> For these reasons, techniques have been developed for removing posterior choroidal melanomas transretinally,<sup>5,6</sup> using standard vitrectomy equipment. In a previous report, eight out of 52 cases received secondary photocoagulation for possible tumour recurrence at the margins of the surgical coloboma and one enucleated eye was found to have microscopic tumour depos-

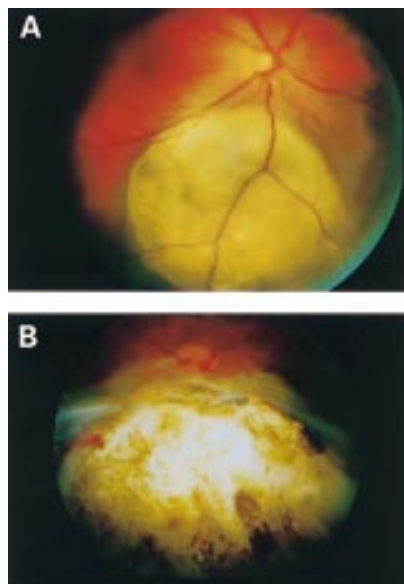


Figure 1 Fundus photographs (A) preoperatively, showing an inferior choroidal melanoma extending close to optic disc and fovea, and (B) 2 months postoperatively, showing surgical coloboma.

its within the coloboma.<sup>7</sup> We report a case of intrascleral tumour recurrence.

#### CASE REPORT

A 40 year old man presented with a 6 month history of photopsia. He was found to have a choroidal melanoma in the right eye and referred for conservative treatment. On examination, the vision was 6/4 with each eye. The tumour was pigmented and located inferiorly, extending to within two disc diameters of the fovea and optic disc margin (Fig 1). Approximately 40% of the retina was detached. On ultrasonography, the tumour had basal dimensions of 12.0 mm by 11.7 mm and a thickness of 4.8 mm (Fig 2). The left eye was healthy. Full systemic assessment revealed no other disease.

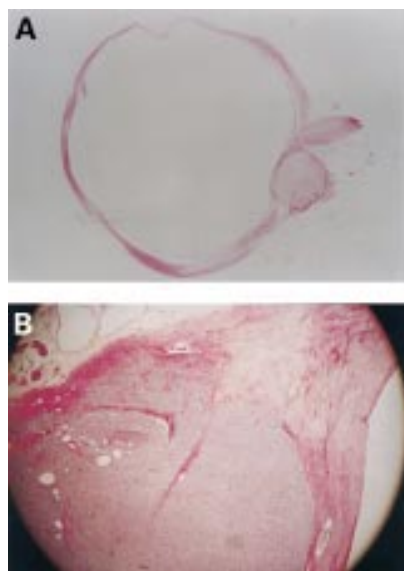


Figure 2 Light micrographs of the enucleated eye. (A) Low power view showing intrascleral tumour recurrence close to optic disc and (B) high power view showing a ciliary nerve within the tumour.

Transretinal “endoresection” was performed in July 1994. The procedure involved three port vitrectomy, retinectomy over the tumour, endodiathermy to bleeding points, endolaser photocoagulation applied to the margins and the bed of surgical coloboma and fluid-gas-silicone exchange. Histological examination showed the melanoma to be of mixed, spindle, and epithelioid cell type. In September 1994, the eye was settling well, except for an amelanotic choroidal swelling, which was noted adjacent to the inferonasal margin of the coloboma. This was believed to consist of a bubble of silicone oil in the suprachoroidal space although the possibility of recurrent melanoma could not be excluded clinically. There was also a localised tractional retinal detachment caused by vitreous bands.

Vitreoretinal surgery was performed, with release of the vitreous traction and excision of the retina and choroid over the swelling. This procedure confirmed that the tumour consisted of a bubble of silicone oil beneath the choroid. The procedure also included endolaser photocoagulation and silicone-gas exchange. The eye nevertheless developed retinal detachment with proliferative vitreoretinopathy and cataract. In December 1994, further surgery was performed, which consisted of phacoemulsification, removal of epiretinal membrane, 180 degree retinectomy, endolaser photocoagulation, and silicone oil fill.

In April 1995, the retina was flat with an epiretinal membrane covering the inferior margin of the coloboma and a fibrovascular scar partially obscuring the optic disc. It was decided that the silicone oil should be left in place because of the high risk of retinal detachment. When reviewed in February 1999, the vision was hand movements and there was band keratopathy, which precluded ophthalmoscopy. Enucleation was performed because it was not possible to screen the eye adequately for local tumour recurrence. At the time of surgery, an extraocular tumour nodule was noted medial to the optic nerve. The tumour nodule measured approximately 8 mm by 6 mm.

Pathological examination showed the recurrent tumour to be of mixed, spindle, and epithelioid cell type. The tumour appeared to arise within the sclera because of the way in which it was encapsulated by the scleral lamellae. The presence of nerve tissue within the tumour suggested that the melanoma had entered the sclera along a channel for a ciliary nerve. Posteriorly, the tumour had broken through the sclera into the orbit.

#### COMMENT

To our knowledge, this is the first report of intrascleral recurrence of choroidal melanoma after transretinal endoresection. The tumour probably survived the surgery and phototherapy because it had invaded a scleral canal adjacent to the optic nerve.

It is known that intrascleral tumour deposits can survive after phototherapy or transscleral local resection of choroidal melanoma. In the present case, the adjunctive phototherapy after completion of the tumour resection was either of insufficient power or was not applied to the area where the scleral invasion had taken place. A more effective method of eliminating residual intrascleral tumour would have been to administer adjunctive plaque radiotherapy, which is routine after transscleral local resection in some centres. In the present

case, however, this would probably have caused optic neuropathy.

Recurrent tumour after transscleral local resection is associated with an adverse prognosis for survival.<sup>8</sup> It is not known, however, whether the recurrence is the source of metastasis or merely an indicator of tumour aggression.

Further follow up studies are required to determine the incidence of intrascleral tumour recurrence after endoresection of choroidal melanoma.

B DAMATO

D WONG

St Paul's Eye Unit,

Royal Liverpool University Hospital

F D GREEN

Department of Ophthalmology,

Aberdeen Royal Hospitals

J M MACKENZIE

Department of Pathology,

Aberdeen Royal Hospitals

Correspondence to: Professor B Damato, St Paul's Eye Unit, Royal Liverpool University Hospital, Prescot St, Liverpool L7 8XP, UK

Accepted for publication 23 June 2000

- 1 Lommatzsch PK, Lommatzsch R. Treatment of juxtapapillary melanomas. *Br J Ophthalmol* 1991;75:715-7.
- 2 Gragoudas ES, Li W, Lane AM, et al. Risk factors for radiation maculopathy and papillopathy after intraocular irradiation. *Ophthalmology* 1999;106:1571-7.
- 3 Journée-de Korver JG, Oosterhuis JA, de Wolff-Rouendaal D, et al. Histopathological findings in human choroidal melanomas after transpupillary thermotherapy. *Br J Ophthalmol* 1997;81:234-9.
- 4 Damato BE, Paul J, Foulds WS. Risk factors for residual and recurrent uveal melanoma after trans-scleral local resection. *Br J Ophthalmol* 1996;80:102-8.
- 5 Lee KJ, Peyman GA, Raichand S. Internal eye wall resection for posterior uveal melanoma. *Jpn J Ophthalmol* 1993;37:287-92.
- 6 Damato BE, Foulds WS. Surgical resection of choroidal melanomas. In: Ryan SJ, ed. *Retina*. 2nd ed. ch 47:795-807. St Louis: CV Mosby, 1994.
- 7 Damato B, Groenewald C, McGalliard J, et al. Endoresection of choroidal melanoma. *Br J Ophthalmol* 1998;82:213-8.
- 8 Damato BE, Paul J, Foulds WS. Predictive factors for metastatic uveal melanoma after trans-scleral local resection. *Br J Ophthalmol* 1996;80:109-16.

#### Leucocoria as the presenting sign of a ciliary body melanoma in a child

EDITOR,—Uveal melanoma is generally a disease of adulthood.<sup>1</sup> It has been reported that 0.6% to 1.6% of all uveal melanomas occur in patients under 20 years of age.<sup>2,3</sup> In a review of 3706 consecutive patients with uveal melanoma, Shields and associates found that 1.1% were children and teenagers younger than 20 years of age, of whom only 0.3% had ciliary body melanoma.<sup>3</sup>

Patients with ciliary body melanoma usually are asymptomatic until the tumour impinges on the lens and causes visual distortion.<sup>1</sup> Children with intraocular tumours generally have few visual symptoms and adapt to visual distortion without complaints.<sup>1,3</sup> Leucocoria in childhood is the most frequent presenting sign of retinoblastoma, but it is generally not associated with uveal melanoma. We report an unusual case of a 9 year old child with a ciliary body melanoma who presented with leucocoria.

#### CASE REPORT

A 9 year old white girl was referred to Oncology Service at Wills Eye Hospital with a 1 month history of leucocoria and strabismus in

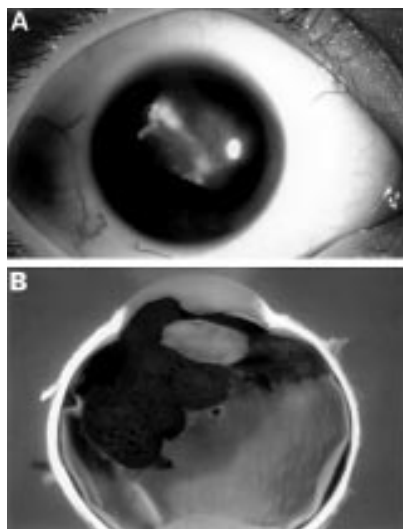


Figure 1 Slit lamp photograph showing the inferonasal dark tumour, subluxing the cataractous lens, causing leucocoria (A). Gross pathology reveals the heavily pigmented ciliochoroidal mass moulding to the lens (B).

her right eye (Fig 1A). She was otherwise healthy and her medical history was unremarkable.

Her visual acuity was hand movements in the right eye and 20/20 in the left eye. The intraocular pressure was 15 mm Hg in each eye. External examination revealed leucocoria in the right eye, 30 degrees of right exotropia, and prominent episcleral sentinel vessel inferotemporally. There was no melanocytosis. Slit lamp biomicroscopy disclosed shallowing of the inferior angle with iris abutting the corneal endothelium between 5:30 and 8:30 o'clock. The cataractous lens was subluxated superiorly and displayed posterior subcapsular and white cortical changes. A heavily pigmented, multilobulated mass was found immediately behind the lens, which was compressed by the tumour. The mass obscured view of the fundus. The left eye was unremarkable.

On transillumination, the mass blocked light transmission for 360° in the pars plana and pars plicata. Ocular ultrasonography (A

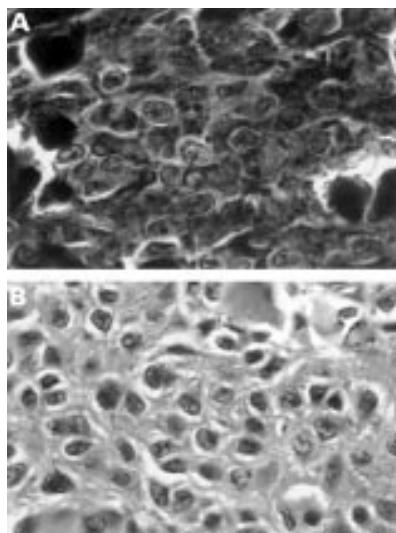


Figure 2 Histopathology discloses large pleomorphic epithelioid melanoma cells. (A) Haematoxylin and eosin; (B) bleach, both original magnifications  $\times 50$ .

and B-scan) showed an acoustically hollow, pedunculated mass in the ciliary body region measuring 10 mm in thickness. Ciliary body melanoma was diagnosed and the eye was enucleated.

Histopathological examination revealed a heavily pigmented multilobulated tumour arising from the pars plana (Fig 1B). The highly cellular tumour was composed of a mixture of spindle and epithelioid cells with a predominance of epithelioid cells. About 15–20% of the tumour was composed of melanophages within extensive areas of necrosis (Fig 2). No mitotic figures were identified. The cataractous lens was partially encased and dislocated by tumour. Parts of the iris, ciliary body, and choroid were heavily pigmented and dendritic melanocytes were observed within the sclera and on the episcleral surface, especially near the optic nerve. These findings were consistent with sector ocular melanocytosis. The histopathological diagnosis was ciliary body melanoma and sector ocular melanocytosis.

The patient has been followed for 10 years and has no evidence of local or systemic metastases.

#### COMMENT

Uveal melanoma is very rare in children and adolescents. Shields and associates reported that approximately 1% of all uveal melanoma patients are 20 years of age or younger at diagnosis.<sup>3</sup> In no case has any of these young patients presented with leucocoria.<sup>2-4</sup>

Ciliary body melanoma in both children and adults is usually asymptomatic and can attain a large size before it is recognised clinically.<sup>1</sup> The most common presenting manifestations of ciliary body melanoma include dilated episcleral vessels in the quadrant of tumour, secondary hypotony or glaucoma, and subluxation of lens with visual aberration and mild cataract.<sup>1</sup> Leucocoria generally is not present because the patient usually seeks consultation before dense cataract or leucocoria develops. In children leucocoria is an important sign reflecting cataract, retinal detachment, ocular inflammation, or retinoblastoma. Cataract rarely develops in eyes with retinoblastoma despite the presence of a large tumour. Therefore, leucocoria from cataract is an unusual presenting sign of an intraocular tumour in a child, especially ciliary body melanoma and we are unaware of any previous report of this occurrence.

One condition associated with the development of uveal melanoma is ocular melanocytosis.<sup>1</sup> Ocular melanocytosis generally presents as excessive pigmentation in the subcutaneous periocular skin, episclera, uvea, orbit, and meninges. The lifetime risk for uveal melanoma in a patient with ocular melanocytosis is approximately 0.25%.<sup>5</sup> Verdaguer found that four of seven young patients under age 20 years with uveal melanoma had ocular melanocytosis.<sup>4</sup> It is possible that sector melanocytosis may have predisposed to the development of melanoma in this case.

The prognosis for large uveal melanoma generally is poor. Barr and associates reported that the 15 year survival for posterior uveal melanoma in children and adolescents was 75%, suggesting that it does not differ from its adult counterparts.<sup>2</sup> They showed that a large tumour size of 10 mm or greater and extraocular extension were poor prognostic features.<sup>2</sup> Shields and associates also found that large tumour size was an important predictive factor of metastatic disease in

children with uveal melanoma.<sup>3</sup> Despite the large size of the tumour in our patient, no mitotic activity was found on histopathological examination. This may explain the continued survival of our patient.

In conclusion, we report a case of ciliary body melanoma in a 9 year old child who presented initially with a tumour induced cataract. A unilateral cataract in a child deserves an evaluation for common and rare conditions such as ciliary body melanoma.

Presented at the Eastern Ophthalmic Pathology Society on 19 November 1990 at Nassau, Bahamas.

Support provided by the International Award of Merit in Retina Research, Houston, TX (JS), Lions Eye Bank, Philadelphia, PA (JS, CS), Macula Foundation (CS), the Orbis International, New York, NY (SH), the Hyderabad Eye Research Foundation (SH) and the Noel T and Sara L Simmonds Endowment for Ophthalmic Pathology, Wills Eye Hospital (RE) and the Eye Tumor Research Foundation, Philadelphia, PA, USA.

HAKAN DEMIRCI  
CAROL L SHIELDS  
JERRY A SHIELDS  
SANTOSH G HONAVAR

Oncology Service, Wills Eye Hospital, Thomas Jefferson University, Philadelphia, PA, USA

RALPH C EAGLE, JR  
Pathology Department

Correspondence to: Dr Carol L Shields, Oncology Service, Wills Eye Hospital, 900 Walnut Street, Philadelphia, PA 19107, USA

Accepted for publication 17 June 2000

- Shields JA, Shields CL. *Intraocular tumors. A text and atlas*. Philadelphia: WB Saunders, 1992:118–36.
- Barr CC, McLean IW, Zimmerman LE. Uveal melanoma in children and adolescents. *Arch Ophthalmol* 1981;99:2133–6.
- Shields CL, Shields JA, Milite J, et al. Uveal melanoma in teenagers and children. A report of 40 cases. *Ophthalmology* 1991;11:1662–6.
- Verdaguer J Jr. Prepubertal and pubertal melanomas in ophthalmology. *Am J Ophthalmol* 1965;60:1002–11.
- Singh AD, De Potter P, Fijal BA, et al. Lifetime prevalence of uveal melanoma in white patients with ocular (dermal) melanocytosis. *Ophthalmology* 1998;105:195–8.

#### Spontaneous extrusion of subconjunctival cysticercus cellulosae

EDITOR.—Cysticercus cellulosae, the larval form of *Taenia solium* (tapeworm), often affects the human eye. Human infection occurs on eating raw or inadequately cooked infected pork, consuming food or water contaminated with faecal matter containing the ova, or as a result of autoinfection.<sup>1</sup> Sommering first reported a case of ocular cysticercosis.<sup>2</sup> The parasite's most favoured site in the eye is vitreous and subretinal space followed by the subconjunctival tissue.<sup>3</sup> Spontaneous expulsion of cysticercosis from the subconjunctival space and orbit is uncommon.<sup>4-7</sup> We report a case of subconjunctival cysticercus cellulosae in which there occurred spontaneous extrusion.

#### CASE REPORT

A young 7 year boy presented with redness and swelling in the right eye. General physical and systemic examination revealed no abnormality. The right eye had a smooth, pinkish, hemispherical, subconjunctival, cystic swelling of approximately 8×5 mm size near the inner canthus (Fig 1). It was loosely adherent to the eyeball, non-reducible, and was mildly tender. The conjunctival vessels over and around it were mildly congested. The left eye was normal. An ultrasound of the right eye done with a waterbath revealed a subconjunctival

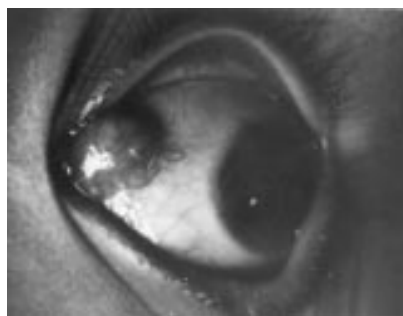


Figure 1 A subconjunctival cyst at the inner canthus of the right eye.

cyst with a central echogenic nodule suggestive of a cysticercus cellulosae (Fig 2). Excision of the cyst was planned, but the patient reported a week later with history of spontaneous expulsion of a small balloon-like translucent structure from the eye after which the swelling subsided. Repeat slit lamp examination did not show any swelling in the eye though there was redness and a conjunctival rent close to the inner canthus. An ultrasound examination was normal and the cyst seen earlier was not present.

#### COMMENT

Cysticercosis has a global distribution particularly in countries where there is increased incidence of pork eating. Ocular dissemination of cysticercus cellulosae is well known and is evident from several reports in the literature. The most favoured site is the vitreous and subretinal space followed by subconjunctival tissue and extraocular muscles. The cysticercus in the present case was subconjunctival and there was spontaneous expulsion. Since 1970 only six cases of spontaneous extrusion of cysticercus from subconjunctival space have been reported.<sup>4-7</sup> In the three cases reported by Bansal *et al*<sup>7</sup> the cyst was located within the medial rectus muscle in the first case, in the subconjunctival space in the second case, and in the superior orbit in the third case from where they were extruded. In the present case the cystic swelling was present near the inner canthus of the eye with attachment to the underlying muscle sheath.

In orbital and subconjunctival cysticercosis the cyst is usually attached to the muscle sheath, where it induces an inflammatory reaction and because of its constant motility it erodes through the conjunctiva and comes out leaving a rent in the conjunctiva which ultimately heals within a short period.<sup>7</sup> This case report highlights the importance of ultrasound in such lesions and should be the

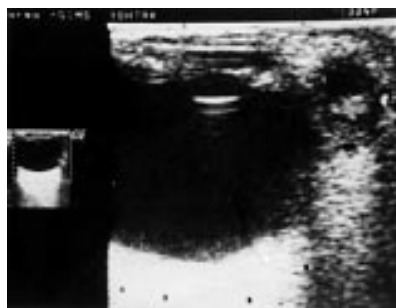

Figure 2 Ultrasound showing a cystic mass in the subconjunctival region in the lateral aspect of the eyeball with a central echogenic scolex and turbid contents within the cyst.

primary mode of investigation. On ultrasound the cyst is seen as a sonolucent area with well defined anterior and posterior margin with the presence of a central echodense, curvilinear highly reflective structure within the cyst, that of a scolex.<sup>8</sup>

SARITA MAGU

Department of Radiology, Pt B D Sharma PGIMS,  
Rohtak, India

MANISHA NADA

A K KHURANA

J P CHUGH

Department of Ophthalmology

Correspondence to: Dr Manisha Nada, Lecturer 2/11 J, University Type, Medical Enclave, PGIMS Rohtak-124001, Haryana, India

Accepted for publication 22 June 2000

- 1 Singh RY. Subconjunctival cysticercus cellulosae. *Ind J Ophthalmol* 1993;41:188-9.
- 2 Swatz WG. *Medical parasitology*. New York: McGraw Hill, 1956:127.
- 3 Bartholomew RS. Subretinal cysticercosis. *Am J Ophthalmol* 1975;79:670.
- 4 Reddy MV, Satyendran OM, Sivaramkrishnan K. Spontaneous extrusion of subconjunctival cysticercosis. *Acta Ophthalmol* 1970;48:321-4.
- 5 Baskararajan G, Srinivasan A, Sivarama Zulermanian P, *et al*. Case of cysticercosis presenting with persistent diplopia and spontaneous extrusion. *Ind J Ophthalmol* 1981;28:219-20.
- 6 Sud RN, Grewal SS. Spontaneous expulsion of subconjunctival cysticercus cellulosae. *Afro Asian J Ophthalmol* 1982;82-3.
- 7 Bansal RK, Gupta A, Grewal SPS, *et al*. Spontaneous extrusion of cysticercosis. Report of three cases. *Ind J Ophthalmol* 1992;40:59-60.
- 8 Murthy H, Kumar A, Verma L. Orbital cysticercosis—an ultrasonic diagnosis. *Acta Ophthalmol* 1990;68:612-14.

#### Massive basal cell carcinoma in a schizophrenic patient: treatment options and constraints

EDITOR,—Basal cell carcinoma (BCC) is the most common malignant tumour of the eyelids and face. Factors which increase the chance of orbital invasion include a medial canthal location, slow indolent growth, morpheiform growth pattern, surgical recurrence, advanced presentation, and neglect. Orbital invasion predisposes to intracranial involvement by direct or perineural spread. Management of orbital invasion is difficult and requires a multidisciplinary team approach for radical surgery and/or radiotherapy.<sup>1,2</sup>

We present a 76 year old Ukrainian man with a neglected tumour on his forehead which had spread over several years to involve the upper eyelids, anterior orbits, and ethmoid sinuses.

#### CASE REPORT

A 76 year old man with a long history of untreated forehead BCC complained of deteriorating vision in his right eye and ocular discharge. He had been admitted by the care of the elderly unit, for social reasons. He was a known paranoid schizophrenic treated with psychotropic drugs. Four years previously his physician had measured the lesion as being 2 cm × 4 cm and recommended plastic surgery, which was declined.

There was a massive, fungating lesion of the forehead, superior orbits, and nasal bridge, at least 15 cm × 17 cm (Fig 1). The right uncorrected visual acuity was 6/24 and left only light perception (unable to use a pin hole). There was fixed ptosis and right lower eyelid involutional ectropion. There was an opaque left cornea. The right fundus was normal. He did not permit intraocular pressure measurement.

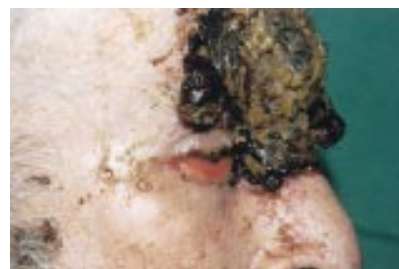

Figure 1 Oblique view of massive basal cell carcinoma of the forehead, nasal bridge, and upper eyelids showing right upper eyelid involvement, superomedial ulceration, and lower eyelid ectropion.

Investigations included a computed tomograph (CT) scan to evaluate the extent of tumour invasion and an incisional biopsy for histopathological diagnosis. The CT scan showed extensive soft tissue destruction, loss of the nasal bone, frontal sinuses, and bilateral anterior ethmoid, and extraconal orbital invasion (Fig 2). Histopathology confirmed extensive solid basal cell carcinoma.

He received symptomatic care with lid cleansing and topical chloramphenicol. A low visual aid assessment was arranged. Palliative treatment with radiotherapy was recommended but he refused all treatment including the low vision assessment.

The patient underwent a thorough mental status examination, which confirmed well controlled schizophrenia. We were not empowered to detain him for treatment against his will. He discharged himself from hospital with an untreated fungating BCC.

#### COMMENT

This patient had a neglected BCC which had caused destruction of soft tissue and bone, with orbital invasion and was threatening the vision in his remaining eye.

Where advanced scalp cancer displays deep invasion, radical excision and reconstruction are indicated.<sup>3</sup> Some authors suggest that aggressive surgical management of advanced skin neoplasia is the only treatment to produce long term survival.<sup>4</sup> In malignant cutaneous tumours involving the anterior skull base, invasion of the dura mater significantly affects survival.<sup>5</sup> In particular, spread along the medial orbital wall can lead to meningeal infiltration by direct invasion. As with squamous cell carcinoma, large basal cell carcinomas can invade the central nervous system by

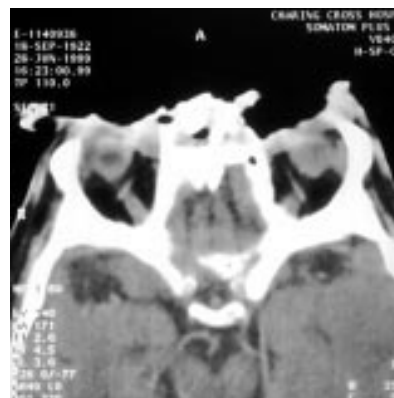

Figure 2 Computed tomograph scan shows destruction of the left nasal bone, frontal sinus, and bilateral anterior ethmoid involvement, bilateral anterior orbital extraconal involvement, as well as extensive soft tissue destruction.

perineural spread. Our patient risks spread of the tumour along the supraorbital and supra-trochlear nerves.

When local surgical therapy fails to prevent recurrence or definitive surgical resection is not possible, as in this case, alternative therapies must be considered. Opinions vary on the roles and efficacy of radiation therapy and chemotherapy for extensive lesions. Cisplatin and doxorubicin have been reported to achieve complete remission of recurrent invasive BCC of the medial canthus and orbit at 5 years.<sup>6</sup> Using adjunctive radiotherapy, large BCCs of the head showed partial to complete response but no cures achieved. A complete response was defined as disappearance of all measurable lesions (but cancer cells are still present microscopically) and a partial response was 50% reduction in all lesions.<sup>7</sup>

Patients with large or aggressive skin cancer are fortunately uncommon and management should be individualised following discussion with both the patient and his/her family. The options include a combination of surgery, radiotherapy, and chemotherapy with every effort made to preserve vision.

Our elderly, schizophrenic patient declined treatment and in these circumstances symptom relief is all that can be offered. Legal issues prevent forced treatment.

Informed consent includes providing adequate information about the treatment to make a reasoned decision. Obtaining consent must be free of coercion or threats, which would affect the patient's decision. The patient must be presumed competent unless shown otherwise. Psychiatric assessment confirmed that this patient was competent to make his own decisions. Exceptions include if immediate treatment is needed and the patient is unable to provide it (in coma or insufficient time to obtain it), the patient is legally incompetent to make a treatment decision, or decides to waive the right to be fully informed.

Untreated, the outlook for this patient is grim.

MUHAMMAD MUHTASEB  
JANE M OLVER

Eye Department, Charing Cross Hospital, Fulham  
Palace Road, London W6 8RF, UK

SHARON CONSTANTINE  
Pathology Department

Correspondence to: Jane M Olver

Accepted for publication 28 June 2000

- Glover TA, Grove AS. Orbital invasion by malignant eyelid tumours. *Ophthalmic Plast Reconstr Surg* 1989;5:1-12.
- Fitzpatrick PJ, Thompson GA, Easterbrook WM, et al. Basal and squamous cell carcinoma of the eyelids and their treatment by radiotherapy. *Int J Radiat Oncol Biol Phys* 1984;10:449-54.
- Lang NP, Kendrick JH, Flanigin H, et al. Surgical management of advanced scalp cancer. *Head Neck Surg* 1983;5:299-305.
- Thomas WO, Harper LL, Wong SG, et al. Surgical management of giant nonmelanoma skin neoplasia. *South Med J* 1998;91:190-5.
- Dias FL, Sa GM, Kligerman J, et al. Prognostic factors and outcome in craniofacial surgery for malignant cutaneous tumours involving the anterior skull base. *Arch Otolaryngol Head Neck Surg* 1997;123:738-42.
- Neudorfer M, Merimsky O, Lazar M, et al. Cisplatin and doxorubicin for invasive basal cell carcinoma of the eyelids. *Ann Ophthalmol* 1993;25:11-13.
- Robinson JK. Use of a combination of chemotherapy and radiation therapy in the management of advanced basal cell carcinoma of the head and neck. *J Am Acad Dermatol* 1987;17:770-4.

### Spontaneous resolution of eyeball displacement caused by maxillary sinusitis

EDITOR,—Spontaneous displacement of the eyeball caused by maxillary sinusitis is rare but is well documented.<sup>1-4</sup> Different treatments have been suggested but all are surgical. Spontaneous enophthalmos due to maxillary sinusitis was first described by Montgomery<sup>1</sup>; there have since been a series of reports describing this condition. The mechanism appears to arise from obstruction of the osteomeatal complex which impairs sinus ventilation. The resorption of retained secretions within the sinus produces a negative pressure which results in erosion of the thin orbital floor.<sup>2</sup> In the absence of trauma the triad of obstructive sinus disease, diminished antral volume, and enophthalmos has been thought to be caused by inflammatory resorption and inferior displacement of the orbital floor.<sup>3</sup> The globe is also displaced downwards and backwards such that the patient will have a narrow palpebral fissure and a deep superior sulcus above the eye.<sup>4</sup>

#### CASE REPORT

A 29 year old white male presented to the ophthalmology clinic having noticed that his right eye had been at a lower level than left one for the previous 2 years. There was no history of trauma. There were no nasal complaints or past history of sinusitis. On examination, the right globe was displaced inferiorly by 5-6 mm. Ophthalmic examination, including a visual acuity cover test and ocular movements were otherwise normal. A computed tomograph (CT) scan showed an opaque right maxillary antrum which was hypoplastic. The floor of the orbit was eroded and the right eyeball had sunk into the antrum (Fig 1).

He was seen in the ENT clinic and listed for an endoscopic middle meatal anastomosis and repair of the orbital floor. The patient changed his address and we were unable to contact him. Three years later, he contacted the ENT department to inquire about his appointment. We advised him that a further review might be beneficial. When reviewed the right eye was noted to be in a normal position. A repeat scan was undertaken which showed a well aerated right maxillary sinus which was larger than on the previous CT scan. The right orbital floor appeared well ossified and at a higher level than before (Fig 2). In view of these findings, it was decided that no further management was required.

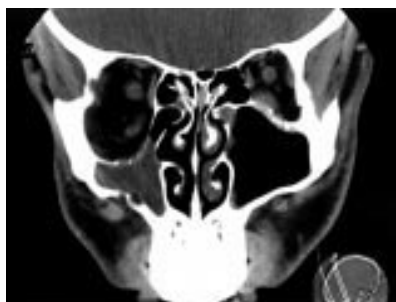

Figure 1 CT scan showing hypoplastic opaque right maxillary antrum, eroded right orbital floor, and sunken right eyeball.

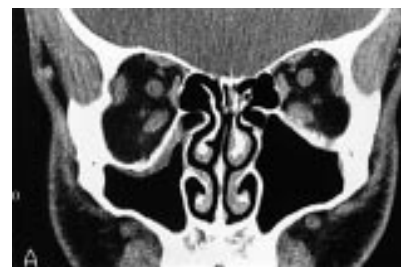

Figure 2 CT scan of the same patient after 3 years which shows reossified right orbital floor which is at a higher level than previously.

#### COMMENT

In this case report the support of the orbital floor was presumably lost secondary to blockage of osteomeatal complex and subsequent inflammatory changes and/or pressure changes within the antrum. Previous reports have advocated the surgical reconstitution of the orbital floor at an early stage.<sup>2-4</sup> Maxillary sinusitis is frequently a self resolving disease, as occurred in this case. Resolution of maxillary sinusitis, inflammatory and pressure components that produced the displacement of eyeball appears to have taken place. In the absence of negative pressure in the maxillary antrum and with orbital floor periosteum intact, new bone was laid down to reform the orbital floor with subsequent repositioning of the globe.

This case raises the question as to whether surgical intervention is required in these cases if the maxillary sinus disease can be treated or resolves of its own accord. Should medical or conservative management be inadequate then it can be hypothesised that a simple middle meatal anastomosis may be enough, following which the orbital floor might reform without need for reconstruction. The authors suggest this as a hypothesis extrapolating from the events that occurred in this patient.

U RAGHAVAN

Department of Otorhinolaryngology,  
Queen's Medical Centre, University Hospital,  
Nottingham NG7 2UH, UK

R DOWNES

Department of Ophthalmology

N S JONES

Department of Otorhinolaryngology

Correspondence to: Professor N S Jones

nick.jones@nottingham.ac.uk

Accepted for publication 28 June 2000

- Montgomery WW. Mucocoele of the maxillary sinus causing enophthalmos. *Eye Ear Nose Throat Monthly* 1964;42:41-4.
- Beasley NJP, Jones NS, Downes RN. Enophthalmos secondary to maxillary sinus disease: single-stage operative management. *J Laryngol Otol* 1995;109:868-70.
- Eto RT, House JM. Enophthalmos, a sequela of maxillary sinusitis. *Am J Neuroradiol* 1995;16:939-41.
- Wesley RE, Johnson JJ, Cate RC. Spontaneous enophthalmos from chronic maxillary sinusitis. *Laryngoscope* 1986;96:353-5.

### Familial thrombophilia and normal tension glaucoma

EDITOR,—The aetiology of normal tension glaucoma (NTG) is still debatable. Abnormal blood flow, systemic hypotension, abnormal blood coagulability, and other factors associated with cerebrovascular disease may have a causative role in NTG.<sup>1</sup> A study was designed to look at the prevalence of familial thrombophilia in cases of NTG.

## CASE REPORT

Seventy two patients were identified from ophthalmological database records with the diagnosis of NTG (defined as intraocular pressure <21 mm Hg, open drainage angle on gonioscopy, absence of any secondary cause for a glaucomatous optic neuropathy, and typical optic disc cupping which correlates with the visual field loss<sup>1</sup>). Strict criteria were used for entry into the study. Patients with NTG had to be under the age of 70 years with normal computerised tomography and normal day time intraocular pressure phasing. Forty five patients did not fulfil these criteria and so were excluded. Twenty seven patients formed the study group. None of these patients were on any medication which would be expected to have altered the values of the prothrombotic factors measured. The control group comprised 90 blood donors used by the regional thrombophilia laboratory as their control values of thrombophilic markers. The control group had an equal male:female ratio, an age range of 18–60 years, and no donor was on any medication or suffering from a medical illness. This gave a good control prevalence of the prothrombotic factors tested for in the study which are not altered by age variation. If any abnormality was found a repeat screen was performed to confirm the thrombophilic state. Blood for rheological factors (full blood count, plasma viscosity, lipid levels, glucose and liver function tests) and thrombophilic markers (protein S, protein C, factor V Leiden mutation, prothrombin G20210A allele, antiphospholipid antibodies, and hyperhomocysteinaemia) was taken for investigation. Informed consent was obtained and ethical approval had been given.

The study group was made up of 16 females and 11 males (ratio 1.5:1). The mean age of diagnosis was 60 years (range 43–69). Table 1 shows the patient details. Twenty three patients had a normal thrombophilia screen. Two patients had moderate hyperhomocysteinaemia (7% , controls 8% p>0.5), one was heterozygous for the factor V Leiden mutation (4% , controls 4.5% p>0.5) and another had a low titre of antiphospholipid antibodies (4%, controls 3% p>0.5). No patient had the prothrombin G20210A variant.

Table 1 Patient details

Patient No	Age	Sex	Thrombophilia screen	Possible risk factors
1	48	M	Negative	Nil
2	61	F	Negative	Nil
3	60	M	Mild raised homocysteine	Nil
4	65	F	Negative	Nil
7	69	M	Mild raised homocysteine	Migraine
8	62	M	Negative	Nil
9	56	F	Negative	Smoker
10	57	F	Negative	Smoker
11	51	F	Negative	CVA
12	66	M	Negative	Nil
13	62	F	Negative	Nil
14	67	F	Negative	CVA
15	63	F	Negative	Nil
16		F	Negative	Nil
17	57	M	Negative	Smoker
18	57	M	Negative	Nil
19	67	F	Low titre antiphospholipid antibodies	Nil
20	54	M	Negative	Migraine
21	43	F	Negative	Nil
22	68	M	Negative	Nil
23	52	F	Heterozygous factor V Leiden	Smoker DVT
24	51	F	Negative	Nil
25	62	F	Negative	Nil
26	69	M	Negative	DVT increased cholesterol
27	65	F	Negative	MI increased cholesterol

DVT = deep vein thrombosis; MI = myocardial infarction; CVA = cerebrovascular accident.

## COMMENT

In trying to discover the aetiology of NTG, some studies have suggested that these patients may have altered rheology producing a greater tendency to thrombosis.<sup>2,3</sup> There is also evidence of activation of the coagulation cascade and fibrinolytic pathway<sup>4</sup> but there is no conclusive evidence of a general vascular aetiology in the causation of NTG.<sup>5-7</sup>

The factor V Leiden mutation is a common hereditary abnormality with a 1–8% prevalence of heterozygous carriers depending on geographic location and accounts for the majority of activated protein C resistance. It is known that familial thrombophilia greatly increases the risk of venous thrombosis but it must be stressed that the most people with the Leiden mutation will not experience a thrombotic event.<sup>8</sup> The prothrombin G20210A variant is another common abnormality with a carrier prevalence of 1–4% being more common in southern Europe and, like the Leiden mutation, rare in people from Asian or African descent. An association of the prothrombin variant and the factor V Leiden mutation with arterial disease has not been demonstrated convincingly<sup>9</sup> and this therefore questions the role of these prothrombotic factors in the causation of ocular conditions suggested, in part, to be due to poor arterial supply. With this in mind, and the non-significant prevalence of factor V Leiden between the patient and control groups, it led us to conclude that the heterozygous state of factor V Leiden seen in patient 23 did not have a causative role in her glaucoma though may have contributed to her deep vein thrombosis.

Retinal artery and vein occlusions have been documented with hyperhomocysteinaemia. A raised homocysteine level has many causes and the haematological and vascular abnormalities associated with hyperhomocysteinaemia lead to a proatherogenic and prothrombotic metabolic environment.<sup>10</sup> Levels can be easily reduced with dietary folic acid supplementation, with or without vitamin B12, but it is unknown if this reduces the risk of vascular disease. It is also unknown if the strong link of hyperhomocysteinaemia and cardiovascular events is actually causal. Both patients in the study with hyperhomocysteinaemia were commenced on folic acid and subsequent levels of homocysteine were in the normal range.

Other hereditary thrombophilic conditions, such as protein C and protein S deficiency, and antiphospholipid antibodies have been reported in association with ocular vascular pathology and a combination of these factors may further increase the risk of hypercoagulability. The low levels of antiphospholipid antibodies, as seen in patient 20, are thought not to be prothrombotic.

It is unlikely that familial thrombophilia plays a significant aetiological part in NTG. A larger study is needed to confirm our findings. On the available evidence, thrombophilia screening in patients with NTG is not indicated.

Previous poster presentation at the Royal College of Ophthalmologists' annual congress. Harrogate 2000.

O C BACKHOUSE  
M J MENAGE  
B A MCVERRY

Leeds Teaching Hospitals NHS Trust, Leeds, UK

Correspondence to: O Backhouse, Department of Ophthalmology, Leeds General Infirmary, Leeds LS1 3EX, UK

[obackhouse@hotmail.com](mailto:obackhouse@hotmail.com)

Accepted for publication 10 July 2000

- Kamal D, Hitchings R. Normal tension glaucoma—a practical approach. *Br J Ophthalmol* 1998;**82**:835–40.
- Drance S, Sweeny V, Morgan R, et al. Studies of factors involved in the production of low tension glaucoma. *Arch Ophthalmol* 1973;**89**:457–65.
- Weinreb R. Blood rheology and glaucoma. *J Glaucoma* 1993;**2**:153–4.
- O'Brien C, Butt Z, Ludlam C, et al. Activation of the coagulation cascade in untreated primary open-angle glaucoma. *Ophthalmology* 1997;**104**:725–30.
- Joist J, Lichtenfield P, Mandell A, et al. Platelet function, blood coagulability and fibrinolysis in patients with low tension glaucoma. *Ann Ophthalmol* 1976;**94**:1893–5.
- Carter C, Brooks D, Doyle D, et al. Investigations into a vascular etiology for low-tension glaucoma. *Ophthalmology* 1990;**97**:49–55.
- Graham S, Golberg I, Murray B, et al. Activated protein C resistance—low incidence in glaucomatous optic disc haemorrhage and central retinal vein occlusion. *Aust NZ J Ophthalmol* 1996;**24**:199–205.
- Zoller B, Svensson P, He X, et al. Identification of the same factor V gene mutation in 47 out of 50 thrombosis-prone families with inherited resistance to activated protein C. *J Clin Invest* 1994;**94**:2521–4.
- Longstreth WT, Rosendaal FR, Siscovick DS, et al. Risk of stroke in young women and two prothrombotic mutations: factor V Leiden and prothrombin gene variant (G20210A). *Stroke* 1998;**29**:577–80.
- Rees MM, Rodgers GM. Homocysteinemia: association of a metabolic disorder with vascular disease and thrombosis. *Thromb Res* 1993;**71**:337–59.

### The wide field multifocal ERG reveals a retinal defect caused by vigabatrin toxicity?

EDITOR,—Vigabatrin is an effective drug for controlling chronic epilepsy and is taken more commonly in conjunction with additional antiepileptic drugs. There has been increasing subjective evidence that this drug may be associated with visual field defects.<sup>1-3</sup> We report here the interesting results we found from wide field multifocal ERGs performed on a patient taking vigabatrin.

## CASE REPORT

A 52 year old white man was referred to the eye clinic with a 6 month history of bumping into objects. His optician reported a bilateral inferior and nasal field defect. On examination his visual acuity was 6/6, N5 with correction, Ishihara 17/17 in each eye and intraocular pressures were 19 mm Hg. He had a full range of ocular movements and pupil reactions were normal. There was a mild pallor to both optic

discs and a spontaneous venous pulsation was present. Both maculae were healthy. Humphrey central 30-2 threshold visual fields recorded peripheral constriction within 10° of fixation. Blood pressure was 162/88 and urinalysis was negative. There was no significant family history nor did he have any history of night blindness. His medical history included epilepsy, for which he commenced anticonvulsant treatment in 1966. Despite a variety of drug regimens he never had adequate control of his symptoms until February 1990, when 1000 mg twice daily of vigabatrin was added to a regimen of carbamazepine 300 mg three times daily and sodium valproate 500 mg three times daily. Attempts were made to replace vigabatrin with gabapentin and then lamotrigine but neither proved to be successful; therefore, he returned to using vigabatrin. At the time of examination treatment included vigabatrin, carbamazepine, sodium valproate, and propranolol. Although the patient has been informed of the associated risk of visual field loss; he has elected to remain on vigabatrin treatment.

In November 1999 he was referred for conventional electrophysiological investigations, including electro-oculogram (EOG), visual evoked cortical potentials (VECP), and electroretinograms (ERG). All tests were performed in accordance with current ISCEV international standards. Findings were similar to other reports in that VEPs were normal, his EOGs were deemed to be equivocal in that the Arden index was >1.7 but <1.9. There was a small reduction in cone and maximal responses of the left eye in the ERG and a significant reduction of oscillatory potentials in both eyes (Table 1).

#### COMMENT

Advances in electrophysiological techniques have enabled topographical maps of retinal function to be constructed.<sup>4</sup> Wide field (90 degree) multifocal stimulation of the retina was performed using a custom built system with a 61 hexagonal display digitally back projected onto a polysilicon screen.<sup>5</sup>

Multifocal electroretinograms were performed in June 2000, results showed good correlation with visual fields in determining the area of visual loss. Normal retinal function was recorded in the central 40° of both eyes. However, a delay in implicit timings occurred with eccentricity; more importantly there were marked reductions in peripheral b-wave amplitudes which may be suggestive of retinal toxicity. These results were consistent in both

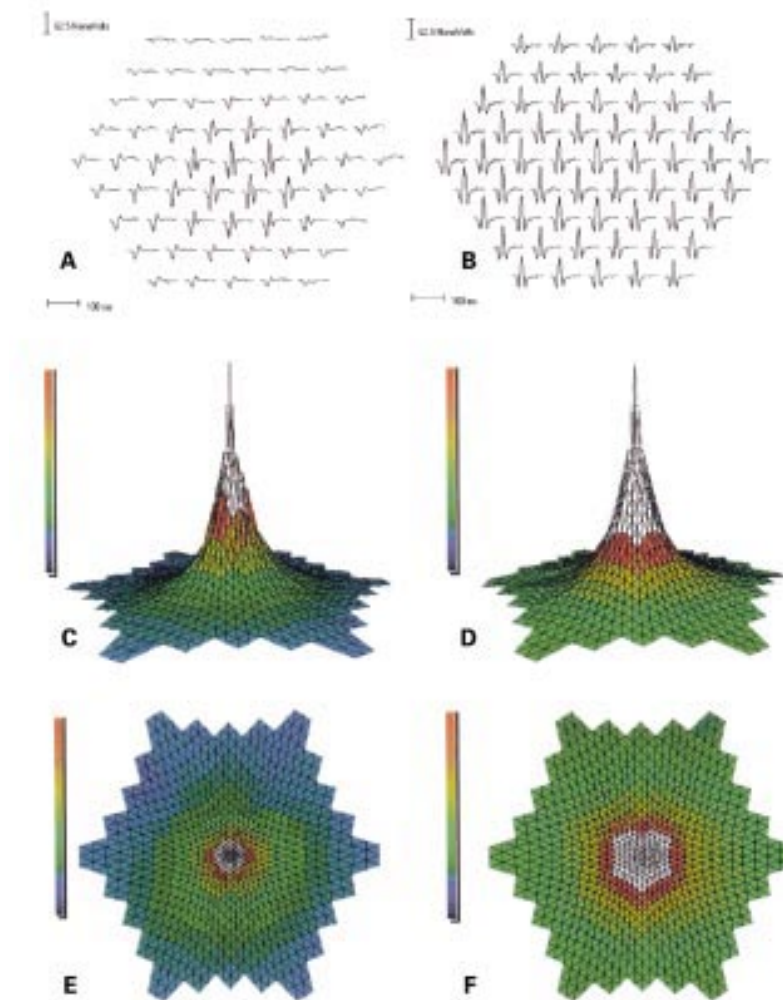


Figure 1 Left eye wide field multifocal ERG results from patient taking vigabatrin shown against results from a normal patient with no ocular pathology. (A) Multifocal waveforms show reduction in peripheral field retinal function, note areas of reduced b-wave amplitudes. (B) Normal multifocal waveforms. (C, D) Topographical maps of retinal function. (E, F) Plan view topographical maps.

eyes. Figure 1 depicts MFERG responses of the patient's left eye in comparison with the left eye of a normal subject.

The wide field multifocal ERG technique is the only objective tool for assessing the effect of vigabatrin toxicity on the peripheral retina. Currently, a larger clinical study utilising this technique is under way. We are confident that this technique will help to answer many of the unresolved issues associated with this form of treatment.

J McDONAGH

ElectroDiagnostic Imaging Unit, Tennent Institute of Ophthalmology, Gartnavel General Hospital, Glasgow, UK

D J GRIERSON

Department of Ophthalmology, Glasgow Royal Infirmary, Glasgow

D KEATING

ElectroDiagnostic Imaging Unit, Tennent Institute of Ophthalmology, Gartnavel General Hospital, Glasgow and Department of Clinical Physics and Bio-Engineering, University of Glasgow

S PARKS

ElectroDiagnostic Imaging Unit, Tennent Institute of Ophthalmology, Gartnavel General Hospital, Glasgow

Correspondence to: Miss Jo McDonagh, Electro-Diagnostic Imaging Unit, Tennent Institute of Ophthalmology, Gartnavel General Hospital, Glasgow G12 0YN, UK

[j.mcdonagh@clinmed.gla.ac.uk](mailto:j.mcdonagh@clinmed.gla.ac.uk)

Accepted for publication 12 July 2000

Table 1 Conventional electrophysiology findings

	Normal range	Right	Left
EOG	>1.9 equivocal >1.7<1.9	1.7	1.75
VEP (ms):			
60' check	85-109	104	95
15' check	89-116	105	109
ERG (µV):			
rod response	72-367	109	113
maximal response	241-709	253	222
oscillatory potentials	36-112	8	7
cone response	68-222	75	57
30 Hz flicker	25-150	57	68

- Eke T, Talbot JF, Lawden MC. Severe persistent visual field constriction associated with Vigabatrin. *BMJ* 1997;**314**:180-1.
- Daneshvar H, Racette L, Coupland SG, et al. Symptomatic and asymptomatic visual loss in patients taking vigabatrin. *Ophthalmology* 1999;**106**:1792-8.
- Manuchehri K, Goodman S, Siviter L, et al. A controlled study of vigabatrin and visual abnormalities. *Br J Ophthalmol* 2000;**84**:499-505.
- Sutter EE, Tran D. The field topography of ERG component in man—1. The photopic luminance response. *Vis Res* 1992;**32**:433-46.
- Parks SW, Keating D, Evans AL. Wide field functional imaging of the retina. *IEEE Medical Applications of Signal Processing* 1999;**99**:107:9/1-9/6.



## Epstein–Barr virus associated acute retinal necrosis

SUSANNE KRAMER, CHRISTOF BRUMMER and MANFRED ZIERHUT

*Br J Ophthalmol* 2001 85: 110  
doi: 10.1136/bjo.85.1.110d

---

Updated information and services can be found at:  
<http://bjo.bmj.com/content/85/1/110.8.full.html>

---

*These include:*

### References

This article cites 3 articles, 1 of which can be accessed free at:  
<http://bjo.bmj.com/content/85/1/110.8.full.html#ref-list-1>

### Email alerting service

Receive free email alerts when new articles cite this article. Sign up in the box at the top right corner of the online article.

---

### Notes

---

To request permissions go to:  
<http://group.bmj.com/group/rights-licensing/permissions>

To order reprints go to:  
<http://journals.bmj.com/cgi/reprintform>

To subscribe to BMJ go to:  
<http://group.bmj.com/subscribe/>