

Advanced glycation end products in human optic nerve head

Shiro Amano, Yuichi Kaji, Tetsuro Oshika, Teruaki Oka, Rikuo Machinami, Ryoji Nagai, Seiko Horiuchi

Abstract

Aims—To localise advanced glycation end products (AGEs) in human optic nerve head.

Methods—Optic nerve samples from 13 elderly individuals (seven diabetics and six non-diabetics) were obtained at necropsy. Pyrraline, an advanced glycation end product, was immunohistochemically localised in the optic nerve heads.

Results—In the diabetic subjects, moderate to intense immunoreactivity for pyrraline was detected in sclera, pia mater, cribriform plates, connective tissues in the optic nerve, and around vessels in the optic nerve and pia mater. Immunoreactivity for pyrraline was also detected around retinal vessels. In the non-diabetic subjects, slight or no immunoreactivity for pyrraline was found in cribriform plates and around the optic nerve vessels.

Conclusion—Accumulation of AGEs in cribriform plates and around vessels in the optic nerve may contribute to the development of optic neuropathy in diabetic patients.

(*Br J Ophthalmol* 2001;85:52-55)

Age is a major risk factor for chronic open angle glaucoma (COAG). Virtually every study agrees that the prevalence of COAG increases with age of the population being considered.¹⁻⁷ Diabetes is also reported to be a risk factor for COAG in several studies,⁸⁻¹² although further information from population based studies is necessary to definitely prove the role of diabetes in the development of COAG.¹³ While direct mechanical damage to the optic nerve and/or microangiopathy in the optic nerve head is a possible contributing mechanism in the pathogenesis of glaucoma,¹⁴ the exact

nature of age or diabetes related changes that contribute to the development of COAG is not known.

Recently, advanced glycation end products (AGEs) have been revealed to have an important role in age related changes and diabetic complications in several organs.¹⁵⁻¹⁷ AGEs have also been reported to accumulate in diabetic or ageing ocular tissues including cornea,¹⁸ lens,¹⁹⁻²² vitreous,²³ and retina.²⁴ Several AGE structures have been identified including ϵ -2-(formyl-5-hydroxymethyl-pyrrol-1-yl)-L-norleucine (pyrraline),²⁵ pentosidine,²⁶ N[ϵ]-carboxymethyl lysine (CML),²⁷ and crossline.²⁸ Among them, pyrraline is one of the major Maillard compounds resulting from long time incubation of glucose and proteins.²⁹ Pyrraline is known to increase in lens, sclerotic glomeruli, and perivascular extracellular matrix (ECM) in elderly subjects and diabetic patients.^{16 17 21}

In the present study, we performed immunohistochemistry for pyrraline in the human specimens to localise AGEs in the optic nerve head.

Materials and methods

SAMPLES

Thirteen optic nerve samples of 13 individuals (seven diabetics and six non-diabetics) were obtained at the time of necropsy at the division of pathology, University of Tokyo Hospital. The clinical characteristics of the subjects are summarised in Table 1. None of these subjects had suffered from any diseases affecting the optic nerve.

ANTIBODY

Polyclonal antibody to pyrraline was produced as previously reported.²⁵ To prepare immunogen, 6 mg of caproyl pyrraline was incubated with 6 mg of keyhole limpet haemocyanin (KLH) in the presence of 50 mM of 1-ethyl-3-(3-dimethylaminopropyl) carbodiimide (Pierce, Rockford, IL, USA) hydrochloride and 2.5 mM of N-hydroxysulphosuccinimide (Pierce, Rockford, IL, USA) at room temperature for 1 hour. The reaction was terminated by 20 mM of 2-mercaptoethanol and dialysed against phosphate buffered saline (PBS) for 24 hours. To raise the polyclonal antibody, 0.5 mg of caproyl pyrraline conjugated KLH in 50% Freund's complete adjuvant was injected intradermally into a rabbit at 20 skin sites, followed by four booster injections with the same amount of hapten conjugated KLH in 50% Freund's incomplete adjuvant. The serum was taken 10 days after the final immunisation for

Department of Ophthalmology, University of Tokyo School of Medicine, Tokyo, Japan

S Amano
Y Kaji
T Oshika

Department of Pathology, University of Tokyo School of Medicine, Tokyo, Japan

T Oka
R Machinami

Department of Biochemistry, University of Kumamoto School of Medicine, Kumamoto, Japan

R Nagai
S Horiuchi

Correspondence to: Shiro Amano, 7-3-1 Hongo, Bunkyo-ku, Tokyo, 113-8655 Japan
amanos-ky@umin.ac.jp

Accepted for publication 23 May 2000

Table 1 Clinical characteristics

Eye	Age	Sex	DM	DM type	Duration of DM	DM retinopathy
1	52	F	-	-	-	-
2	62	F	-	-	-	-
3	68	M	-	-	-	-
4	69	F	-	-	-	-
5	69	F	-	-	-	-
6	75	M	-	-	-	-
7	59	M	+	NA	NA	NA
8	60	M	+	NIDDM	8 years	NA
9	64	F	+	NIDDM	14 years	NA
10	65	F	+	NIDDM	16 years	NA
11	72	M	+	NIDDM	23 years	NA
12	74	M	+	NIDDM	19 years	Background
13	78	M	+	NIDDM	28 years	Proliferative

NA = not available.

Table 2 Pyrraline immunoreactivity

Eye	Retina	Optic nerve axon	Cribriform plates	Sclera	Pia mater	Vessels in		
						retina	optic nerve	pia mater
1	-	-	+	-	-	-	-	-
2	-	-	-	-	-	-	-	-
3	-	-	+	-	+	-	+	+
4	-	-	+	-	+	-	+	+
5	-	-	-	-	-	-	-	-
6	-	-	+	-	-	-	-	++
7	-	-	++	++	++	++	++	++
8	-	-	++	++	++	++	++	++
9	+	-	+++	++	+++	++	++	+++
10	+	-	++	++	++	++	++	++
11	-	-	++	++	++	++	++	+++
12	+	-	+++	++	+++	++	++	+++
13	+	-	+++	+++	+++	++	++	+++

--negative; +=weak immunoreactivity; ++=moderate immunoreactivity; +++=intense immunoreactivity.

further affinity purification. The antiserum against hapten conjugated KLH was passed over 5 ml of protein G immobilised sepharose gel (Amersham Pharmacia Biotech, Uppsala, Sweden). The column was extensively washed with PBS and eluted with 0.1 M citric acid buffer (pH 3.0). The pooled antibody fraction was neutralised, concentrated, and dialysed against PBS and used as affinity purified polyclonal antibody in the present study.

IMMUNOHISTOCHEMISTRY

Immunohistochemical staining was performed by the streptavidin-biotin-complex method. After fixation with 4% paraformaldehyde, optic nerve samples were embedded in paraffin. At least, 10 longitudinal sections 4 µm thick were obtained in each optic nerve sample. The sections were preincubated in 1.0% hydrogen peroxide solution in PBS for 20 minutes at room temperature to inhibit the endogenous peroxidase activity. After washing with PBS three times for 10 minutes at 4°C, the sections were incubated with 10% normal goat serum (Histofine, Nichirei, Tokyo) for 2 hours at room temperature to inhibit non-specific binding. The sections were then exposed to primary antibody (rabbit polyclonal antibody for pyrraline) diluted to 1.0 mg/ml with PBS containing 1% bovine serum albumin and 0.04% sodium azide for 24 hours at 4°C. After washing with PBS three times for 20 minutes at room temperature, secondary antibody (goat biotinylated anti-rabbit IgG: Histofine) was added for 2 hours at room temperature. The sections were then incubated with peroxidase conjugated streptavidin for 2 hours at room temperature. To visualise the immunoreactions, sections were incubated with diaminobenzidine (DAB) in PBS. Finally, sections were counterstained with haematoxylin. For negative control, we replaced the primary antibody with normal rabbit serum IgG (1.0 mg/ml) diluted with PBS containing 1% bovine serum albumin and 0.04% sodium azide. Following these preparations, the sections were processed to immunostaining as described above. The intensity of immunoreactivity was graded by a masked observer qualitatively as negative, weak, moderate, or intense.

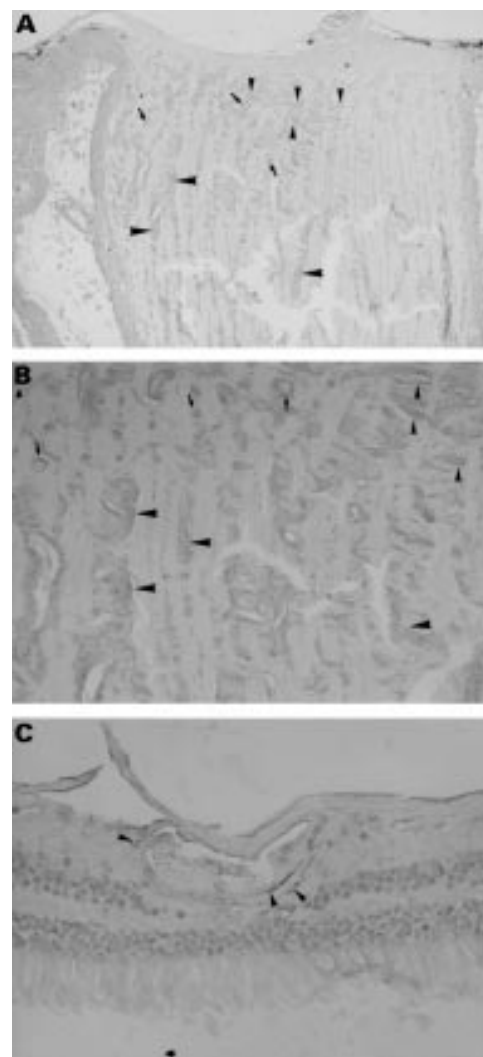


Figure 1 The results of immunohistochemistry in optic nerve head (A and B) and retina (C) of a 72 year old diabetic man (case 11). Moderate to intense immunoreactivity for pyrraline was detected in sclera, pia mater, cribriform plates (small arrowheads in A and B), connective tissues in the optic nerve head (large arrowheads in A and B), and around optic nerve vessels (small arrows in A and B). There was no immunoreactivity in optic nerve axons. Immunoreactivity for pyrraline was also detected around retinal vessels (arrowheads in C). Original magnification, $\times 10$ (A), $\times 25$ (B), $\times 100$ (C).

STATISTICAL ANALYSIS

Since the sample number was small for statistical analysis, the intensity of immunoreactivity was reclassified into two groups: negative (negative or weak immunoreactivity) and positive (moderate or intense). Then, the immunoreactivity for pyrraline was compared between diabetics and non-diabetics using a two tailed Fisher's exact test, with $p < 0.05$ deemed significant.

Results

The results of immunohistochemistry are summarised in Table 2. In the diabetic subjects, moderate to intense immunoreactivity for pyrraline was detected in sclera, pia mater, cribriform plates, connective tissues in optic nerve, and around vessels in optic nerve and pia mater (Fig 1A and B). Immunoreactivity for pyrraline was also detected around retinal vessels (Fig

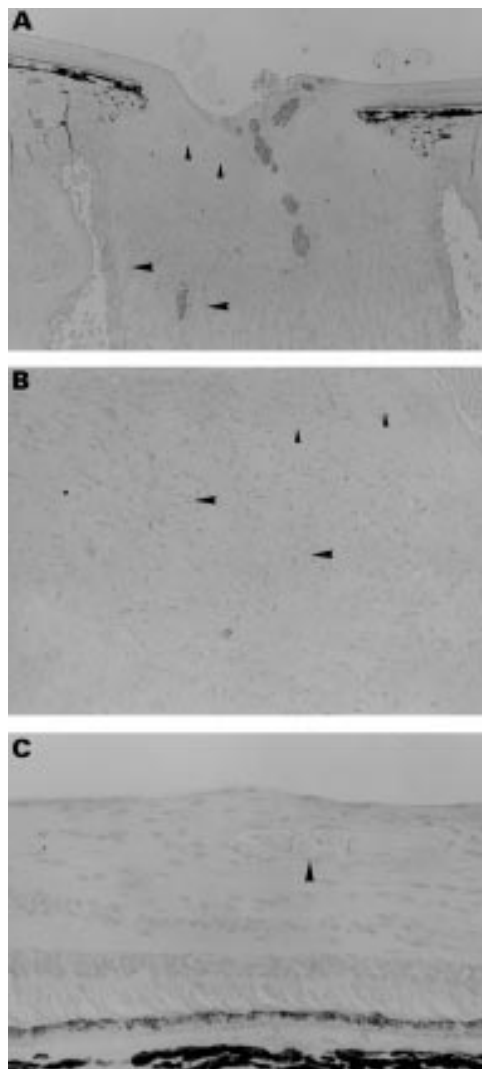


Figure 2 The results of immunohistochemistry in optic nerve head (A and B) and retina (C) of a 69 year old non-diabetic woman (case 5). There was no immunoreactivity in cribriform plates (small arrowheads in A and B), connective tissues in the optic nerve head (large arrowheads in A and B), or around retinal vessels (arrowhead in C). Original magnification, $\times 10$ (A), $\times 25$ (B), $\times 100$ (C).

1C). There was no immunoreactivity in optic nerve axons. In the negative controls in which normal rabbit serum IgG was used instead of primary polyclonal antibody to pyrraline, there was no immunoreactivity in optic nerve heads (data not shown).

In the non-diabetic subjects, slight or no immunoreactivity for pyrraline was found in cribriform plates and around optic nerve vessels (Fig 2A and B). There was no immunoreactivity in optic nerve axons (Fig 2B) and retinas (Fig 2C).

The differences in the intensity of pyrraline immunoreactivity between diabetics and non-diabetics were statistically significant in cribriform plates, sclera, pia mater, and vessels in each tissue ($p < 0.01$).

Discussion

AGEs have been shown to accumulate in diabetic and ageing organs,^{15-17 30 31} including ocular tissues (cornea,¹⁸ lens,¹⁹⁻²¹ vitreous,²³ and

retina²⁴). Accumulation of AGEs in ECM was shown to elicit several changes of ECM including decreased solubility, decreased susceptibility to enzymes, and changes in such properties as thermal stability, mechanical strength, and stiffness.³²⁻³⁵ These changes in the physicochemical properties of ECM are believed to contribute, in part, to the development of age related changes and diabetic complications, including cardiovascular disease, retinopathy, nephropathy, indurated skin and joint stiffness.^{32 36} Albon *et al*³⁷ reported a linear age related increase of pentosidine, an advanced glycation end product, in lamina cribrosa. Accumulation of AGEs in ECM of optic nerve heads in the elderly may decrease elasticity of lamina cribrosa and compromise the ability of cribriform plates to bear the strain caused by elevated intraocular pressure.³⁷ The results of the current study showed that accumulation of pyrraline in cribriform plates was accelerated in diabetics compared with non-diabetics, suggesting that the mechanical properties of the lamina cribrosa change more severely in diabetics than in non-diabetics. Such alterations in cribriform plates may contribute to more frequent development of glaucoma in diabetics.

Owing to the scarcity of samples, we could not examine the accumulation of pyrraline in younger subjects. We obtained one sample of a fetus of 34 weeks, in which immunoreactivity for pyrraline was completely absent in ECM and vessels in the optic nerve head (data not shown). A previous study³⁷ demonstrated a linear age related increase of pentosidine in the lamina cribrosa in subjects ranging from 3 weeks to 92 years old. Thus, it is probable that pyrraline accumulates in lamina cribrosa with age.

Dramatic changes in ECM of lamina cribrosa in COAG have been reported including a decrease of collagen density and an appearance of masses of elastin.³⁸ These changes in ECM may alter the mechanical properties of the tissue early in the disease. In the current series, optic nerve heads from eyes with glaucoma were not available. Examination of AGEs in glaucomatous subjects may further clarify the involvement of AGEs in the development of glaucoma.

AGEs have been shown to accumulate in myelin and tubulin of peripheral nerves.³⁹⁻⁴¹ Non-enzymatic glycation of such neural proteins is thought to impair axonal transport, which may induce diabetic neuropathy. In the present study, immunoreactivity for pyrraline was not detected in neural component of optic nerves, suggesting that diabetic optic neuropathy is different from diabetic neuropathy in other peripheral nerves in that it is not induced by the accumulation of AGEs in the neural proteins.

In conclusion, advanced accumulation of AGEs in cribriform plates and around optic nerve vessels in diabetics may contribute to the development of optic neuropathy by compromising the ability of cribriform plates to bear

the strain caused by elevated intraocular pressure and/or impairing the microcirculation.

The authors have no commercial or proprietary interest in the product or company described in this paper.

- 1 Bengtsson B. The prevalence of glaucoma. *Br J Ophthalmol* 1981;**65**:46–9.
- 2 Coffey M, Reidy A, Wormald R, *et al*. Prevalence of glaucoma in the west of Ireland. *Br J Ophthalmol* 1993;**77**:17–21.
- 3 Hollows FC, Graham PA. Intraocular pressure, glaucoma, and glaucoma suspects in a defined population. *Br J Ophthalmol* 1966;**50**:570–86.
- 4 Klein BE, Klein R, Sponsel WE, *et al*. Prevalence of glaucoma: the Beaver Dam Eye Study. *Ophthalmology* 1992;**99**:1499–504.
- 5 Tielsch JM, Sommer A, Katz J, *et al*. Racial variations in the prevalence of primary open-angle glaucoma: the Baltimore Eye Survey. *JAMA* 1991;**266**:369–74.
- 6 Armaly MF, Krueger DE, Maunder L, *et al*. Biostatistical analysis of the collaborative glaucoma study. *Arch Ophthalmol* 1980;**98**:2163–71.
- 7 Leske MC, Ederer F, Podgor M. Estimating incidence from age-specific prevalence in glaucoma. *Am J Epidemiol* 1981;**113**:606–13.
- 8 Becker B. Diabetes mellitus and primary open-angle glaucoma. *Am J Ophthalmol* 1971;**71**:1–16.
- 9 Klein BE, Klein R, Jensen SC. Open-angle glaucoma and older-onset diabetes: the Beaver Dam Eye Study. *Ophthalmology* 1994;**101**:1173–7.
- 10 Klein BE, Klein R, Moss SE. Intraocular pressure in diabetic persons. *Ophthalmology* 1984;**91**:1356–60.
- 11 Wilson MR, Hertzmark E, Walker AM, *et al*. A case-control study of risk factors in open angle glaucoma. *Arch Ophthalmol* 1987;**105**:1066–71.
- 12 Dielmans J, de Jong PTVM, Stolk R, *et al*. Primary open angle glaucoma, intraocular pressure, and diabetes mellitus in the general population. *Ophthalmology* 1996;**103**:1271–5.
- 13 Ellis JD, Morris AD, MacEwen CJ for the DARTS/MEMO collaboration. Should diabetic patients be screened for glaucoma? *Br J Ophthalmol* 1999;**83**:369–72.
- 14 Wilson MR, Martone JF. Epidemiology of chronic open-angle glaucoma. In: Ritch R, Shields MB, Krupin T, eds. *The glaucoma*. 2nd ed. St Louis: Mosby, 1996:753–68.
- 15 Makita Z, Radoff S, Rayfield EJ, *et al*. Advanced glycosylation end products in patients with diabetic nephropathy. *N Engl J Med* 1991;**325**:836–842.
- 16 Miyata S, Monnier V. Immunohistochemical detection of advanced glycosylation end products in diabetic tissues using monoclonal antibody to pyrraline. *J Clin Invest* 1992;**89**:1102–12.
- 17 Monnier VM, Sell DR, Nagaraj RH, *et al*. Maillard reaction-mediated molecular damage to extracellular matrix and other tissue proteins in diabetes, aging, and uremia. *Diabetes* 1992;**41**:36–41.
- 18 Kaji Y, Usui T, Oshika T, *et al*. Advanced glycation end products in diabetic corneas. *Invest Ophthalmol Vis Sci* 2000;**41**:362–8.
- 19 Dunn JA, Patrick JS, Thorpe SR, *et al*. Oxidation of glycated proteins: age-dependent accumulation of N^ε-(carboxymethyl) lysine in lens proteins. *Biochemistry* 1989;**28**:9464–8.
- 20 Araki N, Ueno N, Chakrabarti B, *et al*. Immunochemical evidence for the presence of advanced glycation end products in human lens proteins and its positive correlation with aging. *J Biol Chem* 1992;**267**:10211–214.
- 21 Nagaraj RH, Sady C. The presence of a glucose-derived Maillard reaction product in the human lens. *FEBS Lett* 1996;**382**:234–8.
- 22 Nakayama H, Mitsuhashi T, Kuwajima S, *et al*. Immunochemical detection of advanced glycation end products in lens crystallins from streptozotocin-induced diabetic rat. *Diabetes* 1993;**42**:345–50.
- 23 Stitt AW, Moore JE, Sharkey JA, *et al*. Advanced glycation end products in vitreous: Structural and functional implications for diabetic vitreopathy. *Invest Ophthalmol Vis Sci* 1998;**39**:2517–23.
- 24 Murata T, Nagai R, Ishibashi T, *et al*. The relationship between accumulation of advanced glycation end products and expression of vascular endothelial growth factor in human diabetic retinas. *Diabetologia* 1997;**40**:764–9.
- 25 Hayase F, Nagaraj RH, Miyata S, *et al*. Aging of proteins: immunological detection of a glucose-derived pyrrole formed during maillard reaction in vivo. *J Biol Chem* 1989;**264**:3758–64.
- 26 Sell DR, Monnier VM. Structure elucidation of a senescence cross-link from human extracellular matrix. *J Biol Chem* 1989;**264**:21597–602.
- 27 Ahmed MU, Thorpe SR, Baynes JW. Identification of N^ε-carboxymethyllysine as a degradation product of fructoselysine in glycated protein. *J Biol Chem* 1986;**261**:4889–94.
- 28 Nakamura K, Hasegawa T, Fukunaga Y, *et al*. Crosslines A and B as candidates for the fluorophores in age- and diabetes-related cross-linked proteins, and their diacetates produced by Maillard reaction of α-N-acetyl-L-lysine with D-glucose. *J Chem Soc Chem Commun* 1992;**14**:992–4.
- 29 Njoroge FG, Sayre LM, Monnier VM. Detection of D-glucose-derived pyrrole compounds during Maillard reaction under physiological conditions. *Carbohydr Res* 1987;**167**:211–20.
- 30 Mitsuhashi T, Nakayama H, Itoh T, *et al*. Immunochemical detection of advanced glycation end products in renal cortex from STZ-induced diabetic rat. *Diabetes* 1993;**42**:826–32.
- 31 Makino H, Shikata K, Hironaka K, *et al*. Ultrastructure of nonenzymatically glycated mesangial matrix in diabetic nephropathy. *Kidney International* 1995;**48**:517–26.
- 32 Vlassara H, Bucala R, Striker L. Pathogenic effects of advanced glycation: Biochemical, biologic, and clinical implications for diabetes and aging. *Lab Invest* 1994;**70**:138–51.
- 33 Andreassen TT, Seyer-Hansen K, Bailey AJ. Thermal stability, mechanical properties and reducible cross-links of rat tail tendon in experimental diabetes. *Biochimica et Biophysica Acta* 1981;**677**:313–7.
- 34 Winlove CP, Parker KH, Avery NC, *et al*. Interactions of elastin and aorta with sugars in vitro and their effects on biochemical and physical properties. *Diabetologia* 1996;**39**:1131–9.
- 35 Bruel A, Oxlund H. Changes in biomechanical properties, composition of collagen and elastin, and advanced glycation endproducts of the rat aorta in relation to age. *Atherosclerosis* 1996;**127**:155–65.
- 36 Reiser KM. Nonenzymatic glycation of collagen in aging and diabetes. *Proc Soc Exp Biol Med* 1998;**218**:23–37.
- 37 Albon J, Karwatowski WSS, Avery N, *et al*. Changes in the collagenous matrix of the aging human lamina cribrosa. *Br J Ophthalmol* 1995;**79**:368–75.
- 38 Hernandez MR, Ye H. Glaucoma: changes in extracellular matrix in the optic nerve head. *Ann Med* 1993;**25**:309–15.
- 39 Vlassara H, Brownlee M, Cerami A, *et al*. Nonenzymatic glycosylation of peripheral nerve protein in diabetes mellitus. *Proc Natl Acad Sci USA* 1981;**78**:5190–2.
- 40 Vlassara H, Brownlee M, Cerami A, *et al*. Excessive nonenzymatic glycosylation of peripheral and central nervous system myelin components in diabetic rats. *Diabetes* 1983;**32**:670–4.
- 41 Cullum NA, Mahon J, Stringer K, *et al*. Glycation of rat sciatic nerve tubulin in experimental diabetes mellitus. *Diabetologia* 1991;**34**:387–9.



Advanced glycation end products in human optic nerve head

Shiro Amano, Yuichi Kaji, Tetsuro Oshika, et al.

Br J Ophthalmol 2001 85: 52-55

doi: 10.1136/bjo.85.1.52

Updated information and services can be found at:

<http://bjo.bmj.com/content/85/1/52.full.html>

References

These include:

This article cites 37 articles, 20 of which can be accessed free at:

<http://bjo.bmj.com/content/85/1/52.full.html#ref-list-1>

Article cited in:

<http://bjo.bmj.com/content/85/1/52.full.html#related-urls>

Email alerting service

Receive free email alerts when new articles cite this article. Sign up in the box at the top right corner of the online article.

Topic Collections

Articles on similar topics can be found in the following collections

[Neurology](#) (1042 articles)

[Optic nerve](#) (558 articles)

[Public health](#) (379 articles)

Notes

To request permissions go to:

<http://group.bmj.com/group/rights-licensing/permissions>

To order reprints go to:

<http://journals.bmj.com/cgi/reprintform>

To subscribe to BMJ go to:

<http://group.bmj.com/subscribe/>