

Slope analysis of the optic disc in eyes with ocular hypertension and early normal tension glaucoma by confocal scanning laser ophthalmoscope

J Dong, E Chihara

Abstract

Aims—To determine whether quantitative differences in sector based slope can differentiate between eyes with ocular hypertension with and without glaucomatous disc changes and eyes with normal tension glaucoma with glaucomatous disc changes.

Methods—Seventy six eyes with ocular hypertension or early glaucomatous disc changes were consecutively categorised into three groups: 22 eyes with ocular hypertension and no glaucomatous disc changes (OHND); 35 with ocular hypertension and glaucomatous disc changes (OHD); and 19 with normal ocular tension and glaucomatous disc changes (NTD). Twenty eyes served as controls. The average total slope angle and sector based slope angle of the cup, total contour area, effective area, neuroretinal rim area, half depth area, cup to disc ratio, contour variation, mean contour depth, average depth, volume below, half depth volume, and contour tilt were evaluated with a confocal scanning laser ophthalmoscope.

Results—The earliest changes in eyes with OHND or OHD started in the slope at the nasal inferior sector ($p<0.05$), followed by the superior and temporal superior sectors ($p<0.05$). The mean slopes in eyes with NTD and OHD were steeper than in controls ($p<0.05$). Statistically significant differences were found between controls and disease groups in the half depth area, mean contour depth, and half depth volume. The cup to disc ratios in eyes with OHD and NTD were greater than in eyes with OHND; the volume below was greater in eyes with NTD than in eyes with OHND and OHD.

Conclusions—The steep slope in the nasal inferior section is the first indicator of glaucomatous nerve defects in many eyes. The half depth parameters, half depth area, and half depth volume may be useful for distinguishing ocular hypertension with and without glaucomatous disc changes.

(Br J Ophthalmol 2001;85:56-62)

using the confocal scanning laser ophthalmoscope (SLO).¹⁻⁴ While many studies have shown a positive correlation between the morphological indices of the optic nerve head and the visual field indices in patients with glaucoma,⁵⁻⁷ the correlation between the slope of the cup and the loss of nerve fibres has not been extensively studied. Caprioli *et al* reported that the mean peripapillary slope of the surface of the nerve fibre layer was significantly different between normal eyes and those with glaucoma.⁸ Ocular hypertension is an important risk factor for glaucomatous optic nerve fibre loss⁹; however, the annual incidence of new glaucomatous visual field loss in patients with ocular hypertension is approximately 1%.¹⁰ It is difficult to predict which patients with ocular hypertension will develop visual field loss.

The optic nerve head in eyes with normal tension glaucoma tends to have more thinning of the rim than eyes with high tension glaucoma, even though the degree of visual field loss is the same in the two glaucoma types.¹¹ Using the Heidelberg retina tomograph, the optic disc area was found to be significantly larger in eyes with normal tension glaucoma than in those with high tension glaucoma ($p<0.05$) but the rim area and volume, the height of the retinal nerve fibre layer, and the retinal nerve layer cross sectional area were not significantly different between eyes with normal tension glaucoma and those with high tension glaucoma.¹² The cup wall of the optic nerve head in normal tension glaucoma was reported to be steeper than in high tension glaucoma.¹³ Recent technological advances that enable us to evaluate the slope of the cup may be useful for detecting very early glaucomatous changes to the optic nerve and for differentiating disc changes between normal tension glaucoma and high tension glaucoma.

We have attempted to evaluate the hypothesis that the sector based slope is useful for differentiating between eyes with ocular hypertension with and without glaucomatous disc changes and eyes with normal tension glaucoma with glaucomatous disc changes (NTD). We also studied the power of two other parameters—the half depth area and the half volume of the optic nerve head—to evaluate their ability to distinguish eyes with ocular hypertension with glaucomatous disc changes (OHD) from those without glaucomatous disc changes (OHND), and eyes with OHD changes from eyes with NTD changes more precisely than other total global variables.

Sensho-kai Eye
Institute, Uji, Kyoto,
Japan
J Dong
E Chihara

Department of
Ophthalmology and
Visual Science,
Graduate School of
Medicine, Kyoto
University, Kyoto,
Japan
J Dong

Correspondence to:
Dr J Dong, Sensho-kai Eye
Institute, Hiraki-cho 1-6, Uji,
Kyoto 611-0026, Japan
jdong@kuhp.kyoto-u.ac.jp

Accepted 16 June 2000

Glaucomatous optic nerve damage is largely irreversible so detection of early structural changes in the optic nerve head is clinically important. To evaluate changes to the optic disc, many investigators have studied the topographic parameters of the optic nerve head

Table 1 Patient demographic data

	Control	OHND	OHD	NTD
No of eyes	20	22	35	19
Age (years)	47.9 (22.1)	49.0 (20.0)	54.7 (9.6)	57.9 (12.8)
Best corrected visual acuity	1.43 (0.13)	1.36 (0.22)	1.32 (0.22)	1.32 (0.24)
Refractive error (D)	-0.57 (2.11)	-1.74 (2.72)	-1.20 (2.58)	0.02 (0.92)*
Corneal curvature (mm)	7.68 (0.23)	7.59 (0.24)	7.67 (0.30)	7.63 (0.25)
Mean deviation (dB)	0.83 (1.45)	1.11 (1.67)	0.12 (1.37)	0.50 (1.89)

*Indicates significant difference between OHND group and NTD group ($p < 0.05$). OHND = ocular hypertension without glaucomatous disc change; OHD = ocular hypertension with glaucomatous disc change; NTD = normal tension with glaucomatous disc change.

Patients and methods

PATIENTS

Two hundred and twenty six consecutive patients with glaucoma or suspected glaucoma who visited the Sensho-kai Eye Institute were enrolled in this prospective study; 20 volunteers served as controls. All participants underwent evaluations of visual acuity and intraocular pressure (IOP), gonioscopy, and visual field testing. The type of glaucoma was masked to examiners, and the optic disc was evaluated using an ophthalmoscope and confocal SLO (TopSS, Laser-Diagnostic Technology, San Diego, CA, USA). The visual field was tested using the Octopus 1-2-3, program GIX (Interzeag AG, Schlieren, Switzerland). All participants were Asians; informed consent was obtained from all patients in accordance with the tenets of the Declaration of Helsinki 1989.

Exclusion criteria included a best corrected visual acuity of $< 20/40$, a spherical equivalent refractive error that did not fall between -6.0 and $+3.0$ D, and the presence of ocular

diseases other than glaucoma. Patients were also excluded if they had retinochoroidal disease, a narrow angle, hazy media, and did not provide informed consent. Individuals without adequate TopSS imaging or reliable visual fields were also excluded. Because the aim of this study was to detect early glaucomatous changes, patients with visual field changes (described below) were excluded from the study. The demographic characteristics of the patients including best corrected visual acuity, refractive error, corneal curvature, and mean deviation for each group are shown in Table 1.

Glaucomatous visual field defects were defined as three consecutive point depressions > 5 dB more than age matched controls, and at least one of three consecutive points with a depression > 10 dB or two consecutive points depressed > 10 dB and two adjacent points across the nasal horizontal meridian with a difference of > 5 dB.⁷ The visual fields were examined more than three times in each patient. Data were obtained exclusively from the visual field with a reliability factor of $< 15\%$ and a short term fluctuation of < 1.5 dB. The time between the visual field examination and imaging with TopSS was less than 3 months.

Twenty normal healthy subjects were recruited from hospital volunteers and employees between November 1995 and November 1998. One eye of each control subject was chosen randomly for inclusion in the study.

One hundred and fifty patients were excluded from the study, leaving 76 patients (76 eyes) who did not have visual field defects based on the results of testing with the Octopus 1-2-3 who were subdivided as follows: 22 with OHND, 35 with OHD, and 19 with NTD. One eye of each patient was used in the study; the study eye was chosen randomly if both eyes were eligible.

Glaucomatous optic disc changes included retinal nerve fibre layer defects and at least one of the following clinical features: a difference in the cup to disc ratio between the right and left eye of > 0.2 , focal or diffuse thinning of the neuroretinal rim area judged by two of three glaucoma specialists, and undermining of the cup at the superior or inferior meridians. The retinal nerve fibre layer was examined under green light using a Wratten No. 58 green filter.

Eyes with OHD changes were defined as those with untreated IOP of > 21 mm Hg and glaucomatous optic disc changes but no glaucomatous visual field defects. In the group with OHD changes 32 eyes had primary open angle glaucoma and three had pseudoexfoliation syndrome. Eyes with NTD changes did not have a past history of ocular trauma or surgery, pigment dispersion, a shallow anterior chamber, a major haemodynamic crisis, or any other disease that might cause nerve damage. They had an untreated IOP of consistently < 21 mm Hg for more than 6 months without use of any antiglaucoma medications, and had glaucomatous optic disc changes but no glaucomatous visual field defects. Eyes with OHND changes had an untreated IOP of consistently > 21 mm Hg but they had neither ophthalmoscopic glaucomatous optic disc

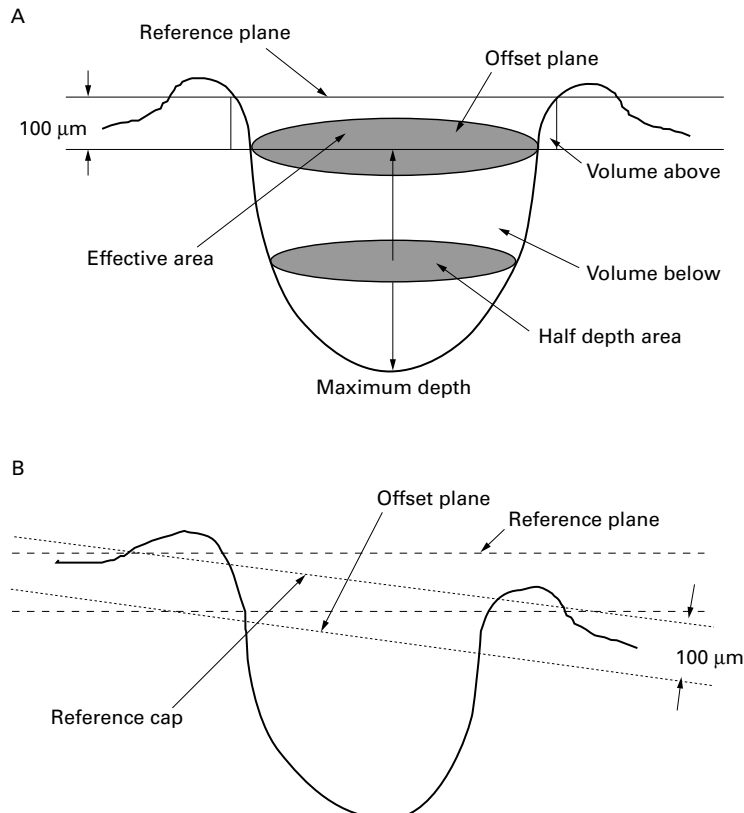


Figure 1 (A) Schematic drawing of optic disc parameters by the TopSS. (B) Image of the reference cap tilting which is automatically corrected by a reference cap.

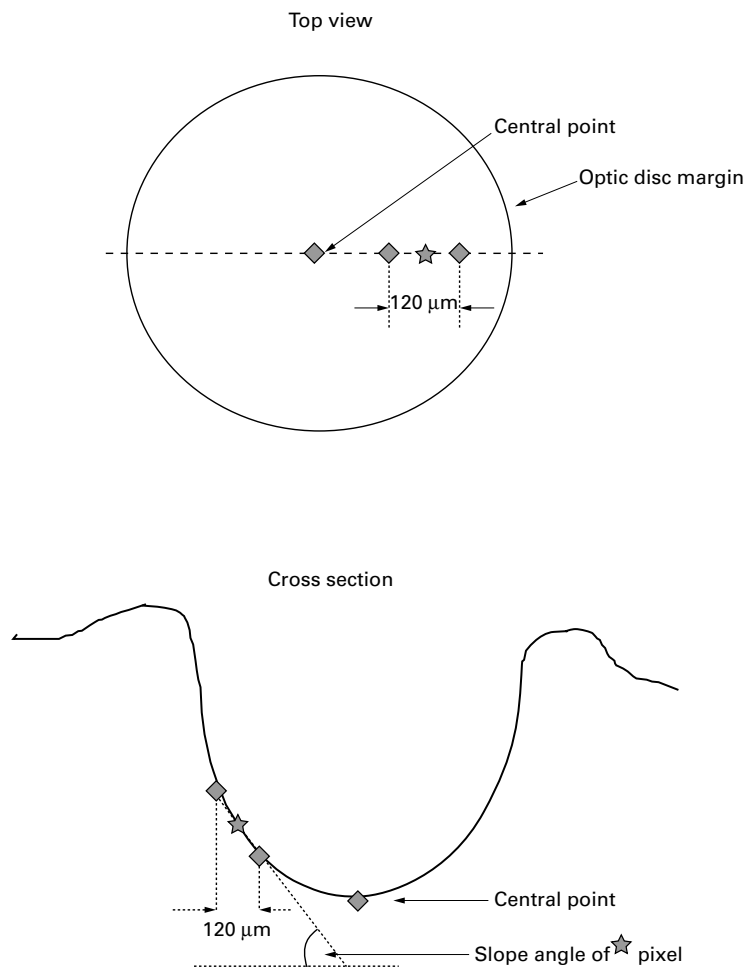


Figure 2 Image of calculation of slope for one pixel.

changes nor a glaucomatous visual defect detected by the Octopus.

Control subjects did not have a history of ocular disease or a family history of glaucoma, an IOP of <21 mm Hg, and normal ophthalmological examination results and normal visual fields.

INSTRUMENTATION

The imaging system of the TopSS has been described previously.¹⁴ Briefly, it has a gallium-aluminium-arsenide diode laser beam (wavelength 780 nm) and a measurement time of 0.9 seconds. The confocal image of the TopSS is based on a three dimensional resolution element in the form of a cylinder; by changing the focal plane of the scanning laser beam, light reflected from 32 slices of tissue is collected and reconstructed to compile the baseline image. Each image is 256×256 pixels and each pixel corresponds to the tissue height at that location. The first slice was taken anterior to the retinal surface and the peak in the axial intensity profile corresponded to the bottom of the optic cup. The scan range was broad enough so that the peak in the axial intensity profile corresponded to both the retinal surface and the optic disc cup. The field of each image was $10^\circ \times 10^\circ$. After the refractive error and axial length were input, the size of the images was adjusted automatically.

PARAMETERS

The definitions of the parameters analysed in this study are described in the user's manual.¹⁴ Briefly, the retinal reference plane (Fig 1A) is flat at the level of the retinal surface. In this study the offset plane was set $100 \mu\text{m}$ below the reference plane and defined the top of the cup area. Tilting of the disc is automatically correlated by a reference cap procedure (Fig 1B). With this methodology, the position of the centre is defined as the average height of all points along the ellipse that cover the area of interest. The central point is connected to each perimeter point, generating a "straw hat" cap that fits over the disc; the cap is then offset by the amount specified by the offset surface distance. When the optic disc is tilted, the retinal reference plane may not be as sensitive as the reference cap for evaluating the disc perimeters. The retinal reference cap was therefore chosen to analyse the data using current TopSS software version 2.1. The instrument automatically forms a baseline or reference image using three consecutive and independent topographic images. The optic disc margin was represented by a computer assisted ellipse when the disc was round or oval, and the margin was manually traced when the disc was irregular.

The program defined the slope topographic data as follows: it determined the central point within the area of interest; constructed 12 radial sectors through the central point at 30° intervals; calculated the slope at all the pixels along the meridian by the linear regression of two dimensional locus values between a span of $120 \mu\text{m}$ (on the right and the left, Fig 2); and the average sector based slope value was obtained by averaging the slope value of each pixel along the radial profiles in the sector. The average slope was defined as an average of 12 sector based slope angles of the cup wall within the area of interest. Sector 1 was located in the superior nasal meridian of the disc; sectors 1–12 were numbered clockwise for right eyes and counterclockwise for left eyes (Fig 3).

Two dimensional parameters

The total contour area was defined as a computer assisted ellipse or an irregularly shaped optic disc area defined by the operator. The effective area was a cupped area $100 \mu\text{m}$ below the reference cap. The neuroretinal rim area was the difference between the total contour area and the effective area. The half depth area was the tomographic area of the cup at the half depth of the cup. The cup to disc ratio was the ratio between the effective area and the total contour area (Fig 1A).

Three dimensional parameters

The contour variation was defined as the difference between the maximum and minimum height values along the perimeter of the total contour area. The mean contour depth was the average height values of all pixels within the total contour area. The average depth was the average height value of all pixels below the reference cap. The volume below was the volume of the cup below the effective

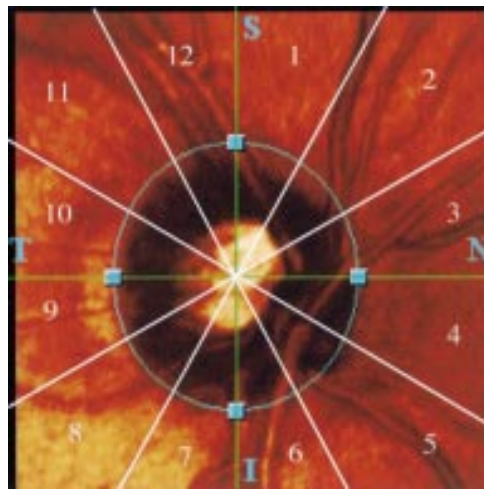


Figure 3 Scheme of the optic disc sectors for right eyes: superior sectors (sectors 1 and 12), nasal superior sector (sector 2), nasal sectors (sectors 3 and 4), nasal inferior sector (sector 5), inferior sectors (sectors 6 and 7), temporal inferior sector (sector 8), temporal sectors (sectors 9 and 10), and temporal superior sector (sector 11). For the purposes of analysis the left eyes were mirror images.

area. The half depth volume was the volume of the cup below the half depth area. The positive contour tilt value indicates nasal tilting of the contour line, and a negative value indicates temporal tilting.

REPRODUCIBILITY

The reproducibility of the data was evaluated in 20 normal control subjects. All selected eyes were scanned five times and a coefficient of variation of the various tomographic param-

eters was computed (Table 2). For the two dimensional parameters the coefficients of variation of the neuroretinal rim area and the effective area were 3.29 (SD1.66)% and 5.63 (SD1.99)%, respectively. For the three dimensional parameters the reproducibility was poor, the coefficient of variation of the volume below and the average depth being 14.1 (SD5.72)% and 10 (SD5.43)%, respectively. The contour tilt indicated a coefficient of variation value that was poorer than the other parameters.

STATISTICAL ANALYSIS

The data were analysed using analysis of variance with post hoc comparisons tested using the Fisher protected least significant difference procedure.¹⁵ The sensitivity and specificity calculated by discriminant analysis were evaluated if the topographic parameters could discriminate between the four groups. A statistical software package by Social Survey Research Information (Tokyo) was used. Differences were considered statistically significant with p values of <0.05.

Results

No statistically significant differences were found in age, refractive error, and corneal curvature between the four groups ($p>0.05$) except for the refractive error; eyes with OHND changes were significantly more myopic than eyes with NTD changes ($p<0.05$; Table 1). The mean (SD) deviation values measured by Octopus 1-2-3 of the control group and the groups with OHND, OHD, and NTD changes were 0.83 (1.45) dB, 1.11 (1.67) dB, 0.12 (1.37) dB, and 0.50 (1.89) dB, respectively.

Table 3 shows the average slopes and 12 sector based slopes for each group. The nasal inferior slope of the control eyes was significantly less steep than that of the eyes with OHD or OHND changes at sectors 5, 6, 7, and sectors 5 and 6, respectively ($p<0.05$). This suggests that morphological changes in the optic disc start from the nasal inferior sectors of the disc in patients with OHND changes. The differences in the slopes in the superior and temporal superior areas (sectors 1, 11, 12) were significant between the eyes with OHD changes and the control eyes ($p<0.05$), but not significant between the eyes with OHND changes and the control eyes. In the eyes with NTD changes the slopes at sectors 1, 2, 5, 6, 7, 8, 11, and 12 were significantly steeper than in the control group ($p<0.05$).

The two and three dimensional topographic data of the four groups are shown in Table 4. There was no significant difference in optic disc parameters between the eyes with OHND changes and control eyes ($p>0.05$, Table 5). Discrimination between these two groups using 12 optic disc variables was not significant ($p=0.17$). The eyes with OHND changes were significantly different from the eyes with OHD changes in half depth area, cup to disc ratio, mean contour depth, and half depth volume ($p<0.05$). Discrimination of the two groups by linear discriminant analysis using 12 optic disc variables was significant ($p=0.022$), and the

Table 2 Reproducibility of optic disc parameters evaluated in 20 normal control subjects

	Mean (SD) coefficient of variation	Average slope section	Mean (SD) coefficient of variation
Total contour area	5.99 (6.43)%	Total	4.46 (2.41)%
Neuroretinal rim area	3.29 (1.66)%	S-1	7.60 (3.33)%
Effective area	5.63 (1.99)%	S-2	7.36 (3.78)%
Half depth area	14.16 (9.73)%	S-3	8.15 (5.28)%
C/D ratio	5.70 (1.99)%	S-4	8.53 (5.28)%
Mean contour depth	16.49 (10.13)%	S-5	8.51 (4.96)%
Volume below	14.10 (5.72)%	S-6	9.09 (5.56)%
Maximum depth	13.58 (6.60)%	S-7	7.94 (4.55)%
Half depth volume	15.45 (9.02)%	S-8	8.50 (5.07)%
Average depth	10.00 (5.43)%	S-9	8.50 (3.88)%
Contour variation	16.62 (11.24)%	S-10	8.79 (5.22)%
Contour tilt	24.71 (26.53)%	S-11	8.28 (5.58)%
		S-12	6.87 (2.94)%

C/D ratio = cup to disc ratio.

Table 3 Differences in global and sector based slopes between the four groups

Slope section	Control	OHND	OHD	NTD
Total	35.72 (7.35)	39.34 (6.62)	39.53 (6.46)*	40.77 (4.92)*
S-1	35.74 (9.47)	40.54 (7.88)	40.97 (7.90)*	41.13 (5.50)*
S-2	36.82 (9.90)	40.83 (8.20)	39.40 (8.52)	42.99 (6.57)*
S-3	36.84 (9.89)	37.75 (8.23)	38.81 (7.41)	39.32 (5.57)
S-4	35.80 (9.97)	40.44 (8.75)	38.66 (7.27)	38.84 (6.31)
S-5	34.57 (7.47)	39.55 (10.18)*	39.81 (7.84)*	40.78 (5.33)*
S-6	35.30 (9.10)	40.88 (7.66)*	39.63 (7.69)*	40.87 (6.61)*
S-7	35.18 (8.01)	39.03 (6.70)	40.15 (8.36)*	40.96 (6.13)*
S-8	35.52 (8.23)	37.27 (7.52)	39.66 (8.80)	40.92 (7.41)*
S-9	34.84 (8.31)	38.20 (8.86)	38.07 (8.80)	39.31 (7.00)
S-10	35.33 (7.91)	38.46 (9.01)	37.88 (8.89)	40.30 (7.08)
S-11	36.44 (8.45)	40.49 (7.97)	41.04 (7.42)*	42.50 (6.45)*
S-12	35.49 (9.22)	40.15 (8.06)	40.32 (7.98)*	41.46 (6.98)*

Values are mean (SD).

*Indicates significant difference from control group ($p<0.05$).

OHND = ocular hypertension without glaucomatous disc change; OHD = ocular hypertension with glaucomatous disc change; NTD = normal tension with glaucomatous disc change.

Table 4 Differences in optic disc parameters between the four groups

	Control	OHND	OHD	NTD
Total contour area (mm ²)	2.248 (0.389)	2.455 (0.654)	2.600 (0.656)	2.747 (0.699)
Effective area (mm ²)	0.870 (0.274)	1.119 (0.578)	1.371 (0.492)	1.592 (0.456)
Neuroretinal rim area (mm ²)	1.352 (0.344)	1.337 (0.367)	1.234 (0.354)	1.112 (0.398)
Half depth area (mm ²)	0.263 (0.126)	0.352 (0.236)	0.489 (0.263)	0.695 (0.354)
C/D ratio	0.386 (0.102)	0.440 (0.145)	0.519 (0.118)	0.576 (0.064)
Mean contour depth (mm)	-0.006 (0.083)	-0.030 (0.079)	-0.080 (0.087)	-0.126 (0.067)
Volume below (mm ³)	-0.175 (0.092)	-0.274 (0.204)	-0.376 (0.242)	-0.498 (0.212)
Maximum depth (mm)	-0.527 (0.169)	-0.609 (0.208)	-0.625 (0.315)	-0.692 (0.133)
Half depth volume (mm ³)	-0.032 (0.022)	-0.046 (0.041)	-0.074 (0.061)	-0.107 (0.072)
Average depth (mm)	-0.130 (0.161)	-0.220 (0.079)	-0.257 (0.093)	-0.257 (0.093)
Contour variation	0.326 (0.091)	0.370 (0.241)	0.373 (0.134)	0.322 (0.096)
Contour tilt (°)	-4.430 (5.464)	-1.364 (6.134)	-3.409 (5.928)	-1.721 (5.368)

Values are mean (SD).

C/D ratio = cup to disc ratio; OHND = ocular hypertension without glaucomatous disc change; OHD = ocular hypertension with glaucomatous disc change; NTD = normal tension with glaucomatous disc change.

sensitivity, specificity, and diagnostic precision were 75.8%, 85.0%, and 79.2%, respectively. There were statistically significant differences between the eyes with OHND changes and those with NTD changes in effective area, half depth area, cup to disc ratio, mean contour depth, volume below, and half depth volume ($p < 0.001$, Table 5).

A comparison between the control eyes and the eyes with OHD changes showed significant differences in effective area, half depth area, cup to disc ratio, mean contour depth, volume below, half depth volume ($p < 0.001$), and total contour area ($p = 0.045$). Other than the variables listed above, there was a statistically significant difference between the eyes with NTD changes and the control eyes in the neuroretinal rim area and the maximum depth. When the series of 12 optic disc variables was used for testing discriminant analysis, discrimination of OHD and NTD eyes from control eyes was significant ($p = 0.014$ and $p = 0.0002$, respectively). The sensitivity, specificity, and diagnostic precision were 85.7%, 75.0% and 81.8%, 100%, 90.0% and 94.9%, respectively. A comparison between the eyes with OHD changes and the eyes with NTD changes revealed a larger half depth area ($p < 0.001$), larger volume below, mean contour depth and half depth volume in patients with NTD changes ($p < 0.05$). Discrimination of OHD and NTD eyes by linear discriminant analysis was not significant ($p = 0.52$). No statistically significant difference was found between any of the groups in visual field indices such as the mean deviation.

Table 5 Statistical differences in the optic disc parameters evaluated by the Fisher's protected least significant difference procedure

	Control/ OHND	Control/ OHD	Control/ NTD	OHND/ OHD	OHND/ NTD	OHD/ NTD
Total contour area	0.280	0.045†	0.016†	0.392	0.136	0.406
Neuroretinal rim area	0.821	0.211	0.035†	0.302	0.052	0.244
Effective area	0.091	0.0003‡	<0.0001‡	0.052	0.002‡	0.102
Half depth area	0.264	0.0023‡	<0.0001‡	0.049†	<0.0001‡	0.006‡
C/D ratio	0.124	<0.0001‡	<0.0001‡	0.013†	0.0002‡	0.019
Mean contour depth	0.330	0.002‡	<0.0001‡	0.027†	0.0003‡	0.047†
Volume below	0.119	0.0007‡	<0.0001‡	0.070	0.0007‡	0.040†
Maximum depth	0.265	0.142	0.033†	0.801	0.269	0.328
Half depth volume	0.396	0.0063‡	<0.0001‡	0.049†	0.0005‡	0.036†
Average depth	0.995	0.992	0.106	0.998	0.100	0.072
Contour variation	0.350	0.278	0.935	0.954	0.315	0.245
Contour tilt	0.089	0.530	0.147	0.197	0.844	0.308

† $p < 0.05$; ‡ $p < 0.001$.

C/D ratio = cup to disc ratio; OHND = ocular hypertension without glaucomatous disc change; OHD = ocular hypertension with glaucomatous disc change; NTD = normal tension with glaucomatous disc change.

Discussion

The reproducibility of the data in this study using TopSS was compatible with reports published by Janknecht *et al*¹⁶ and Bhandari *et al*¹⁷ who used the Heidelberg retinal tomograph. Our study confirms the results of a previous study by Geyer and others that high reproducibility of data by TopSS enables quantitative measurements of the optic nerve head; they reported that the mean (SD) values of all variables had good reproducibility.¹⁸

In the present study we have emphasised the importance of measuring the slope of the cup wall of the optic disc, which was not quantifiable before the advent of laser scanning tomography. Typically, low slope values showed a shallow cup and large values a steep cup (Table 3). The nasal inferior slope in patients with OHND changes was statistically significantly steeper than in control subjects but there was no statistically significant difference in the global slope value between the two groups. In the early stage of the disease no other two and three dimensional TopSS variables were significantly different between the group with OHND changes and the control group, which suggests that infinitesimal changes begin in the nasal inferior section of the disc in eyes with OHND changes.

Using Heidelberg retinal tomographic parameters, no differences between patients with ocular hypertension and healthy individuals were detected by Iester and colleagues.¹⁹ Tuulonen and Airaksinen²⁰ examined 23 patients with ocular hypertension and found that the superior or inferior notches and vertical enlargement (cup to disc ratio) or cup enlargement were the most common signs of early disc changes. We found a significantly larger effective area, half depth area, cup to disc ratio, mean contour depth, volume below, and half depth volume in patients with OHD changes than in control subjects (Table 4). These results confirm previous reports by Wollstein and coworkers²¹ and Bathija and associates.²² Using the Heidelberg retina tomograph, these investigators found that there were statistically significant differences between healthy and glaucomatous eyes in all topographic parameters of the optic disc measured. They reported the most sensitive parameters to be cup shape, rim area, height variation contour, and retinal nerve layer thickness. However, previous studies did not mention

slope data because previously available instrumentation could not analyse the slope. Levy *et al*³ reported that the earliest change in eyes with glaucoma is recession of the lamina cribrosa. Because the steep slope in the nasal inferior portion was the only finding in patients with ocular hypertension without ophthalmoscopically observable glaucomatous optic disc changes, slope changes reflect the earliest optic disc changes at the lamina cribrosa preceding nerve fibre loss. This suggests that steep nasal inferior and temporal superior slopes are indicators of new glaucomatous visual field loss in patients with ocular hypertension.

The large disc size in eyes with NTD changes may explain some differences between those with NTD changes and those with OHD, but not all because statistically significant differences were still apparent when the effects of the total contour area were cancelled by proportional analysis of disc parameters between these two groups (results not shown). Because the half depth volume was significantly more affected in eyes with NTD changes than in those with OHD changes, the glaucomatous nerve loss tends to occur below the half depth of the disc in eyes with normal tension glaucoma.

The total contour area of the eyes with OHD and NTD changes was larger than in the control eyes ($p < 0.05$). Our results do not agree with those of Bathija *et al*²² and Zangwill and coworkers²⁴ who reported no significant differences in the disc sizes between patients with normal tension glaucoma, ocular hypertension, and high tension glaucoma. These different results may be attributed primarily to different ethnic groups, ages, and to refractive errors, and secondarily to differences in the definition of the reference plane and the placement of the observer drawn contour line. Bathija *et al*²² and Zangwill *et al*²⁴ defined the reference plane as the height of the retinal surface at the level of the papillomacular bundle, but we used the reference cap as the standard for reasons described above. Our data showed that the contour area could not distinguish controls from patients with OHD or NTD changes. In contrast, Hatch and colleagues reported that older patients with glaucoma had smaller discs.¹ This difference again may be attributed to differences in the study groups.

The half depth area and half depth volume successfully differentiated between eyes with OHND and OHD changes. Discriminant analysis using a combination of half depth area and half depth volume has higher sensitivity and higher specificity to discriminate between eyes with OHND and OHD changes ($p < 0.05$) than when these two parameters are not combined (results not shown). This suggests that these two parameters appropriately specify characteristic changes of the optic nerve head in the different groups.

Garway-Heath and Hitchings suggested that preferred selection of patients with discs with large cups would tend to overestimate the diagnostic power of the device.²⁵ To avoid this bias our study included subjects with no glaucomatous optic disc or visual field changes.

Discriminant analysis was sufficiently precise to apply correct diagnostic assignments to the healthy and glaucomatous eyes. Garway-Heath and Hitchings also wondered whether abnormal disc morphology could correctly identify patients with glaucoma. They pointed out that the diagnosis of glaucoma includes many clinically recognisable signs so quantitative measurements of the optic disc should be as important as measurements of IOP and perimetry in clinical practice.

Weinreb²⁶ reported the usefulness of the confocal SLO in clinical glaucoma. Both the optic disc findings and visual field examinations may be useful for evaluating nerve damage. However, the reproducibility of the measurements may be of concern. The mean deviation values of the visual field may not be sufficiently precise to distinguish glaucomatous visual fields from normal fields because the visual field test depends on a subjective patient response. It is well recognised that there are significant changes in the visual field indices between the first and second visual field tests in patients with glaucoma.²⁷ The error of automated visual field testing is especially high when patients are old and cataracts are dense. The confocal SLO may also address problems such as poor ocular stability and lenticular opacities; however, this system is superior to others in that it provides an objective examination and does not depend on patient responses. We hypothesise that laser scanning tomography will provide an important potential benefit in examining elderly patients with glaucoma.

In summary, we have used the TopSS to analyse the optic nerve head and to differentiate normal eyes from eyes with OHD and OHND changes, and from eyes with NTD changes. The results suggest that the steep slope in the nasal inferior and temporal superior sections is the first sign that glaucomatous nerve defects are developing. The results also suggest that the half depth variables are useful for distinguishing patients with OHND changes from those with OHD changes.

The authors have no proprietary interest in any aspect of this study.

- Hatch WV, Flanagan JG, Etchells EE, *et al*. Laser scanning tomography of the optic nerve head in ocular hypertension and glaucoma. *Br J Ophthalmol* 1997;**81**:871–6.
- Airaksinen PJ, Drance S, Schulzer M. Neuroretinal rim area in early glaucoma. *Am J Ophthalmol* 1985;**99**:1–4.
- Jonas JB, Gusek GC, Naumann GO. Optic disc morphometry in chronic primary open-angle glaucoma. II Correlation of the intrapapillary morphometric data to visual field indices. *Graefes Arch Clin Exp Ophthalmol* 1988;**226**:531–8.
- Balasz G, Drance S, Schulzer M, *et al*. Neuroretinal rim area in suspected glaucoma and early chronic open angle glaucoma. Correlation with parameters of visual function. *Arch Ophthalmol* 1991;**109**:77–83.
- Iester M, Seindale MV, Mikelberg FS. Section-based analysis of optic nerve head parameters and visual field indices in healthy and glaucomatous eyes. *J Glaucoma* 1997;**6**:371–6.
- Brigatti L, Caprioli J. Correlation of visual field with scanning confocal laser optic measurements in glaucoma. *Arch Ophthalmol* 1995;**113**:1191–4.
- Iester M, Mikelberg FS, Courtright P, *et al*. Correlation between the visual field indices and Heidelberg retinal tomograph parameters. *J Glaucoma* 1997;**6**:78–82.
- Caprioli J, Park HJ, Ugurlu S, *et al*. Slope of the peripapillary nerve fiber layer surface in glaucoma. *Invest Ophthalmol Vis Sci* 1998;**39**:2321–8.
- Hart WM Jr, Yablonski M, Kass MA, *et al*. Multivariate analysis of the risk of glaucomatous visual field loss. *Arch Ophthalmol* 1979;**97**:1455–8.
- Shields B. *Textbook of glaucoma*, 3rd ed. Baltimore: Williams & Wilkins, 1992.

- 11 Caprioli J, Spaeth GL. Comparison of the optic nerve head in high- and low-tension glaucoma. *Arch Ophthalmol* 1985; **103**:1145-9.
- 12 Tarek EID, Spaeth GL, Moster MR, *et al*. Quantitative difference between the optic nerve head and peripapillary retina in low-tension and high-tension primary open angle glaucoma. *Am J Ophthalmol* 1997; **124**:805-13.
- 13 Caprioli J. Correlation between optic disc appearance and type of glaucoma. In: Varma R, Spaeth GL, eds. *The optic nerve in glaucoma*. Philadelphia: Lippincott, 1993:91-8.
- 14 Diagnostic Technologies Inc. *Software Version 3.0.13. TopSS™ Software Manual Preliminary*.
- 15 Beausencourt E, Elsner AE, Hartnett ME, *et al*. Quantitative analysis of macular holes with scanning laser tomography. *Ophthalmology* 1997; **104**:2018-29.
- 16 Janknecht P, Funk J. Optic nerve head analyser and Heidelberg retina tomograph: accuracy and reproducibility of topographic measurements in a model eye and in volunteers. *Br J Ophthalmol* 1994; **78**:760-8.
- 17 Bhandari A, Fontana L, Fitzke FW, *et al*. Quantitative analysis of the lamina cribrosa in vivo using a scanning laser ophthalmoscope. *Curr Eye Res* 1997; **16**:1-8.
- 18 Geyer O, Michaeli-Cohen A, Silver DM, *et al*. Reproducibility of topographic measures of the glaucomatous optic nerve head. *Br J Ophthalmol* 1998; **82**:14-7.
- 19 Iester M, Broadway DC, Mikelberg FS, *et al*. A comparison of healthy, ocular hypertensive, and glaucomatous optic disc topographic parameters. *J Glaucoma* 1997; **6**:363-70.
- 20 Tuulonen A, Airaksinen PJ. Initial glaucomatous optic disc and retinal nerve fiber layer abnormalities and their progression. *Am J Ophthalmol* 1991; **111**:485-90.
- 21 Wollstein G, Garway-Heath DF, Hitchings RA. Identification of early glaucoma cases with the scanning laser ophthalmoscope. *Ophthalmology* 1998; **105**:1557-63.
- 22 Bathija R, Zangwill L, Berry CC, *et al*. Detection of early glaucomatous structural damage with confocal scanning laser tomography. *J Glaucoma* 1998; **7**:121-7.
- 23 Levy NS, Grapps EE, Bonney RC. Displacement of the optic nerve head; response to acute intraocular pressure elevation in primate eyes. *Arch Ophthalmol* 1981; **99**:2166-74.
- 24 Zangwill LM, Van Horn S, De Souza Lima M, *et al*. Optic nerve head topography in ocular hypertensive eyes using confocal scanning laser ophthalmoscopy. *Am J Ophthalmol* 1996; **122**:520-5.
- 25 Garway-Heath DF, Hitchings RA. Sources of bias in studies of optic disc and retinal nerve fibre layer morphology. *Br J Ophthalmol* 1998; **82**:986.
- 26 Weinreb RN. Assessment of optic disc topography for diagnosing and monitoring glaucoma. *Arch Ophthalmol* 1998; **116**:1229-31.
- 27 The Advanced Glaucoma Intervention Study Investigators. Advanced glaucoma intervention study. *Ophthalmology* 1994; **101**:1445-55.



Slope analysis of the optic disc in eyes with ocular hypertension and early normal tension glaucoma by confocal scanning laser ophthalmoscope

J Dong and E Chihara

Br J Ophthalmol 2001 85: 56-62

doi: 10.1136/bjo.85.1.56

Updated information and services can be found at:

<http://bjo.bmj.com/content/85/1/56.full.html>

References

These include:

This article cites 23 articles, 11 of which can be accessed free at:

<http://bjo.bmj.com/content/85/1/56.full.html#ref-list-1>

Article cited in:

<http://bjo.bmj.com/content/85/1/56.full.html#related-urls>

Email alerting service

Receive free email alerts when new articles cite this article. Sign up in the box at the top right corner of the online article.

Topic Collections

Articles on similar topics can be found in the following collections

[Angle](#) (791 articles)

[Glaucoma](#) (779 articles)

[Intraocular pressure](#) (789 articles)

Notes

To request permissions go to:

<http://group.bmj.com/group/rights-licensing/permissions>

To order reprints go to:

<http://journals.bmj.com/cgi/reprintform>

To subscribe to BMJ go to:

<http://group.bmj.com/subscribe/>