

Chorioretinal post-transplant lymphoproliferative disorder induced by the Epstein-Barr virus

P F Demols, P M Cochaux, T Velu, L Caspers-Velu

Abstract

Background—The Epstein-Barr virus (EBV) is responsible for the lymphoproliferative disorders observed in transplanted patients.

Methods—The case history is described of a 59 year old man with a chorioretinal lesion who had received a single lung transplant and was on immunosuppressive treatment. Immunoglobulin gene rearrangement and EBV detection by polymerase chain reaction (PCR) with semiquantification were used on the vitreous material.

Results—A proliferation of B lymphocytes with a monoclonal subpopulation was found by PCR on the vitreous sample. The large amounts of EBV genomes found in the vitreous suggest that EBV was the cause of the lymphoproliferation. Healing of the lesion was achieved by a decrease in immunosuppressive treatment and the use of nucleotide analogues.

Conclusion—The diagnosis of ocular post-transplant lymphoproliferative disorder (PTLD) can be made by PCR on vitreous material. Early diagnosis and treatment can lead to regression of limited monoclonal lesions.

(Br J Ophthalmol 2001;85:93-95)

The use of immunosuppressive agents following transplantation has already saved many lives, but the incidence of neoplasms has increased.¹ Lymphomas which occur in allograft recipients are mainly of B cell origin. Post-transplant lymphoproliferative disorders (PTLD) include a number of diseases ranging from infectious mononucleosis-like syndrome to malignant lymphoma.

We report a case of chorioretinal PTLD in whom large amounts of Epstein-Barr virus (EBV) DNA were detected by semiquantitative polymerase chain reaction (PCR) in the vitreous.

Case report

A 59 year old man received a single lung transplant for emphysema in December 1992 and was treated with immunosuppressive drugs (cyclosporin, azathioprine, and methylprednisolone). He had already needed treatment for *Pneumocystis carinii* and cytomegalovirus (CMV) lung infections, relapsing herpes zoster, and episodes of positive CMV antigenaemia.

In November 1994 the patient presented to our clinic complaining of floaters and decreased vision in the right eye for 2 days. Because of a recent relapse of CMV antigenaemia, the immunosuppressive treatment had

recently been decreased (cyclosporin from 300 mg to 250 mg daily, azathioprine 50 mg daily was discontinued, and methylprednisolone remained at 8 mg daily). Intravenous ganciclovir had been administered (350 mg/day 5 days a week) for 5 days. At first examination visual acuity was 20/35 in the right eye and 20/15 in the left. There was 1+ anterior cells, a 1+ vitreous haze, and a thick homogeneous yellow-white chorioretinal lesion along the superior temporal arcade extending to the posterior pole with an arteriovenous thrombosis of the superotemporal branch with minimal haemorrhages.

The diagnosis was thought to be atypical CMV retinitis or toxoplasmic retinochoroiditis and treatment with intravenous ganciclovir was continued. Two days later the dose of cyclosporin was further reduced. After 2 weeks the chorioretinal lesion extended to the macular region with the appearance of a few haemorrhages and aggravation of the vitreous haze (Fig 1A). Many granulomatous keratic precipitates appeared and the visual acuity dropped to finger counting. The first molecular study by PCR did not reveal CMV, herpes simplex virus (HSV), varicella zoster virus (VZV), or toxoplasmosis in the vitreous. A weak PCR positivity was present for *Pneumocystis carinii* in the vitreous but the clear positivity in the serum suggested contamination of the vitreous with blood during vitrectomy. As expected, a trial of oral trimethoprim and sulfamethoxazole did not improve the ocular lesion and confirmed this hypothesis. Semi-quantitative PCR revealed the presence of a large number of EBV genomes in the vitreous material (Fig 2).

Polymerase chain reaction of the EBV genome was performed using TC60 and TC61 primers derived, as previously described,² from the Bam HI W region, giving an amplified fragment of 122 base pairs. The PCR mixture contained 200 µM dNTP, 2.5 mM MgCl₂, 50 mM KCl, 10 mM TRIS HCl (pH 8.3), 0.1 mg/ml gelatin, 2.5 U Taq DNA polymerase, and 1 µg of each primer for a total reaction volume of 50 µl. As a control for gene amplification, primers derived from the phenylalanine hydroxylase gene, giving an amplified product of 260 base pairs, were used (5A and 5B).³ Reactions were incubated in a Biometra Trioblock cyler for 35 cycles (48 seconds at 93°C, 48 seconds at 53°C, 90 seconds at 72°C; last extension cycle of 6 minutes). The PCR products were analysed by agarose gel stained with ethidium bromide and by transfer and hybridisation with a ³²P labelled probe (TC62 probe specific for the EBV Bam HI W fragment).² The semiquantification was assessed by comparison of the sample PCR

Department of
Ophthalmology,
Erasmus University
Hospital, Université
Libre de Bruxelles,
Brussels, Belgium
P F Demols

Department of
Medical Genetics,
Erasmus University
Hospital, Université
Libre de Bruxelles,
Brussels, Belgium
P M Cochaux
T Velu

Department of
Ophthalmology, St
Pierre and Brugmann
University Hospitals
L Caspers-Velu

Correspondence to:
Dr P F Demols, Department
of Ophthalmology, Erasme
Hospital, 808 Route de
Lennik, 1070 Brussels,
Belgium
paul.demols@euronet.be

Accepted 27 June 2000

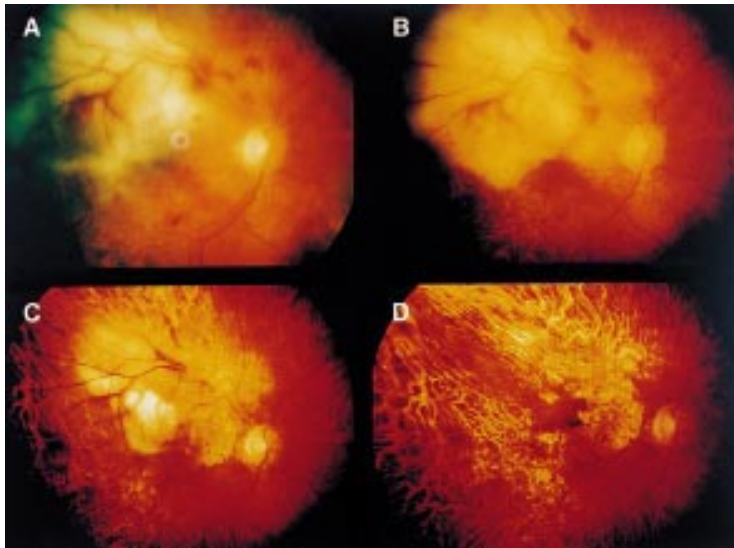


Figure 1 (A) Chorioretinal yellow-white lesion extending towards the macula with arterial and venous thrombosis of the superotemporal arcade. (B-D) Progressive healing of the chorioretina over 6 months. (B) January 1995, (C) March 1995, (D) July 1995.

product with amplified dilutions of decreasing amounts of EBV control plasmid DNA mixed with DNA from uninfected cells. The plasmid pBA-W containing the Bam HI fragment from the B95-8 EBV genome was kindly provided by A Sergent (CNRS, Lyons, France).⁴

Further molecular study with PCR revealed rearrangement of a clonal immunoglobulin

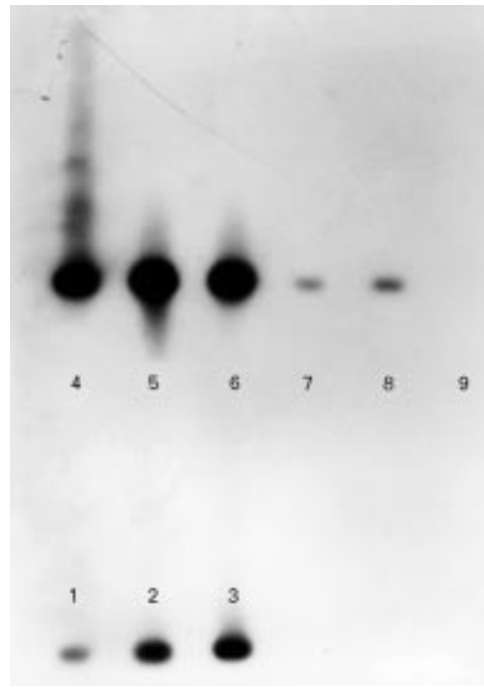


Figure 2 Semiquantitative EBV PCR. Lanes 1-4: control EBV plasmid dilutions 10^9 , 10^8 , 10^7 , and 10^6 (0.1, 1, 10, and 100 EBV genomes/1000 cells, respectively); lanes 5 and 6: vitreous material; lane 7: blood sample from the same patient; lanes 8 and 9: blood samples from another patient, the second one being EBV negative. The amount of EBV genomes is estimated to be lower than 10^9 in the blood and higher than 10^6 in the vitreous. The amount of EBV genomes in the vitreous material appears to be at least 1000 times higher than in the blood, and is probably largely underestimated since the ethidium bromide staining of the control amplification (see Methods) showed that there were only a few cells in the vitreous material compared with the blood sample.

gene at the heavy chain locus, showing that a monoclonal cell population had emerged among the EBV positive proliferating B lymphocytes.

Serological tests showed an increase in the EBV viral capsid antigen (VCA) antibodies (IgG 1/320→1/1280) between August and October 1994 which strongly supported the diagnosis of chorioretinal EBV induced monoclonal PTLD.

EBV genomes decreased in the vitreous fluid with intravitreal administration of ganciclovir and foscavir in association with intravenous ganciclovir, although the lesion continued to grow. This antiviral treatment was then replaced with intravenous aciclovir (1 g twice daily) for 3 weeks from 26 December 1994 followed by oral administration (800 mg three times daily) because of chronic renal failure. This led to clinical improvement of the lesion until total scarring was achieved in June 1995, 6 months after the start of treatment (Fig 1B-D). There has been no ocular recurrence to date.

Discussion

EBV induced lymphoproliferative disorders are observed in both iatrogenically and congenitally immunosuppressed patients.⁵ The discovery of significant amounts of EBV genomes in the immunodeficient tissues of patients with lymphoproliferative disorders suggests that EBV is the responsible agent.

The pathogenesis of PTLD is complex and multifactorial. It is caused by a breakdown in the balance between B cell stimulation and the anti-EBV immune response. B lymphocyte proliferation is induced by chronic antigenic stimulation from the allograft, by the presence of an oncogene in the genome of the EBV, and by the degree of immunosuppression.¹⁻⁵⁻⁷ When there is an imbalance, polyclonal B lymphocyte proliferation occurs that may develop into an oligoclonal or monoclonal lymphoma.⁵⁻⁸⁻⁹ Some clones are susceptible to genetic modifications—for example, oncogene or tumour suppressor gene alterations which result in the development of a true lymphoma.⁹

The clonal state is not the only criterion for malignancy. In the case presented here, a monoclonal state occurred with no malignancy. The major risk factors for developing PTLD are the intensity, type, and duration of immunosuppressive therapy.^{2,3} Non-clonal PTLD and a subpopulation of clonal PTLD regress when the dose of immunosuppressive treatment is decreased, with or without aciclovir.^{5,6}

Clinical, morphological, immunological, and cytogenetic analysis enables the therapeutic response to be predicted.^{5,6,10} Patients with stage I PTLD (lymphoid hyperplasia) respond to treatment with aciclovir, often without a reduction in the dose of immunosuppressive treatment, thus avoiding any risk of graft rejection.^{5,10} At the other extreme, stage III PTLD (true lymphoma) progresses in spite of a decrease in immunosuppressive treatment, with or without aciclovir.^{5,10} These lesions require standard antineoplastic treatment (chemotherapy, radiotherapy, surgery) and the discontinuation of immunosuppressive drugs if

possible.^{5 10} Aciclovir has been shown to be ineffective when the tumour is monoclonal, probably because it consists of latent infected B cells which no longer depend on EBV replication to proliferate but have acquired a malignant autonomous growth potential.^{5 10} Nevertheless, an early clonal subpopulation (stage II PTLD) may respond to aciclovir treatment associated with a reduction in immunosuppression if the autonomous growth potential has not yet been reached.¹⁰

Some cases of chorioretinitis with serologically determined acute EBV infection have been observed,¹¹⁻¹³ but without solid evidence of their cause. A few cases of intraocular lymphoproliferation associated with AIDS have been reported, and EBV has recently been found by in situ hybridisation in a retinal biopsy specimen of an HIV positive patient with multifocal chorioretinitis.¹⁴ EBV has been suspected but its presence has not been confirmed in another four cases of intraocular lymphoproliferation following transplantation.¹⁵⁻¹⁸

The case reported here is the first documented case of chorioretinal PTLD in whom a large number of EBV genome copies have been found in vitreous cells by PCR semi-quantification associated with monoclonal proliferation. This case also confirms that a monoclonal proliferation can regress with decreased immunosuppressive therapy associated with nucleotide analogues. It also shows that the diagnosis of intraocular EBV induced PTLD can be made from the vitreous alone using a PCR amplification technique which permits semi-quantification of the virus.

Early detection and treatment are essential for the regression of limited monoclonal lesions. Identification of patients who are at high risk for this kind of complication might lead to a decrease in morbidity and mortality in this population.

- 1 Penn I. Cancers complicating organ transplantation. *N Engl J Med* 1990;**323**:1767-9.
- 2 Saito I, Serenius B, Compton T, et al. Detection of Epstein-Barr virus DNA by polymerase chain reaction in blood and tissue biopsies from patients with Sjogren's syndrome. *J Exp Med* 1989;**169**:2191-8.
- 3 Okano Y, Wang T, Eisensmith RC, et al. Missense mutations associated with RFLP haplotypes 1 and 4 of the human phenylalanine hydroxylase gene. *Am J Hum Genet* 1990;**46**:18-25.
- 4 Jones MD, Griffin BE. Clustered repeat sequences in the genome of Epstein-Barr virus. *Nucleic Acids Res* 1983;**11**:3919-37.
- 5 Hanto DW, Gajl-Peczalska KJ, Frizzera G, et al. Epstein-Barr virus (EBV) induced polyclonal and monoclonal B-cell lymphoproliferative diseases occurring after renal transplantation. *Ann Surg* 1983;**198**:356-69.
- 6 Nalesnik MA, Jaffe R, Starzl TE, et al. The pathology of posttransplant lymphoproliferative disorders occurring in the setting of cyclosporine A-prednisone immunosuppression. *Am J Pathol* 1988;**133**:173-92.
- 7 Cockfield SM, Preiksaitis JK, Jewell LD, et al. Post-transplant lymphoproliferative disorder in renal allograft recipients. *Transplantation* 1993;**56**:88-96.
- 8 Cleary ML, Warnke R, Sklar J. Monoclonality of lymphoproliferative lesions in cardiac-transplant recipients. *N Engl J Med* 1984;**310**:477-82.
- 9 Knowles DM, Cesarman E, Chadburn A, et al. Correlative morphologic and molecular genetic analysis demonstrates three distinct categories of posttransplantation lymphoproliferative disorders. *Blood* 1995;**85**:552-65.
- 10 Hanto DW, Frizzera G, Gajl-Peczalska KJ, et al. Acyclovir therapy of Epstein-Barr virus-induced posttransplant lymphoproliferative diseases. *Transplant Proc* 1985;**17**:89-92.
- 11 Bonamour G, Pommier ML. Manifestations chorioretiniennes dans la mononucléose infectieuse. *Bull Soc Ophthalmol Fr* 1968;**68**:52-4.
- 12 Kelly SP, Rosenthal AR, Nicholson KG, et al. Retinochoroiditis in acute Epstein-Barr virus infection. *Br J Ophthalmol* 1989;**73**:1002-3.
- 13 Tiedeman JS. Epstein-Barr viral antibodies in multifocal choroiditis and panuveitis. *Am J Ophthalmol* 1987;**103**:659-63.
- 14 Mitra RA, Pulido JS, Hanson GA, et al. Primary ocular Epstein-Barr virus-associated non-Hodgkin's lymphoma in a patient with AIDS. *Retina* 1999;**19**:45-50.
- 15 Johnson BL. Intraocular and central nervous system lymphoma in a cardiac transplant recipient. *Ophthalmology* 1992;**99**:987-92.
- 16 Khetarpal S, Kirkby GR, Neuberger JM, et al. Intraocular lymphoma after liver transplantation. *Am J Ophthalmol* 1993;**116**:507-8.
- 17 Robinson R, Murray PI, Willshaw HE, et al. Primary ocular posttransplant lymphoproliferative disease. *J Pediatr Ophthalmol Strabismus* 1995;**32**:393-4.
- 18 Ziemianski MC, Godfrey WA, Lee KY, et al. Lymphoma of the vitreous associated with renal transplantation and immunosuppressive therapy. *Ophthalmology* 1980;**87**:596-601.



Chorioretinal post-transplant lymphoproliferative disorder induced by the Epstein-Barr virus

P F Demols, P M Cochaux, T Velu, et al.

Br J Ophthalmol 2001 85: 93-95

doi: 10.1136/bjo.85.1.93

Updated information and services can be found at:

<http://bjo.bmj.com/content/85/1/93.full.html>

These include:

References

This article cites 18 articles, 4 of which can be accessed free at:

<http://bjo.bmj.com/content/85/1/93.full.html#ref-list-1>

Article cited in:

<http://bjo.bmj.com/content/85/1/93.full.html#related-urls>

Email alerting service

Receive free email alerts when new articles cite this article. Sign up in the box at the top right corner of the online article.

Notes

To request permissions go to:

<http://group.bmj.com/group/rights-licensing/permissions>

To order reprints go to:

<http://journals.bmj.com/cgi/reprintform>

To subscribe to BMJ go to:

<http://group.bmj.com/subscribe/>