

Intravitreal vancomycin and gentamicin concentrations in patients with postoperative endophthalmitis

Ivan M Gan, Jaap T van Dissel, W Houdijn Beekhuis, Wouter Swart, Jan C van Meurs

Abstract

Background/aims—To study the intravitreal antibiotic concentrations and the efficacy of an intravitreal dosing regimen to treat patients with postoperative bacterial endophthalmitis. This regimen, based on pharmacokinetic/pharmacodynamic considerations, relies on a repeat antibiotic injection of a lower dose than is generally used.

Methods—In consecutive patients with suspected postoperative endophthalmitis a vitreous biopsy for bacterial culture was taken before 0.2 mg vancomycin and 0.05 mg gentamicin were injected intravitreally. After 3 or 4 days a second biopsy was taken for bacteriological culture and to measure intravitreal vancomycin and gentamicin concentrations, followed by a repeat injection of 0.2 mg vancomycin.

Results—17 patients entered the study. In 11 patients the initial bacterial culture was positive, predominantly coagulase negative staphylococci. All second vitreous biopsies were sterile. Intravitreal vancomycin levels varied between 2.6 and 18.0 µg/ml (mean 10.3 (SD 4.1) µg/ml) after 3 days and between 3.1 and 16.6 µg/ml (mean 7.5 (6.2) µg/ml) after 4 days which is well above the minimal inhibitory concentration for most micro-organisms. Concentrations of intravitreal gentamicin varied between 0.90 and 3.3 µg/ml (mean 1.6 (0.72) µg/ml) after 3 days and between 1.2 and 2.6 µg/ml (mean 1.9 (0.99) µg/ml) after 4 days.

Conclusion—This dosing regimen resulted both in adequate intravitreal vancomycin and gentamicin levels for over a week as well as in negative second cultures. This study also provides new information on intravitreal vancomycin and gentamicin concentration over time in patients with postoperative endophthalmitis.

(Br J Ophthalmol 2001;85:1289-1293)

Bacterial endophthalmitis is a severe complication of intraocular surgery that may rapidly cause permanent visual loss. Therefore, when confronted with a possible postoperative infection of the eye, timely diagnostic and empirical therapeutic decisions should be made by medical history taking and a focused examination without the aid of the results of laboratory and culture results. If it is likely that the symptoms

and signs are due to bacterial infection, prompt antimicrobial treatment is indicated.

In empirical therapy, the activity spectrum of the antibiotic should cover all likely causative micro-organisms. Other important parameters directing the choice and dosing regimen of antibiotics in endophthalmitis include the ability to achieve effective concentrations of the drug inside the eye, especially the vitreous, and the toxicity of the drug for retinal structures. The vast majority of postoperative eye infections are caused by Gram positive bacteria such as coagulase negative staphylococci, *S aureus*, and streptococci.¹⁻³ Awaiting culture results and susceptibility testing, the methicillin resistance of many strains of staphylococci make glycopeptides such as vancomycin the antibiotic of choice.¹⁻³⁻⁶ As the penetration of this drug into non-vitreotomised, inflamed eyes after intravenous administration is unreliable, direct intravitreal injection of vancomycin is recommended.⁷⁻⁸ The efficacy of such an empirical antibiotic regimen of vancomycin injected intravitreally was confirmed in the Endophthalmitis Vitrectomy Study.¹

Thus, the intravitreal injection of vancomycin, supplemented with a second antibiotic such as ceftazidime or an aminoglycoside covering for rare Gram negative bacteria, has become the standard treatment in postoperative endophthalmitis. The commonly recommended 1 mg vancomycin dose, however, is extremely high as it results in vitreous concentrations many times higher than accepted serum and fluid concentrations of this drug in severe extraocular infections such as endocarditis and meningitis. Moreover, in some case reports where vancomycin is used in combination with amikacin retinotoxicity cannot be ruled out.⁹⁻¹⁰

When the antimicrobial effect of an antibiotic depends mainly on how long the concentration exceeds the minimal inhibitory concentration (MIC) rather than how high a dose is given, as is the case for vancomycin, efficacious therapy requires more frequent rather than higher dosages.¹¹⁻¹² To ensure prolonged exposure of micro-organisms to vancomycin at a concentration well above the MIC but without the need for very high and potential toxic dosing, we decided on a treatment protocol for suspected postoperative endophthalmitis consisting of an intravitreal injection of vancomycin at a dose of 0.2 mg, to be repeated once after 3-4 days. Initial treatment included an intravitreal injection of gentamicin to cover for the rare occurrence of

The Rotterdam Eye Hospital
I M Gan
W H Beekhuis
J C van Meurs

Leiden University Medical Center, Department of Infectious Diseases
J T van Dissel

Leiden University Medical Center, Department of Ophthalmology
W Swart

Correspondence to:
Dr Jan C van Meurs, The Rotterdam Eye Hospital, PO Box 70030, 3000 LM Rotterdam, Netherlands
janvanmeurs@cs.com

Accepted for publication
23 May 2001

Table 1 Patient characteristics

Patient No	Male/female	Age (years)	Visual acuity	
			At presentation	After 3 months
1	F	75	Light perception	Light perception
2	F	86	Counting fingers	0.25
3	F	75	Light perception	Counting fingers
4	F	69	Counting fingers	1.0
5	F	83	Light perception	Light perception
6	M	52	Hand movements	1.0
7	M	73	Light perception	Counting fingers
8	V	82	Light perception	Counting fingers
9	V	77	Hand movements	0.5
10	V	74	Counting fingers	0.9
11	M	83	Hand movements	0.8
12	M	82	Light perception	0.15
13	F	60	0.5	1.0
14	F	61	0.4	0.6
15	M	78	Light perception	Counting fingers
16	F	84	Counting fingers	0.5
17	M	47	Hand movements	0.4

Gram negative bacteria. Specimens of the vitreous for Gram stain and culture were collected before the start of antibiotic therapy and at the time of the repeat injection. This enabled us to prospectively measure concentrations of vancomycin and gentamicin in the vitreous specimens taken at the time of the repeat injection to investigate whether antibiotic levels were adequate and to obtain new data on the vitreous concentration of these antibiotics over time.

Materials and methods

The study was performed at the Rotterdam Eye Hospital, a secondary and tertiary referral eye hospital. Consecutive patients who had been referred to the emergency department because of suspected postoperative endophthalmitis were enrolled over a 10 month period. Symptoms suggestive of endophthalmitis included a painful and/or red eye, severe decrease of vision and aqueous cells and flare with or without hypopyon within 6 weeks after cataract surgery. According to the guidelines of the Endophthalmitis Vitrectomy Study¹ only a vitreous biopsy was performed with a vitrectome in patients with better than light perception vision. A core vitrectomy with anterior chamber infusion was performed in patients who presented with light perception only. Undiluted vitreous material was collected for Gram staining and culture before the start

of antibiotic therapy; the material was cultured aerobically and anaerobically. At the end of the procedure all patients received an intravitreal injection of 0.2 mg vancomycin in 0.1 ml phosphate buffered saline and 0.05 mg gentamicin in 0.1 ml phosphate buffered saline.

A second intravitreal injection of 0.2 mg vancomycin was repeated after 3 or 4 days, preceded by a vitreous biopsy with the vitrectome for a repeat bacterial culture and measurements of intravitreal vancomycin levels. Intravitreal gentamicin levels were also measured when sufficient material had been obtained.

If the Gram staining or the subsequent culture of the first biopsy material yielded Gram negative bacteria, 1 mg ceftazidime was immediately injected intravitreally followed by continuous intravenous infusion of ceftazidime of 6 g per day.

Vitreous levels of vancomycin and gentamicin were determined by fluorescence polarisation immuno assay (AxSYM, Abbott Laboratories, Abbott Park, IL, USA).

The study protocol was approved by the hospital's medical ethics committee and all subjects gave permission for the vitreous sampling for assay of antibiotic concentration and bacterial culture.

Results

PATIENT CHARACTERISTICS (TABLE 1)

Seventeen consecutive patients entered the study. The median age was 73 years (range 47–86 years) and there were six men and 11 women. Length of follow up was 3 months.

Seven patients presented with light perception only vision and underwent a core vitrectomy. In 10 patients with better than light perception only a vitreous biopsy was performed with a vitrectome. All patients were treated as intended according to the treatment protocol.

BACTERIOLOGICAL FINDINGS (TABLE 2)

In all patients, vitreous material for Gram stain and culture was obtained before the administration of antibiotics. The Gram staining of the specimen provided preliminary identification of the causative micro-organism in six cases; in all of these, the staining revealed Gram positive cocci. In 11 out of 17 vitreous specimens

Table 2 Bacteriological findings

Patient No	Vancomycin levels (µg/ml)	Gentamicin levels (µg/ml)	Time between drug administration and measurement (hours)	Gram stain first biopsy	Bacterial culture	
					First biopsy	Second biopsy
1	2.6	0.9	63	Gram positive cocci	<i>S epidermidis</i>	Sterile
2	12.0	1.4	66	No micro-organisms	Sterile	Sterile
3	10.8	—	68	Gram positive cocci	<i>S epidermidis</i>	Sterile
4	18.0	3.3	68	No micro-organisms	<i>S epidermidis</i>	Sterile
5	8.2	1.0	69	No micro-organisms	<i>Streptococcus sanguis</i>	Sterile
6	12.0	1.2	69	Gram positive cocci	<i>S epidermidis</i>	Sterile
7	15.5	—	71	No micro-organisms	Sterile	Sterile
8	6.3	1.9	71	Gram positive cocci	<i>S epidermidis</i>	Sterile
9	9.0	1.4	71	No micro-organisms	Sterile	Sterile
10	13.3	1.8	71	No micro-organisms	<i>S epidermidis</i>	Sterile
11	8.9	1.4	72	No micro-organisms	<i>S epidermidis</i>	Sterile
12	6.8	1.0	72	No micro-organisms	Sterile	Sterile
13	10.1	2.4	72	No micro-organisms	Sterile	Sterile
14	5.8	1.2	90	No micro-organisms	<i>S aureus</i>	Sterile
15	3.1	—	90	Gram positive cocci	<i>Streptococcus mitis</i>	Sterile
16	16.6	2.6	92	Gram positive cocci	<i>S epidermidis</i>	Sterile
17	4.6	—	93	No micro-organisms	Sterile	Sterile

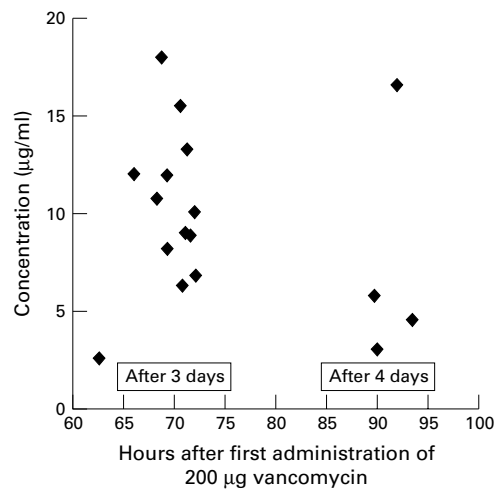


Figure 1 Intravitreal vancomycin concentrations.

(65%), Gram positive bacteria were cultured, predominantly coagulase negative staphylococci (73%), whereas in six specimens no bacteria were cultured. All cultured micro-organisms were susceptible to vancomycin.

In none of the cultures were Gram negative micro-organisms isolated.

After 3 or 4 days a repeat vitreous specimen was collected for culture in all patients. Gram staining of the specimens failed to reveal micro-organisms nor were any of the cultures positive.

CONCENTRATIONS OF VANCOMYCIN AND GENTAMICIN

Vancomycin levels (Fig 1)

In all 17 patients intravitreal vancomycin concentrations were measured. In 13 eyes the repeat biopsy was performed after 3 days (mean 70 (SD 2.7) hours) and in four eyes after 4 days (mean 91 (1.7) hours). Vancomycin concentrations varied between 2.6 and 18.0 µg/ml (mean 10.3 (4.1) µg/ml) after 3 days and between 3.1 and 16.6 µg/ml (mean 7.5 (6.2) µg/ml) after 4 days.

Gentamicin levels (Fig 2)

Measurements of intravitreal gentamicin levels were performed in 13 patients. In 11 eyes the second biopsy was performed after 3 days

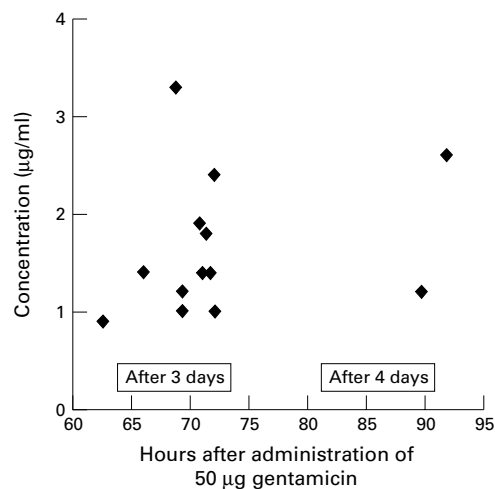


Figure 2 Intravitreal gentamicin concentrations.

(mean 70 (2.9) hours) and in two eyes after 4 days (mean 90 (1.5) hours). Concentrations varied between 0.90 and 3.3 µg/ml (mean 1.6 (0.72) µg/ml) after 3 days and between 1.2 and 2.6 µg/ml (mean 1.9 (0.99) µg/ml) after 4 days.

Discussion

Most cases of postoperative endophthalmitis are caused by Gram positive micro-organisms.¹⁻³ Vancomycin is therefore recommended as a first choice for initial therapy of suspected postoperative bacterial endophthalmitis.^{1-3,6} The present study demonstrates that vancomycin given at the dose of 0.2 mg intravitreally provides adequate empirical antibiotic coverage in postoperative endophthalmitis caused by Gram positive bacteria, because it ensures the prolonged and continuous exposure of the micro-organisms to the antibiotic at a concentration well above the MIC for the initial 3-4 days. At that time a single repeat intravitreal injection of vancomycin will maintain the concentration of the antibiotic well above the MIC for at least another 4 days. The antimicrobial efficacy of the dosing regimen was further confirmed by the finding that in all of the 11 cases in which bacteria were cultured from vitreous specimens at presentation, the repeat vitreous specimen failed to yield bacterial growth.

Many ophthalmologists use a single dose of 1 mg intravitreal vancomycin to treat postoperative endophthalmitis following the recommendations of the Endophthalmitis Vitrectomy Study.¹ The antimicrobial effect of glycopeptide antibiotics such as vancomycin depends on the length of time its concentration is maintained above the MIC.^{11,12} Thus, dosing strategies should optimise the duration of drug exposure to concentrations above the MIC, rather than to aim at higher peak levels.^{9,10} In this respect, adequate and safe antibiotic levels can be better achieved by more frequent rather than higher dosages. For vancomycin there are valid concerns not to dose higher than necessary. The commonly recommended dose of 1 mg vancomycin is high because it results in a vitreous concentration many times greater than accepted serum and cerebrospinal fluid concentrations in severe extraocular infections such as endocarditis and meningitis. In these infections, for reasons of toxicity, serum or fluid concentrations of vancomycin are carefully kept between 5 and 20 µg/ml. These concentrations are of proved clinical efficacy and are about 10-fold higher than the MIC for most Gram positive micro-organisms (MIC₉₀ equal or less than 1-5 µg/ml).^{11,12} The intravitreal injection of 1 mg of vancomycin should result in a peak concentration of over 200-250 µg/ml in the vitreous and superficial retinal structures. Given the time dependent pharmacodynamic activity of vancomycin, with no further gain in antimicrobial activity at MIC above 5-10-fold,^{11,12} intravitreal dosing of vancomycin at 50-200-fold of the MICs of the relevant micro-organisms does not add to its antimicrobial efficacy but may increase the chance of retinal toxicity. In fact, such concentrations of vancomycin reached inadvertently in the

blood (for example, above 100 µg/ml) are generally considered an indication for immediate dialysis and even exchange transfusion, to avoid ototoxicity and nephrotoxicity.¹³⁻¹⁶ Though the rabbit eye apparently is not damaged by vancomycin injected into the vitreous at doses up to 2 mg, there is certainly concern for retinal toxicity at high concentrations of vancomycin injected into human eyes.^{9 10}

Although data have been published from animal studies concerning the half life determination and elimination route of intravitreal vancomycin,^{5 17-19} only one report of a series of four patients is available on intravitreal vancomycin concentrations over time in human eyes.⁷ Aguilar *et al* estimated an intravitreal vancomycin clearance with a half life of 25 hours in human phakic eyes based on experiments in rabbit eyes in which inflammation had no significant influence.¹⁷ Clearance in pseudophakic eyes with an intact posterior capsule is thought to be more similar to phakic rather than to aphakic eyes.⁵ Using these data and assuming the volume of the human vitreous cavity to be approximately 4 ml, we chose a dose regimen of 0.2 mg vancomycin and a same dose repeat injection after 3-4 days.

By way of contrast, the antimicrobial effect of aminoglycosides such as gentamicin depends on peak concentration at the site of infection—that is, their activity is “concentration” rather than “time” dependent.²⁰ If toxicity allows, these drugs should be given less frequently but at higher dosages.

Gentamicin has been widely used to treat bacterial endophthalmitis because of its effectiveness against Gram negative bacteria,²¹⁻²³ but because of reports of retinal toxicity in patients with intravitreal doses between 0.10 and 0.40 mg²⁴⁻²⁶ many institutes replaced gentamicin with other, presumably less toxic, agents. In our treatment protocol a lower dose of 0.05 mg gentamicin is added with the first intravitreal injection to cover the Gram negative organisms not sensitive to vancomycin. For this single use of intravitreal gentamicin our aim was to reach an adequate peak level for bacterial killing during the first 48 hours until Gram stain or culture results exclude a Gram negative organism. We estimated that a dose of 0.05 mg of gentamicin should be sufficient to reach an adequate peak level of approximately 12.5 µg/ml and a minimum therapeutic level of 4 µg/ml during the first 2 days.²⁷⁻³⁰ In the rare case of Gram negative endophthalmitis, we would immediately inject intravitreal ceftazidime in combination with intravenous ceftazidime. Furthermore, the synergistic antimicrobial activity of glycopeptides and aminoglycosides against Gram positive bacteria is a potential advantage in the treatment of postoperative endophthalmitis caused by these micro-organisms.⁵

In conclusion, our study demonstrates that we succeed in reaching adequate intravitreal antibiotic levels with our low dose regimen as shown by direct concentration measurements of vitreous samples and the sterile cultures

from all second biopsies. From these data, we can extrapolate that the commonly used 1 mg dose of vancomycin results in adequate antibiotic concentrations for over 1 week at the expense of a higher than necessary concentration during the first 5 days. The potential risk of retinotoxicity should then be weighed against the possible complications of a second intravitreal injection as in our regime.

Our series, however, is small and did not contain very virulent organisms. Therefore only further practice will show its clinical effectiveness in such patients. This study was important in obtaining precise information on vitreous vancomycin and gentamicin concentration over time in patients with postoperative endophthalmitis.

The authors would like to thank Adam Cohen, PhD, and Rik Schoemaker, MSc, of the Centre for Human Drug Research in Leiden and Gert Jan Platenkamp, MD, and Herman Naaktgeboren of the Regional Medical Microbiological Laboratory in Rotterdam for their assistance in providing and interpreting our laboratory results.

- 1 Endophthalmitis Vitrectomy Study Group. Results of the Endophthalmitis Vitrectomy Study. A randomized trial of immediate vitrectomy and of intravenous antibiotics for the treatment of postoperative bacterial endophthalmitis. *Arch Ophthalmol* 1995;113:1479-96.
- 2 Kattan HM, Flynn HW, Pflugfelder SC, et al. Nosocomial endophthalmitis survey: current incidence of infection after intraocular surgery. *Ophthalmology* 1991;98:227-38.
- 3 Han DP, Wisniewski SR, Wilson LA, et al. Spectrum and susceptibilities of microbiologic isolates in the Endophthalmitis Vitrectomy Study. *Am J Ophthalmol* 1996;122:1-17.
- 4 Smith MA, Sorenson JA, Lowy FD. Treatment of experimental methicillin-resistant staphylococcus epidermidis endophthalmitis with intravitreal vancomycin. *Ophthalmology* 1986;93:1328-35.
- 5 Pflugfelder SC, Hernandez E, Fliesler SJ, et al. Intravitreal vancomycin. Retinal toxicity, clearance, and interaction with gentamicin. *Arch Ophthalmol* 1987;105:831-7.
- 6 Flynn HW, Pulido JS, Pflugfelder SC. Endophthalmitis therapy: changing antibiotic sensitivity patterns and current therapeutic recommendations. *Arch Ophthalmol* 1991;109:175-6.
- 7 Ferencz JR, Assia EI, Diamantstein L, et al. Vancomycin concentration in the vitreous after intravenous and intravitreal administration for postoperative endophthalmitis. *Arch Ophthalmol* 1999;117:1023-7.
- 8 Meredith TA, Aguilar HE, Shaarawy A, et al. Vancomycin levels in the vitreous cavity after intravenous administration. *Am J Ophthalmol* 1995;119:774-8.
- 9 Piguat B, Chobaz C, Gounauer PA. Rétinopathie toxique sur injection intravitréenne d'Amikacine et Vancomycine. *Klin Monatsbl Augenheilkd* 1996;208:358-9.
- 10 Seawright AA, Bourke RD, Cooling RJ. Macula toxicity after intravitreal amikacin. *Aust NZ J Ophthalmol* 1996;24:143-6.
- 11 Craig WA. Pharmacokinetic/pharmacodynamic parameters: rationale for antibacterial dosing of mice and men. *Clin Infect Dis* 1998;26:1-12.
- 12 Levinson ME. Pharmacodynamics of antibacterial drugs. *Infect Dis Clin N Am* 2000;14:281-91.
- 13 Snavely SR, Hodges GR. The neurotoxicity of antibacterial agents. *Ann Intern Med* 1984;101:92-104.
- 14 Burkhart KK, Metcalf S, Shurnas E, et al. Exchange transfusion and multidose activated charcoal following vancomycin overdose. *Clin Toxicol* 1992;30:285-94.
- 15 Kucukguclu S, Tuncok Y, Ozkan H, et al. Multiple-dose activated charcoal in an accidental vancomycin overdose. *Clin Toxicol* 1996;34:83-6.
- 16 Panzarino VM, Feldstein TJ, Kashtan CE. Charcoal hemoperfusion in a child with vancomycin overdose and chronic renal failure. *Pediatr Nephrol* 1998;12:63-4.
- 17 Aguilar HE, Meredith TA, El-Massry A, et al. Vancomycin levels after intravitreal injection. Effects of inflammation and surgery. *Retina* 1995;15:428-32.
- 18 Coco RM, Lopez MI, Pastor JC, et al. Pharmacokinetics of intravitreal vancomycin in normal and infected rabbit eyes. *J Ocul Pharmacol Ther* 1998;14:555-63.
- 19 Park SS, Vallar RV, Hong CH, et al. Intravitreal dexamethasone effect on intravitreal vancomycin elimination in endophthalmitis. *Arch Ophthalmol* 1999;117:1058-62.
- 20 Gilbert DN. Aminoglycosides. In: Mandell GL, Bennett JE, Dolin R, eds. *Principles and practice of infectious diseases*. Edinburgh: Churchill Livingstone, 2000:307-36.

- 21 Baum J, Peyman GA, Barza M. Intravitreal administration of antibiotic in the treatment of bacterial endophthalmitis: III. Consensus. *Surv Ophthalmol* 1982;26:204-6.
- 22 Rowsey JJ, Newsom DL, Sexton DL, *et al*. Endophthalmitis. Current approaches. *Ophthalmology* 1982;89:1055-66.
- 23 Cottingham AJ, Forster RK. Vitrectomy in endophthalmitis: results of a study using vitrectomy, intraocular antibiotics, or a combination of both. *Arch Ophthalmol* 1976;94:2078-81.
- 24 Conway BP, Campochiaro PA. Macular infarction after endophthalmitis treated with vitrectomy and intravitreal gentamicin. *Arch Ophthalmol* 1986;104:367-71.
- 25 McDonald HR, Schatz H, Allen AW, *et al*. Retinal toxicity secondary to intraocular gentamicin injection. *Ophthalmology* 1986;93:871-8.
- 26 Campochiaro PA, Lim JJ. Aminoglycoside toxicity in the treatment of endophthalmitis. The Aminoglycoside Toxicity Study Group. *Arch Ophthalmol* 1994;112:48-53.
- 27 Peyman GA, May DR, Ericson ES, *et al*. Intraocular injection of gentamicin. Toxic effects and clearance. *Arch Ophthalmol* 1974;92:42-7.
- 28 Zachary IG, Forster RK. Experimental intravitreal gentamicin. *Am J Ophthalmol* 1976;82:604-11.
- 29 Ben-Jun J, Joyce DA, Cooper RL, *et al*. Pharmacokinetics of intravitreal injection. Assessment of a gentamicin model by ocular dialysis. *Invest Ophthalmol Vis Sci* 1989;30:1055-61.
- 30 Cobo LM, Forster RK. The clearance of intravitreal gentamicin. *Am J Ophthalmol* 1981;92:59-62.

Direct Access to Medline

Medline

Link to Medline from the homepage and get straight into the National Library of Medicine's premier bibliographic database. Medline allows you to search across 9 million records of bibliographic citations and author abstracts from approximately 3,900 current biomedical journals.

www.bjophthalmol.com



Intravitreal vancomycin and gentamicin concentrations in patients with postoperative endophthalmitis

Ivan M Gan, Jaap T van Dissel, W Houdijn Beekhuis, et al.

Br J Ophthalmol 2001 85: 1289-1293

doi: 10.1136/bjo.85.11.1289

Updated information and services can be found at:

<http://bjo.bmj.com/content/85/11/1289.full.html>

These include:

References

This article cites 27 articles, 10 of which can be accessed free at:

<http://bjo.bmj.com/content/85/11/1289.full.html#ref-list-1>

Article cited in:

<http://bjo.bmj.com/content/85/11/1289.full.html#related-urls>

Email alerting service

Receive free email alerts when new articles cite this article. Sign up in the box at the top right corner of the online article.

Topic Collections

Articles on similar topics can be found in the following collections

[Choroid](#) (434 articles)

[Eye \(globe\)](#) (538 articles)

Notes

To request permissions go to:

<http://group.bmj.com/group/rights-licensing/permissions>

To order reprints go to:

<http://journals.bmj.com/cgi/reprintform>

To subscribe to BMJ go to:

<http://group.bmj.com/subscribe/>