

Phacovitrectomy without prone posture for full thickness macular holes

Peter R Simcock, Sergio Scalia

Abstract

Aims—To investigate the role of phacovitrectomy surgery without prone posture for stage 2 and 3 macular holes.

Methods—A pilot study was performed on 20 patients (20 eyes) having phacoemulsification lens removal and vitrectomy surgery with 20% C₂F₆ tamponade. Patients were advised to avoid lying on their backs for 10 days following surgery but no other posturing instructions were given. Closure rates and improvement in visual acuity were compared with a group of historical controls in whom phacovitrectomy with gas tamponade and face down posturing was performed.

Results—Anatomical hole closure was noted in 18 of the 20 eyes (90%). 19 eyes (95%) showed an improvement of at least 0.3 logMAR units. This compares favourably with the postured group in which anatomical hole closure was noted in 11 of 13 eyes (85%) and nine of 13 eyes (69%) showed an improvement of at least 0.3 logMAR units.

Conclusion—Combined surgery facilitates the use of a large gas bubble. Sufficient tamponade of the hole occurs for closure without prone posturing. Combined surgery prevents patients posturing and returning for cataract surgery.

(*Br J Ophthalmol* 2001;85:1316–1319)

Full thickness macular holes are predominantly seen in elderly patients.¹ Surgery usually involves difficult and uncomfortable prone posturing. The period of prone posturing required for successful hole closure remains unknown. Posturing periods in the literature vary from 4 to 28 days.^{2–4} One pilot study suggested that prone posturing may not be needed.⁵ Combining vitrectomy surgery with cataract surgery facilitates the use of a large gas bubble which may be sufficient to tamponade the hole without prone posture. All phakic elderly patients having surgery for macular hole will develop or note progression of cataract following vitrectomy.^{6,7} The combined technique prevents the patient having to return for cataract surgery. We present the results of a pilot study in which combined surgery was performed without prone posturing and compared with a group of historical controls who underwent an identical surgical procedure with face down posturing.⁸

Methods

Local ethics committee approval was obtained for this study. Combined phacoemulsification lens removal and vitrectomy surgery was

performed in 20 consecutive patients with idiopathic full thickness macular holes. Only the first eye was included when both eyes of an individual were operated on within this study period. Preoperative evaluation included slit lamp biomicroscopy with a Goldmann macular contact lens and peripheral retinal evaluation with the binocular indirect ophthalmoscope. Staging of the holes was according to the Gass classification.⁹ All procedures were performed under general anaesthesia by the authors (PRS and SS). The lens was removed via a corneal wound. The capsulorrhexis size was slightly smaller than the diameter of the intraocular lens optic. No posterior capsule rupture or anterior capsule tear occurred during surgery. Three port pars plana vitrectomy was performed using a wide angle viewing system. The posterior vitreous face was detached by changing the vitreous cutter to aspiration mode only and applying a maximum of 250 mm Hg of aspiration on the posterior vitreous cortex near the disc. When the vitreous had detached from the posterior pole, suction and cutting were applied and the vitreous was detached and trimmed to the vitreous base. The retinal periphery was examined and laser treatment applied if tears were observed. A fluid/air exchange was performed with a 20 gauge flute needle and no attempt was made to aspirate fluid from the macular hole. The eye was softened immediately before lens implantation by switching off the air infusion then releasing air from the vitreous cavity by removing and quickly replacing the sclerostomy plug. This facilitated opening the capsular bag with viscoelastic as a result of the lack of posterior pressure from the gas. The corneal wound was enlarged and a 5.5 mm one piece PMMA intraocular lens implant was inserted into the capsular bag and dialled into position. Viscoelastic was removed from the anterior chamber by irrigation and aspiration with a Simcoe cannula and the cataract wound was secured with one 10/0 nylon suture. Five minutes were allowed to elapse following removal of the viscoelastic to enable residual vitreous cavity fluid to accumulate at the posterior pole. Fluid was then aspirated with the flute needle to ensure a complete air fill on the table. Fifty ml of 20% C₂F₆ gas was flushed through the vitreous cavity before closure of the sclerostomies. Subconjunctival antibiotic and steroid were given at the conclusion of surgery.

Patients were advised to avoid lying on their back for 10 days following surgery. No other posturing advice was given. Patients were included in the study if the vitreous cavity gas fill was greater than 80% on the second postoperative day. Patients were reviewed 2

West of England Eye Unit, Royal Devon and Exeter Hospital
P R Simcock
S Scalia

Correspondence to:
Peter Simcock, West of England Eye Unit, Royal Devon and Exeter Hospital (Wonford), Barrack Road, Exeter EX2 5DW, UK
psimcock@hotmail.com

Accepted for publication
25 April 2001

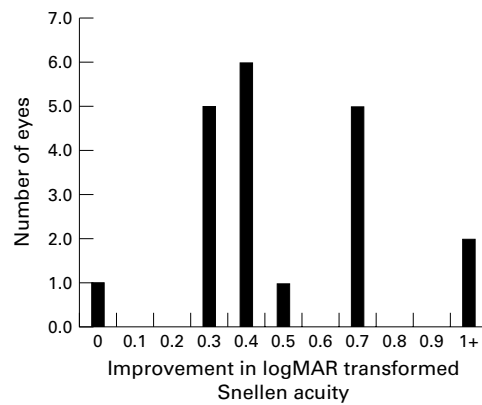


Figure 1 Improvement in visual acuity in the non-postured group.

weeks after surgery. Final review was performed 3 months following surgery. Visual acuities were recorded using Snellen charts and then converted to logMAR format.

Results

Fifteen patients were female and five male with a mean age of 71 years (range 59–77). The mean duration of macular hole before surgery was 13 months (range 3–48). All patients were noted to have mild cataract before surgery. Thirteen eyes had stage 2 holes, seven eyes stage 3 holes, and these findings were confirmed at vitrectomy. Eighteen of the 20 holes (90%) closed in the non-postured group compared with 11 of 13 holes (85%) in the postured historical control group. Hole closure

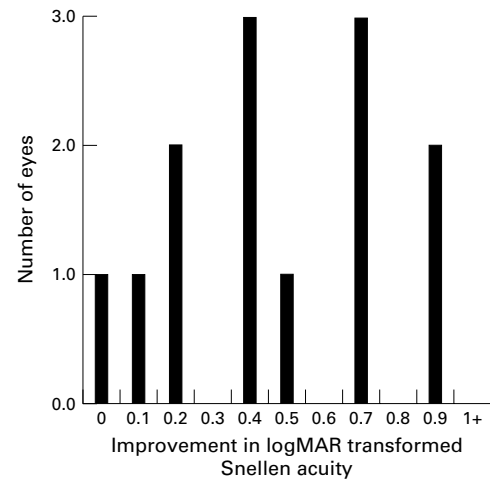


Figure 2 Improvement in visual acuity in the postured group.

was defined as flattening of the edges of the hole with no visible evidence of subretinal fluid. Nineteen of the 20 eyes (90%) showed an improvement of at least 0.3 logMAR units in the non-postured group (Fig 1) compared with nine of 13 eyes (69%) in the postured historical control group (Fig 2).

The mean logMAR transformed preoperative Snellen acuity in the non-postured group was 0.86 logMAR (SD 0.32) and the postoperative acuity 0.33 logMAR (0.24) (Table 1). The mean logMAR transformed preoperative Snellen acuity in the postured historical control group was 0.80 logMAR (0.22) and the postoperative acuity 0.31 logMAR (0.27) (Table 2).

Five eyes (25 %) developed inferior tears during vitreous separation. Tears were treated with endolaser or indirect laser photocoagulation and no scleral buckling was performed. All eyes had gas fills greater than 80% of the vitreous cavity by the second postoperative day. Three eyes (16%) developed raised intraocular pressures (between 25 and 30 mm Hg) in the immediate postoperative period. This responded to medical treatment and was due to residual viscoelastic in the anterior chamber and not to an overfill of gas in the vitreous cavity.

Six (32%) eyes developed significant posterior capsule opacification within 3 months of surgery requiring YAG capsulotomy. No eyes needed YAG capsulotomy within this time in the postured group. No photic retinopathy or cystoid macular oedema was seen clinically. No eyes to date have developed reopening of the hole or retinal detachment (follow up 3 months to 3 years).

Discussion

Macular hole surgery is a procedure performed by most vitreoretinal surgeons. Hole closure rates have improved from 58% in the first report by Kelly and Wendel¹⁰ to 100% in more recent articles.^{11 12} Vitrectomy with internal tamponade of the hole is regarded as being essential for successful hole closure. There is debate, however, about the type of tamponading agent and the need for and duration of

Table 1 Demographic and ocular data in the non-postured group

Patient No	Age	Sex	Duration of hole (months)	Stage of hole	Preop VA Snellen logMAR	Postop VA Snellen logMAR	Postop anatomy
1	59	F	6	3	6/36 + 0.78	6/9 + 0.08	Closed
2	61	F	48	3	1/60 + 1.78	6/18 + 0.48	Closed
3	61	F	10	2	6/18 + 0.48	6/9 + 0.08	Closed
4	66	M	6	3	6/60 + 1.00	6/24 + 0.60	Open but smaller
5	70	M	6	2	6/36 + 0.78	6/9 + 0.08	Closed
6	70	F	6	3	6/36 + 0.78	6/12 + 0.30	Closed
7	71	F	9	2	6/36 + 0.78	6/12 + 0.30	Closed
8	71	F	6	3	6/36 + 0.78	6/9 + 0.08	Closed
9	71	F	10	3	6/60 + 1.00	6/60 + 1.00	Open
10	71	F	12	2	6/36 + 0.78	6/18 + 0.48	Closed
11	72	F	6	2	6/36 + 0.78	6/18 + 0.48	Closed
12	73	F	12	2	6/60 + 1.00	6/12 + 0.30	Closed
13	74	F	14	2	6/60 + 1.00	6/12 + 0.30	Closed
14	74	F	6	2	6/36 + 0.78	6/12 + 0.30	Closed
15	74	M	24	2	6/36 + 0.78	6/12 + 0.30	Closed
16	74	M	60	3	6/36 + 0.78	6/18 + 0.48	Closed
17	75	F	6	2	6/12 + 0.30	6/6 0.00	Closed
18	75	M	3	2	6/36 + 0.78	6/18 + 0.48	Closed
19	76	F	7	2	6/24 + 0.60	6/9 + 0.08	Closed
20	77	F	3	2	2/60 + 1.48	6/18 + 0.48	Closed

Table 2 Demographic and ocular data in the postured group

Patient No	Age	Sex	Duration of hole (months)	Stage of hole	Preop VA Snellen logMAR	Postop VA Snellen logMAR	Postop anatomy
1	62	M	9	3	6/60 + 1.00	6/9 + 0.08	Closed
2	73	F	6	2	6/60 + 1.00	6/36 + 0.78	Closed
3	73	F	5	3	6/24 + 0.60	6/18 + 0.48	Closed
4	73	F	8	2	6/60 + 1.00	6/9 + 0.08	Closed
5	74	F	4	2	6/36 + 0.78	6/12 + 0.30	Closed
6	75	F	3	2	6/60 + 1.00	6/18 + 0.48	Closed
7	76	F	11	2	6/36 + 0.78	6/9 + 0.08	Closed
8	77	F	6	2	6/60 + 1.00	6/12 + 0.30	Closed
9	77	F	6	3	6/60 + 1.00	6/36 + 0.78	Open
10	78	F	8	2	6/18 + 0.48	6/18 + 0.48	Open
11	78	F	3	2	6/36 + 0.78	6/9 + 0.08	Closed
12	78	M	5	2	6/18 + 0.48	6/6 0.00	Closed
13	78	F	5	2	6/18 + 0.48	6/9 + 0.08	Closed

prone posturing. There is also no consensus on the need for internal limiting membrane peeling or adjuvant therapy.^{13 14}

Vitreotomy surgery in phakic elderly patients will result in the development of nuclear sclerotic lens opacity⁶ and large long acting gas fills in the vitreous cavity can induce a more immediate "gas" cataract. All phakic elderly patients undergoing macular hole surgery will therefore develop cataract. Combining the surgery has many advantages for the patient and for the surgeon.¹⁵⁻¹⁷ The patient does not have to return for a further surgical procedure and the surgeon does not have to perform an operation that can be technically difficult. This is due to the lack of vitreous support which may result in an unstable anterior chamber depth and variable pupil size during cataract surgery.¹⁸

Retinal detachment rates between 1% and 25% have been reported following macular hole surgery.¹⁹⁻²¹ Various techniques have been recommended to prevent retinal detachment including scleral buckling and prophylactic laser.^{22 23} Aphakia combined with a wide angle viewing system enables excellent visibility during posterior vitreous peeling and peripheral gel removal. If peripheral retinal tears occur during vitrectomy they can be easily recognised and treated.²⁴ Good visibility also facilitates performing a more complete vitrectomy and although aggressive trimming of the vitreous base was not performed, an attempt was made to detach the gel up to the vitreous base. This reduces the likelihood of further posterior vitreous separation in the postoperative period and may avoid postoperative tear and retinal detachment formation.²⁵ Intraoperative breaks were noted and treated with laser in nine of 33 eyes (27%) in both groups but no postoperative retinal detachments have occurred.

A large gas fill was present in the postoperative period in patients having combined surgery. When patients were upright on the slit lamp there appeared to be good gas tamponade in the macular region. Tornambe suggested in a pilot study that prone posturing may not be necessary and also combined cataract and vitrectomy surgery with the use of C₃F₈ tamponade. Macular holes close without posture when oil is used as a tamponading agent.^{26 27} A gas fill will create a greater tamponade on the macula compared with an equivalent oil fill because of its greater buoyancy.²⁸ Twenty per cent C₂F₆ gas was used as the tamponading agent and this resulted in vitreous cavity gas fills of 80% or greater in all patients.

Internal limiting membrane (ILM) peeling has been advocated to improve hole closure and recent studies show a closure rate of up to 100% by using this technique.^{2 13 29} Indocyanine green may facilitate ILM peeling³⁰ and if long term safety issues are addressed it may be that combined surgery with indocyanine green assisted ILM peeling, will be the preferred technique. Our present technique is a straightforward surgical procedure and can be adopted by most vitreoretinal surgeons if they also have

cataract surgery experience or work in combination with an anterior segment colleague.

Our technique involved placing a one piece PMMA IOL into the capsular bag in a gas filled eye. This was chosen as the preferred sequence at the beginning of the study as it resulted in good visibility up to and including the fluid/air exchange, it provided a rigid lens/capsule diaphragm and the lens was compatible with oil if it needed to be subsequently used. The technique of implant placement is straightforward provided posterior pressure is relieved as discussed in the methods section before implant placement. Surgeons new to this technique may find the air reflexes somewhat disconcerting on their first few attempts. It may be reasonable, however, to use a folding lens before performing the fluid-air exchange.

Early (within 3 months) posterior capsule opacification requiring YAG capsulotomy was noted in six eyes (32%) in the non-postured group. This may be due to the prolonged gas tamponade on the posterior capsule that occurs when prone posture is avoided. Routine posterior capsulotomy at the time of surgery may prevent the need for YAG capsulotomy but does have a slight risk of gas passing into the anterior chamber during or after surgery.

Cataract surgery following vitrectomy for full thickness macular holes may result in reopening of the hole³¹ and the development of cystoid macular oedema.³² Combined surgery negates the risk of the former and no patients in our study have had evidence of clinical cystoid macular oedema following surgery.

Hole closure rates and improvement in visual acuity were similar in both the postured and non-postured groups. These studies were on eyes with stage 2 and 3 macular holes of relatively short duration and therefore carried a more favourable prognosis than stage 4 holes of long duration. The number of eyes in the pilot study and historical control groups were small and therefore prone to possible sampling errors. The results however are encouraging and if reproducible in a larger series may persuade surgeons to adopt this convenient one stop approach to the treatment of full thickness macular holes.

- 1 Freeman W. Vitrectomy surgery for full-thickness macular holes. *Am J Ophthalmol* 1993;116:233-5.
- 2 Park DW, Sipperley Jo, Sneed SR, et al. Macular hole surgery with internal limiting membrane peeling and intravitreous air. *Ophthalmology* 1999;106:1397-8.
- 3 Ellis JD, Malik TY, Taubert MA, et al. Surgery for full-thickness macular holes with short duration prone posturing, result of a pilot study. *Eye* 2000;14:307-11.
- 4 Minihan M, Goggin M, Clearly PE. Surgical management of macular holes; results using gas tamponade alone, or in combination with autologous platelet concentrate, or transforming growth factor β 2. *Br J Ophthalmol* 1997;81:1073-9.
- 5 Tornambe PE, Poliner L, Grote K. Macular hole surgery without face-down positioning. *Retina* 1997;17:179-85.
- 6 Thompson JT, Glaser BM, Sajaarda RN, et al. Progression of nuclear sclerosis and long-term visual results of vitrectomy with transforming growth factor beta-2 for macular holes. *Am J Ophthalmol* 1995;119:48-54.
- 7 Lansing MB, Glaser BM, Liss H, et al. The effects of pars plana vitrectomy and transforming growth factor beta-2 without epiretinal membrane peeling on full-thickness macular holes. *Ophthalmology* 1993;100:868-72.
- 8 Simcock PR, Scalia S. Phaco-vitreotomy for full-thickness macular holes. *Acta Ophthalmol Scand* 2000;78:684-6.
- 9 Johnson RN, Gass JD. Idiopathic macular holes: observations, stage of formation, and implications for surgical intervention. *Ophthalmology* 1998;95:917-24.

- 10 Kelly NE, Wendel RT. Vitreous surgery for idiopathic macular holes: results of a pilot study. *Arch Ophthalmol* 1991;**109**:654-9.
- 11 Glaser BM, Michels RG, Kuppermann BD, *et al.* Transforming growth factor beta-2 for the treatment of full-thickness macular holes. A prospective randomised study. *Ophthalmology* 1992;**99**:1162-73.
- 12 Liggett PE, Slovik SA, Horio B, *et al.* Human autologous serum for the treatment of full-thickness macular holes. *Ophthalmology* 1995;**102**:1071-6.
- 13 Mester V, Kuhn F. Internal limiting membrane removal in the management of full-thickness macular holes. *Am J Ophthalmol* 2000;**129**:769-77.
- 14 Peyman G, Daun N, Greve M, *et al.* Surgical closure of macular hole using an absorbable macular plug. *Int Ophthalmol* 1997;**21**:81-97.
- 15 Grusha YO, Masket S, Miller KM. Phacoemulsification and lens implantation after pars plana vitrectomy. *Ophthalmology* 1998;**105**:287-94.
- 16 Miller JH Jr, Googe JM Jr, Hoskins JC. Combined macular hole and cataract surgery. *Am J Ophthalmol* 1997;**123**:705-7.
- 17 Kotecha AV, Sinclair SH, Gupta AK, *et al.* Pars plana vitrectomy for macular holes combined with cataract extraction and lens implantation. *Ophthalmic Surg Lasers* 2000;**31**:387-93.
- 18 Lacalle VD, Garate FJO, Alday NM, *et al.* Phacoemulsification cataract surgery in vitrectomized eyes. *J Cataract Refract Surg* 1998;**24**:806-9.
- 19 Tabandeh H, Chaudhry NA, Smiddy WE. Retinal detachment associated with macular hole surgery. *Retina* 1999;**19**:281-6.
- 20 Parks SS, Marcus DM, Duker JS, *et al.* Posterior segment complication after vitrectomy for macular hole. *Ophthalmology* 1995;**102**:775-81.
- 21 Banker AS, Freeman WR, Kim JW, *et al.* Vision-threatening complications of surgery for full-macular thickness macular holes. Vitrectomy for Macular Hole Study Group. *Ophthalmology* 1997;**104**:1442-52.
- 22 Chang TS, Mc Gill E, Hay DA, *et al.* Prophylactic scleral buckle for prevention of retinal detachment following vitrectomy for macular hole. *Br J Ophthalmol* 1999;**83**:944-8.
- 23 Morris R, Witherspoon CD, Fivgas G, *et al.* Indirect ophthalmoscopic laser cerclage prophylaxis for post-operative retinal detachment in macular hole surgery. *Invest Ophthalmol Vis Sci* 1999;**40**:1114.
- 24 Carter JB, Michels RG, Glaser BM, *et al.* Iatrogenic retinal breaks complicating pars plana vitrectomy. *Ophthalmology* 1990;**97**:848-54.
- 25 McLeod D. Giant retinal tears after central vitrectomy. *Br J Ophthalmol* 1985;**69**:96-8.
- 26 Demols P, Rasquin F, Schrooyen M. Surgery for macular hole without positioning. *Bull Soc Belge Ophthalmol* 2000;**275**:57-61.
- 27 Goldbaum MH, McCuen BW, Hanneken AM, *et al.* Silicone oil tamponade to seal macular holes without position restrictions. *Ophthalmology* 1998;**105**:2140-7.
- 28 Berger JW, Brucker AJ. The magnitude of the bubble buoyant pressure: implications for macular hole surgery. *Retina* 1998;**18**:84-6.
- 29 Brooks HL Jr. Macular hole surgery with and without internal limiting membrane peeling. *Ophthalmology* 2000;**107**:1939-48.
- 30 Kadosono K, Itoh N, Uchio E, *et al.* Staining of internal limiting membrane in macular hole surgery. *Arch Ophthalmol* 2000;**118**:1116-8.
- 31 Duker JS, Wendel R, Patel AC, *et al.* Late re-opening of macular holes after initially successful treatment with vitreous surgery. *Ophthalmology* 1994;**101**:1373-8.
- 32 Sheidow TG, Gonder JR. Cystoid macular oedema following combined phacoemulsification and vitrectomy for macular hole. *Retina* 1998;**18**:510-14.



Phacovitrectomy without prone posture for full thickness macular holes

Peter R Simcock and Sergio Scalia

Br J Ophthalmol 2001 85: 1316-1319

doi: 10.1136/bjo.85.11.1316

Updated information and services can be found at:

<http://bjo.bmj.com/content/85/11/1316.full.html>

References

These include:

This article cites 30 articles, 5 of which can be accessed free at:

<http://bjo.bmj.com/content/85/11/1316.full.html#ref-list-1>

Article cited in:

<http://bjo.bmj.com/content/85/11/1316.full.html#related-urls>

Email alerting service

Receive free email alerts when new articles cite this article. Sign up in the box at the top right corner of the online article.

Topic Collections

Articles on similar topics can be found in the following collections

[Retina](#) (1217 articles)

[Ophthalmologic surgical procedures](#) (971 articles)

[Lens and zonules](#) (642 articles)

Notes

To request permissions go to:

<http://group.bmj.com/group/rights-licensing/permissions>

To order reprints go to:

<http://journals.bmj.com/cgi/reprintform>

To subscribe to BMJ go to:

<http://group.bmj.com/subscribe/>