

# Trabeculectomy with mitomycin C in the treatment of post-traumatic angle recession glaucoma

T Manners, J F Salmon, A Barron, C Willies, A D N Murray

## Abstract

**Aim**—The presence of traumatic angle recession is a risk factor for failure of glaucoma filtration surgery and a previous study has suggested that antimetabolite treatment should be used in these patients. This study was undertaken to determine for the first time the mid term results of trabeculectomy with intraoperative application of mitomycin C in patients with post-traumatic angle recession glaucoma.

**Methods**—A retrospective analysis was made of 43 consecutive trabeculectomy procedures in 41 young black/mixed race patients followed for a mean period of 25 months (range 2–66 months). Mitomycin C 0.02% was applied between the sclera and conjunctiva for 1–5 minutes at the time of surgery. The intraocular pressure and visual acuity were measured postoperatively. The success of this technique was analysed by using a Kaplan-Meier cumulative survival curve.

**Results**—The intraocular pressure was successfully controlled at last follow up without topical treatment in 77% (33/43 eyes) and the visual acuity was the same or better in 81% (35/43 eyes). Cumulative probability of success was 85% at 1 year follow up, 81% at 2 years, and 66% at 3 years and thereafter. Hypotonous maculopathy occurred in one patient and no cases of late bleb infection were found.

**Conclusions**—In medically uncontrolled post-traumatic angle recession glaucoma trabeculectomy with mitomycin C is an effective surgical procedure with an acceptable complication rate. Good intraocular pressure control and preservation of vision can be expected in most patients.

(Br J Ophthalmol 2001;85:159–163)

Department of  
Ophthalmology,  
Groote Schuur  
Hospital, Cape Town,  
South Africa  
T Manners  
J F Salmon  
A Barron  
C Willies  
A D N Murray

Correspondence to:  
Mr J Salmon, Oxford Eye  
Hospital, Oxford OX2 6HE,  
UK  
[john.salmon@orh.anglox.nhs.uk](mailto:john.salmon@orh.anglox.nhs.uk)

Accepted 19 July 2000

Post-traumatic angle recession glaucoma is an uncommon form of secondary glaucoma which has a high prevalence in Cape Town, South Africa where it typically occurs in young black or mixed race men.<sup>1,2</sup> Medical treatment of traumatic glaucoma is often unsuccessful because of poor compliance and loss to follow up,<sup>3</sup> and the results of argon laser trabeculoplasty (Scharf *et al*, 1992, unpublished data) and YAG-laser trabeculoplasty are disappointing.<sup>4</sup> It has been shown that the presence of angle recession is a risk factor for failure of glaucoma filtration surgery independent of age or race, and that trabeculectomy using adjunctive

antimetabolite therapy is more successful than trabeculectomy undertaken without antimetabolites or Molteno implantation in this condition.<sup>5,6</sup>

Mitomycin C used at the time of glaucoma surgery has the ability significantly to suppress fibrosis and vascular ingrowth after exposure to the filtration site.<sup>7–9</sup> A previous study has reported encouraging success rates after a single application of this drug in young black patients, particularly when other ocular risk factors for failure of filtration surgery are present.<sup>10</sup> However, a number of serious ocular complications have occurred as a direct consequence of the use of mitomycin C, and late endophthalmitis and ocular hypotony may result in permanent visual loss.<sup>11–14</sup>

In a previous study from this unit we reported the use of mitomycin C in a series of nine patients with post-traumatic glaucoma, but the follow up period was short and the full impact of this approach could not be evaluated.<sup>6</sup> To determine the long term results of trabeculectomy with intraoperative application of mitomycin C in patients with post-traumatic angle recession glaucoma, a retrospective analysis was undertaken of 41 consecutive patients (43 eyes) treated in this manner during a 5 year period.

## Patients and methods

From April 1991 to February 1996 trabeculectomy was performed with adjunctive mitomycin C application in 43 eyes of 41 consecutive patients with post-traumatic angle recession glaucoma at Groote Schuur Hospital, Cape Town. The average age of the patients at the time of surgery was 44 years (range 18–72), 36 were men, and all were either black (n=15) or of mixed racial background (n=26).

Thirty patients either denied ocular trauma or had so many episodes of trauma that no date could be given to the occurrence of an injury. In the other 11 the time from injury to surgery ranged from 1 month to 20 years (median 3 years). The indication for surgery was medically uncontrolled glaucoma in 10, documented progression of optic disc cupping or visual field defect in 12, and advanced glaucomatous atrophy and uncontrolled intraocular pressure on initial presentation in 21. The duration of treatment for glaucoma before surgery ranged from 1 month to 9 years (mean 12 months). The preoperative intraocular pressure ranged from 20 mm Hg to 68 mm Hg (mean 34 (SD 9.2) mm Hg) and the amount of angle recession ranged from 90° to 360° (median 360°). Optic disc cupping ranged

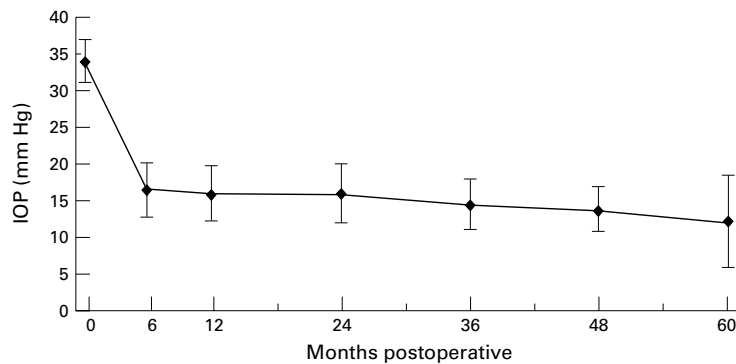


Figure 1 Mean intraocular pressure (with 95% confidence intervals) before surgery, at 6 months, and at yearly intervals following mitomycin C trabeculectomy.

from 0.6 to 1.0 in the vertical meridian (median 0.9).

Visual acuity preoperatively ranged from 6/9 to "hand movements" (median 6/120). Signs of previous trauma noted preoperatively included a subluxed lens in five eyes, cataract in three, and previously treated retinal detachment in two. The fellow eye was blind or severely damaged due to trauma in nine cases.

In all patients the operation was performed or directly supervised by two surgeons (JFS or AB) using a technique similar to that described by Cairns.<sup>15</sup> The conjunctival flap was fornix based in six eyes and limbal based in 37 (depending on the surgeon's preference). After haemostasis of the episclera was attained, mitomycin C was applied between the sclera and Tenon's capsule using a surgical sponge that measured 4.5 mm × 4.5 mm that had been previously soaked in a 0.2 mg/ml solution of mitomycin C. In 21 patients the mitomycin C was applied for 5 minutes, in 18 for 2 minutes, and in four for 1 minute (the different times of application correspond to changes in departmental policy to the use of mitomycin C). After the sponge was removed the entire area was thoroughly irrigated with balanced saline solution. A 4.0 × 4.0 mm limbal based scleral flap was dissected into clear cornea. A 1.0 × 2.0 mm deep scleral block was removed and a peripheral iridectomy was performed. The scleral flap was closed with 2–4 interrupted 10-0 nylon sutures. When a limbus based flap was used, Tenon's capsule and the conjunctival layer were sutured in two separate layers by using a continuous 10-0 nylon suture on a round bodied needle for each layer. When a fornix based flap was used, Tenon's capsule and the conjunctiva were sutured with interrupted 10-0 nylon sutures at the limbus. Subconjunctival injections of 20 mg gentamicin and 1.5 mg betamethasone acetate were administered in the inferior fornix. Postoperatively, topical homatropine 1% was instilled twice daily for the first week. Topical chloramphenicol was used four times daily for four postoperative weeks and topical prednisolone 1% was used four times daily for 2–3 months.

For the purposes of this study, the patients were analysed at the visit nearest to the 6, 12, 24, 36, 48, and 60 month postoperative visit. On each occasion the patients were fully exam-

ined at the slit lamp and the visual acuity, intraocular pressure, and bleb appearance were determined. Any complications of surgery were noted. The two patients who were followed up for less than 1 month were excluded from the statistical analysis.

To compare these results with those of others, the surgery was considered a "complete success" when the intraocular pressure was ≤21 mm Hg without glaucoma medication, a "qualified success" when the intraocular pressure was ≤21 mm Hg with antiglaucoma medication, a "qualified failure" when the pressure was >21 mm Hg with or without medication, and a "complete failure" when progressive glaucomatous atrophy with visual field loss was documented or when an eye required a further glaucoma drainage operation, developed phthisis bulbi, or lost light perception at last follow up.

The success of the technique was analysed using a Kaplan-Meier cumulative survival curve. Comparisons between the groups (2 minute and 5 minute application times; fornix based and limbus based conjunctival flaps) were undertaken using  $\chi^2$  analysis as the groups matched each other demographically and on the basis of the ocular parameters. A p value of <0.05 was considered significant.

## Results

The follow up period ranged from less than 1 month (in two patients) to 66 months, with a mean of 25 months. The mean intraocular pressure measurements preoperatively and at 6, 12, 24, 36, 48, and 60 months postoperatively are shown in Figure 1.

On the first postoperative day the intraocular pressure was ≤6 mm Hg in 55.8% of eyes (24/43), five (11.6%) had a hyphaema, five (11.6%) had a shallow anterior chamber (including one with a wound leak), and one had a significant choroidal detachment. In each case these complications settled spontaneously without the need for surgical intervention.

In 33 of the 43 eyes (76.7%) the result of surgery was considered a "complete success" and in 10 of the 43 eyes (23.3%) a "complete failure" at last follow up. No eyes fulfilled the criteria for "qualified" success or failure. In the group of 21 eyes where mitomycin C was applied for 5 minutes the complete success rate was 71.4% (15/21) and in the group of 18 eyes where mitomycin C was applied for 2 minutes the complete success rate was 72.2% (13/18) at last follow up ( $p>0.5$ ). No significant difference was found when the success rate of the fornix based conjunctival flap group was compared with that of the limbus based conjunctival flap group ( $p>0.5$ ). Kaplan-Meier life table analysis representing longitudinal success rates is shown in Figure 2. The cumulative probability of success was 85% at 1 year follow up, 81% at 2 years, and 66% at 3 years and thereafter.

Visual acuity at last follow up ranged from 6/9 to no light perception (median 6/120). The visual outcome was the same or better in 81.5% of eyes (35/43). Of the eight eyes in which the vision deteriorated over the period of

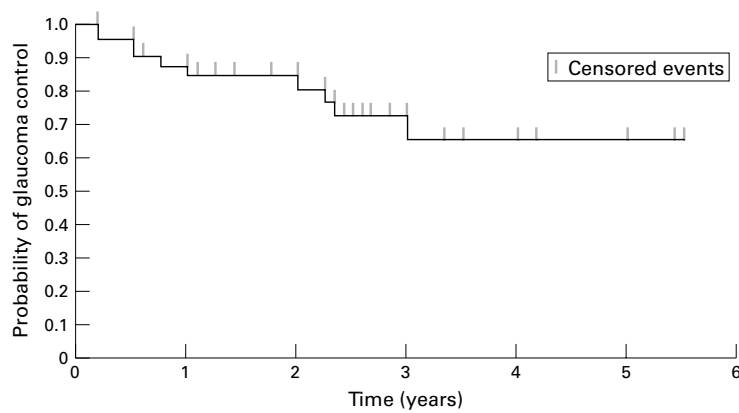


Figure 2 Kaplan-Meier cumulative probability of successful glaucoma control (intraocular pressure <21 mm Hg on no treatment) over 5.5 years following mitomycin C trabeculectomy. Censored events represent drop out from follow up due to non-attendance and include two deaths during the follow up period.

follow up, the visual loss occurred secondary to progressive glaucomatous atrophy in four, hypotonous maculopathy in one, untreated cataract in one, retinal detachment in one, and further trauma resulting in evisceration in one. In four eyes light perception was lost over the period of follow up.

Of the 10 failures, four had no further treatment as they did not return for follow up, three underwent a second trabeculectomy using mitomycin C, two underwent cyclodiode treatment, and one underwent implantation of a Molteno tube. Two of the three patients who underwent repeat trabeculectomy with mitomycin C were successfully controlled (at 12 months and 36 months postoperatively). One patient who underwent cyclodiode treatment was successfully controlled and one was not (at 3 months postoperatively). This patient underwent repeat trabeculectomy with mitomycin C and was successfully controlled (at 12 months postoperatively). The patient who underwent Molteno implantation was successfully controlled (12 months postoperatively).

Twenty seven of the 43 eyes (63%) developed a cystic, thin walled bleb. In no patient was late wound leakage or endophthalmitis found. Late hypotony (intraocular pressure  $\leq 6$  mm Hg) occurred in four eyes (9.3%) and resulted in hypotonous maculopathy in one patient (2.3%).

### Discussion

The association of blunt ocular trauma with subsequent development of glaucoma has been well described.<sup>16-20</sup> The pathological features were described by Wolff and Zimmerman<sup>21</sup> in 1962 who showed histological retrodisplacement of the iris root. Pathological changes have been seen in the trabecular meshwork and angle recession is not responsible for the obstruction to aqueous outflow.<sup>22</sup> It has been reported that the normal fellow eyes of patients with unilateral angle recession glaucoma are more likely to have a raised intraocular pressure with a positive response to corticosteroid provocative testing.<sup>20</sup> It has therefore been suggested that eyes with an underlying tendency to develop open angle glaucoma are

more likely to develop a late increase in intraocular pressure after blunt trauma.

While recession of the irido-corneal angle is common after blunt trauma (60-94%), the late development of glaucoma is rare (2-10%).<sup>16-20 22 23</sup> The rise in intraocular pressure that occurs immediately after a non-penetrating eye injury can be severe but usually lasts only days or weeks and, in most cases, can be controlled with glaucoma medication alone. Traumatic glaucoma with chronically raised intraocular pressure, optic nerve cupping, and visual field damage usually occurs years or even decades after blunt trauma. It has previously been reported from this unit that the mean time between injury and the diagnosis of glaucoma is 7.6 (9.5) years,<sup>6</sup> whereas Herschler<sup>22</sup> found that 16.5 years elapsed between injury and discovery of glaucoma. Late glaucoma is more frequent if the recession involves 180° or more of the angle and in the present series the mean degree of angle recession was 300°.<sup>16 18</sup> Other studies have reported that the injury inducing angle recession and subsequent traumatic glaucoma has resulted from sport or other recreational accidents, but in Cape Town the main cause is assault.<sup>1 18 23</sup>

Cases of traumatic glaucoma have been reported in series of refractory glaucoma but, because of the small numbers, no conclusions regarding the surgical management have been made. In a retrospective analysis of 65 patients from our unit, some guidelines were provided on the surgical management of this condition.<sup>6</sup> In that series the success of trabeculectomy using Kaplan-Meier life table analysis was 62 (5)% after 2 years, 42 (6)% after 4 years, and 10 (8)% after 6 years of follow up. This poor long term success rate could be related to the young age of the patients and their race (black or mixed race), but is also a feature of post-contusional injury. This fact is supported by a study which showed that successful intraocular pressure control could be achieved in only 43% (15/35) of patients with angle recession glaucoma treated with trabeculectomy compared with 74% (26/35) in matched patients with primary open angle glaucoma treated in the same way.<sup>5</sup> Bleb failure occurred a mean of 3.1 (SD 1.2) months after surgery in patients with angle recession glaucoma compared with 9.4 (5) months in those with primary open angle glaucoma.<sup>5</sup> Although it would be useful to explore the relative risk potential of the factors of age, race, and ocular injury further, the data from this study do not allow this determination to be made. In a previous study from this unit antimetabolite treatment was used to suppress fibrosis in 20 patients with post-traumatic angle recession glaucoma.<sup>6</sup> In 11 of these patients 5-fluorouracil was injected into the subconjunctival space postoperatively and in nine patients mitomycin C 0.02% was applied between the sclera and the conjunctiva for 5 minutes at the time of surgery. The fall in intraocular pressure was significantly greater, the percentage of successful cases at 3 and 6 months postoperatively was significantly

higher, and the number of postoperative glaucoma medications was significantly lower in this group than in patients who had undergone trabeculectomy alone, but 15% (3/20) developed late bleb infection.

This study was undertaken to determine the mid term results of trabeculectomy with intraocular application of mitomycin C in patients with post-traumatic angle recession glaucoma. Although a randomised prospective study comparing mitomycin C with placebo would be preferable to a retrospective non-comparative case series, such a study would be difficult to justify in the light of previous studies which show an extremely low success rate without antimetabolite treatment in these circumstances.<sup>5,6</sup> Survival curve analysis revealed a success rate of 81% after 2 years of follow up and 66% after 5 years. There are no other similar studies with which to compare these results. Almost identical results were achieved whether the mitomycin C was applied to the tissue for 5 minutes or for 2 minutes, which supports the findings of a study undertaken on patients at risk of failure of trabeculectomy which determined that the result of surgery with a 2 minute intraoperative application of mitomycin C was as effective as a 5 minute application.<sup>24</sup> The success rate of surgery was not influenced by the type of conjunctival flap, a finding that agrees with a previous study which compared limbus based and fornix based conjunctival flaps in association with trabeculectomy without the use of adjunctive antimetabolite treatment.<sup>25</sup>

Of the 10 procedures in the present series which were considered to be failures, six underwent further surgery. Of the four who underwent trabeculectomy with mitomycin C, three were successfully controlled (3/4, 75%) and, in the one who underwent implantation of a Molteno tube, a successful result was achieved. In a study comparing the success rate of trabeculectomy plus antimetabolite with Molteno tube implantation, when both techniques were used as a secondary procedure in patients with post-traumatic glaucoma, better results were achieved when a single plate Molteno implant was inserted (78%, 7/9 overall success) than were achieved with secondary trabeculectomy plus antimetabolite (57%, 4/7 overall success), although the difference was not statistically significant.<sup>6</sup>

There were no significant immediate postoperative complications of the surgery and those eyes with a hyphaema or a shallow anterior chamber settled spontaneously without the need for surgical intervention. Previous studies using mitomycin C have reported a number of serious late ocular complications as a direct consequence of the use of this agent. Depending on the concentration and exposure time, an incidence of hypotony ranging between 3% and 32.7% has been reported,<sup>11,12,24</sup> and in this series ocular hypotony developed in four of the 43 eyes (9.3%). In one patient in this series (2.3%) hypotony related maculopathy occurred—a complication that has previously been reported in 3–17.3% of patients receiving mitomycin C.<sup>11,12,24</sup> Late bleb infection after

the use of antimetabolites is a major concern, and it is remarkable that no cases of bleb infection or endophthalmitis occurred in the present series despite the fact that 63% (27/43) had a thin walled cystic bleb. Wolner *et al.*,<sup>26</sup> with a mean follow up of 23.7 (16.3) months, reported an incidence of bleb related endophthalmitis of 5.7% (13/229) after 5-fluorouracil trabeculectomy and Higginbotham *et al.*,<sup>14</sup> with a mean follow up of 18.5 (10.8) months, reported an incidence of 2.6% (6/229) after mitomycin C trabeculectomy. It is well established that placing the trabeculectomy in an inferior position increases the risk of late bleb infection,<sup>14,26</sup> and we assumed that post-traumatic angle recession glaucoma might be another risk factor as three such patients in our previous study who received 5-fluorouracil injections postoperatively developed bleb infection.<sup>6</sup> Although the follow up time was not particularly long, the reason for the low incidence of bleb related infections in the present study is not clear. It may be related to a change in the postoperative policy adopted in patients with cystic bleb formation. Patients were specifically warned of the risk of infection, were instructed to seek medical help at the first sign of conjunctivitis, and were not given prophylactic topical medication in order to reduce the risk of bacterial infection secondary to contamination of the drop bottle.<sup>27</sup>

The surgical management of post-traumatic angle recession glaucoma is difficult because the patients are young, the disease is often advanced, and the follow up and compliance are poor. Our results of surgical treatment of post-traumatic angle recession glaucoma using mitomycin C suggest that good mid term control of intraocular pressure can be achieved without the need for topical medication. If a second procedure is required after a failed trabeculectomy with mitomycin C, the procedure can be repeated with good results. This study confirms that there is a small risk of a patient losing vision from hypotonous maculopathy, but suggests that in the medium term the risk of bleb related infection and endophthalmitis may be less than previously thought.

Mr Manners is currently affiliated with the Department of Ophthalmology, York District Hospital, and Mr Salmon with the Oxford Eye Hospital, UK. Dr Barron died during the preparation of this manuscript.

- 1 Salmon JF, Mermoud A, Ivey A, *et al.* The detection of post-traumatic angle recession by gonioscopy in a population-based glaucoma. *Ophthalmology* 1994; **101**:1844–50.
- 2 Salmon JF, Mermoud A, Ivey A, *et al.* The prevalence of primary angle closure glaucoma and open angle glaucoma in Mamre, Western Cape, South Africa. *Arch Ophthalmol* 1993; **111**:1263–9.
- 3 Desai P, MacEwen CJ, Bains P, *et al.* Incidence of cases of ocular trauma admitted to hospital and incidence of blinding outcome. *Br J Ophthalmol* 1996; **80**:592–6.
- 4 Fukuchi T, Iwata K, Sawaguchi S, *et al.* Nd:YAG laser trabeculopuncture (YLT) for glaucoma with traumatic angle recession. *Graefes Arch Ophthalmol* 1993; **231**:571–6.
- 5 Mermoud A, Salmon JF, Straker C, *et al.* Post-traumatic angle recession glaucoma: a risk factor for bleb failure after trabeculectomy. *Br J Ophthalmol* 1993; **77**:631–4.
- 6 Mermoud A, Salmon JF, Barron A, *et al.* Surgical management of post-traumatic angle recession glaucoma. *Ophthalmology* 1993; **100**:634–42.
- 7 Bergstrom TJ, Wilkinson WS, Skuta GL, *et al.* The effects of subconjunctival mitomycin C on glaucoma filtration surgery in rabbits. *Arch Ophthalmol* 1991; **109**:1725–30.
- 8 Costa VP, Mosler MR, Wilson RP, *et al.* Effects of topical mitomycin C on primary trabeculectomies and combined procedures. *Br J Ophthalmol* 1993; **77**:693–7.

- 9 Palmer SS. Mitomycin as adjunct chemotherapy with trabeculectomy. *Ophthalmology* 1991;**98**:317–21.
- 10 Mermoud A, Salmon JF, Murray ADN. Trabeculectomy with mitomycin C for refractory glaucoma in blacks. *Am J Ophthalmol* 1993;**116**:72–8.
- 11 Shields MB, Scroggs MW, Sloop CM, *et al.* Clinical and histopathologic observations concerning hypotony after trabeculectomy with adjunctive mitomycin C. *Am J Ophthalmol* 1993;**116**:673–83.
- 12 Zacharia PT, Depperman SR, Schuman JS. Ocular hypotony after trabeculectomy with mitomycin C. *Am J Ophthalmol* 1993;**116**:314–26.
- 13 Greenfield DS, Suner IJ, Miller MP, *et al.* Endophthalmitis after filtration surgery with mitomycin. *Arch Ophthalmol* 1996;**114**:943–9.
- 14 Higginbotham EJ, Stevens RK, Musch DC, *et al.* Bleb related endophthalmitis after trabeculectomy with mitomycin C. *Ophthalmology* 1996;**103**:650–6.
- 15 Cairns JE. Trabeculectomy. Preliminary report of a new method. *Am J Ophthalmol* 1968;**66**:673–9.
- 16 Blanton FM. Anterior chamber angle recession and secondary glaucoma. A study of the after effects of traumatic hyphemas. *Arch Ophthalmol* 1964;**72**:39–43.
- 17 Mooney D. Angle recession and secondary glaucoma. *Br J Ophthalmol* 1973;**57**:608–12.
- 18 Alper MG. Contusion angle deformity and glaucoma. Gonioscopic observation and clinical course. *Arch Ophthalmol* 1963;**69**:455–67.
- 19 Kaufman JH, Tolpin DW. Glaucomas after traumatic angle recession. A ten-year prospective study. *Am J Ophthalmol* 1974;**78**:648–54.
- 20 Spaeth GL. Traumatic hyphema, angle recession, dexamethasone hypertension, and glaucoma. *Arch Ophthalmol* 1967;**78**:714–21.
- 21 Wolff SM, Zimmerman LE. Chronic secondary glaucoma: associated with retrodisplacement of iris root and deepening of the anterior chamber angle secondary to contusion. *Am J Ophthalmol* 1962;**54**:547–63.
- 22 Herschler J. Trabecular damage due to blunt anterior segment injury and its relationship to traumatic glaucoma. *Trans Am Acad Ophthalmol Otolaryngol* 1977;**83**:239–48.
- 23 Canavan YM, Archer DB. Anterior segment consequences of blunt ocular injury. *Br J Ophthalmol* 1982;**66**:549–55.
- 24 Mégavand GS, Salmon JF, Scholtz RP, *et al.* The effect of reducing the exposure time of mitomycin C in glaucoma filtering surgery. *Ophthalmology* 1995;**102**:84–90.
- 25 Traverso CE, Tomey KF, Antonios S. Limbal versus fornix-based conjunctival trabeculectomy flaps. *Am J Ophthalmol* 1987;**104**:28–32.
- 26 Wolner B, Liebmann JM, Sassani JW, *et al.* Late bleb-related endophthalmitis after trabeculectomy with adjunctive 5-fluorouracil. *Ophthalmology* 1991;**98**:1053–60.
- 27 Geyer O, Bottone EJ, Podos SM, *et al.* Microbial contamination of medications used to treat glaucoma. *Br J Ophthalmol* 1995;**79**:376–9.



## Trabeculectomy with mitomycin C in the treatment of post-traumatic angle recession glaucoma

T Manners, J F Salmon, A Barron, et al.

*Br J Ophthalmol* 2001 85: 159-163

doi: 10.1136/bjo.85.2.159

---

Updated information and services can be found at:

<http://bjo.bmj.com/content/85/2/159.full.html>

---

*These include:*

### References

This article cites 27 articles, 10 of which can be accessed free at:

<http://bjo.bmj.com/content/85/2/159.full.html#ref-list-1>

### Email alerting service

Receive free email alerts when new articles cite this article. Sign up in the box at the top right corner of the online article.

---

### Topic Collections

Articles on similar topics can be found in the following collections

[Angle](#) (788 articles)

[Glaucoma](#) (776 articles)

[Intraocular pressure](#) (786 articles)

[Ophthalmologic surgical procedures](#) (962 articles)

---

### Notes

---

To request permissions go to:

<http://group.bmj.com/group/rights-licensing/permissions>

To order reprints go to:

<http://journals.bmj.com/cgi/reprintform>

To subscribe to BMJ go to:

<http://group.bmj.com/subscribe/>