

Transpupillary thermotherapy (TTT) for the treatment of choroidal neovascularisation

R S B Newsom, J C McAlister, M Saeed, J D A McHugh

Abstract

Aim—To assess the effectiveness of transpupillary thermotherapy (TTT) for the treatment of classic and occult choroidal neovascularisation (CNV).

Method—In a retrospective, case selected, open label trial 44 eyes of 42 patients with CNV secondary to age related macular degeneration (ARMD) were studied. 44 eyes with angiographically defined CNV were treated with diode laser (810 nm) TTT. Laser beam sizes ranged between 0.8 and 3.0 mm and power settings between 250–750 mW. Treatment was given in one area for 1 minute, the end point being no visible change, or a slight greying of the retina. Outcome was assessed with Snellen visual acuity and clinical examination; in 24/44 patients angiographic follow up was available.

Results—12 predominantly classic CNV and 32 predominantly occult membranes were followed up for a mean of 6.1 months (range 2–19). Mean change in vision for classic membranes was -0.75 (SD 1.75) Snellen lines and occult membranes was -0.66 Snellen lines (2.1) ($p > 0.05$). Predominantly classic membranes were closed in 75% (95% CI: 62.5–87.5) of eyes, remained persistent in 25% (95% CI: 12.5–37.5); no recurrences occurred. Predominantly occult membranes were closed in 78% (95% CI: 70.1–85.3) of eyes, remained persistent in 12.5% (95% CI: 6.6–18.5), and were recurrent in 5.1% (95% CI: 4.2–14.3).

Conclusions—Transpupillary thermotherapy is a potential treatment for CNV. It is able to close choroidal neovascularisation while maintaining visual function in patients with classic and occult disease. Further trials of TTT are needed to compare this intervention with the natural history and other treatment modalities.

(Br J Ophthalmol 2001;85:173–178)

King's College
Hospital, Denmark
Hill, London SE5 9RS,
UK

R S B Newsom
J C McAlister
M Saeed
J D A McHugh

Correspondence to:
Mr R S B Newsom,
Department of Vitreoretinal
Surgery, Moorfields Eye
Hospital, City Road, London
EC1V 2PD, UK
rbnewsom@dircon.co.uk

Accepted for publication
31 July 2000

laser treatment because the CNV is occult, or subfoveal and large.^{1–3} The limitations of photocoagulation have led to a proliferation of new treatments (photodynamic therapy,^{11–14} radiotherapy,¹⁵ interferon α_2 ,¹⁶ macular rotation,^{17, 18} and submacular membrane excision for occult and subfoveal lesions¹⁹).

The diode laser (emission wavelength λ 810 nm, near infrared) has a number of biophysical advantages in the treatment of macular disease. It has low absorption in xanthophyll, minimising nerve fibre layer damage, it is poorly absorbed by haemoglobin, allowing treatment through preretinal and subretinal blood but is mainly absorbed in the choroid, enabling effective treatment of choroidal lesions.²⁰ Initial studies using photocoagulation have shown it to be effective in closing CNV^{21, 22} and in treating macular oedema.^{23, 24} Low irradiance, long pulse diode laser irradiation (“transpupillary thermotherapy; TTT”) has been usefully employed for the treatment of choroidal melanomas.^{25, 26}

A recent report by Reichel and colleagues²⁷ has further demonstrated the benefit of diode laser TTT for the treatment of subfoveal CNV. In a non-randomised case selected pilot study, 94% of CNV showed clinical or angiographic improvement and vision was stabilised or improved in 75%. Optical coherence tomography demonstrated membrane resolution with a restoration of the retinal anatomy.

We aimed to assess the efficacy of transpupillary thermotherapy for the treatment of both classic and occult CNV.

Materials and methods

Forty two consecutive patients with CNV secondary to ARMD, referred to the retinal clinic at King's College Hospital, were recruited to a non-randomised pilot trial. Baseline characteristics and eligibility criteria are shown in Table 1. The patients were over 55, had signs of ARMD, and had symptoms of visual loss or metamorphopsia within the previous 4 months. There was angiographic evidence of CNV with or without pigment epithelial detachment. The Snellen visual acuity ranged between 6/9 and counting fingers. Patients who had received previous photocoagulation or were on alternative treatments for AMD were excluded from the trial, as were patients with other serious ocular disease or medical conditions that would prevent them from completing treatment.

BASELINE EXAMINATION

Initial clinical assessment included Snellen visual acuity, anterior segment examination, IOP measurement, mydriasis with 1% tropica-

Age related macular degeneration (ARMD) is the leading cause of visual loss in the developed world and choroidal neovascularisation (CNV) is the main cause of severe visual loss in this group.^{1–4} Laser photocoagulation treatment for classic CNV reduces the incidence of severe visual loss in patients with extrafoveal and juxtafoveal membranes. However, because photocoagulation damages neurosensory mechanisms, severe visual loss is often experienced in patients with subfoveal lesions.^{1–10} The benefits of laser treatment are also reduced by recurrence in many patients.⁹ In addition, 85–90% of patients with CNV are not eligible for argon

Table 1 Baseline characteristics of patients

Characteristic	No (%) of patients	
Age		
55–69	3	(7.2)
70–79	15	(35.7)
80+	24	(57.1)
Sex		
Female	30	(74.8)
Male	12	(33.4)
CNV classification	Classic	Occult
Total	12 (27.2%)	32 (72.8%)
Position		
Extrafoveal	1	
Juxtafoveal	2	
Subfoveal	9	
Area on angiography/disc areas		
1–2	5	2
2–3	3	12
3+	1	6
Haemorrhage	7	22
Serous PED	11	30

mide, and funduscopy with a 78D or 60D Volk lens (Volk Optical, Mentor, OH, USA). Following this, patients were assessed with digital or photographic fundus colour (Topcon, Tokyo, Japan) and fluorescein angiography (sodium fluorescein 5 ml, 10%). Patients were counselled as to the prognosis for their condition and their treatment options. Patients not willing to undergo treatment or to complete the counselling were excluded from the trial. The patients consented to treatment and the investigation took place with the recognition of the King's College Hospital ethics committee.

TREATMENT PROTOCOL

Treatment was scheduled between 1 hour and 4 days of the initial angiogram. The membranes were classified in accordance with their angiographic appearance. Transpupillary thermotherapy with an 810 nm diode laser (Iris Medical OcuLight SLx, Iridex Corporation, Mountain View, CA, USA), was delivered through a dedicated slit lamp mounted delivery system. Laser settings were adjusted to give faint retinal greying following 1 minute of treatment. Beam diameters varied between 800 and 3000 μm .

The goal of TTT is to create and maintain tissue hyperthermia. It has been found that higher irradiance is needed for smaller laser spot diameters owing to the efficient heat conductance of the choroidal circulation. Hence, laser irradiance must be inversely proportional to the spot diameter, which determines the size of the thermally affected tissue volume.²⁸ For a 3 mm beam the settings were between 500–700 mW (irradiance 6–9 W/cm²); for a 2 mm beam between 400–650 (irradiance 11–18 W/cm²); and for a 1.2 mm beam 300–600 mW (irradiance 24–47 W/cm²). A Volk (Mentor, OH, USA) area centralis contact lens was used in every case giving a magnification of 1.06 \times of the laser spot at the retina. Patients were anaesthetised with topical benoxinate 1%. Laser targeting was achieved with a diode red beam, the lesion being covered and extending 100 μm beyond the border. If whitening of the lesion was seen the laser power was reduced by

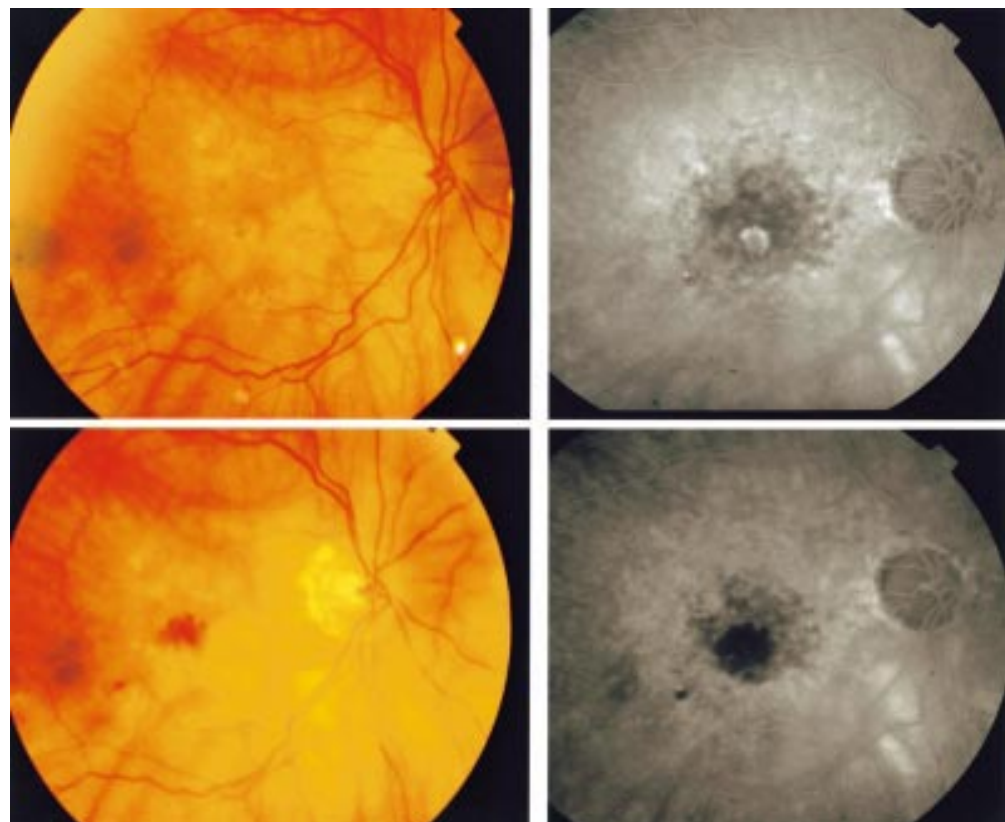


Figure 1 (Top left and right) Colour and fluorescein images showing a small classic juxtafoveal membrane. (Bottom left and right) Colour and fluorescein images following TTT with resolution of the membrane; the patient's initial vision improved from 6/12 to 6/9 3 months after treatment.

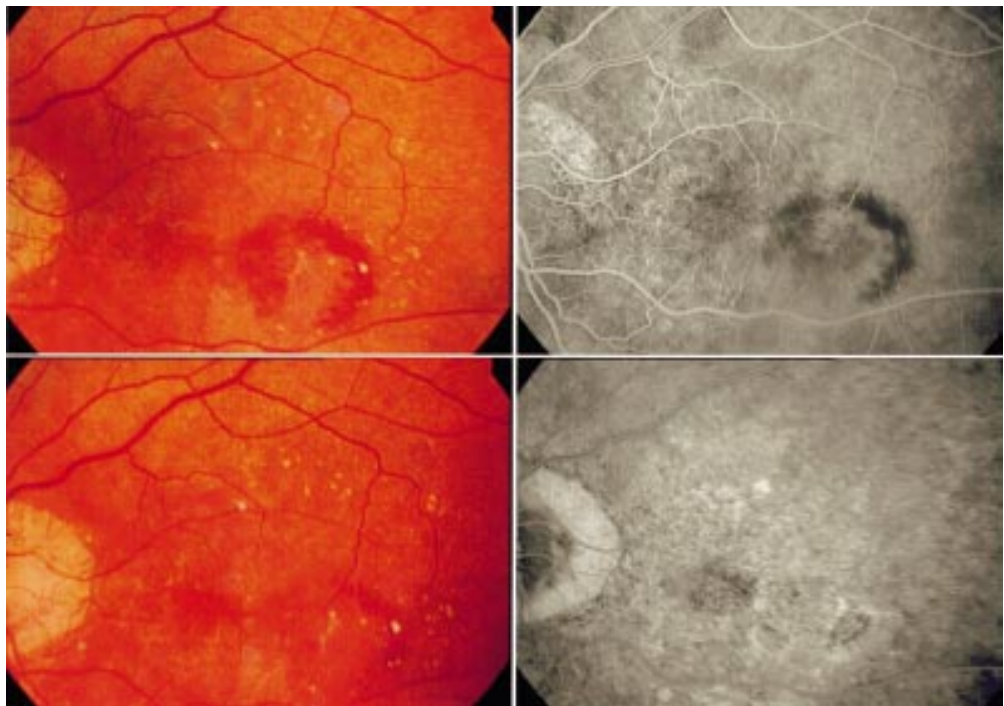


Figure 2 (Top left and right) Colour and fluorescein images showing an occult subfoveal membrane. (Bottom left and right) Colour and fluorescein images following TTT, with complete closure of the CNV. The patient's vision was stabilised 3 months following treatment.

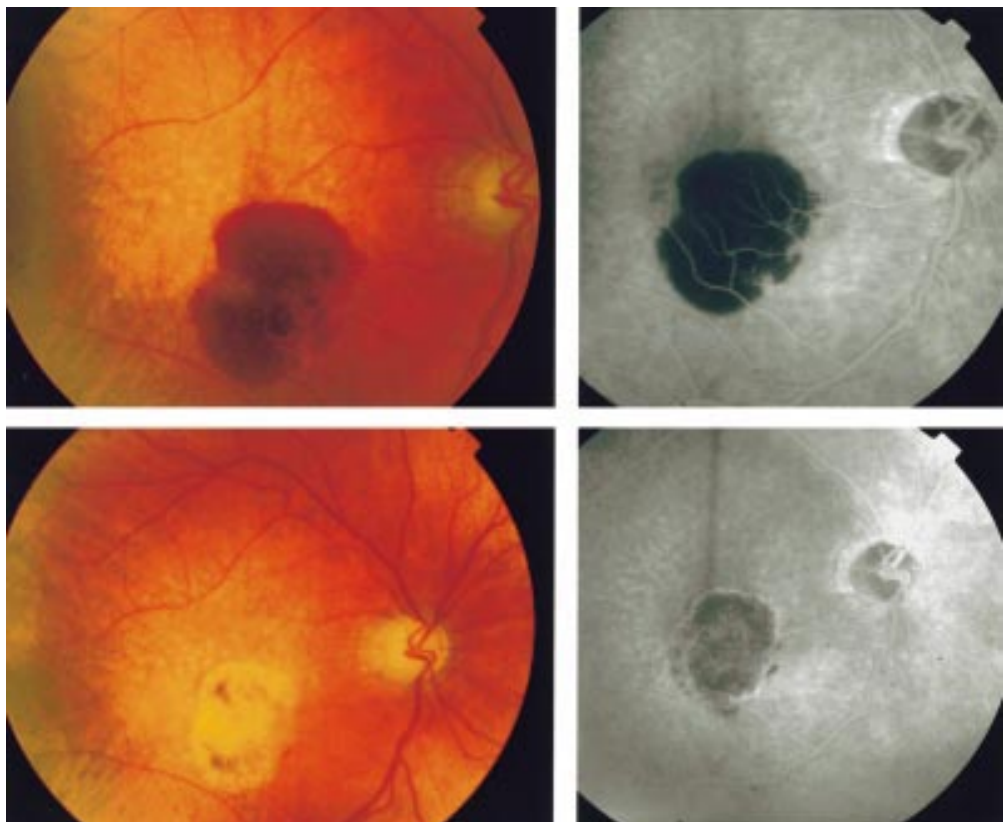


Figure 3 (Top left and right) Colour and fluorescein images showing an occult subfoveal membrane with extensive subretinal haemorrhage. (Bottom left and right) Colour and fluorescein images showing resolution of the CNV and absorption of subretinal haemorrhage 6 weeks following TTT treatment. The patient's vision improved from 6/60 to 6/24.

Table 2 Pre and post-TTT visual acuity classic membranes

Snellen VA	Pre-TTT		Post-TTT	
	No	(%)	No	(%)
6/6	0	(0)	0	(0)
6/9	0	(0)	1	(8.3)
6/12	0	(0)	0	(0)
6/18	4	(33.3)	0	(0)
6/24	1	(8.3)	1	(8.3)
6/36	2	(16.7)	2	(16.7)
6/60	2	(16.7)	3	(16.7)
<CF	3	(25.0)	6	(50.0)

Table 3 Pre and post-TTT visual acuity occult membranes

Snellen VA	Pre-TTT		Post-TTT	
	No	(%)	No	(%)
6/6	0	(0)	1	(2.3)
6/9	3	(9.4)	3	(9.4)
6/12	4	(12.5)	2	(6.3)
6/18	3	(9.4)	0	(0)
6/24	5	(15.6)	3	(9.4)
6/36	4	(12.5)	8	(25.0)
6/60	8	(25.0)	6	(18.8)
<CF	5	(15.6)	9	(28.1)

1–200 mW if further treatment was necessary. In patients with large lesions, confluent overlapping treatments were given.

EVALUATION

Follow up was arranged at 2, 4, 6 weeks and 3, 6, 9, 12, and 18 months. At each visit Snellen visual acuity and retinal examination were performed with fundus photography and fluorescein angiography, if clinically indicated. Retreatment was given to patients who retained active membranes for more than 4 weeks following TTT.

STATISTICAL ANALYSIS

Outcomes measured were clinical or angiographic resolution and visual acuity. The results are presented in terms of percentage of membranes resolved and number of lines of vision lost within each group. The amount of visual deterioration was assessed using Wilcoxon's rank sum test on the Snellen data. Correlation between the visual acuity and the size of the CNV was performed using the Fisher's R-Z correlation.

Results

BASELINE CHARACTERISTICS:

The patient characteristics are summarised in Table 1; 44 eyes of 42 patients were treated. The mean patient age was 77.9 years (SD 8.38 years); 12 (27%) membranes were classic and 32 (73%) were occult with a mean area of 1.7 DA (range of 0.5–4.0 DA). Of the classic membranes one was extrafoveal, two were juxtafoveal, and nine were subfoveal. There was no correlation between visual acuity and size of CNV $Z = -1.23$ $p=0.2$. Haemorrhage was present in 7/12 of the classic membranes and 22/32 of the occult membranes. Seven patients were pseudophakic and two had glaucoma treated with timolol 0.25% BD. Table 1 shows the baseline data.

TREATMENT

The average number of treatments sessions was 1.80 (SD 0.87) spread over 1–6 months.

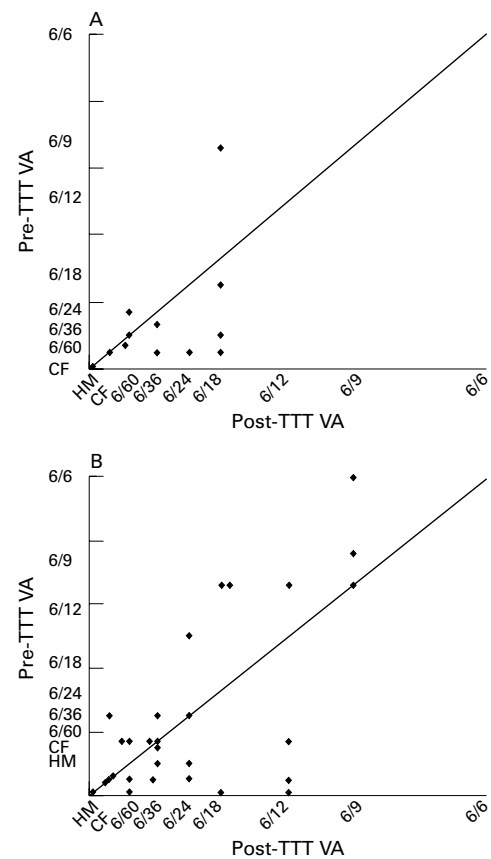


Figure 4 (A) Change in visual acuity following transpupillary thermotherapy for classic CNV. There was no significant deterioration in vision between the pretreatment group (VA = 6/32.4) and the post-treatment group (6/40) ($p=0.1$). (B) Change in visual acuity following transpupillary thermotherapy for occult CNV. There was no significant deterioration in vision between the pretreatment group (VA = 6/24.0) and the post-treatment group (6/26.4) ($p=0.1$).

The average power was 486 mW (140), with a beam diameter of 1.69 mm (0.63). Eyes received 4.25 (1.9) laser spots per treatment. Two patients were noted to have a significant post-treatment haemorrhage, no patients complained of pain, although some sensation was common. No anterior segment damage was noted or reported by the patients. Clinical examples of the treatment of occult and classic membranes are shown in Figures 1–3.

PATIENT OUTCOME

Predominantly classic membranes

Predominantly classic membranes were closed in 9/12 (75%, CI: 62.5–87.5) eyes and remained persistent in 3/12 (25%, 95% CI: 12.5–37.5) with no recurrences; with an average follow up of 6.7 months (SD 4.33, range 3–19) and 1.75 treatments. The initial visual acuity was 6/32.4 with a post-treatment acuity of 6/40.5 ($p=0.17$), an average of 0.75 (SD 1.75) Snellen lines lost (Fig 4A). Vision improved (>2 lines) in 0/12 patients, was stabilised (0 to +1 line) in 7/12 (58.1%, 95% CI: 44.1–72.5) patients, there was mild loss (–1 line) in 1/12 patients (8.1% 95% CI: 3.5–16.3), and four patients lost vision (2–4 lines) 33.3% (95% CI: 19.7–46.9) (Table 2).

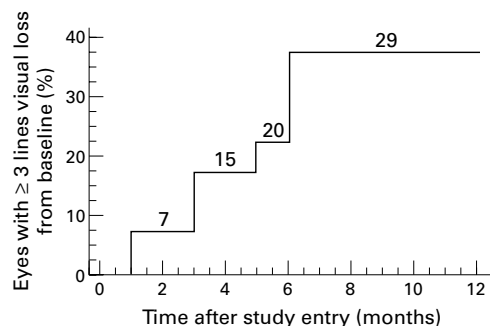


Figure 5 Kaplan-Meier estimates of the cumulative proportion of eyes treated with TTT with moderate visual acuity loss (≥ 3 Snellen lines).

Predominantly occult membranes

Predominantly occult membranes were closed in 25/32 (78%, CI: 70.1–85.3) eyes, remained persistent in 4/32 (12.5%, CI: 6.6–18.5), and were recurrent in 3/32 (5.1%, CI: 4.2–14.3) eyes; at an average follow up of 7.2 months (SD 4.33 range 3–18) and 1.8 treatments. The initial visual acuity was 6/24 with a post-treatment acuity of 6/26.4 ($p=0.68$), an average of 0.66 (SD 2.1) Snellen lines lost (Fig 4B). The vision improved (2+ lines) in 4/32 (12.5%, CI: 6.6–18.3) patients, 14/32 (43.8%; CI: 34.9–52.5) were stable (0 to +1 line), there was mild loss (–1 line) in 5/32 patient (15.6% 95% CI: 9.2–25.6), 6/32 (19.2% CI: 11.8–25.6) had moderate loss (2–4 lines), and 3/32 eyes (9.5% CI: 4.2–14.5) eyes had severe visual loss (Table 3). A Kaplan-Meier estimate of a three line change in vision is shown in Figure 5.

Discussion

The results from this study show that TTT is effective in closing membranes in patients with CNV. Seventy seven per cent of membranes were closed at 6 months and only 7.1% developed recurrent CNV. This high closure rate was associated with a stabilisation or improvement in vision in 71% of patients with occult disease and 67% of patients with classic disease. These results compare well with the natural history of occult CNV where 63% of patients suffered 3 or more lines of visual loss in the first 6 months²⁸ and to the MPS study of classic membranes, where recurrence rates of 59% were reported.¹⁰

Early clinical work recently published by Reichel *et al* have shown encouraging results for patients with occult subfoveal CNV.²⁷ They followed 16 eyes of 15 patients for 13 months following TTT for occult subfoveal CNV: 3/16 eyes experienced a 2+ line improvement, 9/16 stabilisation of vision (+/– 1 line) and 4/16 showed a significant decrease (>1 line). Optical coherence tomography and fluorescein angiography demonstrated resolution of the membranes. This compares with our findings that moderate loss of >2 lines occurred in 33% and severe loss >5 lines occurred in 0% of our patients with occult disease.

Results from this study compare well with the natural history of occult disease²⁹ and the recently reported results from the TAP study group, which evaluated photodynamic therapy (PDT) for predominantly classic membranes.¹⁴

Table 4 Chart of closure rate and visual acuity results at 6 months for TTT, PDT¹⁴ and argon laser photocoagulation of subfoveal membranes¹

Treatment	Closure rate	Visual loss /lines
Argon laser	72%	–3.25
PDT	11.6%	–1.0 (3 months)
TTT	74%	–0.78

Their results show that, at 12 months, PDT stabilised vision in 61.2% (<3 lines lost) of the treatment group compared with 46% of the control group. The visual results of our study are comparable; 75% of patients, with predominantly classic membranes, having <3 lines of visual loss. However, TTT closed a higher proportion of CNV at 6 months (75%) compared with PDT (19%), and the control group (9%).

The MPS demonstrated that argon laser photocoagulation was effective in closing classic membranes (72% at 6 months) but that this was associated with visual loss for subfoveal membranes. TTT may therefore combine the high rate of closure found with argon photocoagulation and the low recurrence rate with PDT, by closing CNV without damaging the neuroretina. Table 4 shows a comparison of the results between argon laser photocoagulation, photodynamic therapy, and transpupillary thermotherapy.

Transpupillary thermotherapy uses hyperthermia to disrupt the neovascular process and has been widely used for the treatment of small choroidal melanoma.^{25 26} The laser is set to a low power with long pulse duration, the aim being to produce a moderate intralésional temperature rise (4–9°C), compared with 40°C for conventional laser photocoagulation. The lower temperature rise confines the thermal damage profile in the target tissue, thereby reducing damage to the middle and inner retina. Conventional photocoagulation may cause dense scotomata and recurrence following argon laser photocoagulation, particularly when treating subfoveal CNV. A large spot (0.8–3 mm) size, and a long low energy pulse enables complete treatment of the lesion and allows dose titration. The mechanism of action with TTT is still unclear. However, histological sections of treated human melanoma have demonstrated intravascular thrombosis,^{30 31} which may account for the small amount of leakage, or haemorrhage following CNV treatment. Vascular closure may be precipitated by release of cytotoxic free radicals released from irradiated tissue. Certainly the relatively rapid involution of the CNV following TTT prevents further subretinal scarring and permanent photoreceptor damage, thereby limiting central scotomata in patients with subfoveal membranes.

The treatment variables have not been completely elucidated. In contrast with Reichel *et al*²⁷ we used several spots during one treatment session (average 4.25). It is clear that the end point is clinically difficult to determine (as there is little retinal reaction) and that treatment parameters may need to be adjusted for the degree of neurosensory retinal detach-

ment and the amount of subretinal haemorrhage, as well as for the location of the CNV.

Several complications have been reported following TTT for uveal tumours, including branch retinal vein and artery occlusions and retinal and choroidal haemorrhage. There also have been reports of ciliary nerve damage and corneal ulceration following panretinal photocoagulation.³² However, low power settings used in TTT for CNV have meant that complications are rare and patient tolerance is good.

The precise role of TTT in the treatment of CNV needs to be further defined. However, the clinical improvement found in several of our patients and the high closure rate of occult CNV membranes, with little recurrence, suggest that this treatment will have a role in the management of some patient groups. Prospective, randomised controlled trials will further clarify the role of TTT in the treatment of CNV.

We thank Dr Lyn Jenkins for coordination of angiography and image processing; Iris Medical for the loan of an OcuLight 810 nm diode laser; and Colin Clements, medical photographer, King's College Hospital, London.

- 1 Macular Photocoagulation Study Group. Visual outcome after laser photocoagulation for subfoveal choroidal neovascularization secondary to age-related macular degeneration. *Arch Ophthalmol* 1994;**112**:480-8.
- 2 Vingerling J, Dielemans I, Hoffman A, et al. The prevalence of age-related macular degeneration in the Rotterdam Study. *Ophthalmology* 1995;**102**:205-10.
- 3 Freund BK, Yannuzzi LA, Sorenson JA. Age-related macular degeneration and choroidal neovascularization. *Am J Ophthalmol* 1993;**115**:786-91.
- 4 Ferris III F, Fine S, Hyman L. Age-related macular degeneration and blindness due to neovascular maculopathy. *Arch Ophthalmol* 1984;**102**:1640-2.
- 5 Macular Photocoagulation Study Group. Visual outcome after laser photocoagulation for subfoveal choroidal neovascularization secondary to age-related macular degeneration: the influence of initial lesion size and initial visual acuity. *Arch Ophthalmol* 1994;**112**:480-8.
- 6 Macular Photocoagulation Study Group. Laser photocoagulation of subfoveal neovascular lesions in age-related macular degeneration: results of a randomized clinical trial. *Arch Ophthalmol* 1991;**109**:1220-31.
- 7 Macular Photocoagulation Study Group. Occult choroidal neovascularization. Influence on visual outcome in patients with age related macular degeneration. *Arch Ophthalmol* 1996;**114**:400-12.
- 8 Macular Photocoagulation Study Group. Argon laser photocoagulation for neovascular maculopathy: five-year results from randomized clinical trials. *Arch Ophthalmol* 1991;**109**:1109-14.
- 9 Macular Photocoagulation Study Group. Krypton laser photocoagulation for neovascular lesions of age-related macular degeneration. Results of a randomized clinical trial. *Arch Ophthalmol* 1990;**108**:816-24.
- 10 Macular Photocoagulation Study Group. Recurrent choroidal neovascularization following argon laser photocoagulation for neovascular maculopathy. *Arch Ophthalmol* 1986;**104**:503-12.
- 11 Schmidt-Erfuth U, Milier J, Sickenberg, M, et al. Photodynamic therapy of subfoveal choroidal neovascularization: clinical angiographic examples. *Graefes Arch Clin Exp Ophthalmol* 1998;**236**:365-74.
- 12 Schmidt-Erfuth U, Hasan T, Schomacker K, et al. Vascular targeting in photodynamic occlusion of subretinal vessels. *Ophthalmology* 1994;**101**:153-61.
- 13 Miller J, Schmidt-Erfuth U, Sickenberg M. Photodynamic therapy of subfoveal choroidal neovascularization in age-related macular degeneration with verteporfin. *Arch Ophthalmol* 1999;**117**:1329-45.
- 14 Treatment of Age-related Macular Degeneration with Photodynamic Therapy (TAP) Study Group. Photodynamic therapy of subfoveal choroidal neovascularization in age-related macular degeneration with verteporfin one-year results of 2 randomized clinical trials—TAP Report 1. *Arch Ophthalmol* 1999;**117**:1329-45.
- 15 Hart P, Chakravarthy U, MacKenzie G, et al. Teletherapy for subfoveal choroidal neovascularisation of age-related macular degeneration: results of follow up in a non-randomised study. *Br J Ophthalmol* 1998;**80**:1046-50.
- 16 Pharmacological Therapy for Macular Degeneration Study Group. Interferon alfa-2a is ineffective for patients with choroidal neovascularization secondary to age-related macular degeneration. Results of a prospective randomized placebo-controlled clinical trial. *Arch Ophthalmol* 1997;**115**:865-72.
- 17 Fujikado T, Ohji M, Hayashi A, et al. Anatomic and functional recovery of the fovea after foveal translocation surgery without large retinotomy and simultaneous excision of a neovascular membrane. *Am J Ophthalmol* 1998;**126**:839-42.
- 18 Wolf S, Lappas A, Weinberger A, et al. Macular translocation for surgical management of subfoveal choroidal neovascularizations in patients with AMD: first results. *Graefes Arch Clin Exp Ophthalmol* 1999;**237**:51-7.
- 19 Roth D, Downie A, Charles S. Visual results after submacular surgery for neovascularization in age-related macular degeneration. *Ophthalmic Surg Lasers* 1997;**28**:920-5.
- 20 Berger J. Thermal modeling of micropulsed diode laser retinal photocoagulation. *Lasers Surg Med* 1997;**20**:409-15.
- 21 Ulbig M, McHugh J, Hamilton P. Photocoagulation of choroidal neovascular membranes with a diode laser. *Br J Ophthalmol* 1993;**77**:218-21.
- 22 Reichel E, Puliafito C, Duker J, et al. Indocyanine green dye-enhanced diode laser photocoagulation of poorly defined subfoveal choroidal neovascularization. *Ophthalmic Surg* 1994;**25**:365-74.
- 23 Ulbig M, McHugh D, Hamilton P. Diode laser photocoagulation for diabetic macular oedema. *Br J Ophthalmol* 1995;**79**:318-21.
- 24 Akduman L, Olk R. Diode laser (810 nm) versus argon green (514 nm) modified grid photocoagulation for diffuse diabetic macular edema. *Ophthalmology* 1997;**104**:1433-41.
- 25 Shields C, Shields J, Cater J, et al. Transpupillary thermotherapy for choroidal melanoma. Tumor control and visual results in 100 consecutive cases. *Ophthalmology* 1998;**103**:2142-51.
- 26 Oosterhuis J, Journee-de Kover H, Kakebeeke-Kemme H, et al. Transpupillary thermotherapy in choroidal melanomas. *Arch Ophthalmol* 1995;**113**:315-21.
- 27 Reichel E, Berrocal A, Ip M, et al. Transpupillary thermotherapy of occult subfoveal choroidal neovascularization in patients with age related macular degeneration. *Ophthalmology* 1999;**106**:1908-14.
- 28 Mainster MA, White TJ, Tips JH, et al. Retinal-temperature increase produced by intense light sources. *J Opt Soc Am* 1970;**60**:264-70.
- 29 Bressler N, Frost L, Bressler S, et al. Natural course of poorly defined choroidal neovascularization associated with macular degeneration. *Arch Ophthalmol* 1988;**106**:1537-42.
- 30 Journee-de-Korver J, Oosterhuis J, de Wolff-Rouendal D, et al. Histopathological findings in human choroidal melanoma after transpupillary thermotherapy. *Br J Ophthalmol* 1997;**81**:234-9.
- 31 Coleman D, Silverman R, Iwamoto T, et al. Histopathologic effects of ultrasonically induced hyperthermia in intraocular malignant melanoma. *Ophthalmology* 1988;**95**:970-81.
- 32 Buckley S, Parmar D, McHugh J, et al. Anterior segment complications of indirect diode laser in diabetic patients. *Br J Ophthalmol* 1998;**82**:1447-8.

MAILBOX

Acute posterior vitreous detachment

EDITOR,—We read Tanner *et al*'s paper on the predictive value of vitreous pigment (Schaffer's sign) for retinal breaks in posterior vitreous detachment¹ with great interest. Based on their figures, patients who have a negative Schaffer's sign had a 1% chance of having a retinal tear or hole and a 0.5% chance of having a lesion where prophylaxis was thought to be appropriate. Thus, Schaffer's sign has a negative predictive value of 99% in their series. They go on to recommend that if vitreous pigment is present then the patient should be referred for urgent vitreoretinal opinion while those with no pigment should be referred on a less urgent basis.

We would like to put these findings in perspective. The incidence of retinal breaks in patients aged 10 years or more who do not have any history of ocular disease is 6–14%.² Retinal breaks have been found in 37/250 (14.8%) of necropsy eyes with posterior vitreous detachment by Foos.³ The incidence of retinal detachment is approximately 12/100 000 of the general population per year.⁴ This suggests that less than 0.2% people with a retinal break eventually have a detachment of the retina. This value may be higher in patients with a symptomatic posterior vitreous detachment; however, it is reasonable to conclude that only a minority of retinal breaks will go on to cause a retinal detachment. Prophylactic treatment of retinal breaks by laser or cryotherapy is not without complications; also detachments can occur in eyes that have had prophylactic treatment.⁵ Byer has reported that retinal breaks in unoperated eyes with posterior vitreous detachment that need treatment can be followed up without treatment, with only a minority progressing to retinal detachments.⁶

We have a test that has a negative predictive value of 99%. We know that only a minority of patients who have a retinal tear or hole actually benefit from prophylactic treatment. Can we still justify referring all patients with a posterior vitreous detachment and no vitreous pigment for a specialist examination or even a follow up examination in the light of this knowledge?

The appropriate recommendation would be that all patients presenting with posterior vitreous detachment, no vitreous pigment, and no retinal tears or holes at initial examination can be safely discharged with an explanation of the warning symptoms which should prompt the patient to reattend.

M GUPTA
S PRASAD

Department of Ophthalmology, Royal Hallamshire Hospital, Glossop Road, Sheffield S10 2JF, UK

Correspondence to: Mr Mohit Gupta

- 1 Tanner V, Harle D, Tan J, *et al*. Acute posterior vitreous detachment: the predictive value of vitreous pigment and symptomatology. *Br J Ophthalmol* 2000;**84**:1264–8.
- 2 Byer NE. Clinical study of retinal breaks. *Trans Am Acad Ophthalmol Otolaryngol* 1967;**71**:461–73.
- 3 Foos RY. Posterior vitreous detachment. *Trans Am Acad Ophthalmol Otolaryngol* 1972;**76**:480–97.
- 4 Haiman MH, Burton TC, Brown CK. Epidemiology of retinal detachment. *Arch Ophthalmol* 1982;**100**:289–92.
- 5 Schroeder W, Baden H. Retinal detachment despite preventive coagulation. *Ophthalmology* 1996;**93**:144–8.

- 6 Byer NE. What happens to untreated asymptomatic retinal breaks, and are they affected by posterior vitreous detachment. *Ophthalmology* 1998;**105**:1045–9.

Reply

EDITOR,—We thank Gupta and Prasad for their interest and comments on our recent paper.¹ We agree that the majority of retinal breaks probably do not progress to cause retinal detachment but suggest caution in the interpretation of data relating to asymptomatic rather than symptomatic tears, the latter having been shown to be associated with subsequent retinal detachment in approximately 30% of cases.² It is the management of recent onset, symptomatic posterior vitreous detachment (PVD) and associated retinal breaks which we addressed in our study. The rationale for treating fresh, symptomatic retinal breaks has been reviewed by numerous authors and is best summarised in the recent preferred practice pattern document produced by the American Academy of Ophthalmology.³

The purpose of our study was to provide help to those practitioners seeing large numbers of patients with acute PVD, but who do not feel confident in the use of indentation ophthalmoscopy. The presence of vitreous pigment in patients presenting with acute PVD is indeed highly predictive of the presence of a retinal break, but a thorough retinal examination is still necessary.

In our series only one patient represented with a retinal break which had not been identified during initial indentation ophthalmoscopy. We agree that no routine follow up examination is required in most cases, provided a retinal break has been confidently excluded with indentation ophthalmoscopy and the PVD is judged to be complete, but that patients should be warned to reattend if further symptoms occur.⁴

V TANNER
A H CHIGNELL

- 1 Tanner V, Harle D, Tan J, *et al*. Acute posterior vitreous detachment: the predictive value of vitreous pigment and symptomatology. *Br J Ophthalmol* 2000;**84**:1264–8.
- 2 Davies MD. Natural history of retinal breaks without detachment. *Arch Ophthalmol* 1974;**92**:183–94.
- 3 American Academy of Ophthalmology. *Management of posterior vitreous detachment, retinal breaks and lattice degeneration. Preferred practice pattern*. San Francisco: AAO, 1997.
- 4 Richardson PS, Benson MT, Kirkby GR. The posterior vitreous detachment clinic: do new retinal breaks develop in the six weeks following an isolated symptomatic posterior vitreous detachment? *Eye* 1999;**13**:237–40.

BOOK REVIEW

Anterior Segment Intraocular Inflammation (ASII): Guidelines. Eds BenEzra D, Ohno S, Secchi AG, Ali JL. Pp 216; £35. London: Martin Dunitz, 2000. ISBN 1853179604.

Anterior uveitis is an important and common cause of ocular morbidity. Drs BenEzra, Ohno, Secchi, and Ali along with their contributors, Drs De Kozak, Forrester,

Caspers-Velu, LeHoang, McCluskey, Okada, and Whitcup provide a comprehensive yet concise summary of this field in their recently released text, which was prepared under the auspices of the International Ocular Inflammation Society. Each of the eight chapters contained in this book are clearly written, well referenced, and accompanied by a number of very nice tables and illustrations, many of which are in full colour. Although by no means encyclopaedic, this manual includes excellent overviews of the clinical characteristics of all of the important causes of anterior uveitis, as well as systematic approaches to diagnosis, treatment, and surgery in patients with anterior uveitis.

EMMETT T CUNNINGHAM, JR

NOTICES

Vision 2020: cataract outcomes

The latest issue of *Community Eye Health* (35) discusses cataract surgery outcome. For further information please contact *Community Eye Health*, International Centre for Eye Health, Institute of Ophthalmology, 11–43 Bath Street, London EC1V 9EL. (Tel: (+44) (0) 20-7608 6909/6910/6923; fax: (+44) (0) 7250 3207; email: eyesource@ucl.ac.uk) Annual subscription £25. Free to workers in developing countries.

Second Sight

Second Sight, a UK based charity whose aims are to eliminate the backlog of cataract blind in India by the year 2020 and to establish strong links between Indian and British ophthalmologists, will be sending volunteer surgeons to India early in 2001. Details can be found at the charity website at www.second-sight.org.uk or by contacting Dr Lucy Mathen (email address lucymathen@yahoo.com).

Office of Continuing Medical Education

A symposium "Randomised trials in ophthalmology: past, present, future" will be held 2–3 April 2001 at the Thomas B Turner Building, Johns Hopkins University School of Medicine, Baltimore, Maryland, USA. Further details: Johns Hopkins University School of Medicine, Office of Continuing Medical Education, Turner 20, 720 Rutland Avenue, Baltimore, MD 21205-2195, USA (tel: (410) 955-2959; fax: (410) 955-0807; email: cmenet@jhmi.edu).

XXV Detachment Course

The XXV Detachment course, retinal and vitreous surgery, will be held in Poznan, Poland on 5–6 April 2001. Further details: Professor Krystyna Pecold, Katedra I Klinika Okulistyki, ul Długa 1/2, 61–848 Poznan, Poland (tel/fax: 004861-8527619) or Professor Ingrid Kreissig, Univ-Augenklinik, Schleichstrasse 12, D-72076 Tuebingen, Germany (fax: 49-7071-293746; email: ingrid.kreissig@uni-tuebingen.de).

Optometry 01

Optometry 01 will take place on 21–23 April 2001 with more than 100 events—lectures and workshops—at the Atrium Gallery, NEC, Birmingham, UK. Further details: tel: 0207 261 9661; email: info@Optometry01.co.uk; website: www.optometry01.co.uk.

14th Annual Meeting of German Ophthalmic Surgeons

The 14th Annual Meeting of German Ophthalmic Surgeons will be held in the Meistersingerhalle, Nuremberg, Germany on 17–20 May 2001. Further details: MCN Medizinische Congress-organisation Nuremberg AG, Zerzabelshofstrasse 29, 90478 Nuremberg, Germany (tel: ++49-911-3931621; fax: ++49-911-3931620; email: doerflinger@mcn-nuernberg.de).

European Association for the Study of Diabetic Eye Complications (EASDEC)

The next meeting of the European Association for the Study of Diabetic Eye Complications (EASDEC) will be held in Paris, France, on 19–20 May 2001. Further details: Colloquium, 12 Rue de la Croix Faubin, 75 557 Paris Cedex 11, France (tel: +33-1-44 64 15 15; fax +33-1-44 64 15 10; email: s.mundler@colloquium.fr).

2nd Interdisciplinary Symposium on the Treatment of Autoimmune Disorders 2001

The 2nd Interdisciplinary Symposium on the Treatment of Autoimmune Disorders 2001 will take place on 7–9 June 2001 at the University Hospital, University of Kiel, Kiel, Germany. Further details: Prof Dr Med Michael Sticherling, Department of Dermatology, University of Kiel, Schittenhelmstrasse 7, D-24105 Kiel, Germany (tel: +49-431 597 1512; fax: +49-431 597 1611; email: msticherling@dermatology.uni-kiel.de).

14th World Congress of the International Society for Laser Surgery and Medicine

The 14th World Congress of the International Society for Laser Surgery and Medicine is to be held on the 27–30 August 2001 at Sri Ramachandra Medical College and University Hospital, Chennai, India. The American Society of Lasers in Medicine and Surgery has indicated that it will designate the 14th World Congress of ISLSM as its society's co-sponsoring meeting. A pre-conference course and separate sessions in ophthalmology will be held as a part of this international meeting.

Further details: Dr B Krishna Rau, President, 14th World Congress of the International Society for Laser Surgery and Medicine, Department of Surgery, D2 Ward, Sri Ramachandra Medical College and Research Institute, Porur, Chennai - 600 116, India (tel: 91-44-4765856, 4768027-28, 8527776, 8594804; fax: 91-44-8594578, 4767008; email: krishnar@giasmd01.vsnl.net.in and website: www.medindia.net/islsm2001).

American Institute of Ultrasound in Medicine—Millennium Ultrasound Course Series

A course entitled "Obstetrical and Gynecological Ultrasound" will be held in New York City, NY, on 24–26 August 2001. Further details: Stacey Bessling, Public Relations Coordinator, AIUM, 14750 Sweitzer Lane, Suite 100, Laurel, MD 20707-5906, USA (tel: 301-498-4100; email: sbessling@aium.org).

31st Cambridge Ophthalmological Symposium

The 31st Cambridge Ophthalmological Symposium will be held 3–5 September 2001 at St John's College Cambridge. The subject is Retinal Detachment. Further details: COS Secretariat, Cambridge Conferences, The Lawn, 33 Church Street, Great Shelford, Cambridge CB2 5EL, UK (tel: 01223 847464; fax: 01223 847465; email: b.ashworth@easynet.co.uk).

1st Asia Pacific Forum on Quality Improvement in Health Care

The 1st Asia Pacific Forum on Quality Improvement in Health Care will be held from 19–21 September 2001 in Sydney, Australia. Presented by the BMJ Publishing Group (London, UK) and Institute for Healthcare Improvement (Boston, USA), with the support of the Commonwealth Department of Health and Aged Care (Australia), Safety and Quality Council (Australia), NSW Health (Australia) and Ministry of Health (New Zealand). Further details: quality@bma.org.uk; fax +44 (0) 7383 6869.

41st St Andrew's Day Festival Symposium on Therapeutics

The 41st St Andrew's Day Festival Symposium on Therapeutics will be held on 6–7 December 2001 at the Royal College of Physicians of Edinburgh. Further details: Ms Eileen Strawn, Symposium Co-ordinator (tel: 0131 225 7324; fax: 0131 220 4393; email: e.strawn@rcpe.ac.uk; website: www.rcpe.ac.uk).

4th International Conference on the Adjuvant Therapy of Malignant Melanoma

The 4th International Conference on the adjuvant therapy of malignant melanoma will be held at The Royal College of Physicians, London on 15–16 March 2002. Further details: Conference Secretariat, CCI Ltd, 2 Palmerston Court, Palmerston Way, London SW8 4AJ, UK (tel: + 44 (0) 20 7720 0600; fax: + 44 (0) 20 7720 7177; email: melanoma@confcomm.co.uk; website: www.confcomm.co.uk/Melanoma).

XXIXth International Congress of Ophthalmology

The XXIXth International Congress of Ophthalmology will be held on 21–25 April 2002 in Sydney, Australia. Further details: Congress Secretariat, C/- ICMS Australia Pty Ltd, GPO Box 2609, Sydney, NSW 2001, Australia (tel: +61 2 9241 1478; fax: +61 2 9251 3552; email: ophthal@icmsaust.com.au; website: www.opthalmology.aust.com).

International Society for Behçet's Disease

The International Society for Behçet's Disease was inaugurated at the 9th International Congress on Behçet's Disease. Professor Shigeaki Ohno represents the ophthalmology division (Department of Ophthalmology and Visual Sciences, Hokkaido University Graduate School of Medicine, Sapporo, Japan: tel: +81-11-716-1161 (ext 5944); fax +81-11-736-0952; email: sohno@med.hokudai.ac.jp). The 10th International Congress on Behçet's Disease will be held in Berlin 27–29 June 2002. Further details: Professor Ch Zouboulis (email: zoubbere@zedat.fu-berlin.de).

CORRECTION

In the paper published in the February issue of the *BJO* (2001;85:173–8) by Newsom *et al*, there was an error in Figure 4 (p 176). The axes were wrongly labelled. The y axis should read Post-TT_a VA and the x axis should be Pre-TTT VA. We apologise for the error.



Transpupillary thermotherapy (TTT) for the treatment of choroidal neovascularisation

R S B Newsom, J C McAlister, M Saeed, et al.

Br J Ophthalmol 2001 85: 173-178

doi: 10.1136/bjo.85.2.173

Updated information and services can be found at:

<http://bjo.bmj.com/content/85/2/173.full.html>

Data Supplement

These include:

"Correction"

<http://bjo.bmj.com/content/suppl/2001/04/10/85.2.173.DC1.html>

References

This article cites 28 articles, 14 of which can be accessed free at:

<http://bjo.bmj.com/content/85/2/173.full.html#ref-list-1>

Article cited in:

<http://bjo.bmj.com/content/85/2/173.full.html#related-urls>

Email alerting service

Receive free email alerts when new articles cite this article. Sign up in the box at the top right corner of the online article.

Topic Collections

Articles on similar topics can be found in the following collections

[Choroid](#) (435 articles)

[Epidemiology](#) (766 articles)

[Retina](#) (1217 articles)

Notes

To request permissions go to:

<http://group.bmj.com/group/rights-licensing/permissions>

To order reprints go to:

<http://journals.bmj.com/cgi/reprintform>

To subscribe to BMJ go to:

<http://group.bmj.com/subscribe/>