

Retinal dystrophies caused by mutations in *RPE65*: assessment of visual functions

Christian P Hamel, Jean-Michel Griffoin, Laetitia Lasquelléc, Christian Bazalgette, Bernard Arnaud

Abstract

Aims—To characterise the disease in patients with mutations in *RPE65*.

Methods—Individuals from two families were studied clinically.

Results—13 and 20 year old compound heterozygote individuals from one family with R234X and 1121delA mutations showed nystagmus, macular dystrophy and low contrasted spots in the fundus. Some heterozygotes had macular drusen. A 40 year old compound heterozygote individual from another family with L22P and H68Y mutations had few bone spicule pigment deposits and macular atrophy.

Conclusion—Compound heterozygote individuals had severe rod-cone dystrophies featuring few pigment deposits in the fundus, pigment epithelium atrophy, and early involvement of the macula, with variations in severity leading to the diagnosis of Leber's congenital amaurosis or retinitis pigmentosa. Macular drusen in heterozygotes carrying a null allele may reflect the decreased capacity in the *RPE65* function.

(Br J Ophthalmol 2001;85:424-427)

Recently, genetic defects in *RPE65*, the gene coding the retinal pigment epithelium (RPE) specific protein RPE65, have been found.¹⁻⁶ There is evidence indicating that *RPE65* is involved in the isomerisation from all-*trans* to

11-*cis* retinol that occurs in the RPE.⁷ Here, we describe the observations of three compound heterozygote individuals and of their relatives (heterozygotes and normal homozygotes) carrying *RPE65* mutations.

Patients and methods

PATIENTS

In the three generation French family 1, 15 members, except II-1, were examined; in the two generation Italian family 2, only the proband (II-2) was examined (Fig 1). Results of the *RPE65* screening in both families has been reported previously.¹⁻⁴

METHODS

Standard ophthalmological examination was performed as well as colour vision testing, Goldmann perimetry, and fluorescein angiography. Full field electroretinogram (ERG) was recorded using a ganzfeld apparatus (Metrovision, France) and dark adaptometry was performed with a Goldmann-Weekers apparatus using a test seen with an angle of 11° according to the standard protocol.

Results

PATIENTS WITH MUTATIONS IN BOTH *RPE65* ALLELES (COMPOUND HETEROZYGOTES)

A 20 year old patient (III-2) from family 1 had nystagmus, night blindness, and inability to move alone since birth in the absence of systemic disease; her condition was reported as

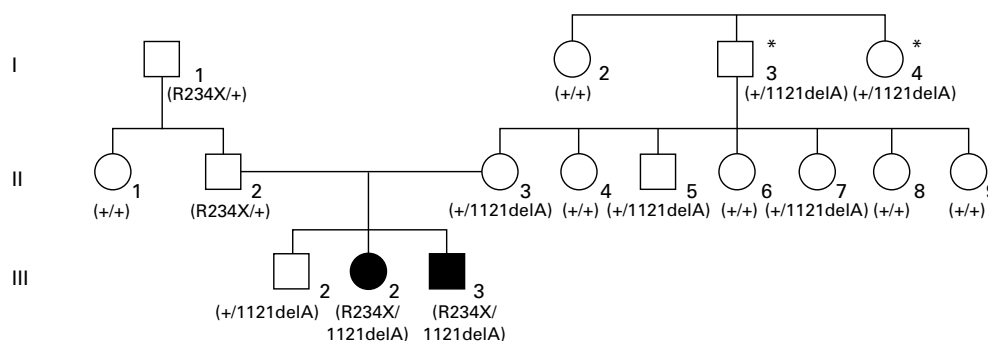
Service
d'ophtalmologie,
Hôpital Gui de
Chauliac, 80, avenue
Augustin Fliche, 34295
Montpellier cedex 5,
France
C P Hamel
L Lasquelléc
C Bazalgette
B Arnaud

Inserm U 254, 71, rue
de Navacelles, 34090
Montpellier, France
C P Hamel
J-M Griffoin

Correspondence to:
Christian P Hamel,
INSERM U 254, 71 rue de
Navacelles, 34090
Montpellier, France
hamel@montp.inserm.fr

Accepted for publication
13 October 2000

Family 1



Family 2

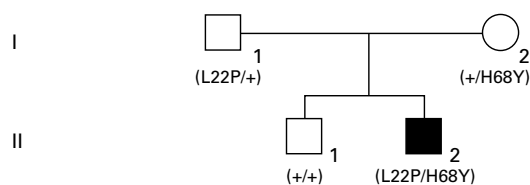


Figure 1 Pedigree of two families with members affected by either Leber's congenital amaurosis (family 1) or retinitis pigmentosa (family 2). Black symbols indicate clinically affected individuals, open symbols unaffected people. Individuals carrying age related macular degeneration are shown by an asterisk. Normal and disease allele carrier status is indicated for each family member.

Leber's congenital amaurosis. She was emmetropic with 4/200 and 2/200 in right and left eyes, respectively. She showed numerous yellowish spots throughout the fundus, narrowing of retinal vessels, moderate pallor of the optic discs, and macular atrophy (Fig 2A, B). She could not discriminate any colour. Photopic and scotopic ERGs were unrecordable. Her 13 year old brother (III-3) showed a similar ocular

history and symptoms, although he seemed to be slightly less severely affected (Fig 2C, D).

Patient II-2 from family 2, aged 40, had a medical history of retinitis pigmentosa. Although he reported night blindness since early childhood, he had no difficulty moving in daytime, and was reading fluently until aged 13. He had visual acuity of 6/200 with $-2.00/-2.00$ at 10° and 8/200 with $-1.50/-1.25$ at

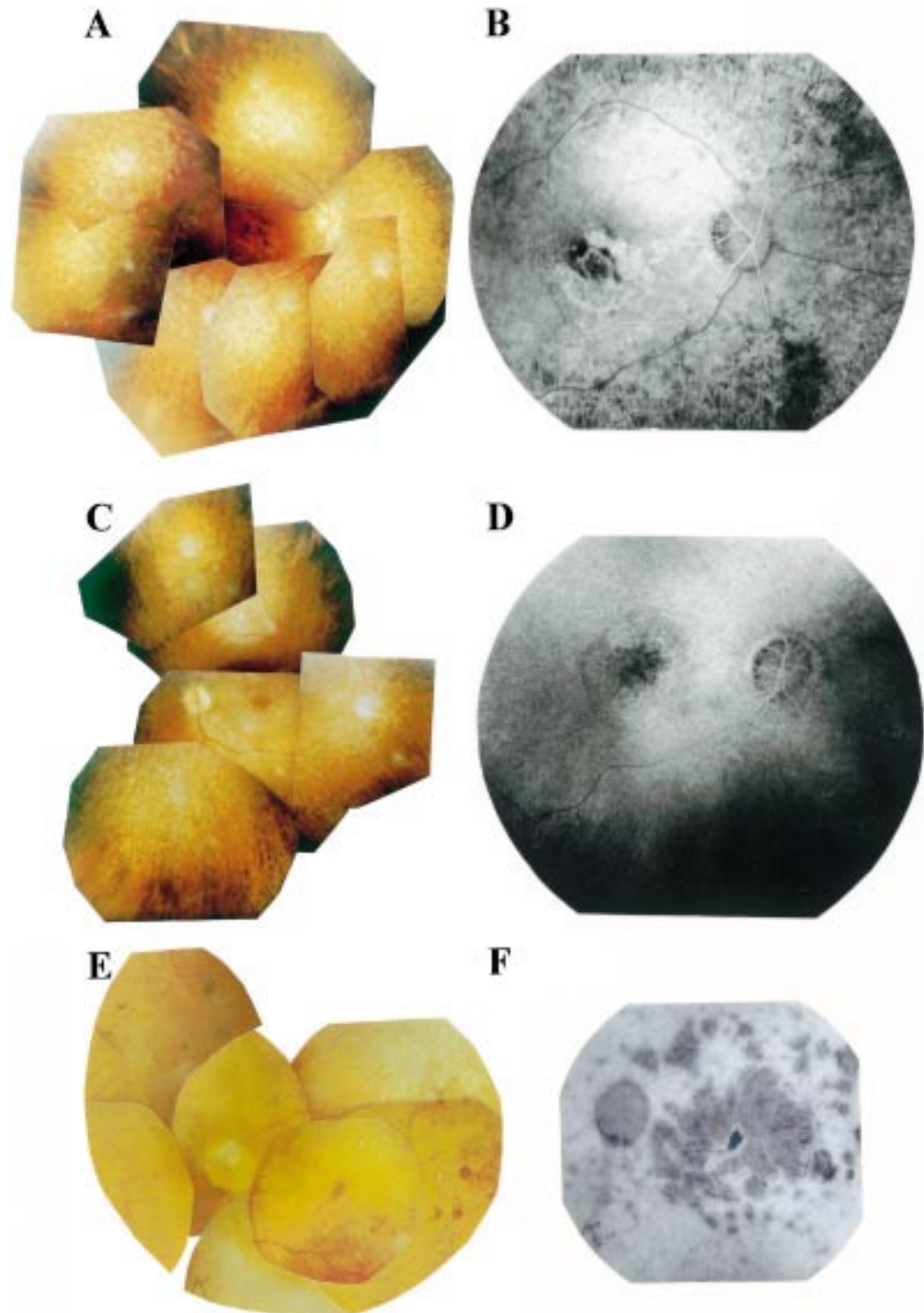


Figure 2 Fundus photographs (A, C, E) and fluorescein angiograms (B, D, F). Right eye of patient III-2 (A, B) and left (C) and right (D) eyes of patient III-3 from family 1, both affected with Leber's congenital amaurosis, exhibit yellowish spots, attenuation of retinal vessels, pallor of optic discs, either atrophy (B) or oedema (D) of the macula, and virtual absence of pigment deposits. Left eye of patient II-2 from family 2 (E, F) affected with retinitis pigmentosa shows rare pigment deposits, narrowing of retinal vessels, pallor of optic disc, and confluent patches of macular chorioretinal atrophy.

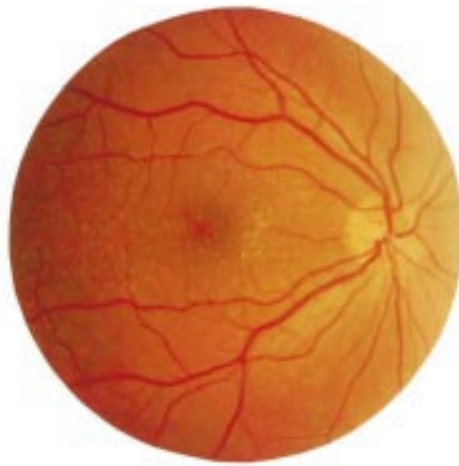

Figure 3 Right eye of 47 year old individual II-7 who is heterozygote (1121delA/+) shows many small macular drusen.

130° in right and left eyes, respectively. Fundus examination showed markedly attenuated retinal vessels, waxy pallor of optic discs, rather sparse bone spicule-shaped pigment deposits in midperiphery, and extended atrophy of the macula with patches of retinal pigment epithelium/choriocapillaris atrophy (Fig 2E, F). Tritanopia and restriction of the V_{4c} isoptre to 12° in each eye were also noted. ERG responses were undetectable.

HETEROZYGOTE INDIVIDUALS

Individuals with the R234X/+ genotype were unremarkable except for a few small macular drusen in I-1 who also had slightly diminished ERG rod responses. Dark adaptometry was within the normal range.

Six individuals carried the 1121delA/+ genotype. In the two heterozygotes from the first generation (I-3 and I-4), there were obvious signs of AMD with many large, soft drusen. By contrast, their normal homozygote sister (I-2) had no soft macular drusen. All three heterozygotes from the second generation had small macular drusen (Fig 3) with ERG rod responses slightly diminished in two of them (II-3 and II-5). Their normal homozygote sisters had no or few scattered drusen and normal ERGs. The only heterozygote from the third generation (III-1) had a normal fundus and his ERG rod response was at the lower limit of the normal value. Dark adaptometry from individuals III-1, II-5, and II-3 were within the normal limits.

Discussion

In patients with Leber's congenital amaurosis (LCA), visual acuity was still measurable, a feature recently described⁵ that distinguishes LCA2 (due to mutations in *RPE65*, OMIM No 204100) from LCA1 (due to mutations in *RETGC1*, OMIM No 204000). Night blindness, the absence of hyperopia, and slow worsening of the visual outcome, also characteristic of LCA2, were noted. These features closely resemble those of childhood onset severe retinal dystrophy (CSRSD) in which mutations in *RPE65* have also been found.² The RP phenotype found in one patient is infrequent in

RPE65 mutations since it has been described in only five unrelated cases,^{3 4 8} while more than 30 unrelated patients have been diagnosed as LCA^{1 3 5 6 9-12} or CSRSD.^{2 13 14} Published cases of LCA and CSRSD show that patients carry either translation terminating or missense mutations on both alleles, suggesting that in most cases a severe disease occurs, whatever the modification of the *RPE65* protein (absence, truncation, or change in amino acid).

Mutations in other RPE expressed genes involved in the retinol metabolism have been described including *RLBP1*, encoding cellular retinaldehyde binding protein (CRALBP), causing severe retinitis pigmentosa,¹⁵ retinitis punctata albescens,¹⁶ and Bothnia dystrophy,¹⁷ and *RDH5* encoding 11-*cis* retinol dehydrogenase, that leads to fundus albipunctatus.¹⁸ These conditions and those due to *RPE65* mutations are characterised by night blindness, few or no pigment deposits, areas of pigment epithelium atrophy, involvement of the macula, and often dot-like deposits in the fundus. These features are also quite similar to vitamin A deprived retinal dysfunction syndrome¹⁹ and to hereditary defect in retinol binding protein,²⁰ suggesting that impairment in the ocular metabolism of retinol predominantly affects rods. Macular involvement may reflect the greater density of rods over cones at the periphery of the macula.

We noted the presence of small macular drusen in individuals heterozygous for the 1121delA mutation, as found in heterozygous carriers with *TULP1* translation terminating mutations that cause early onset severe retinal degeneration in the homozygous state.²¹ The presence of these drusen suggests that mutation in one allele may indeed cause a moderate dysfunction in the outer retina and lead to a time dependent accumulation of materials.

We thank the families, SOS Rétinite (Montpellier, France) which provided financial support for this work and to one of us (J-M G), IRRP (Bordezac, France), as well as Hervé and Monique Offret, Maryse Bélis (Service d'ophtalmologie, Kremlin-Bicêtre), Christian Billotte, and Mrs Labarrière, Montagne, and Noury (Service d'ophtalmologie, Caen) for their help.

- 1 Marlhens F, Bareil C, Griffoin J-M, et al. Mutations in *RPE65* cause Leber's congenital amaurosis. *Nat Genet* 1997;17:139-41.
- 2 Gu S-M, Thompson DA, Srisailapathy Srikanth CR, et al. Mutations in *RPE65* cause autosomal recessive childhood-onset severe retinal dystrophy. *Nat Genet* 1997;17:194-7.
- 3 Morimura H, Fishman GA, Grover SA, et al. Mutations in the *RPE65* gene in patients with autosomal recessive retinitis pigmentosa or Leber congenital amaurosis. *Proc Natl Acad Sci USA* 1998;95:3088-93.
- 4 Marlhens F, Griffoin J-M, Bareil C, et al. Autosomal recessive retinal dystrophy associated with two novel mutations in the *RPE65* gene. *Eur J Hum Genet* 1998;6:527-31.
- 5 Perrault I, Rozet J-M, Ghazi I, et al. Different functional outcome of RetGC1 and *RPE65* gene mutations in Leber congenital amaurosis. *Am J Hum Genet* 1999;64:1225-8.
- 6 Lotery AJ, Nampurumalsamy P, Jacobson SG, et al. Mutation analysis of 3 genes in patients with Leber congenital amaurosis. *Arch Ophthalmol* 2000;118:538-43.
- 7 Redmond TM, Yu S, Lee E, et al. *Rpe65* is necessary for production of 11-*cis*-vitamin A in the retinal visual cycle. *Nat Genet* 1998;20:344-51.
- 8 Apfelstedt-Sylla E, Gu S, Gal A, et al. Clinical findings in patients with retinal dystrophies caused by mutations in *RPE65*. *Invest Ophthalmol Vis Sci* 1998;39:S967.
- 9 Simovich MJ, Miller BE, Fulmer C, et al. Novel mutations in the gene encoding *RPE65* in patients with Leber congenital amaurosis (LCA II). *Invest Ophthalmol Vis Sci* 1999;40:S470.
- 10 Pittler SJ, Miller BE, Simovich MJ. A homozygous Y44D change in the *RPE65* gene in a patient with Leber congenital amaurosis and keratoconus. *Invest Ophthalmol Vis Sci* 1999;40:S471.

- 11 Stockton DW, Lewis RA, Abboud EB, *et al.* Genetic heterogeneity of Leber congenital amaurosis in the Saudi Arabian population. *Invest Ophthalmol Vis Sci* 1999;40:S471.
- 12 Dharmaraj S, Silva E, Li YY, *et al.* Mutational analysis in one hundred consecutive patients with Leber congenital amaurosis. *Invest Ophthalmol Vis Sci* 1999;40:S565.
- 13 Gal A, Gu S, Bremser D, *et al.* Mutation spectrum of RPE65 in autosomal recessive childhood-onset severe retinal dystrophy. *Invest Ophthalmol Vis Sci* 1998;39:S901.
- 14 Thompson DA, Lorenz B, Gyürüs P, *et al.* RPE65 mutations in childhood-onset, severe retinal degenerations. *Invest Ophthalmol Vis Sci* 1999;40:S575.
- 15 Maw MA, Kennedy B, Knight A, *et al.* Mutation of the gene encoding cellular retinaldehyde-binding protein in autosomal recessive retinitis pigmentosa. *Nat Genet* 1997;17:198–200.
- 16 Morimura H, Berson EL, Dryja TP. Recessive mutations in the RLBP1 gene encoding cellular retinaldehyde-binding protein in a form of retinitis punctata albescens. *Invest Ophthalmol Vis Sci* 1999;40:1000–4.
- 17 Burstedt MS, Sandgren O, Holmgren G, *et al.* Bothnia dystrophy caused by mutations in the cellular retinaldehyde-binding protein gene (RLBP1) on chromosome 15q26. *Invest Ophthalmol Vis Sci* 1999;40:995–1000.
- 18 Yamamoto H, Simon A, Eriksson U, *et al.* Mutations in the gene encoding 11-cis retinol dehydrogenase cause delayed dark adaptation and fundus albipunctatus. *Nat Genet* 1999;22:188–91.
- 19 Fuchs A. White spots in the fundus combined with night blindness and xerosis (Uyemura's syndrome). *Am J Ophthalmol* 1959;48:101–3.
- 20 Seeliger MW, Biesalski HK, Wissinger B, *et al.* Phenotype in retinol deficiency due to a hereditary defect in retinol binding protein synthesis. *Invest Ophthalmol Vis Sci* 1999;40:3–11.
- 21 Lewis CA, Batlle IR, Batlle KGR, *et al.* Tubby-like protein 1 homozygous splice-site mutation causes early-onset severe retinal degeneration. *Invest Ophthalmol Vis Sci* 1999;40:2106–14.



Retinal dystrophies caused by mutations in *RPE65*: assessment of visual functions

Christian P Hamel, Jean-Michel Griffain, Laetitia Lasquelléc, et al.

Br J Ophthalmol 2001 85: 424-427

doi: 10.1136/bjo.85.4.424

Updated information and services can be found at:

<http://bjo.bmj.com/content/85/4/424.full.html>

References

These include:

This article cites 19 articles, 6 of which can be accessed free at:

<http://bjo.bmj.com/content/85/4/424.full.html#ref-list-1>

Article cited in:

<http://bjo.bmj.com/content/85/4/424.full.html#related-urls>

Email alerting service

Receive free email alerts when new articles cite this article. Sign up in the box at the top right corner of the online article.

Topic Collections

Articles on similar topics can be found in the following collections

[Eye \(globe\)](#) (538 articles)
[Retina](#) (1207 articles)
[Neurology](#) (1036 articles)
[Vision](#) (496 articles)

Notes

To request permissions go to:

<http://group.bmj.com/group/rights-licensing/permissions>

To order reprints go to:

<http://journals.bmj.com/cgi/reprintform>

To subscribe to BMJ go to:

<http://group.bmj.com/subscribe/>