

Corneal autofluorescence in choroidal melanoma or in choroidal naevus

R P H M Müskens, J A Van Best, J C Bleeker, J E E Keunen

Abstract

Aims—To investigate whether corneal autofluorescence is different in patients with choroidal melanoma or choroidal naevus.

Methods—Corneal autofluorescence was determined by fluorophotometry in both eyes of 32 patients with a unilateral choroidal melanoma, 32 patients with a unilateral choroidal naevus, and 32 age matched healthy controls. The corneal autofluorescence ratio between affected and contralateral eyes of patients or between randomly selected eyes of healthy controls was calculated.

Results—Mean corneal autofluorescence ratio of patients with a choroidal melanoma was significantly higher than that of healthy controls (mean ratio: 1.09 (SD 0.15) and 1.00 (0.09), respectively, ANOVA $p=0.014$), and than that of patients with choroidal naevus (mean ratio 0.96 (0.09), $p<0.001$). Mean ratios of patients with choroidal naevus and healthy controls were not significantly different ($p=0.27$).

Conclusions—Corneal autofluorescence ratio of patients with a unilateral choroidal melanoma is increased. This is probably due to an increased flow of glucose through the impaired blood-aqueous barrier in the affected eye, resulting in additional glycation of corneal proteins and hence in increased autofluorescence. The corneal autofluorescence is not increased in patients with a choroidal naevus, because the blood-aqueous barrier is not impaired in the affected eye in these patients. Measurement of corneal autofluorescence is simple, fast, and non-invasive, and might be helpful to distinguish between patients with choroidal melanoma and those with choroidal naevus.

(Br J Ophthalmol 2001;85:662-665)

Even though choroidal melanoma is the most common primary malignant tumour of the eye in adults, it remains a rare condition, with an incidence of eight per million per year in the Netherlands. For this reason most ophthalmologists see only a few patients with a choroidal melanoma in their working life.¹ In approximately 50% of patients with localised tumours, the choroidal melanoma is treatable, and preservation of vision is possible with current treatment techniques. Prognostic factors are, for instance, the size of the tumour, tumour location, the cell type, nucleus size,

pigmentation, age of onset, number of mitosis, and extraocular extension.^{2,3} Of these factors, size is the most important determinant of treatment—that is, enucleation or eye conserving therapy. The symptoms of choroidal melanoma are loss of vision, flashes, or a decreased field of vision. Often no symptoms are present and the melanoma or its possible precursor,² the choroidal naevus, is detected during routine ophthalmological examination. The diagnosis of choroidal melanoma is generally based on a combination of funduscopy, transillumination, fundus fluorescein angiography, and perimetry. These routine techniques need to be performed and interpreted by an ophthalmologist with experience in ocular oncology.¹ It is important to distinguish between choroidal melanoma and naevus, but this can be difficult, especially when a small melanoma is concerned.⁴

Corneal autofluorescence (λ_{ex} 415 nm–491 nm, λ_{em} 515 nm–630 nm) is the fluorescence that arises from endogenous fluorophores that are physiologically present in the cornea, and is considered an indicator of disease induced changes in the metabolic state of the cornea. For example, corneal autofluorescence is increased in eyes with open angle glaucoma and penetrating keratoplasty and in the eyes of patients with diabetes mellitus.⁵⁻¹⁰ Corneal autofluorescence values in patients with diabetes correlate with the severity of their diabetic retinopathy,⁸⁻¹⁰ although the mechanism underlying this relation remains uncertain.⁵ This study was conducted to investigate whether corneal autofluorescence is different in patients with a melanoma or naevus in the choroid.

Materials and methods

Patients were selected from the oncology outpatient clinic of the department of ophthalmology of the Leiden University Medical Center (LUMC). They were diagnosed with a unilateral choroidal melanoma or naevus. The clinical diagnosis of melanoma or naevus rested on thorough examination of the patient in the ocular oncology service of the Leiden University Medical Center. Standard examination included direct and indirect ophthalmoscopy, ultrasonography (A and B mode), transillumination, fundus fluorescein angiography, and perimetry. In difficult cases, magnetic resonance imaging, fine needle aspiration biopsy, indocyanine green angiography, and electro-oculography were performed as well. Patients were excluded if they had diabetes mellitus type 1 or 2, ocular disease other than ocular melanoma or naevus, if they

Department of Ophthalmology, Leiden University Medical Center, Leiden, Netherlands
R P H M Müskens
J C Bleeker
J E E Keunen

Department of Ophthalmology and Visual Sciences, Biomedical Institute for Research in Light and Image, Coimbra University, Coimbra, Portugal
J A Van Best

Correspondence to: Jaap A van Best, Department of Ophthalmology and Visual Sciences, Biomedical Institute for Research in Light and Image, Coimbra University, Azinhaga Sta, Comba, 3030 Coimbra, Portugal
vanbest@imagem.ibili.uc.pt

Accepted for publication 22 January 2001

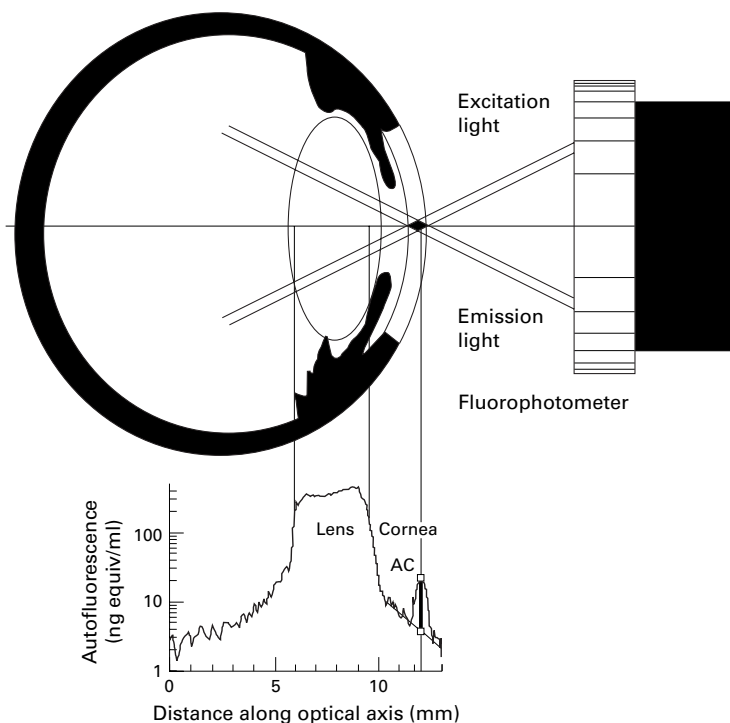


Figure 1 Principle of corneal scans. Upper: An autofluorescence scan of the anterior segment is obtained by moving the intersection diamond between excitation beam and fluorescence viewing beam along the optical axis of the eye. Lower: Owing to limited spatial resolution, part of lens autofluorescence is measured together with corneal autofluorescence. Therefore the lens part is subtracted from the corneal part (straight oblique line in lower part), resulting in net corneal peak autofluorescence (thick vertical line). Note the logarithmic vertical axis. Fluorescence is expressed in equivalent sodium fluorescein concentration.

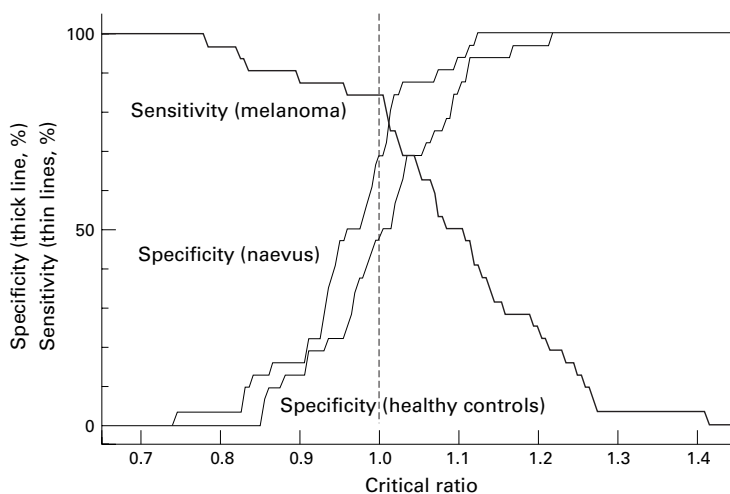


Figure 2 Thick line: sensitivity of the diagnosis of a unilateral choroidal melanoma made on the basis of corneal autofluorescence measurement as a function of the critical ratio chosen (ratio between corneal autofluorescence of eye suspected and contralateral eye). Thin lines: specificity of diagnosis of melanoma in patients with a unilateral naevus and in healthy controls, respectively.

had undergone ocular surgery (except cataract surgery), or if they had received intravenous or intraocular fluorescein less than 36 hours before examination. Healthy controls were selected from among friends and colleagues. They were excluded if they had a history of ocular or systemic disease. Patients and healthy controls were informed about the study and gave their consent in accordance with the Helsinki treaty. The ethics committee of the Leiden University Medical Center approved the study.

Both corneas were inspected by slit lamp examination. Fluorophotometry was carried out with a scanning fluorophotometer (Fluorotron Master, OcuMetrics Inc, Palo Alto, CA, USA, Fig 1). Six fluorophotometric scans of the anterior segment of each eye were made for each participant to reduce the effect of spread in the values. The corneal autofluorescence values were determined after correction for lens tailing¹¹ (Fig 1) and noise (a moving average over three scan points was used). In each patient with a choroidal melanoma or a choroidal naevus, the ratio between mean corneal autofluorescence values of affected and healthy eyes was calculated. In healthy controls a random selection of left-right and right-left ratios was made.

A ratio between the corneal autofluorescence of the selected eye and the control eye of each individual was used to reduce the effect of the large spread in the mean corneal autofluorescence values of both eyes on the results (about a factor 2)⁷ since the corneal autofluorescence values of the right and the left eyes in a group of individuals are strongly correlated (correlation coefficient >0.9, $p < 0.001$).⁸

Before the average ratio of each of the three groups (melanoma patients, naevus patients, and healthy controls) was calculated, a weight factor was introduced in order to take the variation in the autofluorescence values of each cornea into account. The corresponding mathematical procedure is described in the appendix. The corneal autofluorescence ratio distribution of each of the three groups was tested for a normal distribution using d'Agostino's test for departure of normality. A single factor analysis of variance was performed to test the null hypothesis that the values did not differ among groups.^{12, 13} If the null hypothesis was rejected, then the Tukey multiple comparison procedure was applied for each pair of groups. The Kramer approximation for unequal numbers of values was used when necessary. For comparison, the non-parametric Kruskal-Wallis test was performed as well. Software specially developed at the laboratory of the ophthalmology department of the Leiden University Medical Center and written in Borland Pascal 7.0 and in Delphi 3 was used for all calculations.

Results

The personal data and corneal autofluorescence ratios of patients and healthy controls are presented in Table 1. The study included small, medium, and large sized melanomas (mean prominence 4.16 mm (SD 2.85), mean diameter 10.15 (2.62) mm). The naevi were generally smaller compared with the melanomas, according to their nature. Naevi with a prominence in excess of 3 mm are quite rare. The ratios were normally distributed in each of the three groups. The analysis of variance revealed that the values differed among the groups ($p < 0.0005$). The results of the parametric Turkey multiple comparison procedure between pairs of groups are presented in Table 2, together with the results of the non-parametric Kruskal-Wallis test. The ratios of

Table 1 Personal data and corneal autofluorescence ratio

Group	Number	Sex (F:M)	Age (years) (mean (SD))	Ratio† (mean (SD))
Patients with choroidal melanoma	32	15:17	58.0 (12.3)	1.09 (0.15)
Patients with choroidal naevus	32	24:8	60.4 (11.7)	0.96 (0.09)
Healthy controls	32	18:14	58.8 (12.1)	1.00 (0.09)

†Ratio between corneal autofluorescence of selected and control eye.

Table 2 Difference of corneal autofluorescence ratio between groups

Groups compared	Mean difference*	Difference range†	$P_{\text{param}}‡$	$P_{\text{non-param}}§$
Melanoma and naevus	+0.13	+0.068 to +0.192	<0.001	<0.001
Naevus and healthy control	-0.04	-0.085 to +0.005	0.27	0.27
Melanoma and healthy control	+0.09	+0.028 to +0.152	0.014	0.020

*Difference between mean ratios of two groups.

†95% confidence range of the difference.

‡Significance according to the parametric Turkey multiple comparison procedure.

§Significance according to the non-parametric Kruskal-Wallis test.

¶Significance according to the global Kruskal-Wallis test across the three groups: $p < 0.001$.

melanoma patients and healthy controls were significantly different ($p=0.014$), as were those of melanoma patients and naevus patients ($p < 0.001$), whereas those of naevus patients and healthy controls were not ($p=0.27$). The six smallest melanomas in the study (prominence 1–3 mm and diameter 3–7.88 mm) had corneal autofluorescence ratios in excess of 1.08 (mean prominence, diameter and ratio 2.29 (SD 0.74) mm, 6.80 (1.87) mm, 1.23 (0.11) mm). The autofluorescence ratios of the choroidal melanoma patients were not correlated with tumour diameter or tumour prominence (Pearson correlation coefficients -0.19, $p = 0.34$ and 0.15, $p = 0.45$, respectively). In both cases, the ratios were distributed as a horizontal cloud.

Discussion

Corneal autofluorescence was determined in both eyes of patients with a unilateral choroidal melanoma, patients with a unilateral choroidal naevus, and healthy controls. The mean corneal autofluorescence ratio between the affected eye and the healthy eye was significantly higher in patients with a choroidal melanoma than in patients with a choroidal naevus or healthy controls. Because no correlation was found between tumour prominence or tumour diameter and the corneal autofluorescence ratio, and because even the six smallest melanomas in the study had corneal autofluorescence ratios in excess of 1.08, we don't believe that tumour size accounted for the different corneal autofluorescence ratios found between melanomas and naevus patients. Corneal autofluorescence originates mainly from homogeneously distributed non-specific stromal fluorophores, which are probably formed by non-enzymatic glycation of collagen.^{5 14} High serum glucose levels and a higher permeability of the blood-aqueous barrier, as is found in diabetic patients, could cause high aqueous glucose levels, which in turn may increase the glycation of corneal proteins. This would explain the correlation between the severity of diabetic retinopathy and corneal autofluorescence in diabetic patients, as the severity of retinopathy is related to prolonged high serum glucose concentrations.^{8 10 14-16} The increase in

corneal autofluorescence in eyes with choroidal melanoma may be due to an increased permeability of the blood-aqueous barrier. The subsequent increased flow of glucose into the aqueous humour could in turn increase the glycation of corneal proteins and thus increase the corneal autofluorescence. Such a breakdown of the blood-aqueous barrier in patients with a choroidal melanoma has been demonstrated by fluorophotometry, by immunohistochemical staining for albumin, and by measurement of aqueous flare.¹⁷⁻²² The permeability of the blood-aqueous barrier is increased in the affected eye only,¹⁹ which is consistent with our results that show an increase in corneal autofluorescence in the melanoma bearing eye but not in the contralateral eye. The increase in corneal autofluorescence is not as marked in patients with melanoma as it is in diabetic patients (about 9% and 100%, respectively).^{7 8} This may be because, to the best of our knowledge, blood glucose concentrations are not increased in patients with choroidal melanoma. The increased permeability of the blood-aqueous barrier in the eye with a tumour is probably the only cause of glucose entering the aqueous humour. This theory is supported by the simultaneous increase in corneal autofluorescence and aqueous flare observed after penetrating keratoplasty.^{7 23} It is also supported by the independent association between increased intraocular pressure and serum glucose concentration in juvenile diabetics, which explains the increase in corneal autofluorescence found in patients with ocular hypertension.^{24 25} The sensitivity of the diagnosis of a unilateral choroidal melanoma made on the basis of corneal autofluorescence measurements (that is, the percentage of true positive diagnoses) was calculated and is presented in Figure 2 as a function of the chosen critical ratio between both corneas (that is, the minimum ratio required to indicate a melanoma). The specificity (that is, the percentage of true negative diagnosis) in patients with a unilateral naevus or in healthy individuals with a randomly selected eye is also presented in Figure 2. As can be seen, melanoma can be distinguished from naevus with a sensitivity of 80% and a specificity of 80% if a critical ratio of 1.02 is used. Since the corneal autofluorescence ratio can be measured in a simple, fast and non-invasive manner, our results indicate that it might be helpful for distinguishing between possible choroidal melanoma and choroidal naevus.

The authors are indebted to Dr A H Zwinderman of the Department of Medical Statistics of the Leiden University Medical Center for help with the statistical procedures.

Appendix

The mean of six corneal autofluorescence values of the selected eye of an individual (M_{is}), the corresponding standard deviation (SD_{is}), the mean of six values of the control eye (M_{ic}) and the corresponding standard deviation (SD_{ic}) were calculated for each individual (i).

Then the corneal autofluorescence ratio was calculated for each individual:

$$R_i = M_{is}/M_{ic}$$

and the corresponding standard deviation:

$$SD_i = \sqrt{\left(\frac{SD_{is}}{M_{is}}\right)^2 + \left(\frac{SD_{ic}}{M_{ic}}\right)^2}$$

The expression for the standard deviation of a ratio corresponds to equation 15 in Mood *et al* assuming that the ratio is about one, and that the covariance between both corneas is about zero.²⁶ The latter assumption is based on the fact that, in an individual, the deviations from the mean fluorescence value of the selected eye do not correlate with those of the control eye, when fluorescence is not measured simultaneously.²⁶

A weighting factor (w_i) was introduced for each individual in order to take into account that an individual with a large standard deviation in one or both corneas will probably provide a less reliable ratio than an individual with small standard deviations in both corneas. The normalised inverse square root of the standard deviation of the ratio was used as such a weighting factor, with

$$\sum_{i=1}^N w_i = N$$

where N is the number of individuals in the group considered. The weighted standard deviation for the group was defined as²⁷

$$SD_w = \sqrt{\frac{1}{N-1} \sum_{i=1}^N \left(w_i (R_i - M_w) \right)^2}$$

- 1 Meredith TA. Choroidal melanoma: diagnosis and management. *Am J Ophthalmol* 1998;125:745–66.
- 2 Zhao DY, Shields CL, Shields JA, *et al*. Update on the management of posterior uveal melanoma. *J Ophthalmol Nursing Technol* 1998;17:66–71.
- 3 Damato BE, Paul J, Folds WS. Risk factors for metastatic uveal melanoma after trans-scleral local resection. *Br J Ophthalmol* 1996;80:109–16.
- 4 Oosterhuis JA, de Wolf-Rouendaal D. Differential diagnosis of small pigmented choroidal tumors. *Doc Ophthalmol* 1981;50:299–301.
- 5 Van Schaik HJ, Coppens J, van den Berg TJTP, *et al*. Autofluorescence distribution along the corneal axis in diabetic and healthy humans. *Exp Eye Res* 1999;69:505–10.
- 6 Kuppens EVMJ, Stolwijk TR, van Best JA, *et al*. Topical timolol, corneal epithelial permeability and autofluorescence in glaucoma by fluorophotometry. *Graefes Arch Clin Exp Ophthalmol* 1994; 232:215–20.
- 7 Stolwijk TR, van Best JA, Boot JP, *et al*. Corneal autofluorescence in diabetic and penetrating keratoplasty patients as measured by fluorophotometry. *Exp Eye Res* 1990;51:403–9.
- 8 Stolwijk TR, van Best JA, Oosterhuis JA, *et al*. Corneal autofluorescence: an indicator of diabetic retinopathy. *Invest Ophthalmol Vis Sci* 1992;33:92–7.
- 9 Janiec S, Rzendkowski M, Bolek S. The relation between corneal autofluorescence, endothelial cell count and the severity of the diabetic retinopathy. *Int Ophthalmol* 1994–1995;18:205–9.
- 10 Fantaguzzi S, Docchio F, Guarisco L, *et al*. Corneal autofluorescence in diabetic and normal eyes. *Int Ophthalmol* 1994–1995;18:211–14.
- 11 Lohmann AM, van Best JA, de Keizer RJW. Corneal metabolism and epithelial barrier function after cataract surgery and intraocular lens implantation. A fluorophotometric study. *Int Ophthalmol* 1996;19:225–33.
- 12 Zar JH. The analysis of variance. In: Kurz B, ed. *Biostatistical analysis*. Englewood Cliffs, NJ: Prentice-Hall, Chapter 11, 1984:163–83.
- 13 Zar JH. The normal distribution. In: Kurz B, ed. *Biostatistical analysis*. Englewood Cliffs, NJ: Prentice-Hall, Chapter 7, 1984:79–96.
- 14 Mori F, Ishiko S, Abiko T, *et al*. Changes in corneal and lens autofluorescence and blood glucose levels in diabetics: parameters of blood glucose control. *Curr Eye Res* 1997;16: 534–8.
- 15 Nguyen NX, Schonherr U, Kühle M. Aqueous flare and retinal capillary changes in eyes with diabetic retinopathy. *Ophthalmologica* 1995;209:145–8.
- 16 Moriarty AP, Spalton DJ, Moriarty BJ, *et al*. Studies of the blood-aqueous barrier in diabetes mellitus. *Am J Ophthalmol* 1994;118:768–71.
- 17 Blanksma LJ, Kooijman AC, Roze JH, *et al*. Clinical applications of fluorophotometry. *Doc Ophthalmol* 1983;55: 37–40.
- 18 Vinores SA, Kühle M, Mahlow J, *et al*. Blood–ocular barrier breakdown in eyes with ocular melanoma. *Am J Pathol* 1995;147:1289–97.
- 19 Kühle M, Nguyen NX, Naumann GOH. Aqueous flare in eyes with choroidal melanoma. *Am J Ophthalmol* 1992;113: 207–8.
- 20 Kühle M, Nguyen NX, Naumann GOH. Quantitative assessment of the blood-aqueous barrier in human eyes with malignant or benign uveal tumors. *Am J Ophthalmol* 1994;117:521–8.
- 21 Castella AP, Bercher L, Zografos L, *et al*. Study of the blood-aqueous barrier in choroidal melanoma. *Br J Ophthalmol* 1995;79:354–7.
- 22 Nguyen NX, Kühle M, Naumann GOH. Tumor growth of a choroidal malignant melanoma and aqueous flare. *Ophthalmologica* 1999;213:194–6.
- 23 Kühle M, Nguyen NX, Naumann GOH. Aqueous flare following penetrating keratoplasty and in corneal graft rejection. *Arch Ophthalmol* 1994;112:354–8.
- 24 Ganley JP. Epidemiological aspects of ocular hypertension. *Surv Ophthalmol* 1980;25:130–5.
- 25 Kuppens EVMJ. *The involvement of the anterior eye segment in primary open angle glaucoma*. Thesis, Leiden University, 1996:65–97.
- 26 Mood AM, Graybill FA, Boes DC. Introduction to the theory of statistics. Chapter IV, 153–156, Joint and conditional distributions, Stochastic independence, More expectation. Chapter V, 180–181. In: Blackwell D, Solomon H, eds. *Distribution of functions of random variables*. 3rd ed London: McGraw-Hill, 1974.
- 27 Sokal RR, Rohlf FJ. Description of statistics. In: Wilson J, ed. *Biometry*. 2nd ed. New York: WH Freeman, 1981, chapter 4:38–61.



Corneal autofluorescence in choroidal melanoma or in choroidal naevus

R P H M Müskens, J A Van Best, J C Bleeker, et al.

Br J Ophthalmol 2001 85: 662-665

doi: 10.1136/bjo.85.6.662

Updated information and services can be found at:

<http://bjo.bmj.com/content/85/6/662.full.html>

These include:

References

This article cites 21 articles, 4 of which can be accessed free at:

<http://bjo.bmj.com/content/85/6/662.full.html#ref-list-1>

Email alerting service

Receive free email alerts when new articles cite this article. Sign up in the box at the top right corner of the online article.

Notes

To request permissions go to:

<http://group.bmj.com/group/rights-licensing/permissions>

To order reprints go to:

<http://journals.bmj.com/cgi/reprintform>

To subscribe to BMJ go to:

<http://group.bmj.com/subscribe/>