

Bacterial keratitis: a prospective clinical and microbiological study

Frédéric Schaefer, Olivier Bruttin, Léonidas Zografos, Yan Guex-Crosier

Abstract

Aim—To define the clinical and microbiological profile of bacterial keratitis at the Jules Gonin Eye Hospital and to test the *in vitro* bacterial resistance.

Methods—Patients presenting with bacterial keratitis were prospectively followed; clinical features (age, risk factors, visual acuity) and response to therapy were analysed. Bacteriological profile was determined and the sensitivity/resistance of isolated strains were tested towards 12 ocular antibiotics (NCCLS disc diffusion test).

Results—85 consecutive patients (mean age 44.3 (SD 20.7) years) were prospectively enrolled from 1 March 1997 to 30 November 1998. The following risk factors were identified: contact lens wear, 36%; blepharitis, 21%; trauma, 20%; xerophthalmia, 15%; keratopathies, 8%; and eyelid abnormalities, 6%. The most commonly isolated bacteria were *Staphylococcus epidermidis*, 40%; *Staphylococcus aureus*, 22%; *Streptococcus pneumoniae*, 8%; others *Streptococcus* species, 5%; *Pseudomonas*, 9%; *Moraxella* and *Serratia marcescens*, 5% each; *Bacillus*, *Corynebacterium*, *Alcaligenes xyloxydans*, *Morganella morganii*, and *Haemophilus influenzae*, 1% each. 1–15% of strains were resistant to fluoroquinolones, 13–22% to aminoglycosides, 37% to cefazolin, 18% to chloramphenicol, 54% to polymyxin B, 51% to fusidic acid, and 45% to bacitracin. Five of the 85 patients (5.8%) had a poor clinical outcome with a visual loss of one or more lines of visual acuity.

Conclusion—Fluoroquinolones appear to be the therapy of choice for bacterial keratitis, but, based upon these *in vitro* studies, some strains may be resistant.

(Br J Ophthalmol 2001;85:842–847)

be reversed only by a corneal graft transplantation. In addition, emergence of multiresistant strains is a major concern when antibiotics such as fluoroquinolones are used as monotherapeutic agents.

The conjunctiva and ocular adnexae are rapidly colonised by bacteria at birth,² and conjunctival bacterial microflora undergo constant turnover. The flora isolated in healthy individuals consist primarily of *Staphylococcus epidermidis* and diphtheroids. Species of greater virulence, such as *Staphylococcus aureus*, *Streptococcus pneumoniae*, *Pseudomonas aeruginosa*, and even *Neisseria meningitidis*, have been reported.³

Corneal infections result mostly from a failure of one of the protective mechanisms that maintain the ocular surface integrity; most ocular pathogens cannot penetrate an intact epithelial corneal layer that is protected by the eyelids and the tear film. Passive and active host defence mechanisms protect corneal tissues from bacterial invasion. Complement activation and enzyme secretion within the lacrimal fluid are part of the natural host defence mechanisms, and although lysozymes, lactoferrin, betalysin, orosomucoid, and ceruloplasmin have been isolated within the lacrimal fluid,² the specific role of each of these enzymes has yet to be determined. Once the passive mechanisms of corneal protection have failed or the corneal epithelium is breached, bacteria are free to invade the cornea. Polymorphonuclear cell attraction is induced primarily by interleukin 8 (IL-8) and occurs 8–10 hours after the corneal damage. This IL-8 secretion may also be responsible for further development of neovascularisation.^{4,5} Corneal infiltration by inflammatory cells appears, by slit lamp examination, as corneal cloudiness that surrounds the infected tissues. The specific immunity arises from the limbus, which is surrounded by numerous lymphoid T and B cells that are part of the mucosal associated lymphoid tissues (MALT).⁶ Secreted immunoglobulins also enhance bacterial phagocytosis.

Recurrent attacks of bacterial keratitis are particularly frequent in the presence of constitutional factors such as dry eye syndrome or eyelid abnormalities.

Gram negative bacteria are known to be associated with soft contact lens wear, and disposable contact lens wear has been linked to an increased incidence (15–20-fold) of ulcerative keratitis.⁷

Finally, the bacterial pattern of keratitis can also be influenced by geographic and climatic factors; many differences in keratitis profile have been noted between populations living in rural or in city areas. This may be explained by

Bacterial keratitis, because of its high incidence and potential complications, is one of the most visually threatening ocular infectious pathologies. The avascular corneal stroma is particularly susceptible to bacterial infection, and many patients have a poor clinical outcome if aggressive and appropriate therapy is not promptly initiated. Corneal perforations, which can occur in less than 24 hours, have been reported in the presence of particularly invasive pathogens such as *Pseudomonas aeruginosa* and *Staphylococcus aureus*.¹ Furthermore, clinical outcome can be influenced by onset of a corneal opacity within the visual axis, which can cause a decrease in visual acuity that can

Jules Gonin Eye Hospital, University of Lausanne, Switzerland
F Schaefer
L Zografos
Y Guex-Crosier

Polyanalytic SA, Lausanne, Switzerland
O Bruttin

Correspondence to:
Yan Guex-Crosier, Jules Gonin Eye Hospital, 15, av de France, 1004 Lausanne, Switzerland
yan.guex@ophtal.vd.ch

Accepted for publication 20 February 2001

the high variation of habits between these two groups, such as antibiotic use, contact lens wear, or even specific rural pathogen exposure.

Adequate ocular prevention, knowledge of the microbiological pattern in a given clinical practice, and a prompt choice of appropriate fortified antibiotics constitute the management of bacterial keratitis. Identification of the pathogen, initiation of immediate therapy, modification based on the organism identified, and consideration of drug toxicity and bacterial resistances represent the keys to success in the management of bacterial keratitis.^{8,9}

Aim

The objectives of this prospective study were to define the clinical risk factors, the prognosis, and the microbiological pattern of bacterial keratitis at the Jules Gonin Eye Hospital, and then to test these bacteria against the most commonly used ocular antibiotics in order to formulate new guidelines for therapy.

Material and methods

PATIENTS

From 1 March 1997 to 30 November 1998, all patients presenting with a corneal infiltrate compatible with a diagnosis of bacterial keratitis were enrolled in a prospective study.

To avoid the inclusion of chronic ulcerations, patients with a corneal ulceration lasting for 3 weeks or more were excluded. Patients suspected of having or with a positive culture for fungal, viral, or *Acanthamoeba* infection were also excluded.

The following standard protocol for bacteria isolation was used: a corneal smear was taken after topical anaesthesia was obtained by application of a drop of single dose unit oxybuprocaine 0.4% (Faure, Ciba Vision Ophthalmics, Novartis, Switzerland). The swabs were performed with surgical triangular spears from Merocels (Solanm Division of Xomed Surgical products, Jacksonville, FL, USA). Inoculation of agar culture plates (chocolate, blood and Sabouraud media) was performed according to the National Committee for Clinical Laboratory Standards protocol (NCCLS, Villanova PA, USA).¹⁰ An additional swab was performed and the spongy tip of the triangular spear was directly cut into a bottle of sterile brain heart infusion culture medium (BHI). Media were incubated at 37°C in a 2% carbon dioxide atmosphere.

Isolated bacteria were tested for their resistance against the following 12 ocular antibiotics: bacitracin, cefazolin, chloramphenicol, gentamicin, neomycin, polymyxin B, lomefloxacin, ciprofloxacin, norfloxacin, ofloxacin, tobramycin, and fusidic acid. The resistance to antibiotics was evaluated with the standard disc diffusion method, according to the modified test recommended by the NCCLS. The discs of antibiotic for resistance testing were obtained from Difco Laboratories (Dispens-O-disc susceptibility test system, Difco Laboratories, Detroit, MI, USA). Since no criteria for resistance of corneal infections are available,

the cut-off values for systemic bacterial infections applied for septicaemia were used according to the NCCLS recommendations.^{11,12}

TREATMENT PROTOCOL

The standard treatment consisted of topical cefazolin 50 mg/ml (Kefzol, Lilly Pharmaceuticals, Vernier, Switzerland) and fortified gentamicin 9 mg/ml (Garamycin, Essex Pharmaceuticals, Luzern, Switzerland) given alternately every 15 minutes during the first 2 hours, then every hour for the following 24 hours. Later, antibiotics were progressively tapered according to the clinical response. Bottles of antibiotics were freshly prepared and cefazolin was changed every 4–5 days as it contains no preservative. This standard protocol was used for all patients unless they had a corneal infiltrate that was less than 1 mm in diameter or another suitable therapy had already been initiated.

PARAMETERS STUDIED

History and examination were focused on the following risk factors: corneal injuries (organic or mineral foreign bodies), contact lens wear, blepharitis, keratopathies (due to previous herpetic infection, corneal dystrophy or surgical procedure, as in bullous keratopathy), dry eye syndrome, corneal surgery (graft transplantation, excimer treatment), or eyelid abnormalities (entropion, ectropion, lagophthalmos, and others). Visual acuities were measured with Snellen charts.

Extension of keratitis was measured with the Haag-Streit 900 slit lamp. The major site of keratitis was determined according to five zones that were previously defined: central or pupillary area, nasal, inferior, temporal, and superior. The ulceration depth was evaluated as < 30%, 30–60%, or >60% of the total corneal depth. Anterior chamber inflammation, when present, was scored, according to Hogan and associates, a 0+ to 4+ for Tyndall effect and cells.¹³ To define the clinical outcome, patients were considered to have a poor outcome if they had visual loss of acuity of one or more Snellen lines or if a major complication occurred, such as corneal perforation, or if corneal transplantation was indicated.

Results

PATIENT DATA

During 21 consecutive months (from 1 March 1997 to 30 November 1998), 85 patients were seen at the Jules Gonin Eye Hospital with a corneal infiltrate that was compatible with a diagnosis of bacterial keratitis. Twenty (23.5%) patients were admitted to the hospital for therapy, while the other 65 (76.5%) were treated in the outpatient clinic. The mean age of the patients was of 44.3 (SD 20.7) years (range 7–91 years); sex distribution was 1:1 (43 men and 42 women).

Contact lens wear was by far the most common risk factor; this was encountered in 31 (36%) patients. Severe blepharitis was present in 18 (21%) of the patients. In 17 patients (20%), the keratitis was induced by foreign bodies—10 patients with organic material

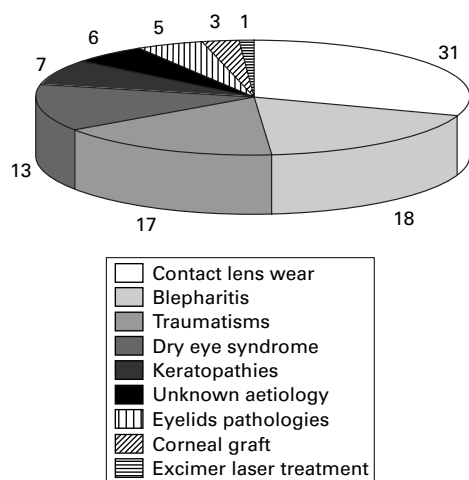


Figure 1 Contact lens wear is by far the most common risk factor encountered. The numbers refer to the numbers of patients. Blepharitis and trauma are also major risk factors for the development of keratitis. Other aetiologies, such as dry eye syndrome, keratopathies, and eyelid pathologies, are less common risk factors.

(vegetable or animal) and seven patients with mineral particles. Dry eye syndrome was diagnosed in 13 (15%) patients. Keratopathies (including herpetic, bullous, and postoperative keratopathies) were present in seven (8%) patients. Other aetiologies are summarised in Figure 1. Fifteen (18%) patients had more than one risk factor: dry eye disease was present in one patient with an eyelid pathology, in two patients with previous corneal trauma, and in three patients who wore contact lenses. Blepharitis was present in four patients having eyelid pathologies, in three patients with previous corneal trauma, in one with contact lens wear, and in one with a corneal graft. No significant difference in risk factors was noted between patients living in rural or urban areas, but organic foreign bodies tended to be more common in patients from rural areas, and all three patients presenting with a corneal infection after keratoplasty were from a rural area.

The corneal localisation of the ulcers was randomly distributed—32% were central, 28% nasal, 48% inferior, 33% temporal, and 28% superior (total percentage is greater than 100 because more than one area was affected in many patients). Lesions of the inferior zones were associated primarily with contact lens wear or trauma. Interestingly, lesions of the temporal and superior zones were never associated with eyelid pathologies.

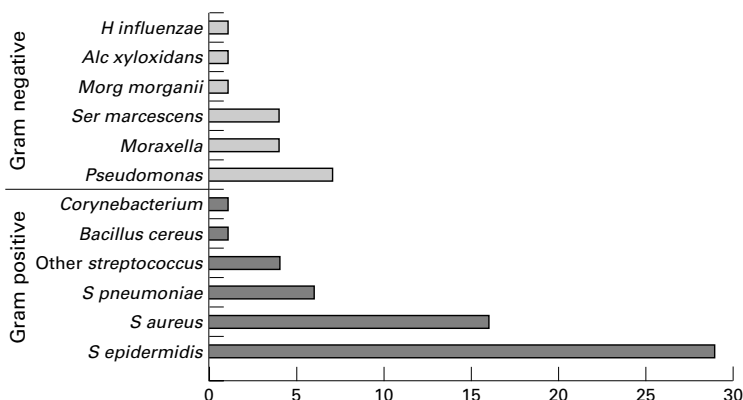


Figure 2 Gram positive bacteria are by far the most commonly isolated organisms of which *Staphylococcus* species predominate. *Pseudomonas aeruginosa* is the Gram negative bacterium most encountered.

The diameter of the corneal ulceration was of 1 mm or less in 44 patients (51.7%), 1–2 mm in 21 patients (24.8%), and over 2 mm in 20 patients (23.5%).

Ulceration depth was less than 30% in 49 patients (57.6%), between 30% and 60% in 31 patients (36.5%), and over 60% in five patients (5.9%).

Anterior chamber inflammation was absent in 56 patients (65.9%). A 1+ to 2+ Tyndall effect with 1+ to 2+ cells was present in 21 patients (24.7%), and severe anterior chamber inflammation (3+ to 4+ Tyndall effect and cells, with or without hypopyon) was present in eight patients (9.4%).

MICROBIOLOGICAL CONSIDERATIONS

In 73 (86%) patients, bacteria were isolated from the corneal smears. In five of the 12 patients with negative cultures, treatment with ocular antibiotics had been initiated before they were referred. Three patients were treated by chloramphenicol drops for, respectively, 12, 6, and 1 day before inclusion; one patient was taking neomycin for 6 days and one gentamicin for 1 day. The remaining seven of the 12 negative cultures (58%) came from patients who were not taking any treatment before the corneal smears were obtained.

BHI media was more sensitive than agar plates for bacterial isolation since 66 (90%) of the 73 positive cultures were in BHI medium, whereas only 39 (53%) were positive in agar plates. In 34/73 (46%) patients, culture was positive in BHI medium only, whereas 7/73 (9%) were positive exclusively in agar plates. In 32/73 (44%), both culture media were positive. The incubation period was similar in 20 cases (30.7 (SD 13.8) hours), shorter in agar plates in seven cases and shorter in BHI in five cases. However, when incubation time was shorter in agar plates, the difference was always less than 24 hours. Bacteria were isolated in less than 3 days (72 hours) in all positive cases. In more than 90% of cases, bacteria were isolated in less than 48 hours. In only two patients were two pathogenic bacteria isolated in the same culture (total number of bacteria, 75 for 73 patients). The bacterial pattern is shown in Figure 2. Gram positive bacteria were predominant, mainly *Staphylococcus* species; Gram negative bacteria were mostly *Pseudomonas* species.

In almost all risk groups (except contact lens wearers and patients who had undergone a corneal graft transplantation), primarily Gram positive bacteria were isolated (75%), mostly *Staphylococcus* species. In patients wearing contact lenses, 12/28 (43%) were Gram negative, mostly *Pseudomonas* species. Two of three patients presenting with a keratitis after keratoplasty were infected by Gram negative bacteria (one *Moraxella* and one *Morganella*); the third patient was infected by *Staphylococcus aureus*.

SENSITIVITY AND RESISTANCE TO ANTIBIOTICS

All (save for eight) isolated bacteria were tested on 12 antibiotics that are currently used in ophthalmology; the eight strains could not be

tested because of improper technical management. The results of bacterial in vitro tests are represented in Figure 3.

Testing showed that more than 40% of strains (Gram positive and Gram negative) are resistant to polymyxin B and fusidic acid. Only 18% of bacteria are resistant to chloramphenicol; in fact, the sensitivity rate is 98% for Gram positive bacteria although 65% of Gram negative strains are either resistant or show only intermediate sensitivity.

The new class of fluoroquinolones showed a good effect against both Gram positive and Gram negative bacteria, except for several strains of *Streptococcus pneumoniae* and a multiresistant *Pseudomonas*. A few bacteria were highly resistant to almost all of the antibiotics available for use in ophthalmology: 3/75 strains (4%) were considered highly resistant as they were resistant to seven or more of the tested antibiotics.

Seventy of the 85 patients (82%) were treated according to the standard protocol as defined previously. The remaining 15 patients, who did

not benefit from the cefazolin-gentamicin regimen, received the following—13 patients were on monotherapy (six with ofloxacin, five with lomefloxacin, two with chloramphenicol), two were on a different combined therapy (one ofloxacin-cefazolin and one ofloxacin-chloramphenicol).

CLINICAL OUTCOME

Among the 70 patients who were treated with the combination of cefazolin 50 mg/ml and fortified gentamicin 9 mg/ml, only three patients (4%) had a poor clinical outcome:

- An 85 year old woman with severe entropion, chronic secondary corneal oedema and neovascularisation had a 2 × 2 mm corneal ulceration in the superotemporal area. The culture was positive for *Morganella*. Corneal ulceration depth was 90% of the total corneal thickness. She developed a corneal perforation 2 weeks after presentation despite application of fortified antibiotics according to our standard protocol.
- An 80 year old man with chronic bullous keratopathy after anterior chamber intraocular lens implantation developed a central corneal abscess, due to *Streptococcus pneumoniae*, that reached 4 × 2 mm and involved 60% of the corneal depth. Two months after the abscess healed he developed a central corneal scar and visual acuity was limited to hand movement.
- A 70 year old man with progressive rheumatoid arthritis developed a nasal corneal ulceration measuring 1.5 × 1 mm involving 60% of the corneal depth. This was due to *Pseudomonas aeruginosa*. He developed a corneal perforation after 3 days of in-hospital therapy and required a corneal graft transplantation.

Of the 15 patients (13%), who did not benefit from the standard therapy, two (13%) had a poor clinical outcome:

- A 77 year old man with severe blepharitis, ocular rosacea and ectropion developed a 4 × 5 mm ulceration in the inferior half of his right cornea; this ulceration, due to *Streptococcus oralis*, involved 60% of total corneal depth. Combined therapy with cefazolin and ofloxacin was introduced. The abscess healed but he subsequently developed major thinning of the cornea and a Gundersen's procedure was performed.
- The second patient was a 40 year old man with severe dry eye syndrome. He received monotherapy of chloramphenicol for a small corneal abscess of 1 × 1 mm, with corneal ulceration depth of less than 30% (near the limbus) after excision of a pterygium. *Staphylococcus epidermidis* was isolated. The keratitis quickly resolved but he developed severe irregular astigmatism 2 months later and his visual acuity decreased from 10/10 to 7/10.

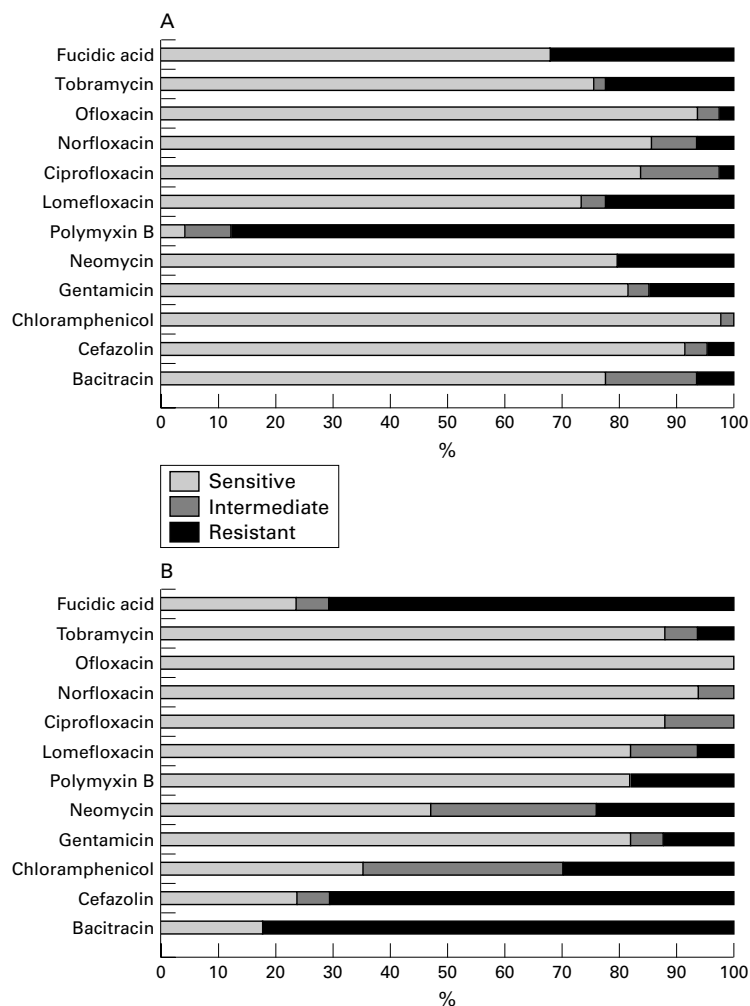


Figure 3 Chloramphenicol, cefazolin, and new fluoroquinolones (particularly ofloxacin) are very effective against Gram positive bacteria. In contrast, many of these same bacteria are resistant to polymyxin B (A). Similar to the effectiveness against Gram positive bacteria, the new fluoroquinolones are also effective against Gram negative bacteria. Aminoglycosides (tobramycin, neomycin, and gentamicin) also provide a broad spectrum of activity against Gram negative pathogens. Bacitracin, cefazolin, chloramphenicol, and fusidic acid, on the contrary, have little effect against these bacteria (B).

Discussion

Bacterial keratitis is rare in the absence of a predisposing factor. Until recently, most cases of microbial keratitis were associated with ocular trauma or ocular surface disease, but the

widespread use of soft contact lenses has greatly increased the risk of bacterial keratitis,¹⁴ which is estimated to be 10–15 times higher with the use of extended wear disposable contact lenses.^{7 15 16} In our series of 85 cases of bacterial keratitis, 31 (36%) were associated with contact lens wear (Fig 1). Ocular trauma remains the second most common cause of bacterial keratitis, accounting for 17 (20%) of our cases. Trauma is a far more common predisposing factor for bacterial keratitis in low income countries, where it accounts for up to 77.5% of cases.¹⁷ The presence of organic materials within the wound represents a much higher risk than does the presence of non-organic substances.

Ocular surface diseases such as dry eye syndrome, chronic blepharitis, and eyelid pathologies also predispose to bacterial keratitis. Older individuals are more commonly affected, particularly those with rheumatoid diseases, who may have difficulty with drop administration, leading to recurrent attacks of bacterial keratitis. Older age, delay in referral, topical steroid treatment, past ocular surgery, poor vision at presentation, large size of ulcer, and central location of the ulcer are all major risk factors that can necessitate penetrating keratoplasty,¹⁸ or even evisceration or enucleation in patients with bacterial keratitis.¹⁹ The specific bacteria isolated is also implicated in loss of the eye, as *Pseudomonas* strains were more often isolated in eyes that had to be removed because of ulcerative keratitis.¹⁹

Various methods have been described for bacterial isolation. When only blood agar and chocolate agar plates were used, the isolation rate was estimated to be 67%, and in 70% of these cases, blood and chocolate agar plates yielded similar results.²⁰ The overall success rate of bacterial isolation was high in the present study, with 86% of smears being positive. The isolation rate of bacteria using blood and chocolate agar plates or BHI media was 45.9% and 77.6% respectively. The higher isolation rate in BHI can probably be explained by the fact that the spongy tip of the Merocels spears was directly cut into the BHI media, whereas agar plates were inoculated by rolling the spear tip across the surface, as described in CUMITECH 13A.¹⁰ Our technique yields an isolation rate similar to that of corneal biopsy and tissue microhomogenisation, in which the isolation rate was of 88%.²¹

Our current treatment of bacterial keratitis consists of topical instillation of fortified antibiotics (cefazolin and gentamicin), which has been the “gold standard” for the therapy of bacterial keratitis.²² However, a rapid decrease in the concentration of gentamicin on the ocular surface does occur. The longest elapsed time after instillation for detection of gentamicin on the conjunctiva was 40 minutes for ointment and only 10 minutes for drops. At 10 minutes, the ocular surface concentration was 310 mg/ml for ointment and 45 mg/ml for drops.²³ Furthermore, gentamicin has poor corneal penetration; the anterior chamber concentration of gentamicin was below limits of detection (<0.6 mg/l) at the time of surgery,

after the administration of five drops or ointment 30–60 minutes before cataract surgery.²³

The use of fortified antibiotics has also been associated with local toxicity to the corneal epithelium.²⁴ Patients often complain of ocular irritation or intense conjunctival reactions during drop instillation. The use of antibiotics without preservatives, such as cefazolin, can be associated with bottle contamination by bacteria. This study was conducted to determine the percentage of clinical cases of bacterial keratitis that are resistant to fluoroquinolone monotherapy.

Since 1991, fluoroquinolones have been available for the treatment of bacterial conjunctivitis. These relatively new agents are bactericidal, exert their effect by DNA gyrase inhibition, and have a broad spectrum of activity against both Gram negative and Gram positive bacteria. Many experimental and clinical studies have shown the efficacy of ciprofloxacin ointment or solution in the treatment of bacterial keratitis.^{10 25–28} Fluoroquinolones have been shown to be effective in the treatment of methicillin resistant *Staphylococcus aureus*²⁹ and *Pseudomonas aeruginosa*,²⁵ but the increasing number of bacterial strains resistant to fluoroquinolones is a major concern when they are used as monotherapeutic agents.

A recent report³⁰ has shown a rapid increase in *Staphylococcus aureus* resistance to ciprofloxacin, with a 5.8% resistance in 1993, 9.4% in 1994, 11.4% in 1995, 26.5% in 1996, and 35% resistance in 1997; a similar rate of resistance progression was observed with ofloxacin. The resistance of other bacteria, such as *Streptococcus pneumoniae*, remained stable. In our study, multiresistant Gram negative strains were detected, and the rate of resistance was higher in bacterial keratitis than in conjunctivitis. The bacteria causing keratitis are possibly more virulent strains that may have been resistant to previously used systemic antibiotics.

Recent reports of bacterial resistance to fluoroquinolones suggest that bacteria isolated from bacterial keratitis must be periodically tested against available antibiotics in order to know the current resistance pattern. The disc susceptibility method provides quantitative measurements that are critical for epidemiology and drug resistance surveillance. Although this approach is both fast and cost effective,³¹ resistance criteria apply only to systemically achieved drugs levels, which are different from those achieved with topical treatments.

Two criteria must be considered when choosing a therapeutic agent in bacterial keratitis: the resistance rate and the penetration of the antibiotic at the level of infection. Among all fluoroquinolones, lomefloxacin has the best penetration of corneal tissues. Corneal tissue levels measured after topical administration of one drop was between 29 and 55 µg/g for lomefloxacin,³² 5.28 (3.4) µg/g (range 1.43–10.58 µg/g) for norfloxacin,³³ and 8.82 (8.24) µg/g for ciprofloxacin.³⁴ The aqueous humour concentration after topical administration was 0.072 µg/ml for ciprofloxacin, 0.057 µg/ml for

norfloxacin, 0.338 µg/ml for ofloxacin, and 2.2–7.6 µg/ml for lomefloxacin.^{33 35}

Visual prognosis after bacterial keratitis depends on the size, locality, and depth of the ulcer, as well as on the risk factors and the bacteria isolated.¹⁸ In this study, five patients had a poor clinical outcome. The presence of chronic diseases such as dry eye syndrome, acquired eyelid deformities, bullous keratopathy, and rheumatoid diseases seems to play an important part in the development of such poor visual outcomes and to predispose to recurrence. Of the five patients in this report who had a poor visual outcome, three had ulcers of 2 × 2 mm, and the central cornea was affected in two. The depth of the ulcerations was 60% or more of total corneal depth in all but one case. This last patient had undergone a surgical procedure 4 weeks before the onset of keratitis (pterygium excision) that led to thinning of the cornea. Depth of the ulceration seemed then to have a more significant role in visual prognosis than did extent and location of the ulcer.

Bacteria isolated from our patients were *Morganella morganii*, *Streptococcus pneumoniae*, *Pseudomonas aeruginosa*, *Streptococcus oralis*, and *Staphylococcus epidermidis*, but the numbers are too small to allow for conclusions concerning the prognosis related to specific bacterial patterns.

In conclusion, bacterial keratitis remains a therapeutic challenge and a vision threatening ocular condition. Contact lens wearers in particular should be informed of the potential risk, and should be carefully instructed on how to care for their lenses. Extended wear contact lenses represent an even more important risk factor for development of bacterial keratitis. Patients suffering from chronic ocular conditions such as dry eye syndrome, eyelid pathologies, severe blepharitis, and bullous keratopathy and those with chronic rheumatoid diseases, should be monitored closely and forewarned about the development of corneal ulcerations.

Rapid isolation of bacteria and treatment with intensive ocular antibiotics represent decisive steps in the management of such pathologies. New classes of fluoroquinolones, such as lomefloxacin, provide a broad spectrum of antibacterial activity, better tolerance, and good tissue penetration, compared with what is currently the gold standard of therapy, which consists of a combination of cefazolin and gentamicin. However, bacterial resistance (in particular with *Streptococcus pneumoniae*) must be taken into account with any monotherapy. A double blind study comparing the benefits of both types of treatment could help in the future management of bacterial keratitis.

This work was supported by Ciba Vision Ophthalmics AG, Grenstrasse 10, 8180 Bülach, Switzerland.

- 1 Ostler HB. Disease of the cornea. In: Mitchell CW, ed. *Disease of the external eye and adnexa*. Baltimore: Williams & Wilkins, 1993:137–252.
- 2 Limberg MB. A review of bacterial keratitis and bacterial conjunctivitis. *Am J Ophthalmol* 1991;112:2S–9S.
- 3 Bohigian GM. *Handbook of external diseases of the eye*. 3rd ed. Thorofare, NJ: Slack, 1987:131.
- 4 Elnor VM, Strieter RM, Pavlack MA, et al. Human corneal interleukin-8, IL-1 and TNF-induced gene expression and secretion. *Am J Pathol* 1991;139:977–88.

- 5 Strieter RM, Kunkel SL, Elnor VM, et al. Interleukin-8: corneal factor that induces neovascularization. *Am J Pathol* 1992;141:1279–84.
- 6 O'Brien TP. Bacterial keratitis. In: Krachmer J, Mannis M, Holland E, eds. *Cornea. Cornea and external disease: clinical diagnosis and management*. St Louis: Mosby, 1997:1139–89.
- 7 Matthews TD, Frazer DD, Minassian DC, et al. Risks of keratitis and patterns of use with disposable contact lenses. *Arch Ophthalmol* 1992;110:1559–62.
- 8 Waring GO III. Initial therapy of suspected microbial corneal ulcers. *Surv Ophthalmol* 1979;24:97–116.
- 9 Allan BDS, Dart JKG. Strategies for the management of microbial keratitis. *Br J Ophthalmol* 1995;79:777–86.
- 10 Wilhelmus KR, Liesgang TJ, Osato MS. Laboratory diagnosis of ocular infections. In: Specter SC, ed. *CUMITECH*. Washington: American Society for Microbiology, 1994.
- 11 National Committee for Clinical Laboratory Standards. *Performance standards for antimicrobial disk susceptibility tests*. 5th ed. Villanova, PA: National Committee for Clinical Laboratory Standards, 1993.
- 12 National Committee for Clinical Laboratory Standards. *Performance standards for antimicrobial disk susceptibility tests. 5th informational supplement*. Villanova, PA: National Committee for Clinical Laboratory Standards, 1994.
- 13 Hogan MJ, Kimura SJ, Thygeson P. Signs and symptoms of uveitis. I. Anterior uveitis. *Am J Ophthalmol* 1959;47(5, pt 2):155–70.
- 14 Radford CF, Minassian DC, Dart JKG. Disposable contact lens use as a risk factor for microbial keratitis. *Br J Ophthalmol* 1998;82:1272–5.
- 15 Poggio EC, Glynn RJ, Schein OD, et al. The incidence of ulcerative keratitis among users of daily-wear and extended-wear soft contact lenses. *N Engl J Med* 1989;321:119–83.
- 16 Schein OD, Glynn RJ, Poggio EC, et al. The relative risk of ulcerative keratitis among users of daily-wear and extended-wear soft contact lenses. A case-control study. Microbiological Keratitis Study Group. *N Engl J Med* 1989;321:773–8.
- 17 Vajpayee RB, Dada T, Saxena R, et al. Study of the first contact management profile of cases of infectious keratitis: a hospital-based study. *Cornea* 2000;19:52–6.
- 18 Miedziak AI, Miller MR, Rapuano CJ, et al. Risk factors in microbial keratitis leading to penetrating keratoplasty. *Ophthalmology* 1999;106:1166–71.
- 19 Cruz CS, Cohen EJ, Rapuano C, et al. Microbial keratitis resulting in loss of the eye. *Ophthalmic Surg Laser* 1998;29:803–7.
- 20 Waxman E, Chechelintsky M, Mannis MJ, et al. Single culture media in infectious keratitis. *Cornea* 1999;18:257–61.
- 21 Diamond J, Leeming J, Coombs G, et al. Corneal biopsy with tissue micro-homogenisation for isolation of organisms in bacterial keratitis. *Eye* 1999;13:545–9.
- 22 Chaudhuri PR, Godfrey B. Treatment of bacterial corneal ulcers with concentrated antibiotic eye drop. *Trans Ophthalmol Soc UK* 1982;102:11–14.
- 23 Lomholt JA, Moller JK, Ehlers N. Prolonged persistence on the ocular surface of fortified gentamicin ointment as compared to fortified gentamicin eye drops. *Acta Ophthalmol Scand* 2000;78:34–6.
- 24 Cutarelli PE, Lass JH, Lazarus HM, et al. Topical fluoroquinolones: antimicrobial activity and in vitro corneal epithelial toxicity. *Curr Eye Res* 1991;10:557–63.
- 25 O'Brien TP, Sawusah MR, Dick JD, et al. Topical ciprofloxacin treatment of pseudomonas keratitis in rabbits. *Arch Ophthalmol* 1988;106:1444–6.
- 26 Reidy JJ, Hobden JA, Hill JM, et al. The efficacy of topical ciprofloxacin and norfloxacin in the treatment of experimental pseudomonas keratitis. *Cornea* 1991;10:25–8.
- 27 Parks DJ, Abrams DA, Sarfarazi FA, et al. Comparison of topical ciprofloxacin to conventional antibiotic therapy in the treatment of ulcerative keratitis. *Am J Ophthalmol* 1993;115:471–7.
- 28 Hyndiuk RA, Eiferman RA, Caldwell DR, et al. Comparison of ciprofloxacin ophthalmic solution 0.3% to fortified tobramycin-cefazolin in treating bacterial corneal ulcers. *Ophthalmology* 1996;103:1854–63.
- 29 Inslar MS, Fisch LA, Silbernagel J, et al. Successful treatment of methicillin-resistant *Staphylococcus aureus* keratitis with topical ciprofloxacin. *Ophthalmology* 1991;98:1690–2.
- 30 Goldstein MH, Kowalski RP, Gordon YJ. Emerging fluoroquinolone resistance in bacterial keratitis. A 5-year review. *Ophthalmology* 1999;106:1313–18.
- 31 Hindler J. Antimicrobial susceptibility testing of gram negative bacteria: meeting the challenge of increasing resistance and decreasing budgets. *Clinical Microbiology Newsletter* 1995:17.
- 32 Elena PP, Jauch A. Ocular distribution of Lomefloxacin 0.3% after a single instillation in the infected eye of pigmented rabbits. *J Ocular Pharmacol Therapeutics* 1997;16:551–8.
- 33 McDermott ML, Tran TD, Cowden JW, et al. Corneal stromal penetration of topical ciprofloxacin in humans. *Ophthalmology* 1993;100:197–200.
- 34 Price FW jr, Whitson WE, Collins KS, et al. Corneal tissue levels of topically applied ciprofloxacin. *Cornea* 1995;14:152–6.
- 35 Donnenfeld ED, Schrier A, Perry HD, et al. Penetration of topically applied ciprofloxacin, norfloxacin, and ofloxacin into the aqueous humor. *Ophthalmology* 1994;101:902–5.



Bacterial keratitis: a prospective clinical and microbiological study

Frédéric Schaefer, Olivier Bruttin, Léonidas Zografos, et al.

Br J Ophthalmol 2001 85: 842-847

doi: 10.1136/bjo.85.7.842

Updated information and services can be found at:

<http://bjo.bmj.com/content/85/7/842.full.html>

References

These include:

This article cites 25 articles, 4 of which can be accessed free at:

<http://bjo.bmj.com/content/85/7/842.full.html#ref-list-1>

Article cited in:

<http://bjo.bmj.com/content/85/7/842.full.html#related-urls>

Email alerting service

Receive free email alerts when new articles cite this article. Sign up in the box at the top right corner of the online article.

Topic Collections

Articles on similar topics can be found in the following collections

[Cornea](#) (380 articles)
[Ocular surface](#) (452 articles)
[Conjunctiva](#) (170 articles)
[Eye Lids](#) (34 articles)
[Lacrimal gland](#) (69 articles)
[Tears](#) (69 articles)

Notes

To request permissions go to:

<http://group.bmj.com/group/rights-licensing/permissions>

To order reprints go to:

<http://journals.bmj.com/cgi/reprintform>

To subscribe to BMJ go to:

<http://group.bmj.com/subscribe/>