

# Electrophysiological changes after 360° retinotomy and macular translocation for subfoveal choroidal neovascularisation in age related macular degeneration

Christoph Lüke, Sabine Aisenbrey, Matthias Lüke, Giulia Marzella, Karl Ulrich Bartz-Schmidt, Peter Walter

## Abstract

**Aim**—To evaluate electrophysiological changes after 360° retinotomy and macular translocation for subfoveal choroidal neovascularisation in patients with age related macular degeneration (AMD).

**Methods**—A consecutive series of 32 patients suffering from subfoveal choroidal neovascularisation secondary to AMD underwent 360° retinotomy and macular translocation. The ERG served as the main parameter of the study and was recorded 1 day before the translocation surgery and no earlier than 4 weeks after the silicone oil removal.

**Results**—The scotopic ERG amplitudes were significantly reduced after translocation surgery. Depending on the applied flash luminance the mean b-wave amplitude reduction of the scotopic ERG varied between 67% (0.2 cd.s/m<sup>2</sup>) and 74% (0.03 cd.s/m<sup>2</sup>). The a-waves and b-waves of the saturating light response decreased significantly by 46% and 59%, respectively. The photopic a-wave and b-wave amplitudes were significantly lower after the translocation surgery resulting in a mean reduction of 27% and 43%, respectively.

**Conclusions**—Although macular translocation may provide the potential of preserving and even restoring vision in patients with subfoveal choroidal neovascular membranes secondary to AMD the present study indicates that a significant electrophysiological decrease is caused by surgical procedures associated with this technique. Further research is necessary to clarify if certain modifications of the surgical procedure are able to substantially reduce the neuroretinal trauma.

(Br J Ophthalmol 2001;85:928-932)

smaller than 3.5 MPS disc areas for new lesions and smaller than 6.0 MPS disc areas for recurrent lesions.<sup>2 3</sup>

Photodynamic therapy is a promising new treatment for neovascular AMD. Recent studies provide safety and efficacy data for primary treatment of choroidal neovascularisation (CNV)<sup>4</sup> and for retreatment of patients with reperfused CNV after initial photodynamic therapy.<sup>5</sup> A single photodynamic treatment with verteporfin typically leads to CNV closure shortly after treatment, but in almost all patients reperfusion of the CNV appears within 3 months.<sup>4</sup> Thus, after a single photodynamic treatment of a CNV secondary to AMD retreatments are usually necessary.

The results of a simple surgical removal of subfoveal choroidal neovascular membranes secondary to AMD have been disappointing owing to the poor visual outcome of these patients.<sup>6-9</sup> Removing a subretinal membrane includes the removal of pigment epithelium that secondly causes degeneration of the outer retina. For this reason Machermer,<sup>10 11</sup> in 1993, proposed surgically translocating the fovea towards an adjacent area with healthier pigment epithelium, Bruch's membrane, and choriocapillaris.

Several surgical approaches have been reported having in common a vitrectomy followed by the creation of a retinal detachment by infusion of fluid under the retina, either through the sclera or from the inside through the retina.<sup>10-15</sup> Differences among the surgical techniques include the use of peripheral retinotomies ranking in size from 180 to 360 degrees<sup>10-12</sup> and the use of varying strategies for scleral shortening.<sup>13-15</sup> In 1998 de Juan<sup>14</sup> introduced a variation of macular translocation, "limited rotation." This technique avoids retinotomies and intensive laser treatment during surgery but only provides a small distance of macular displacement compared with the aforementioned procedures. AMD mainly affects the choroid, the retinal pigment epithelium, and the sensory retina of the posterior eye pole. Macular translocation surgery involves all layers of the sensory retina. To date, no reliable electrophysiological data of retinal function after macular translocation surgery are available. The electroretinogram (ERG) reflects photoreceptor and higher order neuron activity of the retina. The aim of the present

Zentrum für  
Augenheilkunde,  
Universität Köln,  
Germany  
C Lüke  
S Aisenbrey  
M Lüke  
G Marzella  
P Walter

Universitätsaugenklinik,  
Tübingen, Germany  
K U Bartz-Schmidt

Correspondence to:  
Christoph Lüke, Zentrum  
für Augenheilkunde,  
Universität Köln,  
Joseph-Stelzmann Strasse 9,  
D-50924 Köln, Germany  
[aia18@uni-koeln.de](mailto:aia18@uni-koeln.de)

Accepted for publication  
20 February 2001

Subfoveal choroidal neovascularisation in patients with age related macular degeneration (AMD) is a leading cause of severe visual loss among the elderly in Western countries.<sup>1</sup> Currently, the only treatments that have been shown to beneficially influence the natural course of this disease are photocoagulation and photodynamic therapy. The Macular Photocoagulation Study (MPS) Group has demonstrated the beneficial effect of laser treatment for subfoveal lesions when they are well demarcated with a classic component, and are

study was to evaluate potential electrophysiological changes caused by macular translocation in patients with AMD.

## Materials and methods

### STUDY POPULATION

Before selection all patients underwent a routine ophthalmological examination including electroretinography and fluorescein angiography. The patients were considered to be suitable to enter into the study if the following inclusion criteria were fulfilled:

- (1) age of 60 years or older
- (2) a best corrected visual acuity between 20/40 and 20/200 in the eligible eye
- (3) AMD with new or recurrent subfoveal choroidal neovascularisation.

Possible alternatives, beneficial effects, and complications of macular translocation were explained in detail to all patients who were considered to be suitable for entry into the study. Patients who gave written consent for the translocation of the macula entered into the study.

### CLINICAL EXAMINATION

The electrophysiological testing was done by one experienced examiner unaware of the appearance of subjects' fundi or acuities. To exclude the influence of potential circadian fluctuations in the ERG recordings were performed in the morning at about 10 am. The ERG served as the main parameter of the study and was recorded 1 day before the translocation surgery and no earlier than 4 weeks after the silicone oil removal. The scotopic ERG was recorded according to ISCEV standards after a dark adaptation period of 30 minutes with fully dilated pupils. For the responses the flash luminance was adjusted at 0.01, 0.03, 0.1, and 0.2 cd.s/m<sup>2</sup>. After recording of the scotopic light responses the bright flash response using the the ISCEV standard flash of 2.4 cd.s/m<sup>2</sup> was elicited. After light adaptation of 10 minutes with a steady background illumination of 10 cd/m<sup>2</sup> photopic responses were recorded. Corneal contact lens electrodes (Echte & Pabst, Medical Workshop, Groningen, Netherlands) were used for ERG recordings. The recordings were performed using the Amplaid MK 15 Ganzfeld system (Amplaid, Milan, Italy) and a PC based signal acquisition and analysis software.

The best corrected visual acuity was measured by ETDRS charts (Lighthouse, Long Island, USA) using line assessment and the forced choice method.<sup>16</sup> All visual acuity values were conducted by two independent examiners who were not involved in the evaluation of the study results.

All patients had fundus photography and fluorescein angiography not more than 14 days before surgery. Angiographic studies of the choroidal neovascularisation were performed following the guidelines of Bressler<sup>17</sup> and the MPS. Choroidal neovascularisation was classified as classic, mixed, or occult.

### SURGERY

The surgery was performed under general anaesthesia. A standardised surgical procedure was initiated. In phakic eyes the surgical procedure started with a cataract extraction. A continuous curvilinear capsulorhexis of 4.5 mm in diameter was created. Phacoemulsification with in the bag implantation of a C loop haptic foldable acrylic lens (AcrySof, Alcon Model MA60BM) was performed through a self closing 3 mm sclerocorneal incision. A three port pars plana vitrectomy with separation and removal of the posterior hyaloid was performed. A small retinotomy outside the arcades was achieved by means of vertical scissors. Through this retinotomy injection of a calcium and magnesium free irrigating solution (BSS, Alcon Surgical, Fort Worth, TX, USA) with a 33 gauge subretinal cannula into the subretinal space, to detach the sensory retina from the retinal pigment epithelium, was introduced until a complete retinal detachment was achieved. In some cases a retinal manipulator was used to detach residual attachments of the sensory retina to the pigment epithelium. A 360° retinotomy was created close to the ora serrata and the subfoveal choroidal neovascularisation was then removed with subretinal forceps. If bleeding occurred the intraocular pressure was temporarily raised. Air-fluid exchange was performed and the retina was rotated superiorly or inferiorly under semifluorinated alkanes (Semifluran, Fluoron, Neu-Ulm, Germany) with relocation of the fovea on healthier pigment epithelium. The retina was reattached using perfluorcarbon liquid (Perfluorodecalin, Fluoron, Neu-Ulm, Germany) and the edges of the retinotomy were treated with endocoagulation. Finally, the vitreous cavity was filled with silicone oil 5000 cS. The standard postoperative regimen consisted of topical gentamicin and dexamethasone

### STATISTICS

For statistical analysis the *t* test was used; *p* < 0.05 was regarded as statistically significant. For analysis of correlation Pearson's coefficient was calculated.

### Results

A consecutive series of 18 female and 14 male patients suffering from a subfoveal choroidal neovascularisation were considered to be suitable for entry into the study. All patients who were enrolled completed the study. Thus, the ERG data from 32 eyes of 32 patients were analysed. The angiographic studies of the CNV revealed seven eyes with classic lesions, 11 eyes with an occult CNV, and six eyes with a mixed CNV. In eight eyes a sufficient classification of the choroidal neovascularisation was not possible owing the presence of a dense subretinal haemorrhage. The mean interval between the initial macular translocation surgery and the silicone oil removal was 127 days (SD 46 days). The mean interval between the postsurgical ERG examination and the silicone oil removal was 66 days (SD 46 days), but at least 28 days.

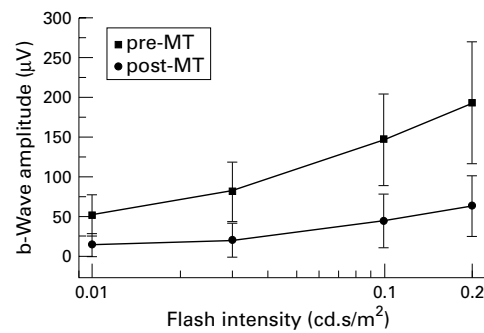


Figure 1 The b-wave amplitude of the scotopic electroretinogram before and after macular translocation with respect to the applied flash luminance. Mean (SD).

#### ELECTROPHYSIOLOGICAL RESULTS

In accordance with our recent results<sup>18</sup> we found a significant difference between the preoperative scotopic and photopic ERG amplitudes of the enrolled patients and the ERG data of an age matched control group (47 eyes/47 patients)<sup>18</sup> with no history of ocular pathology.

The scotopic ERG amplitudes were significantly reduced after translocation surgery. Depending on the applied flash luminance the mean b-wave amplitude reduction of the scotopic ERG varied between 67% (0.2 cd.s/m<sup>2</sup>) and 74% (0.03 cd.s/m<sup>2</sup>).

The a-waves and b-waves of the saturating light response decreased significantly by 46% and 59%, respectively. The a-wave implicit time of the saturating flash response was significantly prolonged by a mean value of 2.89 ms (12%), whereas the b-wave implicit time remained unaffected. The photopic a-wave and b-wave amplitudes were significantly lower after the translocation surgery resulting in a mean reduction of 27% and 43%, respectively. The photopic a-wave and b-wave implicit times remained unaffected by the surgical procedure. Table 1 summarises the ERG data of the study.

A subgroup analysis with respect to the CNV type did not show a significant difference in the ERG changes between the CNV

subgroups. A small but significant positive correlation between the b-wave amplitude reduction of the mixed rod/cone response and the duration of the surgery was found (Pearson's coefficient = 0.43; p = 0.03).

#### VISUAL ACUITY

Compared with the baseline examination the mean logMAR of all patients enrolled increased by 0.13 at the time of the postoperative ERG examination and by 0.03 at 12 months after surgery which is equivalent to a decrease of visual acuity by 1.3 and 0.3 on the ETDRS charts, respectively. At both visits the difference in visual acuity was statistically insignificant (p = 0.11; p = 0.67). The changes of visual acuity in each subgroup with respect to the CNV type were statistically analysed. Patients with a subretinal haemorrhage, a classic or mixed lesion did not show a significant change in visual acuity compared with the baseline examination, whereas patients presenting with an occult CNV showed a significant decrease at the time of the postoperative ERG examination (3.9 lines; p=0.02). One year after the surgery the difference in visual acuity for the subgroup of patients suffering from an occult CNV was no more significant (-2.0 lines; p = 0.157).

No significant correlation between the changes in visual acuity and any single presurgical ERG parameter was found.

#### Discussion

Macular translocation using 360° retinotomy and retinal rotation requires extensive surgery. During the surgical procedure the retina is exposed to considerable mechanical and ischaemic stress.

Electrophysiological impairment was equally apparent under photopic and scotopic conditions. Both a and b-waves were affected suggesting impairment of photoreceptor outer segments. Factors which may have influenced the functional outcome include the number of retinal photoreceptors cut off during retinotomy, the amount of retinal area treated with

Table 1 Electrophysiological outcome after 360° retinotomy and macular translocation

Rod responses	Presurgery	Post surgery	Reduction (%)	Statistical significance
0.01 cd.s/m <sup>2</sup> :				
b-wave amplitude (µV)	51.34 (26.03)	14.19 (13.56)	72.36	**
b-wave implicit time (ms)	112.60 (5.15)	91.70 (38.14)	18.56	*
0.03 cd.s/m <sup>2</sup> :				
b-wave amplitude (µV)	81.34 (37.53)	21.00 (21.25)	74.18	**
b-wave implicit time (ms)	107.4 (7.41)	99.4 (25.13)	7.45	ns
0.1 cd.s/m <sup>2</sup> :				
b-wave amplitude (µV)	147.91 (57.61)	45.69 (33.51)	69.11	**
b-wave implicit time (ms)	95.53 (9.88)	94.13 (26.14)	1.47	ns
0.2 cd.s/m <sup>2</sup> :				
b-wave amplitude (µV)	194.37 (76.73)	64.16 (37.82)	66.99	**
b-wave implicit time (ms)	86.53 (9.58)	92.25 (22.48)	- 6.61	ns
Mixed cone and rod responses:				
a-wave amplitude (µV)	91.81 (45.95)	49.16 (30.06)	46.45	**
a-wave implicit time (ms)	24.07 (1.36)	26.96 (6.05)	-12.01	*
b-wave amplitude (µV)	239.03 (93.49)	98.75 (64.44)	58.69	**
b-wave implicit time (ms)	46.93 (1.62)	48.47 (7.09)	3.28	ns
Cone responses:				
a-wave amplitude (µV)	40.69 (22.25)	29.78 (16.65)	26.81	*
a-wave implicit time (ms)	14.52 (2.72)	17.74 (8.99)	-22.34	ns
b-wave amplitude (µV)	238.91 (109.88)	101.75 (65.98)	42.59	**
b-wave implicit time (ms)	46.75 (2.00)	45.75 (12.79)	2.14	ns

Mean (SD) of the preoperative and postoperative ERG amplitudes (µV) and implicit times (ms). Reduction (%) in comparison with the initial presurgical value given. Significance of the paired t test. ns = not significant, \*0.05 > p > 0.001, \*\*p < 0.001.

photocoagulation, the duration of retinal detachment, the exposure of the retina to mechanical, ischaemic, and light stress, and also the type of the applied irrigating solution.

Schurmans<sup>19</sup> performed photocoagulation in rabbits after which the ERG response was compared with the histologically measured area of retinal damage. They concluded that, when less than 30% of the retina is treated, the ERG is reduced proportionally to the retinal area destroyed. However, Liang and colleagues<sup>20</sup> found that the change in the ERG and the area of retina coagulated is not closely correlated. This lack of close correlation may be interpreted as a reflection of the variability of the health of different areas of the coagulated retina and also of the treatment technique. In the present study a constant number of argon laser burns was applied in each patient destroying less than 20% of the whole retinal area. Thus, the application of argon laser photocoagulation during the surgical procedure may only contribute to about one third of the ERG amplitude reduction.

Although the changes in the retinal pigment epithelium are thought to constitute the primary lesion in AMD,<sup>21</sup> it is the dysfunction and death of photoreceptors that accounts for vision loss. The cone and rod systems are both known to be functionally impaired in patients with AMD. A significant photoreceptor loss in patients with AMD beginning in the parafovea has been demonstrated.<sup>22</sup> Therefore, before any surgical intervention there is significant pre-existing damage to the photoreceptors and the retinal pigment epithelium. This is substantiated by our recent findings which demonstrate a significant difference between the scotopic and photopic ERG of AMD patients and age matched normal controls.<sup>18</sup> Furthermore, we found a significant difference between the preoperative scotopic and photopic ERG amplitudes of AMD patients and the ERG data of the historical age matched normal controls.<sup>18</sup> This suggests that in patients suffering from AMD wider pigment epithelial and retinal areas are affected than one may infer from the fundoscopic appearance.

In ultrastructural studies a partial loss of receptor outer segments was found after macular translocation. It was proposed that the outer segments were torn away during the separation and that the amount of outer segment loss depends on the speed of the retinal separation process.<sup>10</sup> Lafaut<sup>23</sup> found outer segment material in histological specimens of choroidal neovascularisations removed during macular translocation surgery.

It is well known that the ERG becomes unrecordable about 30 minutes after total retinal detachment.<sup>24-25</sup> Previous studies in otherwise healthy animals demonstrated that retinal reattachment results in an early and progressive recovery of retinal electrical activity.<sup>26-28</sup> The recovery of the ERG is known to correlate with improved function of the outer segments of the photoreceptors.<sup>28</sup> Since there is pre-existing damage to the retinal interface in AMD patients, a normal regeneration of receptor outer segments is unlikely to occur

after macular translocation. This may explain the persistent reduction of the ERG even 200 days after the initial relocation surgery.

No apparent differences were reported between rod and cone outer segments in the rate of degeneration ultrastructurally after retinal detachment.<sup>29</sup> It is generally agreed that the duration and height of macular detachment correlate with the visual outcome and the ERG amplitude after reattachment.<sup>24</sup> In the present study a similar observation was made. A small but significant positive correlation between the amplitude reduction of the mixed rod/cone response and the duration of the surgery was shown. This finding emphasises the need for a short period of retinal detachment during translocation surgery.

No significant correlation between the changes in visual acuity and presurgical ERG parameters could be determined. Thus, the presurgical ERG status has no predictive power with respect to the visual outcome after macular translocation.

Several studies investigated the effects of intraocular silicone oil on animal and human retinal function.<sup>30-35</sup> Previous reports of changes in the ERG following silicone oil tamponade in animal eyes have been conflicting. Some authors reported early<sup>32</sup> or complete<sup>35</sup> extinction of the ERG, others<sup>30-34</sup> could not detect persistent electroretinographic changes even after a prolonged period of silicone oil tamponade. There is very little information available about the effects of vitrectomy with silicone oil tamponade on retinal function in humans.

Silicone oil is known to reduce ERG amplitude by 40–50%.<sup>36</sup> To avoid the effects of silicone on the retinal light response the measurements of postoperative ERG were performed no earlier than 4 weeks after silicone oil removal. Thus, a substantial contribution of the silicone oil tamponade to the electrophysiological changes is unlikely.

The functional results after macular surgery may be influenced by the type or composition of ocular irrigating solution that is used during the procedure. The creation of the retinal detachment is achieved by infusion of a calcium and magnesium free intraocular solution into the subretinal space. The use of a calcium and magnesium free fluid instead of regular balanced salt solution facilitates retinal detachment.<sup>37</sup> A recent ultrastructural study demonstrated a reduced retinal adhesion after transretinal injection of a calcium free buffered solution into the subretinal space in pigmented rabbits. The retinal photoreceptor layer showed swelling and fragmentation of the outer segments with partial loss of the plasma membrane.<sup>38</sup> The significance of calcium and magnesium for retinal function has long been recognised and their specific roles have been discussed.<sup>39</sup> Sickel described in detail the effects of changes of the ionic environment on the ERG. He demonstrated that low calcium and magnesium concentrations may lead to a persistent reduction in the ERG amplitudes.<sup>40</sup> A substantial contribution of the modified ionic environment to the severe postsurgical

ERG reduction seems possible. Further research is necessary to clarify if certain modifications of the surgical technique—for example, infusion of a regular instead of a calcium and magnesium free salt solution, are important in reducing the neuroretinal trauma. Furthermore, a comparison of our ERG data after 360° retinotomy and macular translocation with the ERG pattern—for example, after limited macular translocation which avoids retinotomies and extensive laser coagulation, may help to differentiate the contribution of the surgical components to the electrophysiological changes.

Although macular translocation may provide the potential of preserving and even restoring vision in patients with subfoveal choroidal neovascular membranes secondary to AMD the present study indicates that a significant electrophysiological decrease is caused by surgical procedures associated with this technique.

- 1 Leibowitz HM, Maunder LR, Milton RC. The Framingham Eye Study Monograph. *Surv Ophthalmol* 1980;24:335–610.
- 2 Macular Photocoagulation Study Group. Laser photocoagulation of subfoveal recurrent neovascular lesions in age-related macular degeneration: results of a randomized clinical trial. *Arch Ophthalmol* 1991;109:1232–41.
- 3 Macular Photocoagulation Study Group. Laser photocoagulation of subfoveal neovascular lesions of age-related macular degeneration: updated findings from two clinical trials. *Arch Ophthalmol* 1993;111:1200–9.
- 4 Miller JW, Schmidt-Erfurth U, Sickenberg M, et al. Photodynamic therapy with verteporfin for choroidal neovascularisation caused by age-related macular degeneration. *Arch Ophthalmol* 1999;117:1161–73.
- 5 Treatment of Age-related Macular Degeneration With Photodynamic Therapy Study Group. Photodynamic therapy of subfoveal choroidal neovascularisation in age-related macular degeneration with verteporfin. *Arch Ophthalmol* 1999;117:1329–45.
- 6 Berger AS, Kaplan HJ. Clinical experience with the surgical removal of subfoveal neovascular membranes. Short term postoperative results. *Ophthalmology* 1992;99:969–76.
- 7 Thomas MA, Dickinson JD, Melberg NS, et al. Visual results after surgical removal of subfoveal choroidal neovascular membranes. *Ophthalmology* 1994;101:1384–96.
- 8 Lambert HM, Capone A, Aaberg TM, et al. Surgical excision of subfoveal neovascular membranes in age-related macular degeneration. *Am J Ophthalmol* 1992;113:257–62.
- 9 Thomas MA, Grand MG, Williams DF, et al. Surgical management of subfoveal choroidal neovascularisation. *Ophthalmology* 1992;99:952–68.
- 10 Machemer R, Steinhilber UH. Retinal separation, retinotomy, and macular translocation, I: experimental studies in the rabbit eye. *Graefes Arch Clin Exp Ophthalmol* 1993;231:629–34.
- 11 Machemer R, Steinhilber UH. Retinal separation, retinotomy, and macular relocation, II: a surgical approach for age-related macular degeneration? *Graefes Arch Clin Exp Ophthalmol* 1993;231:635–41.
- 12 Ninomiya Y, Lewis JM, Hasegawa T, et al. Retinotomy and foveal translocation for surgical management of subfoveal choroidal neovascular membranes. *Am J Ophthalmol* 1996;122:613–21.
- 13 Imai K, Loewenstein A, de Juan EJ. Translocation of the retina for management of subfoveal choroidal neovascularization, I: experimental studies in the rabbit eye. *Am J Ophthalmol* 1998;125:627–34.
- 14 De Juan EJ, Loewenstein A, Bressler NM, et al. Translocation of the retina for management of subfoveal choroidal neovascularization, II: a preliminary report in humans. *Am J Ophthalmol* 1998;125:635–46.
- 15 Fujikado T, Ohji M, Saito Y, et al. Visual function after foveal translocation with scleral shortening in patients with myopic neovascular maculopathy. *Am J Ophthalmol* 1998;125:647–56.
- 16 Ferris FL, Kassof A, Bresnick GH, et al. New visual acuity charts for clinical research. *Am J Ophthalmol* 1982;94:91–6.
- 17 Bressler NM, Bressler SB, Gragoudas ES, et al. Clinical characteristics of choroidal neovascular membranes. *Arch Ophthalmol* 1987;105:209–13.
- 18 Walter P, Widder RA, Lücke C, et al. Electrophysiological abnormalities in age-related macular degeneration. *Graefes Arch Clin Exp Ophthalmol* 1999;237:962–8.
- 19 Schuurmans RP, de Lege WA, van Lith GHM, et al. The influence of photocoagulation of the retina on the electroretinogram. *Doc Ophthalmol* 1977;42:369–73.
- 20 Liang JC, Fishman GA, Huamonte FU, et al. Comparative electroretinograms in argon laser and xenon arc parretinal photocoagulation. *Br J Ophthalmol* 1983;67:520–5.
- 21 Young RW. Pathophysiology of age-related macular degeneration. *Surv Ophthalmol* 1987;31:291–306.
- 22 Curcio CA, Medeiros NE, Millican CL. Photoreceptor loss in age-related macular degeneration. *Invest Ophthalmol Vis Sci* 1996;37:1236–49.
- 23 Lafaut BA, Bartz-Schmidt KU, Vanden Broecke C, et al. Clinicopathological correlation in exudative age related macular degeneration: histological differentiation between classic and occult choroidal neovascularisation. *Br J Ophthalmol* 2000;84:239–43.
- 24 Si-Dong K, Nobushi N, Futoshi M, et al. Electrical responses from locally detached retina and its recovery after reattachment. *Ophthalmologica* 1996;210:195–9.
- 25 Rendahl I. The electroretinogram in retinal detachment. *Int Ophthalmol Clin* 1969;9:1025–38.
- 26 Foulds WS, Ikeda H. The effects of detachment of the retina on the induced and resting ocular potentials in the rabbit. *Invest Ophthalmol Vis Sci* 1966;5:93–108.
- 27 Blach RK, Behrmann J. The electrical activity of the eye in retinal detachment. *Trans Ophthalmol Soc UK* 1967;87:263–6.
- 28 Hamasaki DI, Machemer R, Norton EWD. Experimental retinal detachment in the owl monkey. VI. The ERG of the detached and reattached retina. *Graefes Arch Clin Exp Ophthalmol* 1969;177:212–21.
- 29 Anderson DH, Stern WH, Fisher SK, et al. Retinal detachment in the cat: the pigment epithelial-photoreceptor interface. *Invest Ophthalmol Vis Sci* 1983;24:906–71.
- 30 Frumar KD, Gregor ZJ, Carter RM, et al. Electroretinographic changes after vitrectomy and intraocular tamponade. *Retina* 1985;5:16–21.
- 31 Armaly MF. Ocular tolerance to silicones. I. Replacement of aqueous and vitreous by silicone fluids. *Arch Ophthalmol* 1962;68:390.
- 32 Lee P, Donovan RH, Mukai N. Intravitreal injection of silicone: an experimental study. I. Clinical picture and histology of the eye. *Ann Ophthalmol* 1969;1:15.
- 33 Ober RR, Blanks JC, Ogden TE. Experimental retinal tolerance to liquid silicone. *Retina* 1983;3:77–84.
- 34 Meredith TA, Lindsey DT, Goldman AI. Electroretinographic evaluation after vitrectomy and silicone oil injection. *Invest Ophthalmol Vis Sci* 1981;20.
- 35 Constable I. Supraviscous silicone oil. *Aust J Ophthalmol* 1982;10:5–11.
- 36 Momirov D, van Lith GHM, Zivojnovic R. Electroretinogram and electrooculogram of eyes with intravitreally injected silicone oil. *Ophthalmologica* 1983;186:183–8.
- 37 Faude F, Wiedemann P, Reichenbach A. A detachment infusion for macular translocation surgery. *Retina* 1999;19:173–4.
- 38 Szurman P, Thumann G, Schraermeyer U, et al. Modification of retinal adhesion for macular translocation—ultrastructural findings after artificial retinal detachment. *Invest Ophthalmol Vis Sci* 2000;41:S181.
- 39 Beuchelt H. Die Abhängigkeit der photoelektrischen Reaktion des Froschauges von den ableitenden Medien. *Z Biol* 1921;73:205–30.
- 40 Fuortes MGF, ed. Retinal metabolism in dark and light. In: *Handbook of sensory physiology*. Vol VII, 2. Berlin, Heidelberg, New York: Springer, 1972:667–727.



# Electrophysiological changes after 360° retinotomy and macular translocation for subfoveal choroidal neovascularisation in age related macular degeneration

Christoph Lüke, Sabine Aisenbrey, Matthias Lüke, et al.

*Br J Ophthalmol* 2001 85: 928-932

doi: 10.1136/bjo.85.8.928

---

Updated information and services can be found at:

<http://bjo.bmj.com/content/85/8/928.full.html>

---

*These include:*

## References

This article cites 35 articles, 10 of which can be accessed free at:

<http://bjo.bmj.com/content/85/8/928.full.html#ref-list-1>

Article cited in:

<http://bjo.bmj.com/content/85/8/928.full.html#related-urls>

## Email alerting service

Receive free email alerts when new articles cite this article. Sign up in the box at the top right corner of the online article.

---

## Topic Collections

Articles on similar topics can be found in the following collections

[Choroid](#) (434 articles)

[Retina](#) (1207 articles)

---

## Notes

---

To request permissions go to:

<http://group.bmj.com/group/rights-licensing/permissions>

To order reprints go to:

<http://journals.bmj.com/cgi/reprintform>

To subscribe to BMJ go to:

<http://group.bmj.com/subscribe/>