

Optic disc changes following trabeculectomy: longitudinal and localisation of change

Aachal Kotecha, Dilani Siriwardena, Frederick W Fitzke, Roger A Hitchings, Peng T Khaw

Abstract

Aims—To determine whether there were any changes in the optic disc at 2 years after trabeculectomy. To determine the factors that most influenced change and whether change was localised to any region of the optic disc.

Methods—95 patients undergoing routine trabeculectomy as part of the ongoing Moorfields/MRC 5-fluorouracil trial were recruited into the study. Eyes were imaged preoperatively (4 (SD 3) weeks) with the Heidelberg retina tomograph (HRT, Heidelberg Engineering), and at 3 months (SD 2 weeks), 1 year (SD 1 month), and 2 years (SD 1 month) after surgery. Parameters investigated for change were rim area, rim volume, and maximum cup depth. The predefined segment analysis available on the HRT analysis software was used to determine segmental change.

Results—The images of 70 patients were analysed. Intraocular pressure reduced from 22.25 (SD 3.76) mm Hg, at the time of preoperative imaging to 15.27 (SD 4.96) mm Hg at 3 months, 14.38 (SD 3.89) mm Hg at 1 year, and 13.80 (SD 3.54) mm Hg at 2 years after trabeculectomy. An increase in rim area and rim volume was present at all time points after surgery, but was only found to be statistically significant at 2 years after surgery. Maximum depth of cup reduced by month 3 and month 12, but showed a slight increase at 2 years after surgery, although this was still lower than the preoperative measure. Segmental analysis found a significant change in rim volume in the nasal, inferonasal, superonasal, and superotemporal regions at 2 years after surgery. No significant regional localisation for change was found at any other time point or in any other parameter investigated.

Conclusions—Reversal of disc cupping is present at 2 years after trabeculectomy. The factor most influencing change is reduction of intraocular pressure. Segmental analysis showed that change in rim volume was greatest in the nasal, inferonasal, superonasal and superotemporal regions at 2 years.

(Br J Ophthalmol 2001;85:956-961)

Reversal of optic disc cupping following intraocular pressure reduction is a well known phenomenon^{1 2-10} and changes seen in juvenile glaucomas are more pronounced than those found in adult patients.¹¹⁻¹³ Examination of stereodisc photographs^{1 3 14} have shown that changes do occur in adults, but of a smaller magnitude than in children. The advent of more sophisticated fundal imaging techniques means that these changes are now more easily quantifiable. Many studies have been done to quantify the degree of optic disc change following pressure reduction in experimental models,^{6 15-18} and in human subjects following pressure reduction by medical and surgical treatments^{3 7 19 20} and by trabeculectomy alone.^{8-10 21-23} The longest follow up period investigated was 12 months,²² and all studies looked at the global change in disc parameters.

The clinical significance of these disc changes appears to be unclear, although reports have suggested that there may be an associated improvement of visual function that corresponds to this improvement in disc appearance.^{5 10 19 24 25}

The purpose of this study was threefold:

- to investigate the evolution of change within the optic disc 2 years after trabeculectomy
- to determine the factors influencing change
- to determine the localisation of change.

Methods

Patients due to undergo trabeculectomy were recruited from the ongoing Moorfields/Medical Research Council UK 5-fluorouracil trial currently running at Moorfields Eye Hospital and the Institute of Ophthalmology in London. The project was reviewed and approved by the ethics committee of Moorfields Eye Hospital, and performed in accordance with the 1964 Declaration of Helsinki. Ninety five eyes of 95 patients (mean age 65.1 years; range 45-80) had confocal scanning laser disc imaging with the Heidelberg retina tomograph 4 weeks before surgery (SD 3 weeks), and at 3 months (SD 2 weeks), 1 year (SD 1 month), and 2 years (SD 1 month) after surgery.

The Heidelberg retina tomograph is a confocal scanning diode laser (670 nm) ophthalmoscope that acquires topographic images of the optic disc and peripapillary retina. The details of the instrument have been described previously²⁶⁻²⁸ and its reproducibility has been established.²⁸⁻³¹ Disc imaging was performed

Wound Healing
Research Unit,
Department of
Pathology, Institute of
Ophthalmology,
London, UK
A Kotecha
D Siriwardena
P T Khaw

Laboratory of
Physiological Optics,
Department of Visual
Science, Institute of
Ophthalmology,
London, UK
A Kotecha
F W Fitzke

Glaucoma Research
Unit, Moorfields Eye
Hospital, London UK
A Kotecha
D Siriwardena
R A Hitchings
P T Khaw

Correspondence to:
Miss Aachal Kotecha,
Glaucoma and Wound
Healing Research Unit,
Institute of Ophthalmology,
11-43 Bath Street, London,
EC1V 9EL, UK
a.kotecha@ucl.ac.uk

Accepted for publication
26 March 2001

through a pupil dilated with tropicamide 1% eyedrops, and three images were taken at each imaging session using a 15 degree field of view. Images were inspected for eye movements and the optimum images were saved. The mean topography of three images was used in all analyses using software version 2.01. A contour line was drawn around the optic disc of the preoperative mean topography by the same observer (AK) and this line was exported to the postoperative images using the "export contour line" function that is available with the program. The standard reference plane was used. Keratometry was also performed on these patients preoperatively and postoperatively, and the appropriate reading was entered into the HRT program at each imaging visit.

HRT software analysis version 2.01 has a feature that automatically scales and "magnification corrects" the contour line when it is exported to another mean topography image. However, in order to maintain a quality control over the images used in the analysis, and counter any possible effects of magnification change, mean topography images had to fulfil two criteria. These were:

- (1) mean topography standard deviation of less than $40 \mu\text{m}$ ³²
- (2) a refractive error change (or change in focus setting) of less than 2 dioptres within the four imaging time points.³³

If these criteria were not met for any of the images within the four imaging time points, or if the exported contour line did not fit exactly over the optic disc in any image, then the patient data were excluded from the analysis.

The parameters investigated for change following surgery were rim area and rim volume and maximum cup depth. Rim area was defined as the total area within the contour line minus the cup area. Rim volume was defined as the total volume of those parts within the contour line but above the reference plane. The HRT generates a surface other than the reference plane known as the "curved surface." The height of the centre of the curved surface is equal to the mean height of the optic disc margin (as defined by the drawn contour line). Mapping a straight line from this centre to a point on the contour line thus generates the surface itself. The maximum cup depth is therefore defined as the average depth of the 5% of pixels with the largest depth values within the disc measured from the curved surface. To investigate regional changes, the HRT predefined segments option was used. This divides the disc into six sectors—nasal, superonasal, superotemporal, temporal, inferotemporal, and inferonasal. Optic disc cupping can be of a focal or diffuse variety, and it is possible that segmental changes may not be detectable if the degree of pre-existing disc damage is greater in one segment than another. Therefore, we wished to quantify the depth of pre-existing segmental disc damage. The new HRT software incorporates a Moorfields analysis feature, that has been described in detail elsewhere.^{34 35}

Briefly, it gives a predicted value of the global and segmental disc rim area based on the size of the optic disc and a range of normal

values. For this study, the predicted rim area in each of the six segments was recorded, and the ratio of the actual rim area to the predicted rim area (for it to be classified as normal) in each segment was calculated. We have termed this ratio "rim index."³⁶ If the rim index is a value of 1 or above, the rim area of the disc segment is within the predicted limits for the subjects disc size. If the rim index value is less than 1, it indicates that the rim area is less than that predicted. The lower the rim index value, the greater the likelihood that the segment has an acquired rim loss. The rim index, therefore, gives a method for determining the degree of pre-existing segmental damage.

Global and segmental change in the optic disc were investigated at three time points—3, 12, and 24 months after surgery—using the Wilcoxon signed ranks test. A non-parametric test was used as examination of the preoperative disc data showed a skewed distribution.

To determine the possible relation between reversal and other factors besides degree of intraocular pressure reduction, the patients' age and degree of pre-existing glaucomatous damage were recorded. All patients had a 24-2 threshold Humphrey visual field test (Humphrey Instruments) 4 (SD 3) weeks before surgery. We used the average mean deviation of the last two most reliable preoperative fields (reliability indices, < 30% false positives and negatives, < 25% fixation losses, and < 2 dB difference in total mean deviation between the two fields) as a measure of pre-existing disease. Linear regression analysis was used to examine the effect of these three factors on change in rim area, volume, and maximum cup depth.

All analyses were performed using SPSS version 10 software, and significance was defined as a p value of < 0.001. A strict p value was chosen to compensate for the multiple significance tests that were being performed to determine localised change.

Results

The results for 70 eyes were examined. Data were not analysed for 25 patients, because of incomplete imaging data (n=13), refractive error changes of more than 2 dioptres (n=5), and mean topography standard deviations of more than $40 \mu\text{m}$ (n=7), as defined by the methods section. The average age of the analysed patient group was 65.7 (SD 9.5) years, and preoperative mean deviation was -9.49 (SD 8.41) dB (Table 1).

Intraocular pressure reduced from 22.25 (SD 3.76) mm Hg, at the time of preoperative imaging, to 15.27 (SD 4.96) mm Hg at 3

Table 1 Demographics of study group

Number of patients	70
Age	65.74 (9.5)
Females	20
POAG	63
CNAG	2
PXE glaucoma	5
Preoperative mean deviation	9.49 (8.41)
Preoperative IOP	22.33 (3.73)

POAG = primary open angle glaucoma, CNAG = chronic narrow angle glaucoma, PXE glaucoma = pseudoexfoliative glaucoma.

Table 2 Change in global disc parameters

	Preop	3 months	1 year	2 years	p at 2 years
IOP (mm Hg)	22.33 (3.73)	15.2 (4.96)	14.38 (3.89)	13.80 (3.54)	<0.001*
Rim area (mm ²)	0.901 (0.349)	0.927 (0.350)	0.928 (0.361)	0.954 (0.382)	0.025
Rim volume (mm ³)	0.179 (0.109)	0.189 (0.115)	0.194 (0.125)	0.221 (0.137)	<0.001*
Maximum cup depth mm	0.689 (0.215)	0.673 (0.196)	0.661 (0.202)	0.668 (0.207)	0.150

Figures are means (SD). Asterisk represents difference significance to predefined level p<0.001 (Wilcoxon ranks test).

Table 3 Change in segmental disc parameters

Region	Preop rim index	Preop rim area (mm ²)	3 month rim area (mm ²)	1 year rim area (mm ²)	2 year rim area (mm ²)	p Value at 2 years
Temporal	0.55	0.127 (0.073)	0.131 (0.073)	0.128 (0.072)	0.133 (0.079)	0.258
Superotemporal	0.53	0.097 (0.057)	0.103 (0.062)	0.104 (0.062)	0.105 (0.064)	0.007
Inferotemporal	0.48	0.099 (0.068)	0.101 (0.068)	0.101 (0.071)	0.106 (0.071)	0.131
Nasal	0.72	0.297 (0.119)	0.302 (0.116)	0.302 (0.118)	0.311 (0.122)	0.185
Superonasal	0.63	0.137 (0.054)	0.140 (0.058)	0.142 (0.061)	0.144 (0.063)	0.035
Inferonasal	0.66	0.145 (0.065)	0.149 (0.066)	0.151 (0.066)	0.154 (0.070)	0.024

Region	Preop rim index	Preop rim volume (mm ³)	3 month rim volume (mm ³)	1 year rim volume (mm ³)	2 year rim volume (mm ³)	p Value at 2 years
Temporal	0.55	0.009 (0.007)	0.010 (0.009)	0.010 (0.009)	0.013 (0.021)	0.218
Superotemporal	0.53	0.018 (0.014)	0.020 (0.016)	0.021 (0.017)	0.024 (0.023)	0.002
Inferotemporal	0.48	0.018 (0.016)	0.018 (0.018)	0.019 (0.020)	0.022 (0.023)	0.012
Nasal	0.72	0.064 (0.044)	0.069 (0.047)	0.069 (0.049)	0.079 (0.053)	<0.001*
Superonasal	0.63	0.032 (0.019)	0.034 (0.020)	0.036 (0.022)	0.039 (0.025)	<0.001*
Inferonasal	0.66	0.037 (0.030)	0.039 (0.030)	0.040 (0.032)	0.045 (0.032)	0.002

Region	Preop rim index	Preop max depth cup (mm)	3 month max depth cup (mm)	1 year max depth cup (mm)	2 year max depth cup (mm)	p Value at 2 years
Temporal	0.55	0.622 (0.212)	0.601 (0.198)	0.595 (0.195)	0.589 (0.203)	0.008
Superotemporal	0.53	0.690 (0.219)	0.669 (0.207)	0.665 (0.209)	0.666 (0.218)	0.064
Inferotemporal	0.48	0.620 (0.213)	0.596 (0.195)	0.594 (0.193)	0.602 (0.205)	0.225
Nasal	0.72	0.611 (0.242)	0.599 (0.230)	0.574 (0.234)	0.575 (0.238)	0.011
Superonasal	0.63	0.685 (0.230)	0.670 (0.220)	0.664 (0.229)	0.671 (0.237)	0.372
Inferonasal	0.66	0.607 (0.225)	0.582 (0.210)	0.570 (0.207)	0.575 (0.211)	0.087

Figures are means (SD). Asterisk represents difference significance to predefined level p<0.001 (Wilcoxon ranks test).

months, 14.38 (SD 3.89) mm Hg at 1 year, and 13.80 (SD 3.54) mm Hg at 2 years after trabeculectomy. In percentage terms, this represents a reduction of 29.07% (SD 28.37%) at 3 months, 33.71% (SD 21.03%) at 1 year, and 36.62% (SD 18.64%) at 2 years.

GLOBAL ANALYSIS

There was an increase in global rim area (mean (mm²) preoperatively 0.901 (SD 0.349); 3 months 0.927 (SD 0.350); 1 year 0.928 (SD 0.361); 2 years 0.954 (SD 0.382)) and global rim volume (mean (mm³) preoperatively 0.179 (SD 0.109); 3 months 0.189 (SD 0.115); 1 year 0.194 (SD 0.125); 2 years 0.221 (SD 0.137)) over the 2 year period following trabeculectomy. These changes were only significant at 2 years postoperatively. The maximum depth of the cup decreased at 3 months and 1 year, but showed a slight increase at 2 years, although this was still less than that found at the preoperative imaging session (mean (mm) preoperatively 0.689 (SD 0.215); 3 months 0.673 (SD 0.196); 1 year 0.661 (SD 0.202); 2 years 0.668 (SD 0.207)). These changes, however, were not significant (Table 2).

SEGMENTAL ANALYSIS

Rim area increased over the 2 year period, but was not localised to one area. Analysis of rim volume change found that at 2 years, "significant" increases occurred in the nasal (p<0.001) and superonasal (p<0.001) segments, as well as

in the inferonasal (p=0.002) and the superotemporal segment (p=0.002), although changes in these last two segments did not quite meet our "significance" level criteria. No significant change in rim volume in any segment was found at the earlier two time points. Change in maximum depth was significantly greatest in the nasal region of the disc at year 1, but this became non-significant by year 2. For the group, the average rim index was smallest in the inferotemporal region, and greatest in the nasal region. This would imply that the region with

Table 4 Linear regression coefficients for factors age, preoperative mean deviation (MD) and change in IOP

At 3 months			
Factor	Rim area	Rim volume	Max cup depth
Age	-0.068	-0.126	-0.022
Preop MD	0.031	-0.090	-0.048
ΔIOP at 3 months	-0.186	0.025	0.354
At 1 year			
Factor	Rim area	Rim volume	Max cup depth
Age	-0.181	-0.160	0.192
Preop MD	-0.035	0.010	-0.021
ΔIOP at 1 year	-0.445*	-0.250*	-0.415*
At 2 years			
Factor	Rim area	Rim volume	Max cup depth
Age	-0.262	-0.217	0.081
Preop MD	0.014	0.060	-0.105
ΔIOP at 2 years	-0.452*	-0.260*	-0.400*

*Difference significance to predefined level p<0.001; †significance at p<0.05 level.

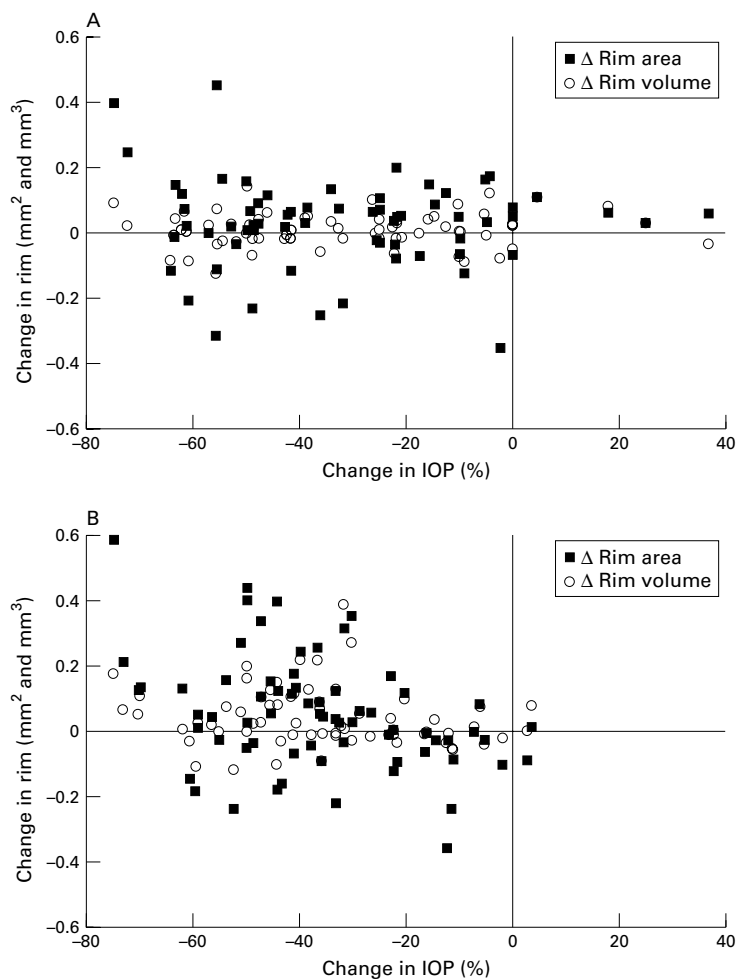


Figure 1 Relation between change in rim parameters and percentage change in intraocular pressure (IOP). (A) At 3 months. Change rim area: $r = -0.186$; change rim volume: $r = 0.025$. (B) At 2 years. Change rim area: $r = -0.452$; change rim volume: $r = 0.260$. See Table 4.

the greatest degree of disc damage was the inferotemporal region (Table 3)

FACTORS INFLUENCING CHANGE

The three factors investigated were age, change in intraocular pressure, and degree of overall preoperative damage as defined by preoperative mean deviation. At 3 months no factor appeared to have a significant influence on the change in disc parameters investigated. There was a significant association between reduction in intraocular pressure and change in rim area and cup depth, and a smaller association with rim volume. Age and degree of pre-existing disease, as defined using the preoperative mean deviation, had no effect on disc reversal (Table 4, Fig 1A and B).

Discussion

The results of this study indicate that reversal of disc cupping following trabeculectomy can be present up to 2 years after pressure reduction. Work by Irak *et al*⁶ found that reversal of cupping persisted up to 3 months after surgery and that the factor most influencing change was reduction in intraocular pressure. In contrast, work by Topouzis and co-workers²³ found that for their group of 25

patients, reversal of cupping was present at 2 weeks after surgery, but disappeared by 4 and 8 months postoperatively. Their group of patients had a large reduction in intraocular pressure (49.3% (SD 14.9%)), and had preoperative rim volume (mean 0.163 mm³) that was comparable to our group (mean 0.179 mm³). However, the average preoperative mean deviation of their group was 13.2 (SD 6.8) dB, compared with our 9.49 (SD 8.41) dB, suggesting that our group had fewer patients with advanced disease. Experimental studies have shown that the earlier the stage of glaucoma, the more likely reversal of cupping will occur.^{16 17} Although linear regression analysis did not find any significant association between degree of pre-existing disease and disc reversal it is possible that our group did not have a wide enough range of pre-existing disease for a relation to be detected.

The overall pressure reduction in our group (-36.62% (SD 18.64%) at 2 years) was not as large as that reported by the previous two groups, but linear regression analysis did show that this was an important factor in determining disc change. This agrees with other studies that have shown that pressure reduction is an important factor in cupping reversal^{5-7 15 37} and it has been suggested that a 30% pressure reduction is necessary before any disc reversal occurs. Both groups mentioned above did not find any significant association between disc reversal and age, as was the same for our group of subjects. However, reports have suggested that the degree of optic nerve head compliance decreases with age,³⁸⁻⁴¹ so one could expect age to have a significant effect on the ability of the lamina to move adequately with IOP reduction, which would be indicated by the mean cup depth. A possible reason for our and earlier studies' finding of no such movement is the mean age group of all three studies (Irak *et al* 70.9 years; Topouzis *et al* 65 years; our group 65.7 years); if there had been more younger patients in the studies, then such an effect may have been found.

It is believed that the main site of glaucomatous damage is at the lamina cribrosa area, and that raised intraocular pressure causes a bowing back of the lamina, resulting in the damage to the nerve fibre bundles passing through the cribrosal plates.^{42 43} It has generally been accepted that one of the main reasons for an apparent improvement in optic nerve appearance with IOP reduction is a reduction in the posterior bowing of the lamina cribrosa, giving relief to these compressed nerve fibre bundles. It has also been shown experimentally that reversal is more likely to occur in early stages of the disease.^{16 17} The pattern of optic disc cupping is such that the last area of the disc to be affected is the nasal disc region, and in particular the upper nasal region.^{44 45} In our group, segmental improvement was localised to the nasal regions, and the rim index value for this group of patients was largest in the nasal segment (0.72), indicating that this segment had the least degree of pre-existing damage. The inferotemporal disc region has been shown to be the site of early glaucomatous damage,⁴⁴ and in our group this region had the

lowest rim index value (0.48), indicating that this area had a greater degree of pre-existing damage. A possible explanation for the improvement being confined to the nasal disc regions may be because this area was least affected by the disease and so, possibly, nerve fibre bundle compression was not as long-standing or as permanent as that within the inferotemporal disc regions. Therefore, with IOP reduction, and forward shifting of the lamina cribrosa, the nerve fibres within the nasal region may regain their original shape, while those within the inferotemporal disc region may be too damaged to be able to do so.

Significant segmental change in rim volume was detected, and not in rim area. However, inspection of the results (Table 3) shows that a steady increase in rim area was found at all three postoperative time points, having greatest magnitude in the nasal disc regions, but was not statistically significant. The standard deviations of the area measurements were much larger than those found with the volumetric measurements. Segmental rim volume measurements are very small in this group of patients, and so small standard deviations would be expected. This would explain why only change in volume reached statistical significance. However, the clinical significance of such small increases has yet to be determined.

Our study shows that in a large group of moderate to early glaucomatous patients, reduction of intraocular pressure by surgery results in an improvement of the appearance of the optic nerve head, and that this is more obvious in the long term. This may be related to the fact that in our subject group the mean intraocular pressure was at its lowest at the 2 year time point.

It has yet to be determined whether these changes in the appearance of the nerve have any clinical significance. The patients in this study are still being followed up, and investigations are currently under way into whether any true improvement of visual function is associated with these disc changes.

This study was supported by the Medical Research Council grant G9330070, and in part by the International Glaucoma Association.

This work was undertaken by the authors who received a proportion of funding from the NHS executive. The views expressed in this publication are those of the authors and not necessarily of the NHS executive.

- Pederson JE, Herschler J. Reversal of glaucomatous cupping in adults. *Arch Ophthalmol* 1982;100:426-31.
- Quigley HA. Childhood glaucoma: results with trabeculectomy and study of reversible cupping. *Ophthalmology* 1982;89:219-26.
- Greenidge KC, Spaeth GL, Traverso CE. Change in appearance of the optic disc associated with lowering of intraocular pressure. *Ophthalmology* 1985;92:897-903.
- Schwartz B, Takamoto T, Nagin P. Measurements of reversibility of optic disc cupping and pallor in ocular hypertension and glaucoma. *Ophthalmology* 1985;92:1396-407.
- Katz LJ, Spaeth GL, Cantor LB, et al. Reversible optic disc cupping and visual field improvement in adults with glaucoma. *Am J Ophthalmol* 1989;107:485-92.
- Shin DH, Bielik M, Hong YJ, et al. Reversal of glaucomatous optic disc cupping in adult patients. *Arch Ophthalmol* 1989;107:1599-603.
- Rath EZ, Shin DH, Kim C, et al. Relationship between optic disc cupping change and intraocular pressure control in adult glaucoma patients. *Graefes Arch Clin Exp Ophthalmol* 1996;234:434-9.
- Irak I, Zangwill L, Garden V, et al. Change in optic disc topography after trabeculectomy. *Am J Ophthalmol* 1996;122:690-5.
- Park KH, Kim DM, Youn DH. Short-term change of optic nerve head topography after trabeculectomy in adult glaucoma patients as measured by Heidelberg retina tomograph. *Korean J Ophthalmol* 1997;11:1-6.
- Lesk MR, Spaeth GL, Azuara-Blanco A, et al. Reversal of optic disc cupping after glaucoma surgery analyzed with a scanning laser tomograph. *Ophthalmology* 1999;106:1013-8.
- Shaffer RN, Hetherington J Jr. The glaucomatous disc in infants. A suggested hypothesis for disc cupping. *Trans Am Acad Ophthalmol Otolaryngol* 1969;73:923-35.
- Quigley HA. The pathogenesis of reversible cupping in congenital glaucoma. *Am J Ophthalmol* 1977;84:358-70.
- Robin AL, Quigley HA. Transient reversible cupping in juvenile-onset glaucoma. *Am J Ophthalmol* 1979;88(Pt 2):580-4.
- Spaeth GL, Fernandes E, Hitchings RA. The pathogenesis of transient or permanent improvement in the appearance of the optic disc following glaucoma surgery. In: Greve EL, ed. *Glaucoma symposium: diagnosis and therapy*. The Hague: Dr W Junk, *Doc Ophthalmol Proc Ser* 1980;22:111-26.
- Shirakashi M, Nanba K, Iwata K. Reversal of cupping in experimental glaucoma. *Ophthalmologica* 1991;202:194-201.
- Shirakashi M, Nanba K, Iwata K. Changes in reversal of cupping in experimental glaucoma. Longitudinal study. *Ophthalmology* 1992;99:1104-10.
- Coleman AL, Quigley HA, Vitale S, et al. Displacement of the optic nerve head by acute changes in intraocular pressure in monkey eyes. *Ophthalmology* 1991;98:35-40.
- Burgoyne CF, Quigley HA, Thompson HW, et al. Measurement of optic disc compliance by digitized image analysis in the normal monkey eye. *Ophthalmology* 1995;102:1790-9.
- Tsai CS, Shin DH, Wan JY, et al. Visual field global indices in patients with reversal of glaucomatous cupping after intraocular pressure reduction. *Ophthalmology* 1991;98:1412-9.
- Azuara-Blanco A, Spaeth GL. Methods to objectify reversibility of glaucomatous cupping. *Curr Opin Ophthalmol* 1997;8:50-4.
- Sogano S, Tomita G, Kitazawa Y. Changes in retinal nerve fiber layer thickness after reduction of intraocular pressure in chronic open-angle glaucoma. *Ophthalmology* 1993;100:1253-8.
- Raitta C, Tomita G, Vesti E, et al. Optic disc topography before and after trabeculectomy in advanced glaucoma. *Ophthalmic Surg Lasers* 1996;27:349-54.
- Topouzis F, Peng F, Kotas-Neumann R, et al. Longitudinal changes in optic disc topography of adult patients after trabeculectomy. *Ophthalmology* 1999;106:1147-51.
- Spaeth GL. The effect of change in intraocular pressure on the natural history of glaucoma: lowering intraocular pressure in glaucoma can result in improvement of visual fields. *Trans Ophthalmol Soc UK* 1985;104(Pt 3):256-64.
- Yildirim E, Bilge AH, Ilker S. Improvement of visual field following trabeculectomy for open angle glaucoma. *Eye* 1990;4(Pt 1):103-6.
- Zinser G, Harbarth U, Schroder H. Formation and analysis of three-dimensional data with the laser tomographic Scanner (LTS). In: Nasemann JE, Burk ROW, eds. *Scanning laser ophthalmoscopy and tomography*. Munich: Quintessenz, 1990.
- Cioffi GA, Robin AL, Eastman RD, et al. Confocal laser scanning ophthalmoscope. Reproducibility of optic nerve head topographic measurements with the confocal laser scanning ophthalmoscope. *Ophthalmology* 1993;100:57-62.
- Rohrschneider K, Burk RO, Kruse FE, et al. Reproducibility of the optic nerve head topography with a new laser tomographic scanning device. *Ophthalmology* 1994;101:1044-9.
- Rohrschneider K, Burk RO, Volcker HE. Reproducibility of topometric data acquisition in normal and glaucomatous optic nerve heads with the laser tomographic scanner. *Graefes Arch Clin Exp Ophthalmol* 1993;231:457-64.
- Dreher AW, Tso PC, Weinreb RN. Reproducibility of topographic measurements of the normal and glaucomatous optic nerve head with the laser tomographic scanner. *Am J Ophthalmol* 1991;111:221-9.
- Chauhan BC, LeBlanc RP, McCormick TA, et al. Test-retest variability of topographic measurements with confocal scanning laser tomography in patients with glaucoma and control subjects. *Am J Ophthalmol* 1994;118:9-15.
- Kamal DS, Viswanathan AC, Garway-Heath DF, et al. Detection of optic disc change with the Heidelberg retina tomograph before confirmed visual field change in ocular hypertensives converting to early glaucoma. *Br J Ophthalmol* 1999;83:290-4.
- Hosking SL, Flanagan JG. Prospective study design for the Heidelberg retina tomograph: the effect of change in focus setting. *Graefes Arch Clin Exp Ophthalmol* 1996;234:306-10.
- Wollstein G, Garway-Heath DF, Hitchings RA. Identification of early glaucoma cases with the scanning laser ophthalmoscope. *Ophthalmology* 1998;105:1557-63.
- Uchida H, Kitazawa Y, Tomita G, et al. Diagnostic ability of a new glaucoma classification program of Heidelberg Retina Tomograph II for early glaucoma. *IOVS: Suppl* 2000;41(4).
- Kotecha A, Khaw PT, Hitchings RA, et al. In vivo imaging of the lamina cribrosa and its relationship to optic nerve head topography. *IOVS: Suppl*, 2000;41(4).

- 37 Xu L, Liu L, Yang H, *et al.* Characteristics of reversal optic cupping in adults glaucoma after reduction of intraocular pressure. *Yen Ko Hsueh Pao* 1995;11:155-60.
- 38 Hernandez MR, Luo XX, Andrzejewska W, *et al.* Age-related changes in the extracellular matrix of the human optic nerve head. *Am J Ophthalmol* 1989;107:476-84.
- 39 Burgoyne CF, Quigley HA, Thompson HW, *et al.* Early changes in optic disc compliance and surface position in experimental glaucoma. *Ophthalmology* 1995;102:1800-9.
- 40 Burgoyne CF, Varma R, Quigley HA, *et al.* Global and regional detection of induced optic disc change by digitized image analysis. *Arch Ophthalmol* 1994;112:261-8.
- 41 Albon J, Purslow PP, Karwatowski WS, *et al.* Age related compliance of the lamina cribrosa in human eyes. *Br J Ophthalmol* 2000;84:318-23.
- 42 Emery JM, Landis D, Paton D, *et al.* The lamina cribrosa in normal and glaucomatous human eyes. *Trans Am Acad Ophthalmol Otolaryngol* 1974;78:290-7.
- 43 Quigley HA, Addicks EM, Green WR, *et al.* Optic nerve damage in human glaucoma. II. The site of injury and susceptibility to damage. *Arch Ophthalmol* 1981;99:635-49.
- 44 Jonas JB, Gusek GC, Naumann GO. Optic disc morphology in chronic primary open-angle glaucoma. I. Morphometric intrapapillary characteristics. *Graefes Arch Clin Exp Ophthalmol* 1988;226:522-30.
- 45 Airaksinen PJ, Tuulonen A, Alanko HI. Rate and pattern of neuroretinal rim area decrease in ocular hypertension and glaucoma. *Arch Ophthalmol* 1992;110:206-10.



Reference linking to full text
of more than 200 journals

Toll free links

You can access the FULL TEXT of articles cited in the *British Journal of Ophthalmology* online if the citation is to one of the more than 200 journals hosted by HighWire (<http://highwire.stanford.edu>) without a subscription to that journal. There are also direct links from references to the Medline abstract for other titles.

www.bjophthalmol.com



Optic disc changes following trabeculectomy: longitudinal and localisation of change

Aachal Kotecha, Dilani Siriwardena, Frederick W Fitzke, et al.

Br J Ophthalmol 2001 85: 956-961

doi: 10.1136/bjo.85.8.956

Updated information and services can be found at:

<http://bjo.bmj.com/content/85/8/956.full.html>

References

These include:

This article cites 38 articles, 7 of which can be accessed free at:

<http://bjo.bmj.com/content/85/8/956.full.html#ref-list-1>

Article cited in:

<http://bjo.bmj.com/content/85/8/956.full.html#related-urls>

Email alerting service

Receive free email alerts when new articles cite this article. Sign up in the box at the top right corner of the online article.

Topic Collections

Articles on similar topics can be found in the following collections

[Ophthalmologic surgical procedures](#) (971 articles)

Notes

To request permissions go to:

<http://group.bmj.com/group/rights-licensing/permissions>

To order reprints go to:

<http://journals.bmj.com/cgi/reprintform>

To subscribe to BMJ go to:

<http://group.bmj.com/subscribe/>