

## Should we aggressively treat unilateral congenital cataracts?

David Taylor, Kenneth W Wright, L Amaya, L Cassidy, K Nischal, Isabelle Russell-Eggitt

### View 1

Kenneth W Wright

I do believe that visually significant congenital cataracts should be treated aggressively with early surgery! However, I advocate surgery only if the cataract is truly visually significant. Small partial cataracts can often be treated with close observation or pupillary dilatation, possibly with part time occlusion therapy.

#### Early surgery for unilateral congenital cataracts—why?

Some might protest that visual results are notoriously poor after surgery for a unilateral congenital cataract. Why drag the family and child through all the turmoil required for the treatment of infantile cataracts for, at best, a “spare eye”? The answer is simple: two eyes are better than one. Two eyes give us a larger field of view, a reserve if one eye is lost, and that wonderful trait of binocular vision with stereopsis. Sure, you can get along with one eye but if there is any reasonable possibility for obtaining two functioning eyes, then we should go for it!

I have both a personal and a professional interest in unilateral cataract as my sister had technically successful unilateral congenital cataract surgery at 2½ years, followed by three strabismus surgeries. She had a childhood of being teased, an adult life of concern for her one good eye and corrected vision of counting fingers in the aphakic eye.

#### Can we realistically expect good visual outcomes in children who have unilateral congenital cataracts?

With aggressive treatment the visual prognosis is good, and there is even the possibility of obtaining binocular vision with stereoscopic acuity. Birch and Stager<sup>1</sup> reported that a mean visual acuity of 20/60 (range 20/800–20/30) was achieved if surgery was performed before 2 months of age, whereas surgery after 2 months of age resulted in poor visual acuity, ranging from hand movements to 20/160. Thus, the prognosis for obtaining good visual function is possible if surgery is performed early, but horrible if done late after irreversible amblyopia

occurs. Even so, one might argue that this is still only a “spare eye,” and that it is impossible to get the eyes to work together.

Historically, patients with unilateral congenital cataracts had a very poor prognosis for obtaining binocular fusion and many studies have reported that 100% of patients with unilateral congenital cataracts develop strabismus.<sup>2,3</sup> However, in separate papers published in 1992, Wright *et al*<sup>4</sup> and Gregg and Parks<sup>5</sup> reported that good visual acuity, straight eyes, and good binocularity with stereopsis is possible in patients with unilateral congenital cataracts. The key to the excellent outcomes was the way the patients were treated.

Firstly, the patients had very early surgery and immediate placement of an aphakic contact lens usually by 4 weeks of age. The case reported by Gregg and Parks<sup>5</sup> had cataract surgery with contact lens placement by the second day of life and ended up with 50 seconds of arc of stereoscopic acuity and visual acuity of 20/25 in the aphakic eye. In the paper of Wright *et al*,<sup>4</sup> five of 13 (38%) patients with unilateral congenital cataracts operated early developed both good visual acuity and binocular fusion. In both the Wright *et al*<sup>4</sup> and the Gregg and Parks<sup>5</sup> studies, extended wear contact lenses were used not aphakic spectacles. Unilateral aphakic spectacles just do not do the job, as infants will never wear them full time and the unilateral magnification causes aniseikonia that disrupts binocular fusion. Intraocular lenses have the theoretical advantage of providing a constant clear retinal image but early experience in newborns has been discouraging, and they are not the standard of care in infants. For me, optimal treatment is early surgery and the contact lens placement by 2 weeks of age.

Secondly, both studies used immediate full time binocular light occlusion when the cataract was first identified. Binocular occlusion was continued until a clear retinal image was restored (that is, cataract surgery performed and the contact lens placed—usually within 1 week). Binocular light occlusion or bilateral patching has been shown to preserve

Pediatric  
Ophthalmology  
Research and  
Education  
Cedars-Sinai Medical  
Center, Cedars-Sinai  
Medical Towers, 8631  
West Third Street,  
Suite 304 E, Los  
Angeles, CA 90048,  
USA  
K W Wright  
director

Table 1 Patching scheme for unilateral congenital cataracts after early surgery (surgery by 1 month of age)

Age (months)	Patching
0–1	No patching
1–2	1–2 hours/day
2–4	2–4 hours/day
4–6	50% awake hours
6–12	Up to 80% as indicated based on vision assessment

visual cortical plasticity in the animal model and to be safe in human infants.<sup>6–8</sup> Binocular occlusion is a way of postponing visual development until a clear retinal image can be established. I recommend binocular occlusion before surgery during the critical period of visual development (birth to 2 months of age) and for a duration of no longer than 2 weeks.

Thirdly, after surgery and contact lens fitting, Wright *et al*<sup>4</sup> and Gregg and Parks<sup>5</sup> used part time monocular occlusion of the good eye (less than 50%) to treat amblyopia rather than the standard treatment of full time occlusion. For the first month or two, virtually no patching was performed, allowing for the development of binocular fusion. Full time monocular occlusion during early infancy destroys binocular visual development and guarantees development of strabismus.<sup>3, 9, 10</sup> In addition, there is evidence that too much patching can actually reduce vision in the good eye (that is, the phakic eye).<sup>11</sup> Full time patching may be necessary in older children with a cataract and strabismus (>1 year of age), but part time patching is preferred in infants who have a clear retinal image established during the first few weeks of life (Table 1).

The papers by Wright *et al*<sup>4</sup> and Gregg and Parks<sup>5</sup> in 1992 and more recently by Brown *et al*<sup>12</sup> in 1999, clearly show that good vision and binocular fusion are not mutually exclusive, and that full time occlusion is not necessary if a clear retinal image is established in early infancy. These papers are important as they document that good visual acuity and binocular vision are obtainable through aggressive treatment (Fig 1).

#### What about older children with presumed unilateral congenital cataracts?

When an older child presents with a unilateral cataract it can be difficult to know whether the cataract was there during the critical period and, if so, to what extent the cataract interfered with visual development. Often, the clinician is unsure whether it is worthwhile removing the cataract in a child who presents late after the critical period of visual development. Should we be aggressive in treating these children who present late with presumed unilateral congenital cataracts? This time the answer is sometimes. Kushner<sup>13</sup> reported relatively good results after surgery for monocular juvenile cataracts of undetermined onset. In the study of Wright *et al*<sup>4</sup> all patients presented after 10 months of age and were treated with lensectomy and aphakic contact lenses. Eighteen patients underwent surgery for a unilateral cataract and, of these, approximately 40% obtained a visual acuity of 20/60 or better. Unilateral cataracts having an especially good



Figure 1 This is my patient who had a dense congenital cataract, left eye, identified at 1 day of age and had urgent surgery 48 hours after birth. The patient was treated aggressively with bilateral light occlusion from day 1 when the cataract was identified, until a contact lens was fitted at 1 week of age. The patient wears a contact lens full time, left eye, and the right eye is being patched 4 hours a day. As pictured above, the patient is now 1 year old, has excellent fixation in each eye, straight eyes, and the family is very happy that aggressive treatment was initiated.

prognosis include lamellar cataracts, posterior lenticonus, and persistent hyperplastic primary vitreous. These types of cataracts are often partial at birth and can progress over time, thus allowing for early visual development. Another indication for a good prognosis was the presence of straight eyes in these children. Approximately 50% of patients with a presumed unilateral congenital cataract who had straight eyes and no strabismus obtained final visual acuity of 20/40 or better. The presence of straight eyes indicates that the cataract was only partially obstructing the visual axis during the critical period of visual development indicating a relatively good visual prognosis.

#### Indications for surgery—is the cataract visually significant?

It is often difficult to determine whether a partial cataract is visually significant in preverbal children. Neonates less than 8 weeks of age normally have poor smooth pursuit eye movements and have not yet developed central fixation. Because of this, testing for fixation is not very useful. Infant vision tests such as preferential looking and pattern visual evoked potential are also unreliable and difficult to obtain during the neonatal period. Neonates do not fully accommodate and it is difficult to maintain their attention on the pattern stimulus. The most useful information comes from objective evaluation of the morphology of the

Table 2 Morphological signs indicating that the cataract might need surgery

Operate	Observe
> 4 mm	<3 mm
Central opacity	Peripheral
Posterior opacity	Anterior opacity
Confluent	Punctate with clear zones

cataract, the red reflex, and the retinal view by direct ophthalmoscopy. Morphological signs of a visually significant cataract include a cataract in the central visual axis larger than 3–4 mm, a posterior cataract, and a cataract which is confluent without clear zones between areas of opacity. Patients who have punctate opacities with intervening clear zones often develop good visual acuity without surgery (Table 2). If direct ophthalmoscopy shows that retinal details can be seen clearly, then it is often best to observe rather than operate.

### Conclusion

Today, with modern paediatric anaesthesia and microsurgical techniques, the risks of cataract surgery is low and there is much to gain with aggressive treatment. Not all children treated aggressively will obtain that lofty goal of good visual acuity and binocular vision, but it is guaranteed that without aggressive treatment virtually all children with a visually significant cataract at birth will end up with a blind eye and strabismus. Critical to success is early detection by the paediatrician using the red reflex test to screen babies in the newborn nursery, and a rapid response from the ophthalmologist. Only through an aggressive

treatment approach can we hope to improve our results, and help our children with congenital cataracts. Our decisions regarding the treatment of paediatric patient should not be taken lightly as they have powerful long term ramifications.

The author acknowledges the Discovery Fund for Eye Research and the Henry L. Guerther Foundation.

- Birch EE, Stager DR. Prevalence of good visual acuity following surgery for congenital unilateral cataract. *Arch Ophthalmol* 1988;106:40.
- Beller R, Hoyt CS, Marg E, et al. Good visual function after neonatal surgery for congenital monocular cataracts. *Am J Ophthalmol* 1981;91:559.
- Cheng KP, Hiles DA, Biglan AW, et al. Visual results after early surgical treatment of unilateral congenital cataract. *Ophthalmology* 1991;98:903–10.
- Wright KW, Matusmoto E, Edelman PM. Binocular fusion and stereopsis associated with early surgery for monocular congenital cataracts. *Arch Ophthalmol* 1992;110:1607.
- Gregg FM, Parks MM. Stereopsis after congenital monocular cataract extraction. *Am J Ophthalmol* 1992;114:314–17.
- Cynader M. Prolonged sensitivity to monocular deprivation in dark-reared cats: effects of age and visual exposure. *Dev Brain Res* 1983;8:155–64.
- Hoyt CS. The long-term visual effects of short-term binocular occlusion of at-risk neonates. *Arch Ophthalmol* 1980;98:1967–70.
- Wright KW, Wehrle MJ, Urrea PT. Bilateral total occlusion during the critical period of visual development. (Letter) *Arch Ophthalmol* 1987;105:321.
- Wiesel TN, Hubel DH. Ordered arrangement of orientation columns in monkeys lacking visual experience. *J Comp Neuro* 1974;158:307.
- Ikeda H, Tremain K. Amblyopia and cortical binocularity. *Trans Ophthalmol Soc UK* 1980;100:452.
- Thompson DA, Möller H, Russell-Eggitt I, et al. Visual acuity in unilateral cataract. *Br J Ophthalmol* 1996;80:794–8.
- Brown SM, Archer S, Del Monte M. Stereopsis and binocular vision after surgery for unilateral infantile cataract. *J AAPOS* 1999;3:109–13.
- Kushner BJ. Visual results after surgery for monocular juvenile cataracts of undetermined onset. *Am J Ophthalmol* 1986;102:468–72.
- Wright KW, Christensen LE, Noguchi BA. Results of late surgery for presumed congenital cataracts. *Am J Ophthalmol* 1992;114:409–15.

## View 2

L Amaya, L Cassidy, K Nischal, Isabelle Russell-Eggitt

Ophthalmologists agree that early, adequate, and aggressive treatment is the only way of getting good visual results in patients with unilateral congenital cataract. What is not agreed is which patients, if any, require treatment and what the surgical/optical correction methods should be.

Aggressive treatment includes early referral, preoperative investigation, surgical management, and multidisciplinary postoperative management of the optical correction and amblyopia treatment. Each of these stages requires highly trained personnel, significant cost, and teamwork. The core team members are not just the professionals but those they are working for—the patient and the family.

Many patients will benefit from aggressive treatment and in our unit the majority of parents opt for treatment, while for others aggressive intervention brings only frustration and failure.

### Consent

The decision whether or not to treat a monocular cataract is not the surgeon's, it belongs to the parents of the affected baby. The parents need to understand that the treatment is not just a surgical procedure, but that it involves patching, and use of some form of optical correction for many years. They must understand the meaning of amblyopia and the importance of achieving a regular, constant, and maintained regime for years together with the implications of the risk, cost, and inconvenience. All the facts must be clear to the parents and presented to them in a way that they can understand, acknowledging the impossibility of any professional giving a totally “spin free” opinion to the parents.

Any decision made by the parents should normally then be considered the correct one, and the ophthalmologist must reinforce the parents' final position; it may be the case that

Department of  
Ophthalmology, Great  
Ormond Street  
Hospital for Children,  
London, UK

L Amaya

senior clinical fellow

L Cassidy

consultant ophthalmologist

K Nischal

consultant ophthalmologist

I Russell-Eggitt

consultant ophthalmologist

many babies and their families are best left uncorrected, and parents must understand that treatment like many other clinical conditions, is not mandatory.

Surgery is, of course, indicated if parents wish, even if for cosmetic reasons only. In our experience, the majority of parents are keen to have the cataract treated, and are also willing to try the essential occlusion and optical correction. Even though good visual results can be achieved if treatment is started early, they are not invariable. The norm is probably that less than 50% of patients treated for unilateral congenital cataract achieve a good functional result.<sup>1 2</sup> Though there are many published series with a large proportion achieving good acuity results and even isolated cases that have achieved binocular vision,<sup>3-6</sup> these are the exception, and only come from the most expert centres. Parents must be aware of this before making any decision.

The fact that the vision of the phakic eye can be affected by amblyopia treatment<sup>7</sup> (with a reduction of visual acuity or contrast sensitivity, even if small) needs to be addressed as well. It should be clearly explained to the parents that the surgical procedure has risks: endophthalmitis, postoperative glaucoma, retinal detachment, or the need for further surgical procedures. Strabismus is an expected outcome in unilateral congenital cataract, even when the final visual acuity is good.

When a child has multiple handicaps in addition to a monocular cataract, life expectancy is limited, or the patient's general health is unsatisfactory, surgery may be unjustifiable in the parents' view. Not all patients with unilateral cataract have adequate access to specialised medical institutions with experienced professionals. Often, only those patients with ready access to major centres can afford the constant, regular, and prolonged treatment. A large proportion of babies in developing countries do not have access to these facilities and treatment is virtually impossible. Usually the social and economic conditions are such that treating a monocular cataract is not worthwhile; for many of these families just surviving is a struggle.

The parents should be made aware that if the visual prognosis is poor, surgery, optical correction, and occlusion will be unlikely to result in the goal of good acuity but the risks remain the same. Cataract surgery in a child with associated optic nerve or retinal disease and abnormal flash VEPs is not going to improve vision and is it fair to subject an extremely ill child who may not survive to surgery and occlusion? Severe mental retardation with behavioural problems where children will not easily comply with occlusion therapy and, most importantly, parent/carer motivation are also factors that the parent needs to consider when making the decision. If the parents do not fully understand and are not fully committed to persevering with postoperative treatment of amblyopia, then surgery for unilateral cataract is not worthwhile. For unilateral cases where other structures of the eye are damaged,

such those patients with monocular toxoplasmosis or cytomegalovirus that are very likely to have macular scarring or optic nerve atrophy, surgery would not be considered helpful by most parents unless for cosmetic reasons. Where profound amblyopia is certain, treatment is not indicated for visual gain but may still be done for other indications.

Sometimes—for instance, in posterior lenticonus which may have a late onset of cataract formation—although the cataract may be marked the eye may have a good potential for improvement of vision after surgery, optical correction, and occlusion. Occasionally, inspection of the red reflex in old photographs may give a clue to the possibility of an unexpectedly good prognosis.

Parents usually want to know what happens to the cataract if left untreated. Many cataracts are mild and don't change with time. A few, untreated, reabsorb spontaneously as in rubeella, persistent hyperplastic primary vitreous (PHPV) or certain syndromes.<sup>8</sup> Occasionally they may swell, inducing pupillary block and glaucoma. When associated with PHPV, traction of the ciliary processes may displace the lens and iris anteriorly, causing angle closure glaucoma.

Our main purpose as ophthalmologists is to act in the main interest of the child as an adviser to the parents, and a good level of vision in a monocularly affected eye may not necessarily represent a benefit for the child's life as a whole. So our answer to "should we aggressively treat unilateral congenital cataracts" in our opinion is: "Sometimes!"

### Preoperative evaluation

Ideally, the investigation of the child with unilateral congenital cataracts is undertaken by the ophthalmologist, a paediatrician, and sometimes a geneticist, a dysmorphologist, a counsellor or vision development team, and a developmental paediatrician. The first role of the ophthalmologist is to see if the problem is a purely ocular one not requiring the involvement of a paediatrician. The parents and any siblings should be examined, preferably dilated and with a slit lamp, even in the absence of a positive family history. The paediatrician may need to assess the overall development of the child, look for the presence of any dysmorphic signs, or signs of metabolic or other disease. There is no need to carry out a battery of biochemical or other tests in *every* case: the paediatrician should direct further investigations appropriately. Treatment of unilateral congenital cataract is indicated only if the visual function of that eye is affected enough to interfere with normal visual development. Careful and sometimes repeated visual assessment is essential; in partial cataracts the decision is more difficult than in total ones.

The qualitative assessment of fixation pattern of each eye is most commonly used as the basis for the decision whether or not to operate. Whether it is central, steady and maintained, whether there is nystagmus, and whether the child has fixation and re-fixation reflexes with the affected eye appropriate for

his age are essential observations. An infant, even with a total cataract, especially if it is acquired, may fix a light normally, despite being effectively blind to solid objects, so the choice of targets is critical. It is most important not to be influenced by the density or extent of the cataract on ophthalmoscopy: it is very misleading and can either underestimate or overestimate vision. Based on optical principles,<sup>9</sup> the ophthalmoscopic optical density or extent of the cataract is never a reliable method of judging whether surgery is indicated *in equivocal cases* and in more dense cataracts the answer is obvious.

There are two main ways of measuring acuity used in preoperative assessment. Visually evoked cortical potentials (VEPs) to transient patterned stimuli,<sup>10-13</sup> or "steady state" or "swept" VEPs.<sup>7, 13</sup> They have been successfully used to measure preoperative and postoperative acuities; although they suffer the disadvantages of cost and require very substantial expertise, they are the only way of measuring vision without the need to observe eye movements, and they may be more suitable for less cooperative and less attentive infants. Flash VEPs may be useful in complete cataract to establish the gross integrity of the neural visual pathways. Forced choice preferential looking (FPL) is now commonly used in clinics managing patients with congenital cataract.<sup>14-17</sup> The method requires meticulous technique if it is to be reliable, but with appropriate training, it can be performed by a wide variety of personnel and it is relatively inexpensive.

If the vision of the infant is good enough, active management is best postponed until the child is older, as it may be possible at the later age to carry out a more satisfactory optical correction, as the change in power of an eye becomes less. To be sure of the best course for each individual, careful, and sometimes repeated, visual assessment is mandatory. The presence of a partial unilateral cataract, whatever its effects on measured vision, should prompt the doctor to consider occlusion treatment even if surgery is not decided on at that stage for whatever reason.

The use of mydriatics is rarely helpful as in the long term the effects on accommodation and glare are significant limiting factors.<sup>18</sup> Optical iridectomy has few indications in the management of unilateral congenital cataract today.

### Surgery and optical correction

Cataract surgery is essentially a way of providing a clear visual axis for the optical correction that is essential for amblyopia treatment. Contact lenses are the standard optical correction in the majority of centres so surgery is directed to ensuring a clear visual axis. Lens aspiration is often performed, often with an intraoperative posterior capsulorhexis or capsulectomy, together with a vitrectomy as this procedure allows secondary intraocular lens implantation if a sufficient amount of posterior capsule has been left to support the lens. Lensectomy is performed frequently but since little posterior capsule is left there is little capsular support for

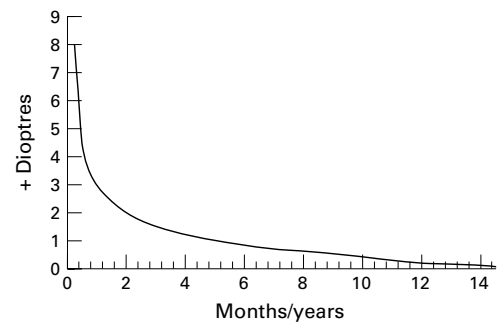


Figure 1 Hypothetical curve for IOL power calculation in infants and children drawn from several sources.<sup>26-31</sup> This represents the amount of hypermetropia that is targeted at different ages at surgery based on the biometry in order to achieve emmetropia in adult life.

the lens. This necessitates the use of a contact lens or a suture fixated intraocular lens; the latter has not stood the test of time in children.

The implantation of intraocular lenses in very young babies is becoming a more widespread practice<sup>2, 19</sup>; they are the treatment of choice in children over 2 years. The optical advantages of pseudophakia over aphakia are substantial and the risks when the operation is performed by a surgeon experienced in infant surgery and implantation are containable. Spectacles or contact lens overcorrection is usually indicated for the residual refractive error and the use of bifocals to allow a near/distance correction. Mostly, the power of the implanted lens is chosen to predict the loss of hypermetropia as the child grows (Fig 1).

### Amblyopia management

The major issue in the management of unioocular cataract is the amblyopia. There are still centres and countries where management of unioocular cataracts is as it was in the 1970s and earlier.<sup>20-22</sup> Later studies demonstrated that very early treatment could give better visual results,<sup>10</sup> and in the 1990s it was concluded that occlusion treatment of the amblyopia more than any other factor determined the visual outcome.<sup>23-25</sup> Before the critical period early deprivation does not affect vision.<sup>3</sup> Early and continued optical correction is mandatory if adequate visual results are to be accomplished. The clinician can discuss with the parents and ask if they are likely to be compliant with the optical and occlusion regime, and if the effort of going through the treatment will not affect the wellbeing of the family and the child. However, this cannot be predicted accurately and some families fail to comply. In most of these circumstances, parents at least have the satisfaction of having tried. Parents need to be aware in advance of this possible outcome, and must be prepared to know when to stop if their lives and the life of the child are profoundly affected. Situations where active management for unilateral cataracts is unlikely to benefit the child's life are given in Table 1.

At our hospital, an occlusion regime has been instituted (see Table 2). Since excessive early occlusion may be associated with an increase in nystagmus and effects on the phakic eye, the child starts with occlusion of the phakic eye of 1 hour per day for each month of age

Table 1 Situations where active management for unilateral cataracts is unlikely to benefit the child's life

Situations where active management is absolutely contraindicated	(1) Life limiting systemic disease (2) Severe other ocular diseases—ie, ROP, toxoplasmosis, absent, flash VEP (3) Parents refuse postop occlusion
Situations where active management is relatively contraindicated	(1) Substantial microphthalmos (2) Severe PHPV (3) Symptomatic systemic disease (4) Parents or child unlikely to manage postop occlusion

Table 2 Great Ormond Street hospital occlusion regime for unilateral congenital cataract

## Occlusion regime for unilateral cataract

- (1) The phakic eye is occluded 1 hour/day for each month of life\* until 6 months of age. After 6 months occlusion depends on interocular difference (see 2–4 below)
- (2) 0–1/2 octave interocular difference in visual acuity, 50% of waking hours occlusion of phakic eye
- (3) 1–2 octaves interocular difference in visual acuity, 75% of waking hours
- (4) More than 2 octaves interocular difference in visual acuity, 100% waking hours (NB: To be reviewed every 2 weeks)

\*A child aged 2 months is patched for 2 hours a day, a 3 month old child for 3 hours/day, etc.

until the baby is 6 months old; from 6 months, the vision is monitored by preferential looking, and the amount of occlusion of the phakic eye is modulated, depending on the interocular difference

- 1 D'Esposito M, Magli A, Daniele A. Functional recovery in congenital cataract. *Eur J Impl Ref Surg* 1990;2:261–4.
- 2 Cassidy L, Rahi J, Nischal K, et al. Outcome of lens aspiration and intraocular lens implantation in children aged 5 years and under. *Br J Ophthalmol* 2001;85:540–2.
- 3 Birch E, Stager DR, Wright W. Grating acuity development after early surgery for congenital unilateral cataract. *Arch Ophthalmol* 1986;104:1783–7.
- 4 Goldstein JH, Scheneckloth BB. Unilateral congenital cataract and binocular vision (letter). *Ophthalmic Surg* 1993;24:560–1.
- 5 Pratt-Johnson A, Tillson G. Unilateral congenital cataract: binocular status after treatment. *J Pediatr Ophthalmol Strabismus* 1989;26:72–5.
- 6 Gregg F, Parks M. Stereopsis after congenital monocular cataract extraction. *Am J Ophthalmol* 1992;114:314–17.
- 7 Thompson DA, Moller H, Russell-Eggitt I, et al. Visual acuity in unilateral cataract. *Br J Ophthalmol* 1996;80:794–8.
- 8 Rogers NK, Strachan IM. Pierre Robin anomalad, maculopathy and autolytic cataract. *J Pediatr Ophthalmol Strabismus* 1995;32:391–2.
- 9 Miller D, Benedek G. *Intraocular light scattering: theory and clinical application*. 1st ed. Springfield, IL: Thomas, 1973:68–72.
- 10 Beller RB, Hoyt CS, Marg E, et al. Good visual function after neonatal surgery for congenital monocular cataract. *Am J Ophthalmol* 1981;91:559–65.

- 11 McCulloch DL, Skarf B. Pattern reversal visual evoked potentials following early treatment of unilateral, congenital cataracts. *Arch Ophthalmol* 1994;112:510–18.
- 12 Nucci P, Brancato P. Pattern reversal visual evoked potentials following early treatment of unilateral congenital cataract (letter). *Arch Ophthalmol* 1995;113:404–5.
- 13 Kriss A, Thompson D, Lloyd C, et al. Pattern VEP findings in young children treated for unilateral congenital cataract. In: Cotlier E, Lambert S, Taylor D, eds. *Congenital cataracts*. Austin, Texas: RG Landes, 1994:79–88.
- 14 Lloyd C, Dowler J, Kriss A, et al. Preferential looking and the management of congenital cataract: new occlusion protocols. In: Cotlier E, Lambert S, Taylor D, eds. *Congenital cataracts*. Austin, Texas: RG Landes, 1994:93–101.
- 15 Lloyd C, Dowler JGF, Kriss A, et al. Modulation of amblyopia therapy following early surgery for unilateral congenital cataracts. *Br J Ophthalmol* 1995;79:802–6.
- 16 Lewis TL, Maurer D, Brent HP. Development of grating acuity in children treated for unilateral or bilateral congenital cataracts. *Invest Ophthalmol Vis Sci* 1995;36:2080–95.
- 17 Mayer DL, Moore B, Robb RM. Assessment of vision and amblyopia by preferential looking tests after early surgery for unilateral congenital cataracts. *J Pediatr Ophthalmol Strabismus* 1989;26:61–8.
- 18 Crawford JS. Conservative management of cataracts. In: Hiles DA, ed. *Infantile cataract surgery*. Boston: Little, Brown, International Ophthalmology Clinics, 1977:31–5.
- 19 O'Keefe M, Mulvill A, Yeoh PL. Visual outcome and complications of bilateral intraocular lens implantation in children. *J Cataract Refract Surg* 2000;26:1758–64.
- 20 Costenbader FD, Albert DG. Conservatism in the management of congenital cataracts. *Arch Ophthalmol* 1957;58:426–30.
- 21 Deweese MW. A survey of the surgical treatment of congenital cataracts. *Am J Ophthalmol* 1962;53:853–7.
- 22 Francois J. Late results of congenital cataract surgery. *J Pediatr Ophthalmol Strabismus* 1970;7:139–45.
- 23 Elsas FJ. Visual acuity in monocular paediatric aphakia; does epikeratophakia facilitate occlusion therapy in children tolerant of contact lens or spectacle wear? *J Pediatr Ophthalmol Strabismus* 1990;27:304–9.
- 24 Lewis T, Maurer D, Brent H. Effects of perceptual development of visual deprivation during infancy. *Br J Ophthalmol* 1986;70:214–20.
- 25 Moore B. The cause of treatment failure in patients with unilateral congenital cataracts. In: Cotlier E, Lambert S, Taylor D, eds. *Congenital cataracts*. Austin, Texas: RG Landes, 1994:143–8.
- 26 Fledelius HC, Christensen AC. Reappraisal of the human ocular growth curve in fetal life, infancy, and early childhood. *Br J Ophthalmol* 1996;80:918–21.
- 27 Enyedi LB, Peterseim MW, Freedman SF, et al. Refractive changes after pediatric intraocular lens implantation. *Am J Ophthalmol* 1998;126:772–81.
- 28 Flitcroft DI, Knight-Nanand D, Bowell R, et al. Intraocular lenses in children: changes in axial length, corneal curvature, and refraction. *Br J Ophthalmol* 1999;83:265–9.
- 29 McClatchey SK. Intraocular lens calculator for childhood cataract. *J Cataract Refract Surg* 1998;24:1125–9.
- 30 Young JDH. Paediatric pseudophakia—choosing the implant power. *Br J Ophthalmol* 1999;83:258–9.
- 31 Ruben JB. Refractive changes after pediatric intraocular lens implantation. *Am J Ophthalmol* 1999;128:260–1.

## Comment

David Taylor

While there are obvious differences in style between the two views expressed here on the management of unilateral congenital cataract, there are a large number of areas where there is agreement.

It is agreed that good acuity results are possible if the treatment is started early and is continued through to the end. A graded occlusion regime is important. There are some children who present later who may have an acquired visual deficit and who may benefit from active treatment. Not all unilateral cataracts are sufficiently visually significant to need treatment.

There is not agreement about how vision should be monitored, with the Californians relying on astute clinical observation of fixation patterns and the red reflex and the Brits eschewing the red reflex as a guide and relying on forced choice preferential looking. The use of preoperative bilateral occlusion is done in California but is not mentioned by those across the Atlantic.

One side uses contact lenses to correct aphakia as their preferred method while implantation of an IOL is the treatment of choice for the other: it is not possible to have a consensus on this point and until there is a study carried out

**Great Ormond Street  
Hospital, London  
WC1N 3JH, UK**  
D Taylor  
lead ophthalmologist

that can clearly show the way forward, we shall have to rely on that old fallback of doctors—clinical judgment.

Writing a comment on two such views puts the author in the invidious and dangerously exposed position of being likely to sound as though he thinks he is Solomon, but it does offer the rare privilege of giving one's own unfettered opinion!

I think that once the difficult discussions have been completed with the parents about whether or not treatment is in the best interests of the baby, and provided that they fully understand the risks and benefits, active management should be pursued vigorously if that is the parents' wish. If the pretreatment discussions have been adequate, there will be a substantial number of parents who do not opt for treatment.

The vast majority of unilateral congenital cataracts have no systemic associations and collaboration with paediatricians is not usually necessary, although one needs to keep the possibility of systemic problems in mind. I do not use preoperative occlusion as the time before surgery is usually minimal. Surgery should be performed as soon as practicable but it is not now thought to be necessary to operate as an emergency. I use an IOL in all eyes that are normal, apart from the cataract, providing that the operation proceeds without complications and that the IOL can be placed in the bag with a good anterior and posterior capsulorhexis. If this "perfection" can't be achieved the infant is better off with aphakia and a contact lens: the parents need to know the possibility of this before the operation.

The surgery is best performed by a surgeon who does a substantial number of infant cataract operations, not by one who just does a large number of cataract operations, and the

surgeon or a member of the same team should also be the person who is responsible for the postoperative optical correction and amblyopia treatment. The lens power can be chosen to try to give approximate emmetropia in late childhood, with overcorrection by spectacles or occasionally by contact lenses. The use of piggyback IOLs, removing one later in life is likely to give an inadequate optical correction unless combined with spectacles or contact lenses and is yet another example of putting technique before safety. The IOL, at least for the time being, should be a one piece PMMA lens because the material has stood the test of time, and despite some disadvantages, is still the safest choice. Publications that extol the virtues of many more modern materials have usually missed the point: it is not a short term technical feat that should be being achieved but a lifelong way of improving the child's life with minimal risk and maximal benefit.

If aphakia is chosen then daily wear contact lens treatment is the best way of achieving good vision, with the lens power chosen for near fixation. The parent training and contact lens management is ideally carried out by a paediatric optometrist or ophthalmologist member of the team.

I think that the most difficult part of the whole treatment is the occlusion and the parents need help and support from the beginning, when it is easy, to the end, often when the child is 10 or more years old, when it can be very difficult. The commonest cause of failure is failure of compliance with occlusion.

There is no "best" way, just as there is no best chef or best novelist—each ophthalmologist develops individual management methods; the only goal is the improvement of the child's life by compassionate understanding and teamwork.



## Should we aggressively treat unilateral congenital cataracts?

David Taylor, Kenneth W Wright, L Amaya, et al.

*Br J Ophthalmol* 2001 85: 1120-1126

doi: 10.1136/bjo.85.9.1120

---

Updated information and services can be found at:

<http://bjo.bmj.com/content/85/9/1120>

---

### References

*These include:*

This article cites 32 articles, 14 of which can be accessed free at:

Article cited in:

<http://bjo.bmj.com/content/85/9/1120#related-urls>

### Email alerting service

Receive free email alerts when new articles cite this article. Sign up in the box at the top right corner of the online article.

---

### Topic Collections

Articles on similar topics can be found in the following collections

- [Lens and zonules](#) (642 articles)
- [Paediatrics](#) (278 articles)
- [Muscles](#) (184 articles)
- [Neurology](#) (1042 articles)
- [Optic nerve](#) (558 articles)
- [Optics and refraction](#) (385 articles)
- [Vision](#) (499 articles)

---

### Notes

---

To request permissions go to:

<http://group.bmj.com/group/rights-licensing/permissions>

To order reprints go to:

<http://journals.bmj.com/cgi/reprintform>

To subscribe to BMJ go to:

<http://group.bmj.com/subscribe/>