

SCIENTIFIC CORRESPONDENCE

Autofluorescence imaging after selective RPE laser treatment in macular diseases and clinical outcome: a pilot study

C Framme, R Brinkmann, R Birngruber, J Roeder

Br J Ophthalmol 2002;**86**:1099–1106

Aim: Selective retinal pigment epithelium (RPE) laser treatment is a new technique which selectively damages the RPE while sparing the neural retina. One difficulty is the inability to visualise the laser lesions. The aim of the study was to investigate whether fundus autofluorescence (AF) is changed because of the RPE damage, and thus might be used for treatment control. Additionally, the clinical course of patients with various macular diseases was evaluated.

Methods: 26 patients with macular diseases (diabetic maculopathy (DMP), soft drusen maculopathy (AMD), and central serous retinopathy (CSR)) were treated and followed up for at least 6 months. Treatment was performed with a train of repetitive short laser pulses (800 ns) of a frequency doubled Nd:YAG laser (parameters: 532 nm, 50 and 500 pulses at 100 and 500 Hz, retinal spot diameter 200 μ m, pulse energies 75–175 μ J). AF was excited by 488 nm and detected by a barrier filter at 500 nm (HRA, Heidelberg Engineering, Germany). Patients were examined by ophthalmoscopy, fluorescein angiography, and autofluorescence measurements at various times after treatment (10 minutes, 1 hour, 1 and 6 weeks, 3, 6, and 12 months).

Results: Fluorescein angiography showed leakage from the irradiated areas for about 1 week after treatment. None of the laser lesions was ophthalmoscopically visible during treatment. Identification of the lesions was possible by AF imaging showing an intensity decay in the irradiated area in 22 out of 26 patients, predominantly in patients with CSR and AMD. Lesions could be identified 10 minutes after treatment as hypoautofluorescent spots, which were more pronounced 1 hour later. During follow up the laser spots became hyperautofluorescent. In patients with DMP some AF images were less helpful because of diffuse oedema and larger retinal thickness. In these cases ICG angiography was able to confirm therapeutic success very well. Most of the patients have had benefit from the treatment, with best results obtained for CSR patients.

Conclusion: Imaging of non-visible selective RPE laser effects can be achieved by AF measurements predominantly in patients without retinal oedema. Therefore, AF may replace invasive fluorescein angiography in many cases to verify therapeutic laser success. Selective laser treatment has the potential to improve the prognosis of macular diseases without the risk of laser scotomas.

argon laser (514 nm). Generally the exposure times are longer than 50 ms, typically 100–200 ms. After application of the laser energy to the retina, an ophthalmoscopically visible greyish-white lesion normally develops, as a result of the thermal heat conduction from the centre of the laser burn towards the periphery. Histologically, a destruction of the retinal pigment epithelium (RPE), which is the primary absorption site, occurs, leading to an irreversible destruction of the outer and inner segments of the neuroretina as a result of thermal denaturation.^{3–6}

It has been shown that a variety of macular diseases such as diabetic macular oedema, diabetic retinopathy, age related macular degeneration, and central serous retinopathy can be treated successfully by conventional laser irradiation. However, the benefit for the patient has to be considered carefully when performing macular irradiation because of resulting laser scotomas, which can lead to a severe loss of visual acuity.

Several macular diseases are thought to be caused only by a reduced function of the RPE cells. Therefore, a method for the selective destruction of the RPE cells without causing adverse effects to choroid and neuroretina, especially to the photoreceptors, seems to be an appropriate treatment.⁷ The selective effect on RPE cells, which absorb about 50% of the incident light because of their high melanosome content⁸ has been demonstrated using 5 μ s argon laser pulses at 514 nm with a repetition rate of 500 Hz.⁷ By irradiating the fundus with a train of μ s laser pulses it was possible to achieve high peak temperatures around the melanosomes. This led to a destruction of the RPE, but only a low sublethal temperature increase in adjacent tissue structures.⁹ This selective destruction of the RPE cells sparing the photoreceptors has been proved by histological examinations at different times after treatment.^{9, 10} The first clinical trial using a Nd:YLF laser system with a pulse duration of 1.7 μ s (100 pulses, 100 and 500 Hz) also proved the concept of selective RPE destruction and demonstrated the clinical potential of this technique.^{11, 12}

One of the problems concerning selective RPE laser destruction is the inability to visualise the laser lesions. Therefore, it is necessary to perform fluorescein angiography after treatment to confirm the laser success and to make sure that sufficient energy was used. Since dosimetry of such laser lesions is not known, test lesions with various energy and numbers of pulses in non-significant areas of the macula—usually at the lower vessel arcade—have to be applied to elucidate the energy levels required for treatment. If the RPE is damaged, or the tight junctions of the RPE barrier are broken, fluorescein from angiography can pool from the choriocapillaris into the subretinal space. Thus fluorescein angiography has been used to detect a break of the RPE barrier. However, fluorescein angiography is an invasive method and has a potential risk for allergic reactions because of the intravenous injection of the fluorescein dye.

Fundus autofluorescence imaging is a recently developed non-invasive diagnostic tool which might be helpful for imaging the laser lesions. Autofluorescence has been shown to be

The method of retinal photocoagulation is one of the most important treatments in ophthalmology. It was first investigated by Meyer-Schwickerath in 1949 using sunlight for irradiation of the retina¹ and further developed by Maiman in 1960, who presented the first ruby laser.² Today conventional retinal laser treatment is performed using the cw

Table 1 Number of patients given treatment of the macular pathology with various laser settings of a Nd:YLF laser (532 nm, 200 µm, 125 and 500 Hz)

Number of pulses applied in a train	Energy per single pulse				
	75 µJ	100 µJ	125 µJ	150 µJ	175 µJ
50 pulses	0	0	0	0	2
100 pulses	3	7	1	12	1

derived from the lipofuscin within the retinal pigment epithelium.^{13,14} Lipofuscin accumulates in RPE cells as a byproduct of phagocytosis of the photoreceptors.¹⁴ With a confocal laser scanning ophthalmoscope it is possible to illuminate the fundus and to record the autofluorescence from the lipofuscin.¹⁵ Imaging of normal fundus revealed a decreased autofluorescence at the perifoveal area. The optic nerve head and the vessels appear dark.^{13,14} The decreased autofluorescence towards the fovea is explained by an absorption of short wavelength light by the macular pigments.¹⁵ The area around the vessel arcades reveals the highest intensity of autofluorescence and decreases towards the periphery.^{16–18} Since the autofluorescence is confined to the RPE it might be supposed that alterations in the RPE due to laser destruction lead to a change in the autofluorescence behaviour.¹⁹

The aim of this pilot study was to evaluate the importance of fundus autofluorescence to detect ophthalmoscopically invisible laser lesions from the selective laser treatment. A clinical prototype Nd:YAG laser (532 nm) (Zeiss, Jena, Germany) was used with pulse durations of 800 ns. Additionally the course of the different macular diseases was studied after selective treatment.

MATERIAL AND METHODS

Patients

All patients gave written informed consent to the selective laser treatment and to the prospective nature of this study. The protocol was approved by the institutional ethics committee. In 26 eyes of 25 patients (14 female, 11 male) laser lesions were applied to the macula. There were 14 patients who were treated for diabetic macular oedema (DMP, group I). The mean age of this group was 60.2 (range 39–78) years. In eight patients a prophylactic treatment was planned for soft drusen in eyes with a high risk of developing choroidal neovascularisation²⁰ (AMD, group II, mean age 71.8, range 61–84 years). Four patients were treated for long standing central serous retinopathy (CSR, group III); their mean age

was 45.6 (range 37–53) years. Fifty four per cent of the patients had visual acuity better than 20/25, 42% had visual acuity better than 20/63, and 4% had less than 20/63. All patients had clear media or minimal cataract as assessed by slit lamp examination. Pigmentation of the irises appeared uniform. After treatment the patients were evaluated at 10 minutes, 1 hour, 1 and 6 weeks, 3, 6, 12 months and longer after laser treatment. Mean follow up was 8.9 months ranging from 6 to 18 months.

Before treatment and during follow up the following tests were performed on all patients—visual acuity measurements, fundus examination, colour photography, fluorescein angiography and autofluorescence measurements (see below). In selected cases additionally ICG angiography was performed.

Autofluorescence measurements

Autofluorescence and angiography images were obtained using the Heidelberg retina angiograph (HRA; Heidelberg Engineering, Heidelberg, Germany). Before imaging, the pupil was dilated to more than 6 mm using phenylephrine 2.5% and tropicamide 1% eye drops. The HRA is a confocal scanning laser ophthalmoscope equipped with a laser source able to emit laser light with four different wavelengths for different acquisition modes. Autofluorescence was excited by the argon blue wavelength (488 nm) used originally for fluorescein angiography. A barrier filter at 500 nm separates the excitation and fluorescent light. The illumination beam is 3 mm in diameter and the aperture of the dilated eye was used to collect light from the posterior pole. Maximal retinal irradiation at 30° was 0.2 mW/cm², well below the limits established by the American National Standards Institute.²¹ The confocal detection unit employs a 400 µm pinhole aperture to suppress light from below or above the confocal plane. The digital images were saved for processing where an average image from the original image series was created to reduce noise and to produce more detailed images for the spatial distribution of the fundus autofluorescence.¹⁵

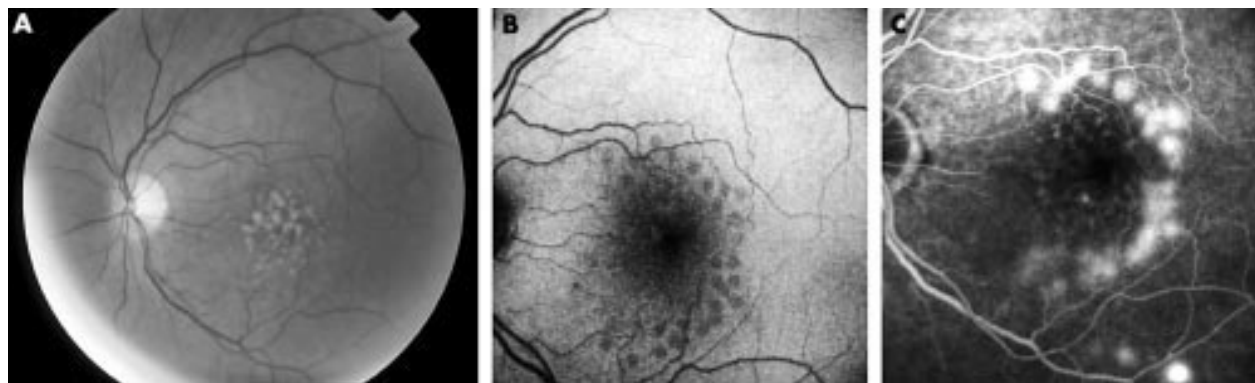


Figure 1 (A) Patient's left eye showing multiple soft confluent drusen. Visual acuity was 20/20. Prophylactic selective RPE laser treatment was recommended to prevent choroidal neovascularisation. (B) Autofluorescence image 1 hour after selective RPE laser treatment. About 30 grid pattern laser lesions could be identified as hypoautofluorescent spots. Very central spots disappeared "under" the blockage of the autofluorescence signal due to the perifoveolar pigments. (C) Corresponding fluorescein angiography showed leakage in the irradiated areas suggesting successful RPE damage. Note also the different amount of leakage of the dosimetry laser lesions at the lower vessel arcade.

Table 2 Autofluorescence (AF) measurements 1 hour after RPE laser treatment

AF	Hypofluorescent*	No reaction†
DMP (n=14)	N=11 (79%)	N=3
AMD (n=8)	N=7 (86%)	N=1
CSR (n=4)	N=4 (100%)	N=0

*Hypofluorescence of laser lesions immediately after treatment.

†No immediate hypofluorescence notable.

Treatment laser

A clinical prototype of a Nd:YAG laser built by Zeiss (Zeiss, Jena, Germany) was used and coupled to a slit lamp (Zeiss Instruments, Jena, Germany). The wavelength was 532 nm and the pulse duration of a single pulse was about 800 ns (full width half maximum). The spot size of the laser beam, as analysed by a beam analyser (Spiricon LBA-100A; Polytech, Waldbronn, Germany), was about 200 μm in air. Each test lesion was created by a train of a different number of repetitive laser pulses and different energies. The number of laser pulses applied were 100 and 50. The repetition rate was 125 Hz and 500 Hz. Single pulse energy varied between 75 and 175 μJ . Laser spots were applied by means of an OGFA fundus laser lens (Ocular Instruments).

Treatment protocol

Since the energy necessary for selective laser RPE destruction with this laser technique was unknown, each patient received

test exposures to the lower temporal arcades. Four to eight test lesions with various energy levels (75, 100, 125, 150, and 175 μJ) were applied. Initially patients were treated with 100 pulses at 500 Hz. It subsequently became apparent that selectivity could be achieved by a smaller repetition rate, and so a lower rate of 125 Hz was used towards the end of the study to avoid unnecessary temperature increase in the tissue. However, the total exposure time then extended from previously 200 ms to nearly 1 second, which was found to interfere with occasional eye movements in some patients. Thus, the total number of pulses was later reduced to 50 (table 1).

Energy was adjusted up to the level where test exposures became visible. Based on the evaluation of these test lesions the energy necessary for treating the macular pathology was chosen, reducing it to subthreshold values. Autofluorescence measurements were performed 10 minutes and 1 hour after treatment followed by fluorescein angiography after 1 hour to confirm the laser success and for comparison with the autofluorescence image. Autofluorescence imaging was always performed before angiography.

If angiography revealed no leakage after laser treatment the chosen energy was judged to be insufficient for RPE damage. In this case treatment was repeated using higher power levels. Table 1 shows the laser settings for laser energy and number of pulses for treating the macular pathology.

For diabetic macular oedema treatment was performed to the area of exudation as evaluated by fluorescein angiography. A total of 20–100 exposures were applied, depending on the area (group I). In group II soft drusen were treated indirectly

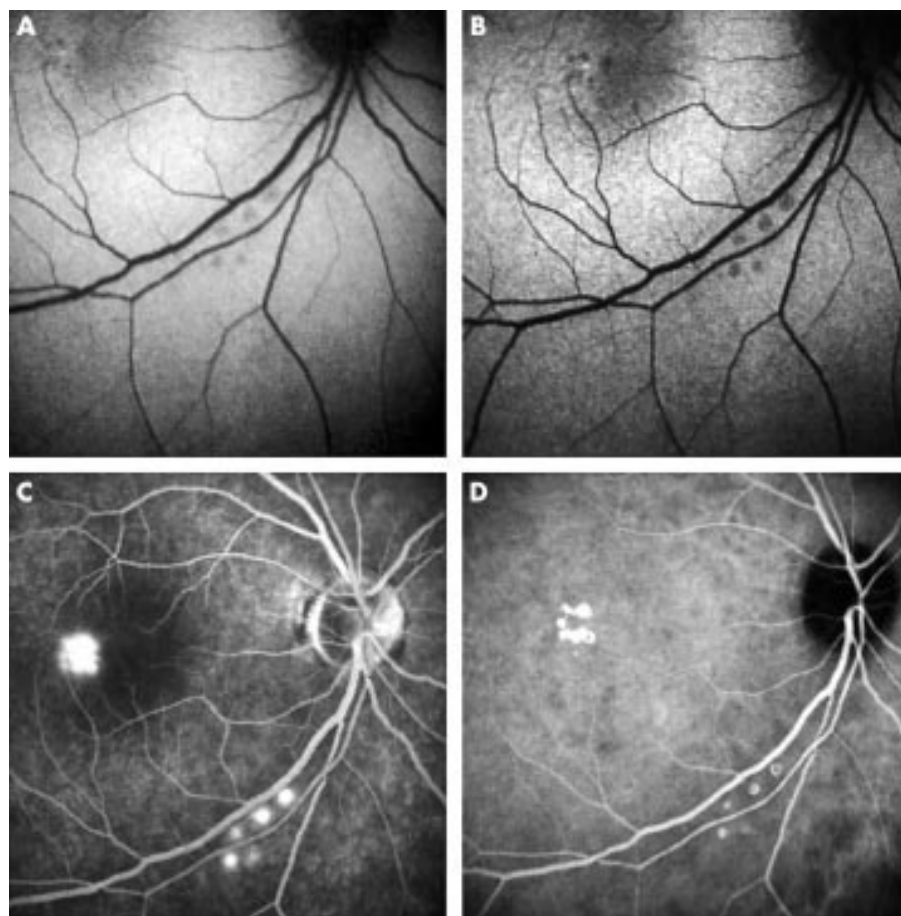


Figure 2 (A) Autofluorescence image 10 minutes after treatment for CSR. The five test lesions at the lower vessel arcade were hypofluorescent. (B) Autofluorescence image 1 hour after treatment revealed a more pronounced hypofluorescence of the lesions. Also the treatment lesions temporal the foveal spot could be noticed as hypofluorescent spots. (C) Fluorescein angiography demonstrated the laser success showing leakage in the parafoveal area and at the lower vessel arcade (doismetry spots). (D) ICG angiography shows sharp demarcation of the single laser lesions and therefore it seems to be superior to fluorescein angiography.

Table 3 Follow up and change of autofluorescence (AF) behaviour longer than 1 week after RPE laser treatment

AF	*Hyperfluorescent	†No reaction
DMP (n=14)	N=10 (71%)	N=4
AMD (n=8)	N=7 (86%)	N=1
CSR (n=4)	N=4 (100%)	N=0

*Hyperautofluorescence of laser lesions longer than 1 week after treatment.

†No hyperautofluorescence notable.

by a 270 degree horseshoe-shaped pattern temporal to the fovea with 30–50 exposures. In group III the CSR was treated with about 5–12 exposures around the focal point of leakage as determined by angiography.

Outcome assessment

Autofluorescence images were compared to preoperative ones and to the angiograms. If autofluorescence showed intensity changes in the area of irradiation this case was evaluated as positive. If no changes were observed the case was evaluated as negative. No fraction of “positive” and “negative” lesions in

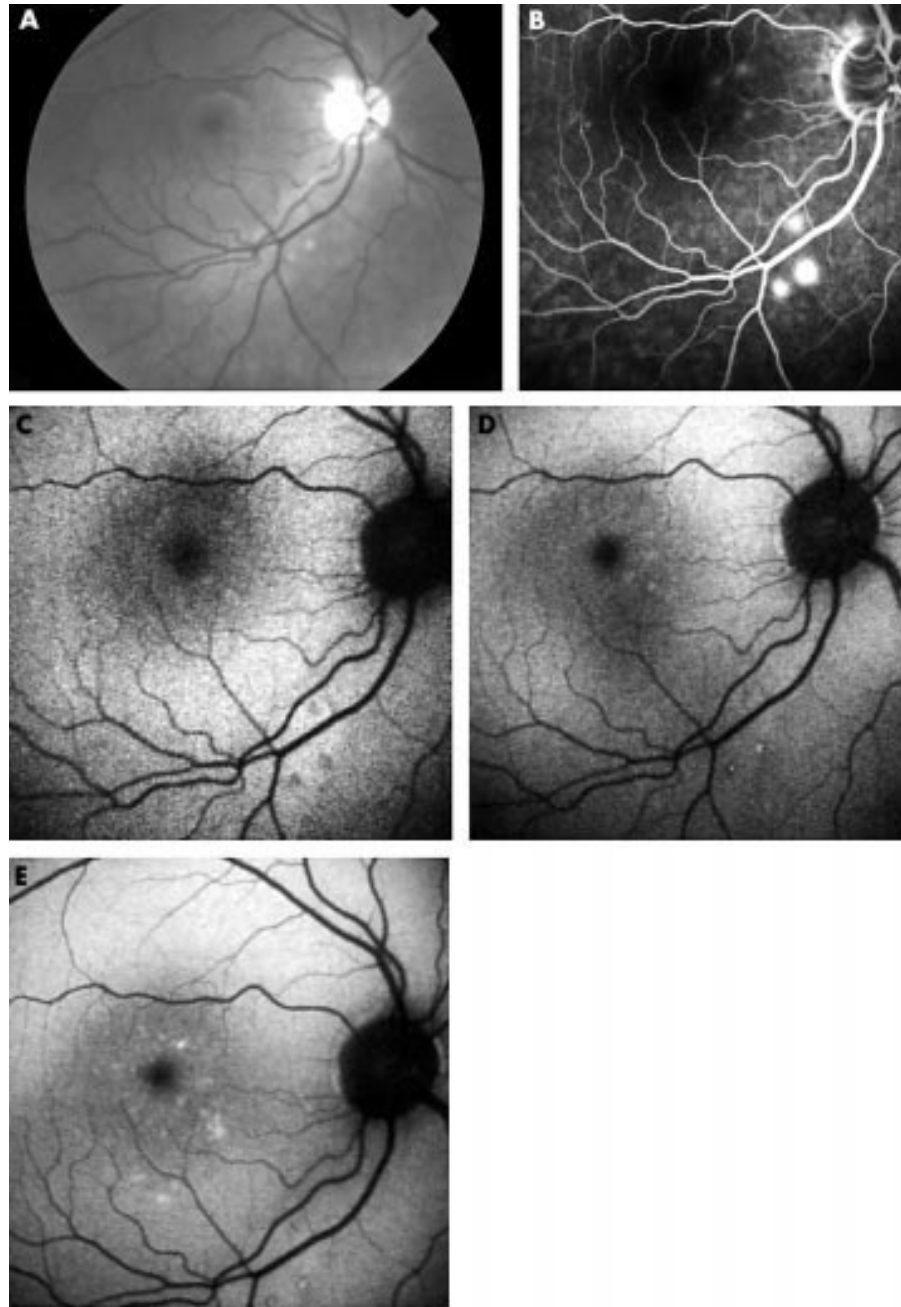


Figure 3 (A) Right eye of a 35 year old patient 1 hour after treatment for CSR. Visual acuity was 20/30. Two of the suprathereshold test lesions at the lower arcade were visible. None of the treatment lesions is ophthalmoscopically detectable. (B) Fluorescein angiography performed 1 hour after treatment confirmed therapeutical success by showing leakage of the test and treatment lesions. Treatment was performed nasally from the foveal area. (C) Autofluorescence obtained 1 hour after treatment revealed hypofluorescent test lesions at the lower arcade. Detection of the treatment lesions in the macular area are difficult presumably due to the lutein pigment and the leakage. (D) Autofluorescence 3 months after treatment showed the test laser spots at the arcade as hyperautofluorescent lesions. Also some parafoveal spots could be noticed. Visual acuity at this point was 20/20. (E) Autofluorescence 15 months after treatment showed the test lesions to be constantly hyperautofluorescent. However, the parafoveal treatment lesions were insufficiently detectable.

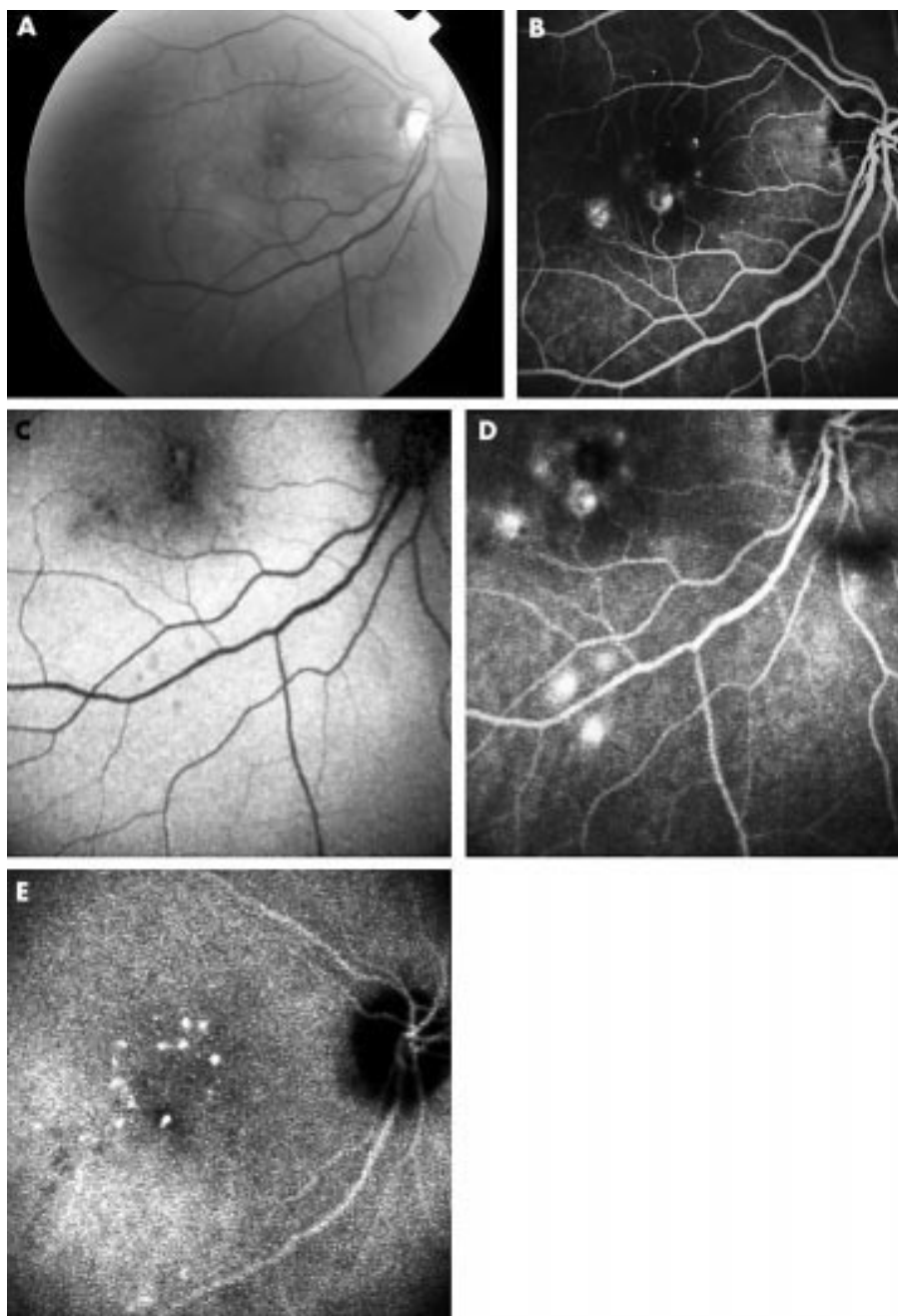


Figure 4 (A) Right eye of a 65 year old patient with diabetic maculopathy. A clinically significant oedema was present. Visual acuity was 20/50. (B) Fluorescein angiography revealed perifoveolar leakage. (C) Autofluorescence 1 hour after treatment. Test lesions were very visible but central oedema disturbed sufficient localisation of the treatment lesions. (D) Fluorescein angiography 1 hour after treatment in the same patient. Leakage of the test lesions at the lower arcade could be noticed but central treatment lesions were not distinguishable from the macular oedema. (E) Simultaneously, ICG angiography in the same patient showed better resolution of the laser spots than fluorescein angiography and therefore it has a better potential to visualise selective laser spots in thicker and oedematous diabetic retina.

each patient could be determined because exact localisation of single treatment laser spots were not documented throughout the study. Additionally, the behaviour of the autofluorescence pattern was observed and described during follow up.

In order to evaluate the subsequent disease course, preoperative and postoperative fundus photographs and angiograms were compared. In group I (DMP) the number of hard exudates and the extent of leakage was judged to be less, more, or equal and also visual acuity was determined. In group II (AMD) the change in number of drusen was determined to be less or equal, and finally in group III (CSR) the disappearance of leakage by angiography was evaluated as well as the improvement in visual acuity.

RESULTS

Postoperative measurements

None of the laser lesions was ophthalmoscopically visible during or 1 hour after treatment. In 20 patients first treatment was successful as determined by fluorescein leakage in the irradiated areas. Leakage could generally be observed for about 1 week after laser exposure. In six patients treatment had to be repeated because angiography revealed no leakage from the irradiated areas suggesting that the energy chosen during the first treatment was too low to damage the RPE. In those cases autofluorescence did not show any intensity alterations in treated areas. Second treatment was performed using higher energy levels which then led to angiographic leakage.

Table 4 Course of the disease after RPE laser treatment

Course	Better	Same	Worse
DMP (n=14)	N=8	N=5	N=1
AMD (n=8)	N=3	N=5	
CSR (n=4)	N=4		

MP better = VA increase, reduction of oedema and/or hard exudates; AMD better = reduction of drusen and/or oedema; CSR better = VA increase, disappearance of oedema.

Autofluorescence measurements revealed an intensity decay in the irradiated area in 22 of 26 patients (84.6% positive). This means that in the image (10 minutes and 1 hour after treatment) laser spots could be evaluated as hypoautofluorescent lesions as demonstrated in a 60 year old patient 1 hour after treatment for drusen maculopathy (Fig 1). This hypoautofluorescent appearance of the laser lesions was apparent in 79% (11/14) of the patients in group I (DMP), 86% (7/8) of the patients in group II (AMD), and in 100% (4/4) of the patients in group III (CSR) (Table 2).

Test lesions at the lower arcade could be detected more easily throughout the study than central treatment lesions, since autofluorescence in the perifoveolar area is blocked by macular pigments. Hence, in four cases with hypofluorescent test lesions at the lower vessel arcade no hypoautofluorescence could be observed in the treatment area.

The hypoautofluorescent appearance of the lesions were found to be more pronounced 1 hour after irradiation than just 10 minutes after irradiation (Fig 2A, B). Additionally performed ICG angiography revealed that laser lesions were more exactly defined in ICG than in fluorescein angiography (Fig 2C, D).

During follow up autofluorescence behaviour changed significantly (Table 3). After 1 week post treatment the laser lesions became hyperautofluorescent. The hyperautofluorescence of those laser lesions older than 1 week were stable over 15 months after irradiation (Fig 3). This appearance could be

observed in all patients with CSR and all but one patient with AMD. In the patients with diabetic maculopathy observation failed in four patients because of the retinal oedema.

In four patients no immediate change of the autofluorescence behaviour could be detected (test and treatment lesions) presumably due to larger retinal thickness and oedema. Three of these patients suffered from advanced diabetic maculopathy and one patient had large soft confluent drusen with leakage on angiography. In those cases even fluorescein angiography was not helpful to evaluate laser success because of the difficulty in distinguishing laser oedema from pathological oedema in the central macular area. Then ICG angiography was performed because—as already indicated above—it seems to have more potential to visualise the laser lesions as well demarcated hyperfluorescent spots (Fig 4).

Clinical outcomes

All patients with CSR showed disappearance of oedema and increase of visual acuity. Eight of 14 patients (57%) with diabetic maculopathy showed improvement of the disease, five were stable, and one got worse. In the AMD group five patients were stable and three (38%) showed reduction of drusen while visual acuity was unchanged (Table 4). In summary most of the patients have had benefit from the treatment. Best results could be obtained for CSR patients. Table 5 gives an overview about all treated patients.

DISCUSSION

The purpose of this study was to evaluate whether fundus autofluorescence is able to detect ophthalmoscopically invisible laser lesions from selective laser treatment as this could potentially then be used as non-invasive treatment control. Furthermore, the clinical outcome of the treated diseases was assessed.

Using the Heidelberg retina angiograph (HRA) it was possible to obtain in vivo fundus autofluorescence in a non-invasive and easy manner. Based on the results of the fundus spectrophotometry and in vitro examinations lipofuscin is thought to be the main fluorophor in autofluorescence.²²⁻²⁵ Since the main energy of therapeutic

Table 5 Summary of patient characteristics and the course of disease (sorted by diagnosis and course of the disease)

No	Sex	Age	Dx	Vapre	VApst	HE	Oedema	Drusen	Course	FU
1	Male	35	CSR	0.6	1.0		Less		Better	18
2	Male	45	CSR	0.6	0.8		Less		Better	6
3	Male	47	CSR	0.8	1.0		Less		Better	6
4	Male	51	CSR	0.25	0.6		Less		Better	6
5	Female	64	AMD	0.8	1.0		Less	Less	Better	6
6	Female	72	AMD	0.6	0.8			Less	Better	12
7	Female	70	AMD	0.5	0.6			Same	Better	12
8	Female	59	AMD	1.0	0.8		Less	Same	Stable	6
9	Female	67	AMD	0.4	0.4			Same	Stable	12
10	Female	73	AMD	0.8	0.6			Same	Stable	6
11	Female	75	AMD	0.8	0.6		Less	Same	Stable	12
12	Male	82	AMD	1.0	1.0			Same	Stable	12
13	Male	58	DMP	1.0	1.0	Less	Less		Better	6
14	Female	61	DMP	0.6	0.8	Less	Less		Better	6
15	Male	62	DMP	0.8	1.0		Less		Better	6
16	Male	66	DMP	0.4	0.8	Less	Less		Better	6
17	Male	66	DMP	0.6	0.8	Less	Less		Better	6
18	Male	68	DMP	0.5	0.5	Less	Less		Better	6
19	Female	73	DMP	0.8	0.8		Less		Better	6
20	Female	76	DMP	0.8	0.8	Less	Less		Better	18
21	Female	54	DMP	0.6	0.5		Same		Stable	6
22	Female	65	DMP	0.6	0.6		Same		Stable	6
23	Female	65	DMP	1.0	1.0	Same	Same		Stable	12
24	Male	70	DMP	0.8	0.8	Same	Same		Stable	6
25	Male	61	DMP	0.5	0.5		Same		Stable	6
26	Male	53	DMP	0.8	0.5	More	More		Worse	12

Dx = diagnosis; VA = visual acuity; HE = hard exudates judged by fundus photograph; oedema = oedema judged by fluorescein angiography; FU = follow up (months).

laser irradiance is absorbed in the melanosomes of the RPE,⁸ this structure is the primary site of damage; thus, laser treatment should have an effect on the lipofuscin and consecutively on the autofluorescence. In fact, we demonstrated that autofluorescence showed an intensity decay after conventional mild coagulation.¹⁹ There are two possible mechanisms to explain why the autofluorescence decreased after irradiation: firstly, RPE cells will be destroyed by the laser interaction and thus lead to hypofluorescent spots and, secondly, a focal oedema could act as a blockage for the autofluorescence. Presumably both mechanisms act together. However, in selective RPE laser treatment no visible lesion appears, suggesting that there is only minimal heat conduction and denaturation in the neurosensory layer. Thus, no immediate oedema should be obtained, but still autofluorescence is decreased in most of the patients 10 minutes after irradiation, indicating a destruction of the RPE. After 1 hour the hypofluorescent spots were more pronounced suggesting that during this time also some oedema may appear as a biological tissue reaction.

Nearly 85% of all patients showed hypofluorescence after selective laser treatment. However, dosimetry lesions at the lower vessel arcade were generally easier to detect than central lesions because of the lack of autofluorescence in the foveolar region due to the macular pigments, which act as a blockage for the laser excitation signal (488 nm). This could limit the potential application of this particular technique, but another possibility might be excitation with longer wavelengths—for example, 550 nm. By using this wavelength the central autofluorescence signal would be enhanced because excitation of the macular pigments would be avoided (Delori, personal communication). At this time the only reason for excitation of autofluorescence using 488 nm is the fact that this wavelength is also used for fluorescein angiography with no need for another laser device.

In some patients with pronounced diabetic maculopathy a decay of autofluorescence intensity was not observable. In these patients increased retinal thickness and retinal oedema seem to block the autofluorescence. Then ICG angiography was found to be more effective than fluorescein angiography to confirm laser success, because lesions were more clearly demarcated and could more easily be distinguished from pathological macular oedema.

It was interesting to note that after 1 week laser lesions became hyperautofluorescent indicating an ongoing biological reaction in the RPE layer. This behaviour of autofluorescence, changing from hypofluorescence to hyperfluorescence, could also be observed with conventional laser photocoagulation.¹⁹ Therefore, it can be assumed that a destruction of the RPE—no matter if with conventional or selective laser treatment—always leads to the same effect on the RPE. These effects of laser treatment on the fundus have been studied by several groups. It has been shown that cw argon laser photocoagulation of monkey and human fundus causes necrosis of the RPE and a lifting of the RPE from Bruch's membrane,^{26–28} budding of individual RPE cells,^{29–30} and a multilayered RPE formation in the area of laser irradiation by 7 days after treatment.^{26–27, 29–32} Histological sections revealed that RPE cells were destroyed and the choriocapillaris as well as the vessels of the choroidea were damaged.³³ After laser photocoagulation RPE cells migrate and proliferate to cover the defect resulting in an intact RPE barrier.³⁴ The same action took place in histological studies on animals after selective RPE laser treatment.^{7, 9} So proliferation of the RPE seems to be the general repair mechanism for any defects, cw laser photocoagulation as well as selective laser treatment, and apparently associated with a higher intensity of autofluorescence as underlined in this study. This intensity enhancement might be explained by a higher metabolic uptake in RPE proliferation and a subsequent increase of the fluorophor concentration. However, animal studies need to be conducted to prove this conclusion.

As shown in Figure 3 (test lesions at lower vessel arcade) such hyperautofluorescence could be stable for at least 1 year. It is not known what happens to the selective laser lesions after several years. Concerning the conventional laser treatment after 1–2 years all laser spots appear dark in autofluorescence suggesting RPE atrophy.¹⁹ Presumably this happens because of the irreversible destruction of the photoreceptors and consecutive loss of RPE, which might not happen in our laser approach maintaining intact photoreceptors.

Clinical outcome

The results of this prospective study regarding the clinical outcome underline previous results of a clinical study indicating that selective RPE laser destruction might be sufficient and effective in various macular diseases.¹² All patients with CSR showed disappearance of subretinal fluid, more than half of the patients with diabetic retinopathy had an improvement of the disease as judged by reduction of hard exudates and leakage, and in about a third of patients with AMD drusen reduction could be achieved. It might be possible that different treatment patterns with respect to localisation and number of lesions could further improve the clinical outcome. However, it indicates clearly that conventional laser strategies, which recommend visible laser burns (for example, Early Treatment Diabetic Retinopathy Study Research Group³⁵), grossly over-treat in macular diseases.¹²

As discussed, the effect of the selective laser treatment on the clinical course of the disease is thought to be the RPE proliferation. Marshall *et al* indicated that photocoagulation leads to cell division of the RPE remote to the lasered site, suggesting the indirect effect.³⁶ Thus, it seems not to be necessary to aim the laser directly on the macular pathology. After selective RPE laser destruction in rabbits it has been shown that the RPE reacts in a wide area around the lasered site.⁷ Therefore, this new technique has the potential to be used for all RPE related diseases like CSR, AMD, and diabetic maculopathy. It could also be considered for other diseases where conventional laser treatment is known to improve RPE “pump function”—for example, retinal vein occlusion.

CONCLUSION

Autofluorescence imaging is a proper non-invasive method to verify laser success of selective RPE laser destruction. Owing to destruction of RPE after irradiation a hypofluorescence is noticed, changing into hyperautofluorescence after 1 week, and this might indicate proliferation of the RPE. Autofluorescence has the potential to replace invasive fluorescein angiography as treatment control for the ophthalmoscopically invisible laser lesions. One limitation of this method is the decreased perifoveolar autofluorescence signal due to macular pigments, which makes it impossible to detect very central lesions. Longer wavelengths to excite autofluorescence could increase the perifoveolar signals. Another difficulty occurred when autofluorescence imaging failed, in cases where thicker retinal layers and large oedemas are present as in advanced diabetic maculopathy. In these cases ICG angiography is able to detect well demarcated laser lesions.

Patients with RPE related diseases such as CSR, diabetic maculopathy, and drusen maculopathy can mainly be treated with this new method without the risk of having laser scotomas afterwards. Prospective studies should evaluate this technique for other indications such as advanced AMD.

ACKNOWLEDGEMENTS

The authors would like to thank Georg Schuele, MSc, from the medical laser centre in Luebeck, Germany for technical support and helpful discussions and Kirsty Swindells, MD, from the Wellman Laboratories of Photomedicine, Massachusetts General Hospital, Harvard Medical School, Boston, USA, for proofreading the manuscript.

None of the authors have any conflict of interest related to the material or methods used in this study.

Presented in part on the ARVO annual meeting 2001 in Ft Lauderdale, Florida, USA.

.....

Authors' affiliations

C Framme, J Roeder, University Eye Hospital Regensburg, Germany
R Brinkmann, R Birngruber, Medical Laser Center, Luebeck, Germany

Correspondence to: Dr Carsten Framme, University Eye Hospital Regensburg, Franz-Josef-Strauss-Allee 11, D-93042 Regensburg, Germany; carsten.framme@klinik.uni-regensburg.de

Accepted for publication 9 May 2002

REFERENCES

- Meyer-Schwickerath G.** Koagulation der Netzhaut mit Sonnenlicht. *Ber Dtsch Ophthalmol Ges* 1949;**55**:256-9.
- Maiman TH.** Stimulated optical radiation in ruby. *Nature* 1960;**187**:493-7.
- Birngruber R.** Die Lichtbelastung unbehandelter Netzhautareale bei der Photokoagulation. *Fortschr Ophthalmol* 1984;**81**:147-9.
- Lorenz B, Birngruber R, Vogel A.** Quantifizierung der Wellenlängenabhängigkeit laserinduzierter Aderhauteffekte. *Fortschr Ophthalmol* 1989;**86**:644-54.
- Marshall J, Mellerio J.** Pathological development of retinal laser photocoagulations. *Exp Eye Res* 1968;**7**:225-30.
- Wallow IH, Birngruber R, Gabel VP, et al.** Netzhautreaktion nach Intensivlichtbestrahlung. *Adv Ophthalmol* 1975;**31**:159-232.
- Roeder J, Michaud NA, Flotte TJ, et al.** Response of the retinal pigment epithelium to selective photocoagulation. *Arch Ophthalmol* 1992;**110**:1786-1792.
- Gabel VP, Birngruber R, Hillenkamp F.** Visible and near infrared light absorption in pigment epithelium and choroid. In: Shimizu K, ed. *International Congress Series No 450, XXIII Concilium Ophthalmologicum*, Kyoto. Princeton, NJ: Excerpta Medica, 1978:658-62.
- Roeder J, Hillenkamp F, Flotte TJ, et al.** Microphotocoagulation: selective effects of repetitive short laser pulses. *Proc Natl Acad Sci USA* 1993;**90**:8643-7.
- Roeder J, Brinkmann R, Wirbelauer C, et al.** Retinal sparing by selective retinal pigment epithelial photocoagulation. *Arch Ophthalmol* 1999;**117**:1028-34.
- Roeder J, Wirbelauer C, Brinkmann R, et al.** Control and detection of subthreshold effects in the first clinical trial of macular diseases. *Invest Ophthalmol Vis Sci* 1998;**39**:104.
- Roeder J, Brinkmann R, Wirbelauer C, et al.** Subthreshold (retinal pigment epithelium) photocoagulation in macular diseases: a pilot study. *Br J Ophthalmol* 2000;**84**:40-7.
- Von Rückmann A, Fizke FW, Bird AC.** Fundus autofluorescence in age related macular disease imaged with a laser scanning ophthalmoscope. *Invest Ophthalmol Vis Sci* 1997;**38**:478-486.
- Delori FC, Dorey K, Staurengi G, et al.** In vivo autofluorescence of the ocular fundus exhibits retinal pigment epithelial lipofuscin characteristics. *Invest Ophthalmol Vis Sci* 1995;**36**:718-29.
- Von Rückmann A, Fizke FW, Bird AC.** Distribution of fundus-autofluorescence with a scanning laser ophthalmoscope. *Br J Ophthalmol* 1995;**119**:543-62.
- Wing GL, Blanchard GC, Weiter JJ.** The topography and age relationship of lipofuscin concentrations in the RPE. *Invest Ophthalmol Vis Sci* 1978;**17**:600-7.
- Feeney-Burns L, Berman ER, Rothman H.** Lipofuscin of the human retinal pigment epithelium. *Am J Ophthalmol* 1980;**90**:783-91.
- Feeney-Burns L, Hildebrand ES, Eldridge S.** Aging human RPE: morphometric analysis of macular, equatorial, and peripheral cells. *Invest Ophthalmol Vis Sci* 1984;**25**:195-200.
- Framme C, Roeder J.** Fundus-autofluorescence after conventional mild laser photocoagulation in diabetic retinopathy. *Invest Ophthalmol Vis Sci (Suppl)* 1999;**41**:S655.
- Bressler SB, Maguire MG, Bressler NM, et al,** and the Macular Photocoagulation Study Group. Relationship of drusen and abnormalities of the retinal pigment epithelium to the prognosis of neovascular macular degeneration. *Arch Ophthalmol* 1990;**108**:1442-7.
- The Laser Institute of America.** American National Standards of the safe use of laser. Toledo, Ohio: the American National Standards Institute, 1993. ANSI Z 136.1.1993.
- Boulton M, McKechnie M, Breda J, et al.** The formation of autofluorescent granules in cultured human RPE. *Invest Ophthalmol Vis Sci* 1989;**30**:82-9.
- Feeney L.** Lipofuscin and melanin of human retinal pigment epithelium. Fluorescence, enzyme cytochemical, and ultrastructure studies. *Invest Ophthalmol Vis Sci* 1978;**17**:583-600.
- Weiter JJ, Delori FC, Wing GL, et al.** Retinal pigment epithelial lipofuscin and choroidal melanin in human eyes. *Invest Ophthalmol Vis Sci* 1986;**27**:145-52.
- Von Rückmann A, Fizke FW, Zdenek JG.** Fundus-autofluorescence in patients with macular holes imaged with a laser scanning ophthalmoscope. *Br J Ophthalmol* 1998;**82**:346-51.
- Smiddy WE, Fine SL, Quigley HA, et al.** Comparison of krypton and argon laser photocoagulation: results of simulated clinical treatment of primate retina. *Arch Ophthalmol* 1984;**102**:1086-92.
- Smiddy WE, Fine SL, Quigley HA, et al.** Simulated treatment of recurrent choroidal neovascularization in primate retina: Comparative histopathologic findings. *Arch Ophthalmol* 1985;**103**:428-33.
- Smiddy WE, Fine SL, Quigley HA, et al.** Cell proliferation after laser photocoagulation in primate retina: an autoradiographic study. *Arch Ophthalmol* 1986;**104**:1065-9.
- Marshall J, Bird AC.** A comparative histopathologic study of argon and krypton laser irradiations of the human retina. *Br J Ophthalmol* 1979;**63**:657-68.
- Marshall J, Clover G, Rothery S.** Some new findings on retinal irradiation by krypton and argon lasers. *Doc Ophthalmol* 1984;**36**:21-37.
- Matsumoto M, Yoshimura N, Honda Y.** Increased production of transforming growth factor-β2 from cultures human retinal pigment epithelial cells by photocoagulation. *Invest Ophthalmol Vis Sci* 1994;**35**:4245-52.
- Pollack A, Heriot WJ, Henkind P.** Cellular processes causing defects in Bruch's membrane following krypton laser photocoagulation. *Ophthalmology* 1986;**93**:1113-19.
- Del Priore LV, Glaser BM, Quigley HA, et al.** Response of pig retinal pigment epithelium to laser photocoagulation in organ culture. *Arch Ophthalmol* 1989;**107**:119-22.
- Wallow IH.** Repair of the pigment epithelial barrier following photocoagulation. *Arch Ophthalmol* 1984;**102**:126-35.
- Early Treatment Diabetic Retinopathy Study Research Group.** Photocoagulation for diabetic macular oedema. *Arch Ophthalmol* 1985;**103**:1796-806.
- Marshall J, Clover G, Rothery S.** Some new findings of retinal irradiation by krypton and argon lasers. In: Birngruber R, Gabel VP, eds. *Laser treatment and photocoagulation of the eye. Doc Ophthalmol Proc Series 36*. The Hague: Junk, 1984:21-37.



Autofluorescence imaging after selective RPE laser treatment in macular diseases and clinical outcome: a pilot study

C Framme, R Brinkmann, R Birngruber, et al.

Br J Ophthalmol 2002 86: 1099-1106

doi: 10.1136/bjo.86.10.1099

Updated information and services can be found at:

<http://bjo.bmj.com/content/86/10/1099.full.html>

These include:

References

This article cites 32 articles, 21 of which can be accessed free at:

<http://bjo.bmj.com/content/86/10/1099.full.html#ref-list-1>

Article cited in:

<http://bjo.bmj.com/content/86/10/1099.full.html#related-urls>

Email alerting service

Receive free email alerts when new articles cite this article. Sign up in the box at the top right corner of the online article.

Topic Collections

Articles on similar topics can be found in the following collections

[Macula](#) (24 articles)

[Neurology](#) (1036 articles)

[Vision](#) (496 articles)

Notes

To request permissions go to:

<http://group.bmj.com/group/rights-licensing/permissions>

To order reprints go to:

<http://journals.bmj.com/cgi/reprintform>

To subscribe to BMJ go to:

<http://group.bmj.com/subscribe/>