

## CLINICAL SCIENCE

# Three dimensional ultrasound of retinoblastoma: initial experience

P T Finger, A Khoobehi, M R Ponce-Contreras, D Della Rocca, J P S Garcia Jr

*Br J Ophthalmol* 2002;**86**:1136–1138

See end of article for authors' affiliations

Correspondence to:  
Paul T Finger, MD, FACS,  
The New York Eye Cancer  
Center, 115 East 61st  
Street, New York City, NY  
10021, USA;  
[pfinger@eyecancer.com](mailto:pfinger@eyecancer.com)

Accepted for publication  
6 May 2002

**Aim:** To use 3D ultrasonography (3DUS) for the diagnosis of retinoblastoma.

**Methods:** Five eyes of three children with retinoblastoma were evaluated using a commercially available computerised 3DUS system. Interactive sectioning of the stored and reconstructed 3D volumes were performed. 3DUS and histopathological findings were correlated after enucleation.

**Results:** 3DUS examination revealed characteristics consistent with retinoblastoma: endophytic mass, retinal detachment, intratumoural calcifications, and secondary orbital shadowing. Unlike 2D imaging, 3DUS allowed for analysis of the acquired and stored volumes. Rotation and sectioning of this volume allowed the discovery of new oblique and coronal views. For example, calcium related orbital shadows were seen as 3D volumes and (coronal) cross sections of the optic nerve were evaluated for evidence of intraneural invasion by retinoblastoma.

**Conclusion:** This is the first reported series of patients examined with 3DUS imaging for retinoblastoma. This technique allowed for new oblique and coronal views of the tumour and optic nerve. The ability to retrospectively analyse the (scanned and stored) ocular volume facilitated patient care, teaching, tumour-volume analysis, and telemedicine.

Retinoblastoma is the most common primary intraocular malignancy in children. Imaging techniques are essential for the diagnosis and follow up of retinoblastomas. Ultrasonography has been used to reveal calcifications within the tumour and to evaluate extrascleral and optic nerve invasion.<sup>1–6</sup> After treatment, ultrasonography and ophthalmoscopy are the main tools used to evaluate intraocular tumour regression.<sup>7–10</sup>

Computer assisted three dimensional ultrasonography (3DUS) has become available to ophthalmological oncology.<sup>11</sup> There is an emerging literature on the use of 3DUS for tumour diagnosis, radiation plaque placement, and follow up of treated choroidal melanomas.<sup>12–15</sup>

This study presents the first reported use and our initial experience with 3DUS in evaluation of retinoblastoma. We have found new and exciting capabilities which have allowed us to produce unique and interesting views. Further experience and comparative studies will determine the role of 3DUS in the care of patients with retinoblastoma.

## MATERIALS AND METHODS

Our methods of three dimensional ultrasonography (3DUS) have been described.<sup>11–14</sup> In sum, we utilised a commercially available computerised 3D ultrasound system (Ophthalmic Technologies Incorporated (OTI) Downsview, Ontario, Canada) to examine three patients (five eyes) with retinoblastoma. This system typically acquires data from 90 consecutive two dimensional (2D) images from which a 3D volume is rendered. The 3D volume is presented as a block, which was sliced, rotated, and examined from transverse, longitudinal, oblique, and coronal orientations.

## RESULTS

Our first patient had a unilateral retinoblastoma. Before enucleation, 3DUS revealed multiple highly reflective nodules consistent with calcification (Fig 1A). Histopathology revealed a poorly differentiated retinoblastoma with intratumoural calcification and vitreous seeding (Fig 1B). Though focal extension to the optic nerve head was present ultrasound was

not able to detect this small amount of optic nerve invasion. Tumour measurements from 3DUS were an apical height of 10.4 mm, a largest basal dimension of 14.9 mm, and a tumour volume of 909 mm<sup>3</sup>.

A 10 month old girl with bilateral retinoblastoma was examined with 3DUS which revealed a large intraocular tumour with multiple highly reflective calcifications. The optic nerve was sectioned for longitudinal, transverse, and unique coronal views. Where the tumour was found to overlay the optic nerve head, 3DUS allowed us to scroll through sequential coronal sections of the orbital portion of the optic nerve (Fig 1C). Interactive examination of the 3D volume revealed no evidence of intraneural tumour invasion or intraneural calcification. Histopathological examination revealed a poorly differentiated, retinoblastoma with focal necrosis, calcifications and no optic nerve invasion (Fig 1D).

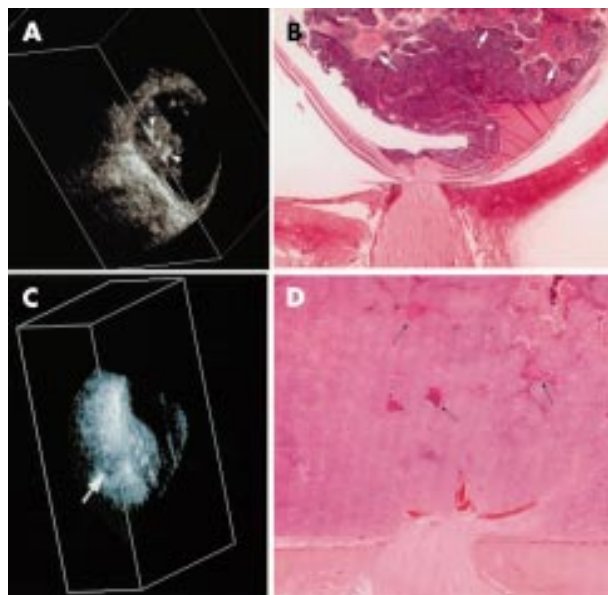
Another 10 month old girl with bilateral retinoblastoma presented with a total retinal detachment, a large exophytic retinoblastoma, and a transretinal tumour (Fig 2A). With 3DUS, views clearly differentiated between the juxtapapillary tumour, adjacent retinal detachment, and the second transretinal tumour (Fig 2B). Not visible by ophthalmoscopy, the optic nerve was free of tumour by 3DUS (Fig 2B).

This patient's right eye contained six non-macular tumours. Vitreous seeds could be imaged as overlying one of the tumours but could not be seen on ultrasound (Fig 2C). A unique coronal view allowed for three of the six tumours to be simultaneously imaged around the equator (Fig 2D).

Intratumour calcification causes orbital shadowing which can be confused with the optic nerve. Interactive sectioning of the 3D volume allows the examiner to clearly demonstrate the optic nerve shadow (in one plane of section) while simultaneously imaging the orbital shadow in a second plane (Fig 2E and F). This technique (obtained by quartering the reconstructed ocular volume) cannot be done with 2D imaging.

## DISCUSSION

Retinoblastomas are typically diagnosed before their third year of life. For the next 2 years, most ophthalmic



**Figure 1** (A) A coronal section of the eye in case 1. This unique 3D coronal section of the retinoblastoma demonstrates intratumoural calcification (arrowheads). (B) Histopathological correlation demonstrates the corresponding nodules of calcium (arrows). Note that the tumour overlies, but did not extend into the optic nerve (haematoxylin and eosin  $\times 10$ ). (C) In case 2 when the tumour was found to overlay the optic nerve head, 3DUS allowed us to scroll through sequential coronal sections of the orbital portion of the optic nerve (arrow). There was no ultrasonographic evidence of intraneural tumour invasion or calcification. (D) Histopathology of this enucleated eye also demonstrates retinoblastoma overlying the optic nerve with no intraneural invasion (haematoxylin and eosin  $\times 10$ ).

examinations are performed under anaesthesia. The risks of sedation requires the examiners be both quick and thorough.

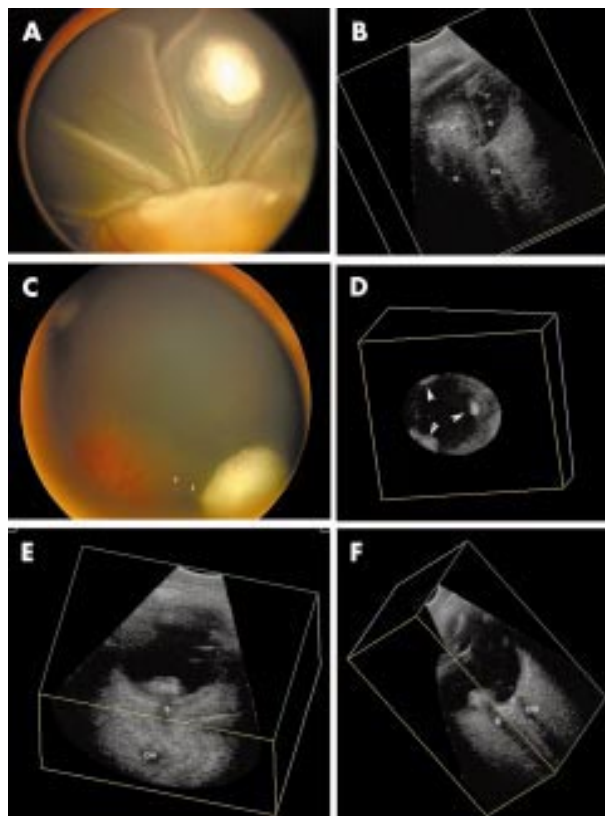
We have found 3DUS to be uniquely valuable for evaluation of retinoblastomas. This is because 3DUS includes the ability to replay and reconstruct ultrasonograms in standard, oblique, and coronal views. Therefore, one main advantage of 3DUS (compared to 2DUS) is that it allows for multiple interactive reviews of reconstructed ocular volumes (without patient contact or anaesthesia). It also allowed for the first ultrasound generated coronal views of the optic nerve.

These unique 3DUS capabilities become even more important when one considers the findings that have been associated with an increased risk for metastasis: tumour contact with the choroid, optic nerve invasion, and extrascleral extension.<sup>16</sup> Unlike standard two dimensional ultrasound (2DUS), 3DUS offers the potential to quantify the area of tumour contact with the choroid. With 3DUS, extrascleral extension and optic nerve invasion can be scrutinised with unique previously unavailable oblique and coronal sections. Though none of our patients exhibited intraneural tumour invasion, 3DUS clearly allowed for the first ultrasonographic views of serially examined coronal sections of the optic nerve.

Other unique findings included calcium related 3D orbital shadowing, unique coronal sections of the calcified tumour, as well as simultaneous views of a cross section the optic nerve and the tumour (obtained by quartering the reconstructed ocular volume). These cases demonstrate that 3DUS offers unique and valuable capabilities that can be used to improve the management of retinoblastoma.

#### ACKNOWLEDGEMENTS

Supported by The EyeCare Foundation, Inc, New York City, <http://www.eyecarefoundation.org> the Research Fund of The New York Eye and Ear Infirmary, New York, and Research to Prevent Blindness, New York City.



**Figure 2** (A) In case 3 a digital funduscopy image reveals a total retinal detachment, a large subretinal tumour, and a focus of transretinal retinoblastoma. (B) Interactive sectioning of the 3DUS volume revealed an image with included the large orbital shadow (S) created by the adjacent tumour (T), a normal appearing optic nerve shadow (ON) attached to the retina (R). (C) A RetCam photograph (one of the tumours in the left eye) documents an anterior retinoblastoma with several vitreous seeds too small to be resolved by ultrasound (arrows). (D) A unique coronal section was used to image three equatorial tumours in the same eye (arrowheads). These types of images could be used to determine relative distances between tumours (for example, for radiation therapy). Though it was not possible to view these three tumours simultaneously by ophthalmoscopy, they were concurrently imaged by interactive coronal sectioning of the 3D volume (arrowheads). (E) and (F) Unique simultaneous oblique and coronal views were sectioned to demonstrate asymmetric calcification within a smaller tumour, associated orbital shadowing (S), and how calcifications can be differentiated from the optic nerve (ON) in views obtained during interactive analysis a capability which is even more important with opaque media.

#### Authors' affiliations

**P T Finger, A Khoobeji**, The New York Eye Cancer Center and New York University School of Medicine

**P T Finger, M R Ponce-Contreras, D Della Rocca, J Garcia**, The New York Eye and Ear Infirmary, New York City, USA

#### REFERENCES

- Sterns GK**, Coleman DJ, Ellsworth RM. Characterization and evaluation of retinoblastoma by ultrasonography. *Bibl Ophthalmol* 1975;**83**:125-9.
- Pierro L**, Capoferri C, Brancato R. Early ultrasonographic diagnosis of hereditary retinoblastoma. *Pediatr Radiol* 1991;**21**:137-8.
- Maat-Kievit JA**, Oepkes D, Hartwig NG, *et al*. A large retinoblastoma detected in a fetus at 21 weeks gestation. *Prenat Diagn* 1993;**13**:377-84.
- Salim A**, Wiknjastro GH, Danukusumo D, *et al*. Fetal retinoblastoma. *J Ultrasound Med* 1998;**17**:717-20.
- Ramji FG**, Slovis TL, Baker JD. Orbital sonography in children. *Pediatr Radiol* 1996;**26**:245-58.

- 6 **Zilelioglu G**, Gunduz K. Ultrasonic findings in intraocular retinoblastoma and correlation with histopathologic diagnosis. *Int Ophthalmol* 1995;**19**:71-5.
- 7 **Spraul CW**, Lim JJ, Lambert HE, et al. Retinoblastoma recurrence after iodine-125 plaque application. *Retina* 1996;**16**:135-8.
- 8 **Wilson MW**, Czechonska G, Finger PT, et al. Chemotherapy for eye cancer. *Surv Ophthalmol* 2001;**45**:416-44.
- 9 **Finger PT**, Czechonska G, Demirci H, et al. Chemotherapy for retinoblastoma: a current topic. *Drugs* 1999;**58**:983-96.
- 10 **Motolese EG**, Addabbo G, Manes C. Ultrasonographic features and patterns of regression after conservative treatment of retinoblastoma. *Ophthalmologica* 1998;**212**(Suppl 1):42-3.
- 11 **Finger PT**. Three-dimensional (3D) ultrasound of the eye. In: Byrne SF, Green R, eds. *Ultrasound of the eye and orbit*. 2nd ed. St Louis: Mosby-Year Book, 2002:236-243.
- 12 **Finger PT**, Romero JM, Rosen RB, et al. Three-dimensional ultrasonography of choroidal melanoma: localization of radioactive eye plaques. *Arch Ophthalmol* 1998;**116**:305-12.
- 13 **Romero JM**, Finger PT, Izzzi R, et al. Three-dimensional ultrasound of choroidal melanoma: extrascleral extension. *Am J Ophthalmol* 1998;**126**:842-4.
- 14 **Romero JM**, Finger PT, Rosen RB, et al. Three-dimensional ultrasound for measurement of choroidal melanomas. *Arch Ophthalmol* 2001;**119**:1275-82.
- 15 **Shammas JH**, Dunne S, Fisher YL. Choroidal melanomas and other intraocular tumors. In: Shammas HJ, Dunne S, and Fisher YL eds. *Three-dimensional ultrasound tomography of the eye*. Ontario, Canada: Nova Coast Publishing, Eden Mills, 1998:114-17.
- 16 **Finger PT**, Harbour W, Karcioğlu Z. Risk factors for metastasis of retinoblastoma. *Surv Ophthalmol* 2002;**47**:1-36.



Find out what's in the latest issue  
the moment it's published

**Email Alerts**

Sign up to receive the table of contents by email every month. You can select from three alerts: Table of Contents (full), TOC Awareness (notice only); *British Journal of Ophthalmology* related announcements.

**[www.bjophthalmol.com](http://www.bjophthalmol.com)**



## Three dimensional ultrasound of retinoblastoma: initial experience

P T Finger, A Khoobehi, M R Ponce-Contreras, et al.

*Br J Ophthalmol* 2002 86: 1136-1138

doi: 10.1136/bjo.86.10.1136

---

Updated information and services can be found at:

<http://bjo.bmj.com/content/86/10/1136.full.html>

---

### References

*These include:*

This article cites 12 articles, 3 of which can be accessed free at:

<http://bjo.bmj.com/content/86/10/1136.full.html#ref-list-1>

Article cited in:

<http://bjo.bmj.com/content/86/10/1136.full.html#related-urls>

### Email alerting service

Receive free email alerts when new articles cite this article. Sign up in the box at the top right corner of the online article.

---

### Topic Collections

Articles on similar topics can be found in the following collections

[Public health](#) (377 articles)

[Retina](#) (1207 articles)

---

### Notes

---

To request permissions go to:

<http://group.bmj.com/group/rights-licensing/permissions>

To order reprints go to:

<http://journals.bmj.com/cgi/reprintform>

To subscribe to BMJ go to:

<http://group.bmj.com/subscribe/>