

CLINICAL SCIENCE

Macular hole and myopic refraction

H Kobayashi, K Kobayashi, S Okinami

Br J Ophthalmol 2002;**86**:1269–1273

Aim: To study a correlation between age at the onset and myopic refraction and axial length in patients with idiopathic macular hole and to evaluate a correlation of the size and surgical outcome of macular hole with axial length.

Methods: In a prospective clinical study, 94 eyes of 91 patients with stage III and IV idiopathic macular hole were enrolled. A standardised surgical protocol was performed using vitrectomy and gas tamponade. This study evaluated the size of macular hole and the rate of anatomical and functional success of surgery. To assess dimensions of macular hole, confocal laser scanning tomography was employed.

Results: Age at the onset showed a significant increase in relation to myopic refraction and axial length ($r = 0.689$, $p < 0.0001$; $r = 0.723$, $p < 0.0001$). Mean age was 52.1 (SD 10.3) years in eyes with axial length of 26.0 mm and longer, 64.5 (8.5) years in eyes with 23.0 to 25.99 mm, and 69.8 (5.7) years in eyes with shorter than 23.0 mm. In stage III macular holes, mean area of macular hole was 0.291 (0.134) mm² in eyes with 26.0 mm and longer, 0.283 (0.170) mm² in eyes with 23.0 to 25.99 mm, and 0.296 (0.160) mm² in eyes with shorter than 23.0 mm. No significant difference was found in area, volume, and depth of macular hole, and area of cuff and retinal striae among the three groups. Overall anatomical success rate and logMAR visual improvement in stage III macular holes were 100% (19 of 19 eyes) and -0.575 (0.174) in eyes with 26.0 mm and longer, 100% (16 of 16 eyes) and -0.536 (0.174) in eyes with 23.0 to 25.99 mm, and 95% (40 of 42 eyes) and -0.599 (0.201) in eyes with shorter than 23.0 mm; there was no significant difference.

Conclusions: Macular hole develops in eyes with the severer myopia at the younger age. Myopic refraction appears not to influence the size and surgical outcomes of macular holes. Further investigation on more cases is needed.

See end of article for authors' affiliations

Correspondence to: Hiroshi Kobayashi, MD, PhD, Department of Ophthalmology, Saga Medical School, 5-1-1 Nabeshima, Saga 849-8501, Japan; kobayas3@post.saga-med.ac.jp

Accepted for publication 6 May 2002

In the age related macular holes, vitreoretinal surgical techniques have been used to close macular holes based on theory that the tangentially oriented contraction of the premacular vitreous cortex is involved in the pathogenesis of macular holes.¹⁻³ The procedure for repairing a macular hole involves the removal of the premacular cortical vitreous and the performance of intraocular gas tamponade. Theories regarding the mechanisms by which closure of macular hole occurs include the release of vitreous traction and the formation of a glial scar.¹⁻¹⁰

Highly myopic individuals are known to be a high risk group for macular holes. The early stages of age related macular holes have been described,¹⁻¹⁰ but it is uncertain whether the degree of myopic refraction may influence the development of macular hole.^{11,12}

The objective of the present study was to study the effect of myopic refraction on the development of macular hole. We also investigated a relation between refractive error and the size of macular hole, and anatomical and visual improvement of surgery.

MATERIALS AND METHODS

Patients

We studied 94 eyes of 91 Japanese patients with idiopathic full thickness stage III and IV macular holes who had symptoms present for 6 months or shorter and were scheduled to undergo macular hole surgery. Any patient with pre-existing ocular disease (that is, trauma, chronic inflammatory, or neoplastic disorders) or previous surgery were excluded as were those with systemic disorders (diabetes, uncontrolled hypertension) or a known life threatening disease at enrolment into the study. Patients were informed of the purpose of our study and provided written informed consent. Macular holes were

diagnosed based on the results of slit lamp biomicroscopy with a precorneal lens, indirect ophthalmoscopy, and fluorescein angiography. A macular hole was defined as a full thickness, sharp-edged retinal defect with an elevated rim and retinal striae in the foveal area with a hyperfluorescent window defect visible on fluorescein angiography.

Evaluation of effects of macular hole surgery

All recruited patients were subjected to a detailed ophthalmic examination. Fully corrected visual acuity was measured using the Early Treatment Diabetic Retinopathy Study (ETDRS) chart, and the log of the minimum angle of resolution (logMAR) was calculated and used for all statistical analysis. A pretreatment fluorescein angiogram was obtained within 1 week of commencing surgery. Macular hole surgery was carried out as described below. After treatment the patients were reviewed at 2 weeks, 1, 2, 3, 6, 9, 12 months, and then every 6 months. Visual function was assessed at every visit and angiography scheduled at 1, 2, 3, 6, 12, 18, and 24 month visits. An increase or decrease in best corrected visual acuity (BCVA) was defined as a change of 0.2 or greater of logMAR BCVA. Safety was evaluated by determining the incidence of treatment related complications and adverse reactions. The patients were regularly questioned and examined for side effects. To detect adverse events, all patients were examined by the same examiner (HK) to avoid interobserver variation.

All patients had idiopathic macular holes classified according to the Gass system as stage II, III, or IV.^{1,2} All holes were measured before surgery using the vein at the edge of the optic nerve as a reference of 150 μ m. Stage II was defined as less than 400 μ m, and stage III as 400 μ m or greater with the vitreous attached to the optic nerve.³ Stage IV was any hole with a pre-existing vitreous separation.³ The stage was ultimately

Table 1 Demographics of patient groups

	High myopia	Mild and moderate myopia	Emmetropia and hyperopia
<i>All macular holes</i>			
Axial length	≥26.0 mm	23.0–25.99 mm	<23.0 mm
No of patients	20	17	54
Men	5 (25.0%)	4 (23.5%)	16 (32.7%)
Women	15 (75.0%)	13 (76.5%)	33 (67.3%)
Age (years)	52.1 (10.3) (23 to 70)	64.5 (8.5) (52 to 82)	69.8 (5.7) (57 to 82)
No of eyes	20	18	56
RE	8 (40.0%)	10 (55.6%)	33 (59.6%)
LE	12 (60.0%)	8 (44.4%)	23 (41.4%)
Duration since the onset (weeks)	7.6 (6.9) (1 to 24)	8.0 (5.2) (2 to 24)	9.4 (5.2) (1 to 24)
Refractive error (dioptres)	-9.28 (2.31) (-17.0 to -7.0)	-3.40 (1.17) (-8.0 to -2.0)	+0.27 (1.23) (-3.5 to +6.0)
Axial length (mm)	27.04 (0.93) (26.22 to 30.15)	23.78 (0.78) (22.82 to 25.43)	21.70 (0.71) (18.52 to 23.23)
Best corrected visual acuity	0.164 (20/122.0) (0.05 to 0.4)	0.180 (20/111.1) (0.03 to 0.4)	0.148 (20/135.1) (0.05 to 0.4)
LogMAR	0.786 (0.248)	0.744 (0.271)	0.828 (0.241)
<i>Stage III macular holes</i>			
Axial length	≥26.0 mm	23.0–25.99 mm	<23.0 mm
No of patients	19	15	41
Men	5 (25.0%)	3 (20.0%)	14 (34.2%)
Women	14 (75.0%)	12 (80.0%)	27 (65.8%)
Age (years)	52.6 (10.3) (23 to 70)	64.5 (8.5) (52 to 82)	69.1 (6.4) (57 to 82)
No of eyes	19	16	41
RE	8 (42.1%)	9 (56.3%)	24 (59.0%)
LE	11 (57.9%)	7 (43.7%)	18 (41.0%)
Duration since the onset (months)	6.9 (6.5) (1 to 24)	8.0 (5.2) (2 to 24)	7.6 (5.4) (1 to 24)
Refractive error (dioptres)	-9.34 (2.36) (-17.0 to -7.0)	-3.40 (1.17) (-8.0 to -2.0)	+0.27 (1.24) (-3.5 to +6.0)
Axial length (mm)	27.07 (0.94) (26.22 to 30.15)	23.78 (0.78) (22.82 to 25.43)	21.60 (0.70) (18.52 to 23.23)
Best corrected visual acuity	0.172 (20/116.3) (0.05 to 0.4)	0.200 (20/100.0) (0.03 to 0.4)	0.158 (20/124.2) (0.03 to 0.4)
LogMAR	0.764 (0.232)	0.699 (0.271)	0.795 (0.258)

determined intraoperatively when the presence or absence of vitreous separation could be ascertained.

Surgical procedure

A standard three port pars plana vitrectomy was performed in all patients.^{4–10} We achieved a complete posterior vitreous detachment during pars plana vitrectomy using a soft tipped needle. If epiretinal membranes were present, they were removed with a slightly bent microvitrectomy blade or a soft tipped needle; their absence was then verified. The edges of the macular hole were approximated as much as possible by gentle manipulation with the soft-tipped needle; the hole was smaller or closed at the end of the procedure. No adjuvant therapy, such as transforming growth factor β and autologous platelet concentrate, was administered to any patients.^{13–16} No internal limiting membrane removal was employed.^{17–19} Sulphur hexafluoride (20%) was used for gas tamponade. Patients remained in the prone position for 10–14 days postoperatively. The macular hole was considered to have closed when the surrounding cuff was flattened and the edge of the hole could not be identified by fundus biomicroscopy.

If the macular hole was not closed in the first operation, perifoveal tissue, especially tissue adhered to the edge of macular hole, was carefully dissected with a bent microvitrectomy blade or a soft-tipped needle. This tissue was then removed with end gripping forceps. No internal limiting membrane removal was employed. Sulphur hexafluoride (20%) was used for gas tamponade.

Heidelberg retina tomograph measurement

Preoperative imaging was obtained within 1 week before surgery (3.5 (SD 1.6) days). The Heidelberg retina tomograph (Heidelberg Engineering, Heidelberg, Germany), a confocal scanning diode laser (670 nm) retinal tomograph, was used to scan and analyse the macular area.^{20–26} The topographic images are a series of 32 optical images, which are taken along the z axis at height planes of 50–80 μ m each over a 2 mm scan depth. Each two dimensional transverse image consists of 256 \times 256 pixels scanned along the x and y axes, with a scanning

angle of 10–20°. The image acquisition time is 1.6 seconds. The technology of the laser scanner relies on an extremely shallow depth of field and thus the HRT records only the image at the focal plane, disregarding any information outside the focal plane. The resolution is 40 μ m along the z axis and 10 μ m along the x and y axes, as reported by Menezes and associates.²¹

In present study, the scan angle was 10° of the retina; the fovea was the centre of the scanned region. Scanning was performed with a scan depth of 2.0–2.5 mm. All examinations were performed by the same observer. Measurements were repeated five times to confirm reproducibility and to eliminate artefacts. Fluctuations were minimised by using the average of the five values obtained. When repeated measurement were done on the same picture, statistical analysis of the reproducibility of this measuring method showed a high correlation coefficient of 0.995.

We measured Heidelberg retina tomograph parameters of the macular holes, fluid cuff, and retinal striae, including the area of the macular hole, measured in square millimetres; and the volume of the macular holes, measured in cubic millimetres; the mean and maximum depths of the macular holes, measured in millimetres. We also measured the area of cuff and retinal striae, measured in square millimetres.

Statistical analysis

Values are presented as the mean (SD) and as the range, or as the frequencies. This method was chosen as an appropriate way to express the incidence of particular outcomes by broad categories of patients. For all two by two comparisons, the Fisher's exact test was used. Other comparisons of frequency distributions were performed using the χ^2 test for independence. Unless otherwise specified, data were analysed by unpaired, one sided *t* tests. A level of *p* < 0.05 was accepted as statistically significant.

For the pairing of groups, age, sex, best corrected visual acuity, dimensions of macular hole, and area of cuff and retinal striae at baseline were used for matching. We studied a correlation between the paired observation. If this observation

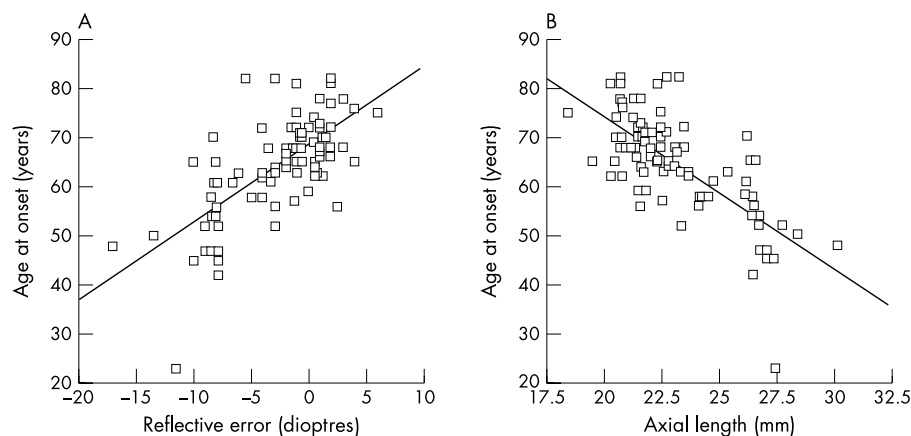


Figure 1 (A) Correlation between age of onset of macular hole and refractive error. (B) Correlation between age of onset and axial length.

was correlated, the F test was used to study two population variances.

RESULTS

Baseline data are summarised in Table 1. Ninety four eyes of 91 patients with idiopathic stage III and IV macular hole were enrolled in this study. Seventy seven eyes had stage III macular holes, and 17 eyes had stage IV holes. All eyes were divided into three groups based upon axial length; (1) 26.0 mm and longer (high myopia), (2) 23.0–25.99 mm (mild and moderate myopia), and (3) shorter than 23.0 mm (emmetropia and hyperopia). Age at the onset showed a significant correlation with refractive error and axial length ($r = 0.689$, $p < 0.0001$; $r = 0.723$, $p < 0.0001$) (Fig 1). Mean age at the onset was 52.1 (10.3) years in eyes with 26.0 mm and longer, 64.5 (8.5) years in eyes with 23.0–25.99 mm, and 69.8 (5.7) years in eyes with shorter than 23.0 mm; there was a significant difference between any two groups (all; $p < 0.001$) (Table 1). In all macular holes, duration since the onset decreased in relation to the increase of axial length; this was not statistically significant (Table 1).

Dimensions of macular hole

In all macular holes, the mean area of macular hole was 0.296 (0.135) mm^2 in eyes with 26.0 mm and longer, 0.318 (0.168) mm^2 in eyes with 23.0–25.99 mm, and 0.348 (0.168) mm^2 in eyes with shorter than 23.0 mm. Mean area, volume, maximal depth, and mean depth of macular hole, and area of cuff and

retinal striae also decreased in relation to myopic refraction (Table 2), but there was no significant difference.

In stage III macular holes, mean area of macular hole was 0.291 (0.134) mm^2 in eyes with 26.0 mm and longer, 0.283 (0.170) mm^2 in eyes with 23.0–25.99 mm, and 0.296 (0.160) mm^2 in eyes with shorter than 23.0 mm; there was no significant difference among the three groups (Table 2). No significant difference was found in mean volume, maximal depth and mean depth of macular hole, and area of cuff and retinal striae (Table 2).

Anatomical and functional success rate of macular hole surgery

In all macular holes, overall success rate was 100% (20 of 20 eyes) in eyes with 26.0 mm and longer of axial length, 94.4% (17 of 18 eyes) in eyes with 23.0–25.99 mm, and 89.2% (50 of 54 eyes) in eyes with shorter than 23.0 mm (Table 3). Mean logMAR visual improvement was -0.581 (0.581 in eyes with 26.0 mm and longer of axial length, -0.564 (0.208) in eyes with 23.0–25.99 mm, and -0.539 (0.265) in eyes with shorter than 23.0 mm (Table 3). The overall success rate and visual improvement in eyes with shorter than 23.0 mm of axial length was lower compared with the other groups; this is not statistically significant.

In stage III macular holes, the rate of overall success was 100.0% (19 of 19 eyes) in eyes with 26.0 mm and longer of axial length, 100.0% (16 of 16 eyes) in eyes with 23.0–25.99 mm, and 95.2% (40 of 42 eyes) in eyes with shorter than 23.0 mm (Table 3). The success rate at the first operation was

Table 2 Dimensions of macular holes

	High myopia	Mild and moderate myopia	Emmetropia and hyperopia
All macular holes			
Number of eyes	20	18	56
Area (mm^2)	0.296 (0.135) (0.064 to 0.524)	0.318 (0.168) (0.075 to 0.642)	0.348 (0.168) (0.067 to 0.662)
Volume (mm^3)	0.043 (0.041) (0.002 to 0.134)	0.056 (0.059) (0.002 to 0.213)	0.062 (0.046) (0.002 to 0.160)
Mean depth (mm)	0.119 (0.071) (0.031 to 0.263)	0.131 (0.095) (0.025 to 0.331)	0.147 (0.079) (0.023 to 0.286)
Maximal depth (mm)	0.235 (0.133) (0.063 to 0.498)	0.261 (0.184) (0.052 to 0.604)	0.290 (0.153) (0.048 to 0.574)
Area of cuff (mm^2)	0.831 (0.448) (0.216 to 1.855)	0.897 (0.483) (0.242 to 1.846)	0.954 (0.517) (0.144 to 1.854)
Area of retinal striae (mm^2)	3.228 (1.024) (1.896 to 5.213)	3.352 (1.165) (1.822 to 5.012)	3.787 (1.399) (1.155 to 5.213)
Stage III macular holes			
Number of eyes	19	16	39
Area (mm^2)	0.291 (0.134) (0.064 to 0.524)	0.283 (0.170) (0.044 to 0.662)	0.296 (0.160) (0.064 to 0.584)
Volume (mm^3)	0.042 (0.042) (0.002 to 0.134)	0.039 (0.035) (0.002 to 0.104)	0.051 (0.046) (0.002 to 0.160)
Mean depth (mm)	0.117 (0.072) (0.031 to 0.263)	0.107 (0.071) (0.025 to 0.232)	0.136 (0.082) (0.023 to 0.286)
Maximal depth (mm)	0.230 (0.135) (0.063 to 0.498)	0.215 (0.141) (0.052 to 0.455)	0.271 (0.159) (0.048 to 0.574)
Area of cuff (mm^2)	0.814 (0.453) (0.216 to 1.855)	0.842 (0.442) (0.242 to 1.809)	0.843 (0.510) (0.144 to 1.854)
Area of retinal striae (mm^2)	3.229 (1.016) (1.896 to 5.213)	3.352 (1.165) (1.822 to 5.042)	3.398 (1.364) (1.155 to 6.125)

Table 3 Anatomical and functional success rate

	High myopia	Mild and moderate myopia	Emmetropic and hyperopic group
<i>All macular holes</i>			
No of eyes	20	18	56
Hole closure			
Overall	20 (100.0%)	17 (94.4%)	50 (89.2%)
1st operation	16 (80.0%)	14 (77.8%)	40 (71.4%)
Postoperative best corrected visual acuity	0.622 (20/32.2) (0.2 to 1.0)	0.594 (20/33.7) (0.07 to 1.0)	0.511 (20/39.1) (0.08 to 1.0)
LogMAR (mean (SD))	0.206 (0.185)	0.226 (0.249)	0.295 (0.277)
Change of logMAR best corrected visual acuity	-0.581 (0.581) (-0.845 to -0.222)	-0.517 (0.188) (-0.845 to 0)	-0.539 (0.258) (-1.125 to 0)
Follow up duration (months)	21.3 (12.1) (6 to 48)	20.5 (10.9) (6 to 42)	23.5 (13.0) (6 to 48)
Reopening of macular hole	0 (0.0%)	1 (5.5%)	0 (0.0%)
<i>Stage III macular holes</i>			
No of eyes	19	16	42
Hole closure			
Overall	19 (100.0%)	16 (100.0%)	40 (95.2%)
1st operation	16 (80.0%)	13 (81.3%)	34 (81.0%)
Best corrected visual acuity	0.647 (20/30.9) (0.2 to 1.0)	0.687 (20/29.1) (0.3 to 1.0)	0.638 (20/31.4) (0.1 to 1.0)
LogMAR	0.189 (0.188)	0.163 (0.148)	0.198 (0.162)
Change of logMAR best corrected visual acuity	-0.575 (0.174) (-1 to -0.398)	-0.536 (0.174) (-0.845 to -0.301)	-0.599 (0.201) (-1.125 to 0)
Follow up duration (months)	21.8 (12.2) (6 to 48)	20.8 (10.7) (6 to 42)	23.3 (13.7) (6 to 48)
Reopening of macular hole	0 (0.0%)	1 (6.3%)	0 (0.0%)

80.0%, 80.0%, and 81.0%. No significant difference was found in overall success rate and success rate at the first operation. Mean preoperative and postoperative best corrected visual acuity was 0.172 (20/116.3) and 0.647 (20/30.9) in eyes with 26.0 mm and longer of axial length, 0.200 (20/100.0) and 0.687 (20/29.1) in eyes with 23.0 to 25.99 mm, and 0.161 (20/124.2) and 0.638 (20/31.4) in eyes with shorter than 23.0 mm (Table 3). Mean logMAR visual change was -0.575 (0.174), -0.536 (0.174), and -0.599 (0.201). No significant difference was found in the anatomical and functional improvement.

Mean follow up duration was 21.3 (12.1) months in eyes with 26.0 mm and longer of axial length, 20.5 (10.9) months in eyes with 23.0–25.99 mm, and 23.5 (13.0) months in eyes with shorter than 23.0 mm (Table 3); no significant difference was found among three groups. One (5.5%) of 18 eyes with 23.0–25.99 mm showed reopening of macular hole 30 months after surgery; the patient underwent reoperation and then the macular hole was closed. None of 20 eyes with 26.0 mm and longer axial length and 56 eyes with shorter than 23.0 mm axial length showed no reopening; there was no significant difference in the incidence of reopening among three groups.

DISCUSSION

We demonstrated a significant correlation of age of the onset with refractive error and axial length in patients with idiopathic stage III and IV macular hole. Age at onset showed a significant decrease in relation to axial length and myopic refraction. Mean age was 52.1 (10.3) years in eyes with severe myopia, 64.5 (8.5) years in eyes with mild and moderate myopia, and 69.8 (5.7) years in eyes with emmetropia and hyperopia. Akiba and we have reported that posterior vitreous detachment developed in the severer myopic eyes at the younger age.^{27, 28} Eyes with -3 dioptres and -8 dioptres had posterior vitreous detachment 4–5 years and 10–12 years earlier compared to emmetropic eyes, respectively. These results may be consistent with the difference of the age at the onset of macular hole. Before the development of posterior vitreous detachment, lacuna formation, advanced liquefaction, and numerous degenerative opacities are often observed in the vitreous of young highly myopic eyes. These vitreous degenerations may lead to the development of tangential traction of the premacular vitreous cortex and therefore the formation of macular hole. Concentrations of protein,

collagen, and hyaluronic acid were considerably lower in the human vitreous of patients with myopia compared with those without myopia.²⁹ Vitreous body in highly myopic eyes may be affected by the degenerative process than in non-highly myopic eyes. The increased volume of the vitreous cavity in the highly myopic eyes may play a major part in the early development of vitreous degeneration and macular holes.

In stage III macular holes, no significant difference was found in mean area, volume, mean depth, and maximal depth among eyes with high myopia eyes, mild and moderate myopia, and emmetropia. The anatomical success rate and logMAR visual improvement were 100% and -0.575 (0.174) in eyes with high myopia, 100% and -0.536 (0.174) in eyes with mild and moderate myopia, 95% and -0.599 (0.201) in eyes with emmetropia and hyperopia. There was no significant difference in the surgical outcome. These findings support that macular hole in highly myopic eyes may be identical to that in mild and moderate myopic eyes and emmetropic eyes, and that the similar mechanism may cause macular hole in eyes with high myopia, mild and moderate myopia, and emmetropia.

Sulkes *et al* showed that macular hole surgery resulted in anatomical and visual improvement in severely myopic eyes.¹² The retinal pigment epithelium change characteristic of myopic degeneration limited final visual acuity and hence outcome measures for improvement. In this study, no significant difference was found in anatomical success rate and functional recovery among highly myopic eyes, mild and moderate myopic eyes, and emmetropic eyes. In eyes with high myopia, two eyes (10%) had mild pigment epithelial change and the remaining eyes had no degeneration or atrophy. These findings may encourage ophthalmologists to treat macular hole in highly myopic eyes.

In this study area, volume, and depth of macular hole and area of cuff and retinal striae tended to decrease in relation to myopic refraction in all macular holes. Anatomical and visual outcomes tended to improve in proportion to myopic refraction. The percentage of stage IV macular hole was 7% in eyes with high myopic eyes, 8% in eyes with mild and moderate myopia, 25% in eyes with emmetropia and hyperopia. Duration since the onset decreased in relation to myopic refraction. Macular hole developed in patients with more severe myopia at the younger age, and the younger patients appeared to be aware of visual loss.

Although the sample size in each refractive error group was small, the current study demonstrated that (1) age at the onset of macular hole significant decreased in relation to the increasing myopic refraction; (2) no significant difference was found in area, volume and depth of macular hole and area of cuff and retinal striae among the highly myopic eyes, mild and moderate myopic eyes, and emmetropic eyes; (3) there was no significant difference in surgical outcomes. A future study of a large population is needed to verify this observation. However, this information may be clinically valuable when treating macular hole in highly myopic eyes.

.....
Authors' affiliations

H Kobayashi, K Kobayashi, S Okinami, Department of Ophthalmology, Saga Medical School, Saga, Japan

REFERENCES

- 1 **Gass JDM**. Idiopathic senile macular hole. Its early stage and pathogenesis. *Arch Ophthalmol* 1988;**106**:629-39.
- 2 **Johnson RN**, Gass JDM. Idiopathic macular holes: observations, stages of formation, and implications for surgical intervention. *Ophthalmology* 1988;**95**:917-24.
- 3 **Gass JDM**. Reappraisal of biomicroscopic classification of stages of development of a macular hole. *Am J Ophthalmol* 1995;**119**:752-9.
- 4 **Smiddy WE**, Michels RG, Glaser BM, *et al*. Vitrectomy for impending idiopathic macular holes. *Am J Ophthalmol* 1988;**105**:371-6.
- 5 **Jost BF**, Hutton WL, Fuller DG, *et al*. Vitrectomy in eyes at risk for macular hole formation. *Ophthalmology* 1990;**97**:843-7.
- 6 **Kelly NE**, Wendel RT. Vitreous surgery for idiopathic macular holes: results of a pilot study. *Arch Ophthalmol* 1991;**106**:654-9.
- 7 **Poliner LS**, Tornambe PE. Retinal pigment epitheliopathy after macular hole surgery. *Ophthalmology* 1992;**99**:1671-7.
- 8 **De Bustros S**, Wendel RT. Vitrectomy for impending and full-thickness macular holes. *Int Ophthalmol Clin* 1992;**32**:139-52.
- 9 **Wendel RT**, Patel AC, Kelly NE, *et al*. Vitreous surgery for macular holes. *Ophthalmology* 1993;**100**:1671-6.
- 10 **Ryan EH Jr**, Gilbert HD. Results of surgical treatment of recent-onset full-thickness idiopathic macular holes. *Arch Ophthalmol* 1994;**112**:1545-53.
- 11 **Freeman WR**, Azen SP, Kim JW, *et al*. Vitrectomy for the treatment of full-thickness stage 3 or 4 macular holes. *Arch Ophthalmol* 1997;**115**:11-21.
- 12 **Kokame GT**. Early stage of macular hole in a severely myopic eye. *Am J Ophthalmol* 1995;**119**:240-2.
- 13 **Sulkes DJ**, Smiddy WE, Flynn HW, *et al*. Outcomes of macular hole surgery in severely myopic eyes: a case-control study. *Am J Ophthalmol* 2000;**130**:335-9.
- 14 **Glaser BM**, Michels RG, Kupperman BD, *et al*. Transforming growth factor- β 2 for the treatment of full-thickness macular holes. A prospective randomized study. *Ophthalmology* 1992;**99**:1162-73.
- 15 **Lansing MB**, Glaser BM, Liss H, *et al*. The effect of pars plana vitrectomy and transforming factor-beta 2 without epiretinal membrane peeling on full-thickness macular holes. *Ophthalmology* 1993;**100**:868-72.
- 16 **Smiddy WE**, Glaser BM, Thompson JT, *et al*. Transforming growth factor β -2 significantly enhances the ability to flatten the rim of subretinal fluid surrounding macular holes. Preliminary anatomic results of a multicenter prospective randomized study. *Retina* 1993;**13**:296-301.
- 17 **Korobelnik J-F**, Hannouche D, Belayachi N, *et al*. Autologous platelet concentrate as an adjunct in macular hole healing. A pilot study. *Ophthalmology* 1996;**103**:590-4.
- 18 **Park DW**, Sipperley JO, Sneed SR, *et al*. Macular hole surgery with internal-limiting membrane peeling and intravitreal air. *Ophthalmology* 1999;**106**:1392-7.
- 19 **Mester V**, Kuhn F. Internal limiting membrane removal in the management of full-thickness macular holes. *Am J Ophthalmol* 2000;**129**:769-77.
- 20 **Brooks HL**. Macular hole surgery with and without internal limiting membrane peeling. *Ophthalmology* 2000;**107**:1939-48.
- 21 **Menezes AV**, Giunta M, Chisholm L, *et al*. Reproducibility of topographic measurements of the macular region with a scanning laser Ophthalmoscope. *Ophthalmology* 1995;**102**:230-5.
- 22 **Bartsch DU**, Intaglietta M, Bille JF, *et al*. Confocal laser tomographic analysis of the retina in eyes with macular hole formation and other focal macular diseases. *Am J Ophthalmol* 1989;**108**:277-87.
- 23 **Weinberger D**, Stiebel H, Gatton DD, *et al*. Three-dimensional measurements of idiopathic macular holes using a scanning laser tomograph. *Ophthalmology* 1995;**102**:1445-9.
- 24 **Beausencourt E**, Elsner AE, Hartnett ME, *et al*. Quantitative analysis of macular holes with scanning laser tomography. *Ophthalmology* 1997;**104**:2018-29.
- 25 **Kobayashi H**, Kobayashi K. Correlation of quantitative three-dimensional measurements of macular hole size with visual acuity after vitrectomy. *Graefes Arch Clin Exp Ophthalmol* 1999;**237**:283-8.
- 26 **Kobayashi H**, Kobayashi K. Quantitative measurements of changes of idiopathic stage 3 macular holes after vitrectomy using confocal scanning laser tomography. *Graefes Arch Clin Exp Ophthalmol* 2000;**238**:410-9.
- 27 **Akiba J**. Prevalence of posterior vitreous detachment in high myopia. *Ophthalmology* 1993;**100**:1384-7.
- 28 **Kobayashi H**, Ogino N. Incidence of posterior vitreous detachment in healthy eyes with age, sex, and refraction as variables. *Jpn J Clin Ophthalmol* 1985;**39**:514-5.
- 29 **Berman ER**, Michaelson IC. The chemical composition of the human vitreous body as related to age and myopia. *Exp Eye Res* 1964;**3**:9-15.



Macular hole and myopic refraction

H Kobayashi, K Kobayashi and S Okinami

Br J Ophthalmol 2002 86: 1269-1273
doi: 10.1136/bjo.86.11.1269

Updated information and services can be found at:
<http://bjo.bmj.com/content/86/11/1269.full.html>

These include:

References

This article cites 29 articles, 3 of which can be accessed free at:
<http://bjo.bmj.com/content/86/11/1269.full.html#ref-list-1>

Article cited in:
<http://bjo.bmj.com/content/86/11/1269.full.html#related-urls>

Email alerting service

Receive free email alerts when new articles cite this article. Sign up in the box at the top right corner of the online article.

Topic Collections

Articles on similar topics can be found in the following collections

[Retina](#) (1207 articles)
[Ophthalmologic surgical procedures](#) (962 articles)
[Optic nerve](#) (552 articles)
[Optics and refraction](#) (381 articles)

Notes

To request permissions go to:
<http://group.bmj.com/group/rights-licensing/permissions>

To order reprints go to:
<http://journals.bmj.com/cgi/reprintform>

To subscribe to BMJ go to:
<http://group.bmj.com/subscribe/>