

# PostScript

## LETTERS

If you have a burning desire to respond to a paper published in the *BJO*, why not make use of our "rapid response" option?

Log on to our website ([www.bjophthalmol.com](http://www.bjophthalmol.com)), find the paper that interests you, and send your response via email by clicking on the "eLetters" option in the box at the top right hand corner.

Providing it isn't libellous or obscene, it will be posted within seven days. You can retrieve it by clicking on "read eLetters" on our homepage.

The editors will decide as before whether to also publish it in a future paper issue.

### Sebaceous carcinoma of the eyelid: a rarity worth considering

The sebaceous carcinoma is a very rare malignant tumour primarily found in the area of the eyelid. Most of these carcinomas originate in the tarsal meibomian glands although they may in extremely rare cases originate in the glands of Zeis of the eyelashes or the sebaceous glands of the caruncle.<sup>1</sup> The peri-orbital primaries are reported to behave aggressively with the tendency to metastasise early with a significant mortality in most series.<sup>2</sup>

In many cases correct diagnosis of a sebaceous carcinoma of the eyelid is delayed not only as a result of the rarity of this tumour but also because of its ability to masquerade as a variety of other eye conditions such as chalazion or chronic blepharoconjunctivitis. A

high index of suspicion is vital if these tumours are to be adequately treated.

We present a case of sebaceous carcinoma and discuss the clinical behaviour, the diagnosis, and the differential diagnosis difficulties as well as the therapy.

#### Case report

A 78 year old patient presented with a localised inflammation in the centre of the right upper eyelid. Under local antibiotic therapy for 6 weeks the lesion increased in size and showed putrid secretion on the surface. The patient refused further treatment and presented 22 months later with no healing of the lesion on the upper lid and a visible increase in size. The clinical examination revealed an ulcerating tumour measuring 3 cm in diameter at the right upper lid with a bloody encrusted lid margin (Fig 1A) and an enlarged lymph node on the right preauricular area of the parotid gland. The ocular examination revealed no conjunctival or corneal involvement. A biopsy of the eyelid tumour revealed a carcinoma of a meibomian gland with complete infiltration of the upper lid. Conjunctival map biopsies were negative.

Two weeks later a total resection of the upper lid with rapid section examination of the resection margins was carried out as well as the extirpation of the lymph node and an underlying metastasis beneath the parotid gland. Because the rapid section examination from the lateral mucosal border did not show any infiltration with tumour tissue, we decided to do a three layered primary reconstruction of the upper lid with a pedicled temporal island flap covered with a full thickness skin graft from the contralateral upper lid. The reconstruction of the conjunctiva was achieved by an oral mucosal graft. In order to make the raising of the lid possible, the flap was fixed on the fascial residue of the superior levator palpebrae muscle. The histopathological reappraisal revealed tumour stage T3N1 (Fig 2) and a R0 resection.

Two weeks after the surgery a neck dissection was performed and an adjuvant radiation therapy of the right orbit as well as the cervical lymph draining was begun in 25 cycles with a dose of 50 Gy.

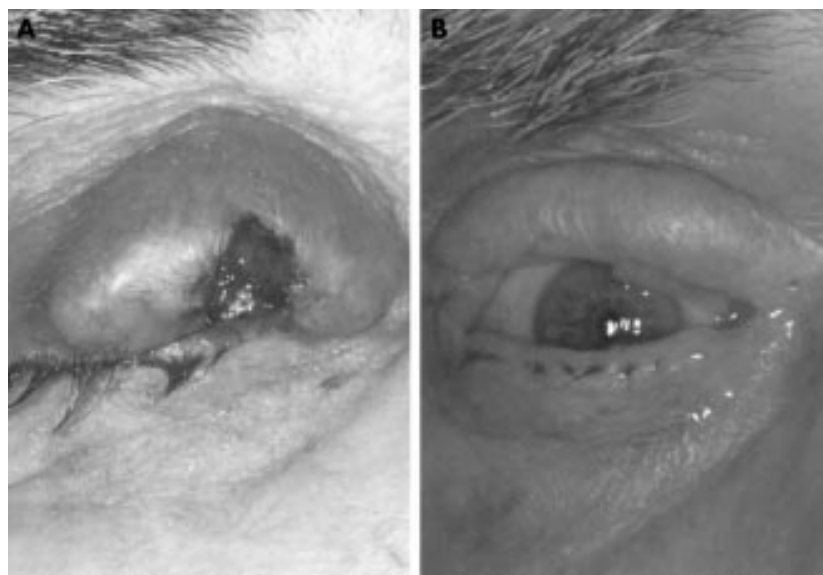
A local relapse or further metastasis 15 months after the surgery did not occur (Fig 1B).

#### Comment

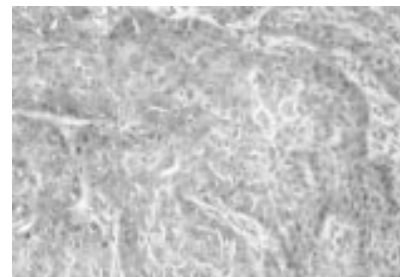
The low incidence and the non-specific clinical symptoms led us to conclude that the diagnosis of a sebaceous carcinoma of the eyelid often occurs very late. One warning sign is the local loss of the eyelashes resulting from a tumour infiltration of the follicle. Every therapy refractive, one sided, tumour-like eyelid lesion has to be clarified histologically to rule out a sebaceous carcinoma. A full thickness eyelid biopsy combined with conjunctival map biopsies is the appropriate approach to the diagnosis.<sup>3</sup> In our case we found the typical pagetoid infiltration of the overlying epidermis at the margins of the widely exulcerated carcinoma. It presented without sign of multicentric growth, which together with pagetoid spread indicates poor prognosis.<sup>4</sup>

The therapy of choice for the sebaceous carcinoma is primarily a surgical one. If the tumour is very large or recurrent with demonstrated spread to bulbar conjunctiva, to the other eyelid, or to orbital tissue, a subtotal or complete exenteration may be necessary.<sup>5-7</sup> If evidence of spread to regional lymph nodes is present a lymph node or radical neck dissection should be performed,<sup>8</sup> usually combined with partial parotidectomy.<sup>3</sup> An alternative to the surgical excision is the radiation therapy with a total dose of >50 Gy.<sup>9</sup> Radiation therapy may be considered as an adjunct to local surgery. Recurrence of tumour usually occurs within 3 years following radiotherapy alone.<sup>10</sup>

There are some techniques of eyelid reconstruction presently available. An ideal eyelid reconstruction should replace the missing tarsoconjunctival structures and skin, protect the globe, give a natural appearance with only minor donor defect morbidity, and should be done as a one stage procedure. The temporal island flap described in our case report has the advantage of being a one stage procedure, which is relatively easy and quickly done and provides well vascularised tissues. A disadvantage is that the overlying temporal skin of the island flap can be very heavy, which makes



**Figure 1** (A) A 78 year old man with a meibomian carcinoma of the right upper eyelid. Note the exulcerating tumour measuring 3 cm in diameter with a bloody encrusted lid margin. (B) Result 15 months after surgery.



**Figure 2** Deep infiltrating partly sebaceous differentiated tumour formations with high mitotic activity (haematoxylin and eosin,  $\times 200$ ).

de-epithelialisation or excision of the relatively thick skin and replacement by a full thickness skin graft necessary.

Postoperative patients must be followed up at short intervals as the tumour has a fast growth potential. The approximate guidelines are 3 monthly interval during the first year, 6 monthly during the second year, and then on a yearly basis for life.<sup>3</sup>

**Alexander Gardetto**  
**Christian Rainer**

Department of Plastic and Reconstructive Surgery,  
University Hospital of Innsbruck and  
Ludwig-Boltzmann-Institute for Quality Control in  
Plastic Surgery, Austria

**Christian Ensinger**

Institute of Pathology, University Hospital of  
Innsbruck, Austria

**Ivo Baldissera**

Department of Ophthalmology, University Hospital  
of Innsbruck, Austria

**Hildegunde Piza-Katzer**

Department of Plastic and Reconstructive Surgery,  
University Hospital of Innsbruck and  
Ludwig-Boltzmann-Institute for Quality Control in  
Plastic Surgery, Austria

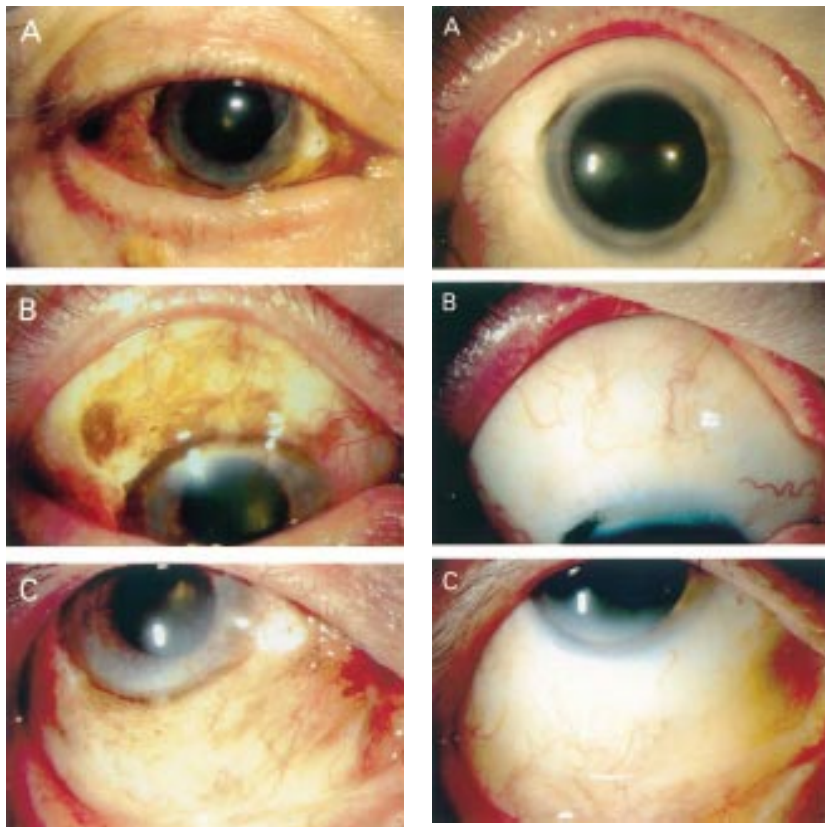Correspondence to: Alexander Gardetto, MD,  
University Hospital of Innsbruck, Department of  
Plastic and Reconstructive Surgery, Anichstrasse 35,  
A-6020 Innsbruck, Austria;  
[alexander.gardetto@uibk.ac.at](mailto:alexander.gardetto@uibk.ac.at)  
Accepted for publication 27 April 2001

## References

- 1 **Batsakis JG**, Littler ER, Leahy MS. Sebaceous cell lesions of the head and neck. *Arch Otolaryngol* 1972;**95**:151.
- 2 **Prioleau PG**, Santa Cruz DJ. Sebaceous gland neoplasia. *J Cutaneous Pathol* 1984;**11**:396-414.
- 3 **Zürcher M**, Hintschich CR, Garner A, *et al*. Sebaceous carcinoma of the eyelid: a clinicopathological study. *Br J Ophthalmol* 1998;**82**:1049-55.
- 4 **Rao NA**, Hidayat AA. Sebaceous carcinomas of the ocular adnexa. *Hum Pathol* 1982;**13**:113-22.
- 5 **Doxanos MT**, Green WR. Sebaceous gland carcinoma. *Arch Ophthalmol* 1984;**102**:245-9.
- 6 **Haas AF**, Kietly DW. Basal cell carcinoma. In: Mannis MJ, Maccsai MS, Huntly AC, eds. *Eye and skin disease*. Philadelphia: Lippincott-Raven Publishers, 1996:395-403
- 7 **Harvey JT**, Anderson RL. The management of meibomian gland carcinoma. *Ophthalmic Surg* 1982;**13**:56-61.
- 8 **Kostick Da**, Linberg JV, McCormick SA. Sebaceous gland carcinoma. In: Mannis MJ, Maccsai MS, Huntly AC, eds. *Eye and skin disease*. Philadelphia: Lippincott-Raven Publishers, 1996:413-17.
- 9 **Yen MT**, Tse DT, Wu X, *et al*. Radiation therapy for local control of eyelid sebaceous cell carcinoma: report of two cases and review of the literature. *Ophthal Plast Reconstr Surg* 2000;**16**:211-5.
- 10 **Nunery WR**, Welsh MG, McCord CD Jr. Recurrence of sebaceous carcinoma of the eyelid after radiation therapy. *Am J Ophthalmol* 1983;**96**:10-15.

## Dramatic regression of conjunctival and corneal acquired melanosis with topical mitomycin C

Conjunctival primary acquired melanosis is the most important precursor of conjunctival malignant melanoma.<sup>1,2</sup> Primary acquired melanosis appears as flat, patchy, non-cystic pigmentation in the conjunctival epithelium and can remain dormant for years or show



**Figure 1** Before mitomycin C treatment. (A) The entire medial and lateral bulbar conjunctiva, limbus, and cornea are superficially infiltrated with brown pigment of primary acquired melanosis. A biopsy had been previously taken at the medial limbus where the pigment is absent. (B) Extensive primary acquired melanosis of superior conjunctiva with diffuse limbal and corneal pigmentation is shown. (C) Diffuse conjunctival melanosis inferiorly is demonstrated.

**Figure 2** Ten months after mitomycin C treatment. (A) The corneal and conjunctival melanosis has completely resolved with minor granular pigment at the superotemporal limbus. (B) Dramatic resolution of superior melanosis with no epithelial abnormality. (C) Impressive resolution of inferior melanosis.

slow progression.<sup>2</sup> Studies have shown that it leads to conjunctival melanoma in approximately 1% to 30% patients.<sup>3,4</sup> Treatment of primary acquired melanosis includes observation, excisional biopsy, alcohol epitheliectomy, cryotherapy, and topical chemotherapy.<sup>1,2,5,6</sup> We illustrate a dramatic case where topical chemotherapy provided complete regression of advanced, aggressive primary acquired melanosis.

A 73 year old white man had noted slowly progressive pigmentation on the surface of his right eye for 5 years. A biopsy revealed intraepithelial conjunctival melanosis with atypia. The patient was referred to the Oncology Service at Wills Eye Hospital for evaluation and management. On examination, his visual acuity was 20/20 right eye and 20/40 left eye. Intraocular pressures were 13 mm Hg in both eyes. The interior of both eyes was unremarkable with mild nuclear sclerosis and mild retinal pigment epithelial mottling. The only abnormality on examination was the presence of patchy, flat, brown conjunctival pigmentation on the right eye for 360 degrees on the bulbar and fornical conjunctiva with involvement of the caruncle, upper tarsal conjunctiva, and entire surface of the cornea (Fig 1). There was no thickening or excessive vascularity to suggest malignant melanoma.

One option for management of this precancerous condition was extensive conjunctival excision and 360 degrees of cryotherapy followed by complete alcohol induced corneal epitheliectomy with anticipation of extensive postoperative scarring, possible symblepharon, and likely conjunctival overgrowth onto the cornea because of the absence of corneal stem cells. The other options included topical chemotherapy with mitomycin C or low dose radiotherapy with a custom designed conformal plaque. Mitomycin C was selected and the patient was treated with a total of 6 weekly cycles of topical mitomycin C 0.04% four times daily interrupted by a week's hiatus of no medication between each cycle.

Three months after therapy, the primary acquired melanosis was 80% resolved and at 10 months' follow up, the melanosis had nearly completely disappeared with minor granular pigment near the limbus (Fig 2). During the weeks of topical chemotherapy, the patient had occasional symptoms of ocular irritation and periocular cutaneous erythema and minor oedema. The ocular surface was injected during treatment but, on follow up, there was no chronic ocular surface disease or skin or cilia abnormality.

Topical mitomycin C ophthalmic preparation has been found to be safe and effective for conjunctival squamous neoplasia.<sup>7</sup> Its usefulness for conjunctival melanocytic neoplasia is debatable and not yet proved in a large series of patients. A recent study on a small number of patients with conjunctival melanoma and

melanosis indicated a possible role for topical chemotherapy, but the authors advised further investigation.<sup>6</sup> In this regard, we prefer to reserve mitomycin C therapy for patients with biopsy proved primary acquired melanosis with atypia. An important observation in our case was the effectiveness of topical chemotherapy for corneal melanosis where other methods of treatment could have led to scarring, conjunctival overgrowth, and ultimate visual loss. We emphasise, however, that patients should be monitored biomicroscopically while taking the medication as overuse could lead to lasting corneal and scleral tissue damage. The recommended duration of treatment has not yet been established in a randomised study. We prefer to limit treatment to two to four cycles with a non-treatment weekly hiatus between cycles to avoid complications. In summary, we report a dramatic case that supports the value of topical mitomycin C for primary acquired melanosis.

### Acknowledgments

Support provided by the Eye Tumor Research Foundation, Philadelphia, PA (CS) and the Paul Kayser International Award of Merit in Retina Research, Houston TX (JS).

**Carol L Shields, Hakan Demirci, Jerry A Shields, Christopher Spanich**

Ocular Oncology Service, Wills Eye Hospital Service, Thomas Jefferson University, Philadelphia, PA, USA

Correspondence to: Carol L Shields, MD, Ocular Oncology Service, Wills Eye Hospital, 900 Walnut Street, Philadelphia, PA 19107, USA  
Accepted for publication 15 June 2001

### References

- 1 Shields CL, Shields JA, Cater J, *et al*. Conjunctival malignant melanoma: risks for recurrence, exenteration, metastasis, and death in 150 cases. *Arch Ophthalmol* 2000;**118**:1497–507.
- 2 Shields JA, Shields CL. Melanocytic tumors. In: *Atlas of conjunctival and eyelid tumors*. Philadelphia: Lippincott Williams and Wilkins 1999:243–65.
- 3 Gloor P, Alexandrakis G. Clinical characterization of primary acquired melanosis. *Invest Ophthalmol Vis Sci* 1995;**36**:1721–9.
- 4 Folberg R, McLean I, Zimmerman LE. Conjunctival melanosis and melanoma. *Ophthalmology* 1984;**91**:673–8.
- 5 Shields JA, Shields CL, DePotter P. Surgical management of conjunctival tumors: the 1994 Lynn B. McMahan Lecture. *Arch Ophthalmol* 1997;**115**:808–15.
- 6 Demirci H, McCormick SA, Finger PT. Topical mitomycin C chemotherapy for conjunctival malignant melanoma and primary acquired melanosis with atypia. *Arch Ophthalmol* 2000;**118**:885–91.
- 7 Frucht-Pery J, Sugar J, Baum J, *et al*. Mitomycin C treatment for conjunctival-corneal intraepithelial neoplasia. A multicenter experience. *Ophthalmology* 1997;**104**:2085–93.

### Recurrent corneal ulceration as late complication of toxic keratitis

Abuse of topical anaesthetic agents is a rare but potentially dangerous cause of toxic keratitis. Persistent use of topical anaesthetics may result in severe pain, hyperaemia, mucopurulent discharge, chronic epithelial defects, stromal infiltrates with oedema and neovascularisation, and even hypopyon or hyphaema.<sup>1</sup> Permanent corneal scarring and visual loss may lead to penetrating keratoplasty and enucleation.<sup>2</sup> Patients have obtained anaesthetic drops from eye care practitioners and

pharmacists, from theft of the practitioners' offices, and over the counter in some developing countries.<sup>2–4</sup> We present a case of toxic keratitis secondary to topical anaesthetic abuse that is unique in two aspects. Firstly, the patient received the drops directly from an emergency department physician and, secondly, the patient developed an ulcerative keratitis months after the cornea had re-epithelialised.

### Case report

A 24 year old woman presented with complaints of decreased vision and severe eye pain bilaterally. Two weeks before presentation, she had a history of intensely pruritic allergic conjunctivitis. She was examined by a community hospital emergency department physician, who reportedly treated her for a corneal abrasion in the right eye. Two ophthalmologists subsequently treated her for presumed bilateral bacterial keratitis that worsened despite aggressive topical antibiotic therapy, and the patient was referred to the UMDNJ-New Jersey Medical School ophthalmology department. The patient was not a contact lens wearer, and she denied tap or pool water exposure. Past medical history was unremarkable.

On examination, visual acuity was hand movements in both eyes. The eyelids were oedematous and the palpebral and bulbar conjunctiva were severely hyperaemic. The corneas had relatively symmetrical 5 by 7 mm epithelial defects with underlying dense stromal ring infiltrates (Fig 1). The stromas were mildly thinned, and endothelial folds and fine keratitic precipitates were noted. Anterior chamber examination revealed a mild cell and flare reaction, but no hypopyon. Iris, pupils, and lens examinations were unremarkable, and retinal examination revealed normal macula, disc, and blood vessels in both eyes.

Initial differential diagnosis included bacterial, fungal, viral, and *Acanthamoeba* infection. However, after repeated review of the history, the patient admitted that the initial emergency department physician had given her a bottle of topical anaesthetic and told her "not to tell anyone." The patient confessed to using

the oxybuprocaine (proparacaine) drops every hour in both eyes over the previous 2 weeks. The anaesthetic drops were discarded, and treatment with erythromycin ointment, diclofenac drops, and homatropine 5% was instituted. A bandage soft contact lens reduced the patient's pain. Corneal cultures, performed to rule out concurrent or subsequent infection, were negative. Over the next week, visual acuity improved to 20/80 in the right eye and 20/40 in the left, though residual bilateral 4 mm epithelial defects with stromal rings remained. The patient was then lost to follow up for 2 months.

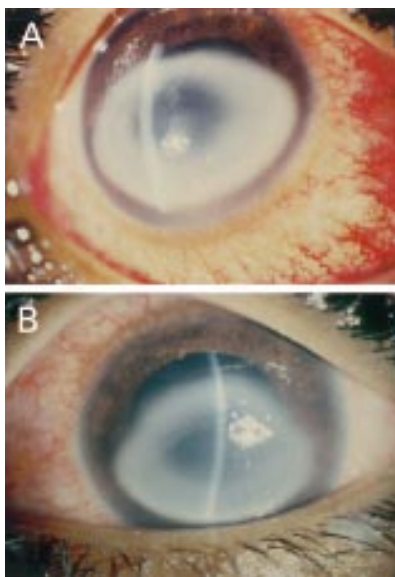
Follow up examination revealed a residual epithelial defect in the right eye, and healed epithelium in the left eye. Over the next month, the epithelial defect resolved in the right eye, but bilateral ring-like stromal haze persisted. Four months later the patient presented with a new 2 by 3 mm epithelial defect with underlying stromal infiltrate and neovascularisation in the left eye (Fig 2). The patient vehemently denied any further use of topical anaesthetic drops. Cultures were performed, and treatment with ofloxacin and erythromycin was instituted. The cultures were negative, and the epithelial defect slowly resolved. The underlying corneal stroma remained opacified and neovascularisation progressed. At last examination, visual acuities were 20/40 in the right eye, and counting fingers at 1 foot in the left eye.

### Comment

Topical anaesthetic agents are routinely used in ophthalmic examinations and procedures. The most commonly used preparations include oxybuprocaine and amethocaine (tetracaine). They are topical ester anaesthetics with fast onset of action (10–20 seconds), and relatively short durations of action (10–15 minutes).<sup>1</sup> The agents act by interfering with sodium transmission through neuronal membranes, thereby stabilising the transmembrane potential, inhibiting the generation of action potentials, and blocking the sensation of pain.<sup>5</sup>

The toxic effects of topical anaesthetics are both direct and indirect. Epithelial cell organelles, desmosomes, and cytoskeletal elements can be directly damaged by these agents, altering cellular metabolism and function.<sup>4–7</sup> Indirectly, loss of epithelial microvilli can cause tear film instability, promoting corneal desiccation and inhibiting re-epithelialisation.<sup>4–7</sup> Secondary neurotrophic changes may then occur.

Electron microscopy of corneal endothelial cells exposed to topical anaesthetics shows loss of the normal mosaic of hexagonal cells and abnormalities of the intercellular junctions and apical attachments.<sup>3</sup> Immune complexes released from the cornea may be



**Figure 1** (A, B) Slit lamp photographs demonstrating bilateral corneal ulceration with ring infiltrates secondary to topical anaesthetic abuse.



**Figure 2** Slit lamp photograph of left eye with recurrent corneal ulceration and neovascularisation 4 months after initial resolution.

recognised by the body as antigen, causing the Wessely immune ring infiltrate seen clinically.<sup>4,5</sup> A combination of these mechanisms may result in the clinical manifestations presented in our case.

Patients who have abused topical anaesthetic agents often present in extreme pain. There may be eyelid oedema with mucopurulent discharge and conjunctival hyperaemia. Like our patient, large chronic corneal epithelial defects with underlying stromal infiltrates are often initially misdiagnosed as *Acanthamoeba* or Gram negative bacterial infection.<sup>3,6</sup> The stroma may be oedematous or thinned. Keratitic precipitates and an anterior chamber reaction are common. Cultures are most often negative, but superinfection may occur. Infectious crystalline keratopathy, which is usually associated with concomitant use of topical corticosteroids, has been reported in association with topical anaesthetic abuse.<sup>2</sup> In that report, Kintner *et al* diagnosed *Streptococcus viridans* by corneal biopsy.<sup>2</sup> Concurrent or subsequent infection with *Pseudomonas* and *Bacillus* has also been reported.<sup>5</sup> Stromal neovascularisation and scarring complicate the healing and may be responsible for permanently decreased visual acuity. Patients may undergo conjunctival flaps, penetrating keratoplasty, and even enucleation for intractable pain after anaesthetic abuse.<sup>4,5</sup>

We are unaware of previous reports of a late occurring corneal ulcer after resolved toxic keratitis, and could find no reference to it in a computerised search utilising Medline. While the initial visual acuity improved to 20/40 in the left eye, late ulceration resulted in stromal scarring and neovascularisation that ultimately led to the poor visual acuity. The patient now requires penetrating keratoplasty to restore vision. The initial epithelial toxicity may have caused unstable epithelial attachment to the underlying stroma, leaving it susceptible to erosion and ulceration. Close long term follow up is necessary for these patients.

Patients who abuse topical anaesthetic agents obtain the drugs in various ways. In a report from Saudi Arabia, several patients sustained toxic keratopathy after the anaesthetic was dispensed over the counter.<sup>3</sup> In countries where dispensing is more restricted, patients have been inappropriately prescribed topical anaesthetics by optometrists, ophthalmologists, and even otolaryngologists.<sup>2</sup> Theft of the drugs from practitioners' offices may also contribute to the abuse.<sup>2</sup> An association between topical anaesthetic abuse and psychiatric disturbances has been reported.<sup>2</sup> In our case, the patient vehemently insisted that an emergency department physician gave her the oxybuprocaine. If true, then the dangers of topical anaesthetic abuse need to be more widely understood throughout the entire medical community. This information may ultimately lead to a decreased incidence of this rare but preventable entity.

#### Acknowledgments

Presented as poster at the American Society of Cataract and Refractive Surgery Meeting, Boston, MA, USA May 2000.

The authors have no financial interest in any product mentioned in this report.

#### Barry N Wasserman

Princeton Eye Laser Center, 100 Canal Pointe Blvd, Suite 112, Princeton, NJ 08540, USA

#### Robert P Liss

Chester County Eye Care Associates, 606 East Marshall Street, Suite 104, West Chester, PA 19380, USA

Correspondence to: Barry N Wasserman, MD, Princeton Eye Laser Center, 100 Canal Pointe Blvd, Suite 112, Princeton, NJ 08540, USA; Bnwass27@aol.com  
Accepted for publication 27 June 2001

#### References

- 1 Penna EP, Tabbara KF. Oxybuprocaine keratopathy: a preventable disease. *Br J Ophthalmol* 1986;**70**:202-4.
- 2 Kintner JC, Grossniklaus HE, Lass JH, *et al*. Infectious crystalline keratopathy associated with topical anaesthetic abuse. *Cornea* 1990;**9**:77-80.
- 3 Risco JM, Millar LC. Ultrastructural alterations in the endothelium in a patient with topical anaesthetic abuse keratopathy. *Ophthalmology* 1992;**99**:628-33.
- 4 Varga JH, Rubinfeld RS, Wolf TC, *et al*. Topical anaesthetic abuse ring keratitis: report of four cases. *Cornea* 1997;**16**:424-9.
- 5 Rosenwasser GOD, Hollard S, Pflugfelder SC, *et al*. Topical anaesthetic abuse. *Ophthalmology* 1990;**97**:967-72.
- 6 Wilson FM. Toxic and allergic reactions to topical ophthalmic medications. In: Arffa RC, ed. *Grayson's diseases of the cornea*. 3rd ed. St Louis: Mosby Year Book, 1991:638-40.
- 7 Peyman GA, Rahimy MH, Fernandes ML. Effects of morphine on the corneal sensitivity and epithelial wound healing: implications for topical ophthalmic analgesia. *Br J Ophthalmol* 1994;**78**:138-41.

### Ataxia and vision loss: flow cytometric diagnosis of primary central nervous system lymphoma

Approximately 20% of patients with primary central nervous system lymphoma will have eye involvement, which often precedes diagnosis by a number of months.<sup>1-4</sup> The diagnosis of intraocular and/or CNS lymphoma depends on histological evidence in tissue obtained from a CNS biopsy or cytological demonstration of malignant cells in the vitreous or cerebrospinal fluid (CSF).<sup>4</sup>

Cytological differentiation of reactive lymphoid cells from well differentiated lymphoma using morphological characteristics depends on observer skill and the preservation of adequate numbers of cells.<sup>5</sup> Immunocytochemical staining of cell surface antigens assists in this differentiation and can detect cell population monoclonality, a common feature of large B cell lymphomas.<sup>5</sup> Cytofluorography or flow cytometry is a semi-automated method of immunocytochemistry which has some advantages over slide based immunocytochemistry including objective and quantitative data on cell surface markers.<sup>6,7</sup>

We present a patient with ataxia and vision loss who was diagnosed with primary CNS lymphoma using cytofluorographic analysis of a vitreous biopsy specimen.

#### Case report

A 53 year old woman was diagnosed with bilateral panuveitis. Best corrected visual acuity (BCVA) was 20/30 right eye and 24/40 left eye. Bilateral mild anterior uveitis and vitritis was present. Diagnostic tests for uveitis were negative. The patient was treated with topical (1%) and oral prednisolone (35 mg) over 16 weeks resulting in a BCVA of 20/30 right eye and 20/25 left eye, resolution of the anterior uveitis, and marked reduction in the vitreous cells bilaterally.

Three months later, the patient presented to the Beth Israel Deaconess Medical Center emergency room with ataxia and vision loss. She had recurrence of her bilateral panuveitis,

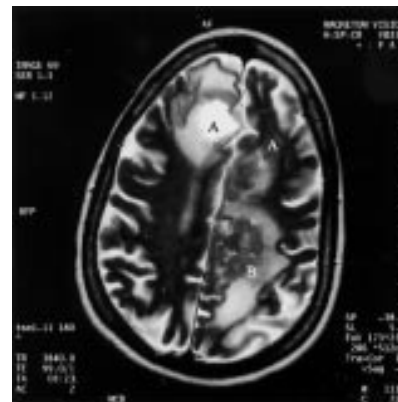
but no chorioretinal lesions were noted on ophthalmoscopy. A magnetic resonance image (MRI) with contrast demonstrated multiple well defined, enhancing lesions of varying size located at the grey-white matter junction consistent with either metastatic neoplasia or lymphoma (Fig 1). Pars plana vitrectomy was performed and an undiluted and diluted vitreous specimen was sent for cytology. The patient recovered a BCVA of 20/16 right eye and 20/40 left eye.

The diluted vitreous was analysed by flow cytometry using three colour gating (light scatter versus CD45) to optimise lymphoid yield. Approximately 58% of the total gated events were composed of abnormal B cells as evidenced by expression of surface antigen CD 19, a pan-B cell marker (Fig 2). The cells showed monoclonal lambda light chain restriction and did not express CD20, CD5, CD10, or CD23 surface antigens (Fig 2). These cytofluorographic findings combined with cytological features of large cell size, moderately abundant amphophilic cytoplasm, and large irregular nuclei with coarse, clumped chromatin and conspicuous nucleoli seen in the undiluted vitreous were consistent with a high grade B cell non-Hodgkin's lymphoma.

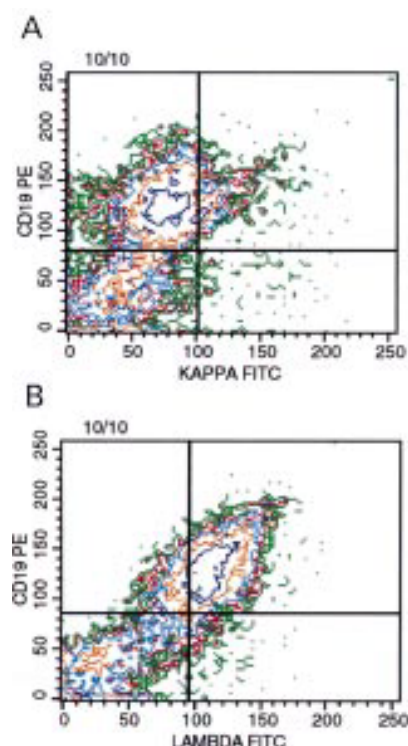
The patient declined chemotherapy and underwent whole brain external beam radiotherapy consisting of a total of 30 Gy administered over 4 weeks and adjunctive intravenous dexamethasone, 1.5 mg twice daily tapered off over 3 weeks. Treatment resulted in a reduction in the size of the cerebral lesions on follow up MRI.

#### Comment

This case highlights typical features of intraocular lymphoma including uveitis of unknown aetiology presenting before evidence of CNS-NHL, bilateral involvement, and an initial response to steroids.<sup>1-4</sup> Decisions regarding the method of diagnosis weigh the lower morbidity and mortality of vitrectomy and lumbar puncture compared to CNS biopsy, against a lower diagnostic yield using cytology.<sup>4-6</sup> Flow cytometry is a semi-automated method of immunocytochemistry that can rapidly identify abnormal B and T lymphocyte subsets. Other benefits include easier cell preparation and multiparameter analyses of specimens.<sup>7</sup> Earlier shortcomings including blood contamination, errors introduced by non-viable cells, difficulty in identifying monoclonality, and slow, single cell suspension analysis, have been overcome.



**Figure 1** Photograph of MRI with contrast demonstrating multiple well defined, enhancing lesions of varying size located at the grey-white matter junction region involving both frontal lobes (A), and the left parietal lobe (B).



**Figure 2** Multivariable, three colour flow cytometric histogram of vitreous lymphocytes showing a cluster of cells (upper right quadrant, 20% of the lymphocyte gate) coexpressing CD 19 and kappa light chain (A). However 58% of the B lymphocytes express surface lambda light chains (B). The pattern of dot plots indicates the presence of a monoclonal, lambda light chain restricted B cell population.

However, correlation of flow cytometry analysis with morphological examination of the tissue section or cytology preparation is still required.<sup>7</sup> Although two early reports did not find flow cytometry helpful in diagnosing intraocular lymphoma,<sup>8,9</sup> three recent cytofluorography studies detected malignancy in 100% of 13 cases<sup>3, 10</sup> and 70% of 10 cases<sup>4</sup> usually with one vitrectomy.<sup>3, 6, 10</sup>

While primary CNS-NHL is initially extremely sensitive to radiotherapy or corticosteroids, tumours will recur in 90% of patients within 1 year.<sup>4</sup> Combined treatment with radiotherapy, corticosteroid and chemotherapy may double median survival time, but the 5 year survival rate is only 4% to 30%.<sup>4</sup> In the minority of patients with this rare disease who have eye involvement, early vitrectomy using cytology and flow cytometry can provide a prompt diagnosis.

#### Acknowledgments

Dr Arroyo is a recipient of an NIH K-23 physician training award.

None of the authors has any proprietary interest in any of the products in this paper.

#### Mark T Cahill

Beetham Eye Institute, Joslin Diabetes Center, One Joslin Place, Harvard Medical School, Boston MA, USA and Division of Ophthalmology, Beth Israel Deaconess Medical Center, Division of Ophthalmology, Brigham and Women's Hospital, and the Department of Ophthalmology, Massachusetts Eye and Ear Infirmary, Harvard Medical School, Boston MA, USA

#### Mirela Stancu

Department of Hematology, Beth Israel Deaconess Medical Center, Harvard Medical School, Brookline Avenue, Boston MA, USA

#### Jorge G Arroyo

Division of Ophthalmology, Beth Israel Deaconess Medical Center, Division of Ophthalmology, Brigham and Women's Hospital, and the Department of Ophthalmology, Massachusetts Eye and Ear Infirmary, Harvard Medical School, Boston MA, USA

Correspondence to: Jorge G Arroyo, MD, Department of Ophthalmology, Retina Service, 12th Floor, Massachusetts Eye and Ear Infirmary, 243 Charles Street, Boston, MA 02114, USA; [jarroyo@caregroup.harvard.edu](mailto:jarroyo@caregroup.harvard.edu)  
Accepted for publication 18 July 2001

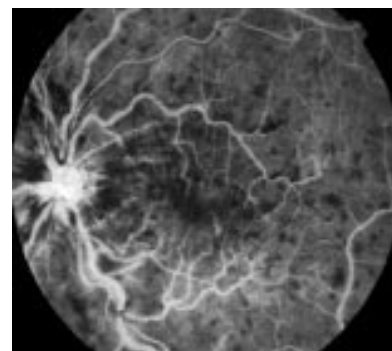
#### References

- Whitcup SM, de Smet MD, Rubin BI, *et al*. Intraocular lymphoma. Clinical and histopathologic diagnosis. *Ophthalmology* 1993;**100**:1399-406.
- Verbraeken HE, Hanssens M, Priem H, *et al*. Ocular non-Hodgkin's lymphoma: a clinical study of nine cases. *Br J Ophthalmol* 1997;**81**:31-6.
- Akpek EK, Ahmed I, Hochberg FH, *et al*. Intraocular-central nervous system lymphoma. Clinical features, diagnosis and outcomes. *Ophthalmology* 1999;**106**:1805-10.
- Blay JY, Ongolo-Zogo P, Sebban C, *et al*. Primary cerebral lymphomas: unsolved issues regarding first-line treatment, follow-up, late neurological toxicity and treatment of relapses. The FNCLCC. French Federation Nationale des Centres de Lutte contre le Cancer. *Ann Oncol* 2000;**11**(Suppl 11):39-44.
- Davis JL, Solomon D, Nussenblatt RB, *et al*. Immunocytochemical staining of vitreous cells. Indications, techniques, and results. *Ophthalmology* 1992;**99**:250-6.
- Davis JL, Viciano AL, Ruiz P. Diagnosis of intraocular lymphoma by flow cytometry. *Am J Ophthalmol* 1997;**124**:362-72.
- McCoy Jr JP. Basic principles of clinical flow cytometry. In: Keren DF, Hanson CA, Hurlbise PE, eds. *Flow cytometry and clinical diagnosis*. 1st ed. Chicago: ASCP Press, 1994:26-55.
- Ljung BM, Char DM, Miller TR, *et al*. Intraocular lymphoma: cytologic diagnosis and the role immunologic markers. *Acta Cytol* 1987;**2**:840-7.
- Char DH, Ljung BM, Deschenes J, *et al*. Intraocular lymphoma: immunological and cytological analysis. *Br J Ophthalmol* 1988;**72**:905-11.
- Wilson DJ, Brazier R, Rosenbaum JT. Intraocular lymphoma. Immunopathologic analysis of vitreous biopsy specimens. *Arch Ophthalmol* 1992;**110**:1455-8.

#### Intravitreal triamcinolone acetonide for macular oedema due to central retinal vein occlusion

No proved treatment exists for macular oedema secondary to central retinal vein occlusion (CRVO) despite the potential for significant visual loss in affected eyes. We report a patient with bilateral non-ischaemic CRVOs and macular oedema treated with intravitreal triamcinolone acetonide.

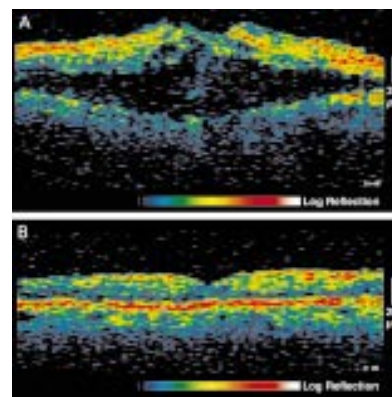
An 80 year old woman presented with a 2 week history of acute visual loss in her left eye (LE). She had a 9 month history of poor vision in her right eye (RE). On examination, visual acuity was counting fingers RE and 20/400 LE. Intraocular pressures were 12 and 14 mm Hg, respectively. Anterior segment examination showed bilateral pseudophakia with no evidence of neovascularisation. Dilated fundus



**Figure 1** Mid-phase fluorescein angiography of the left eye shows a central retinal vein occlusion with diffuse leakage and blockage secondary to retinal haemorrhage.

examination revealed bilateral CRVOs with macular oedema. Collateral disc vessels were present in the RE. Fluorescein angiography showed diffuse leakage and blockage from intraretinal haemorrhages in both eyes with no areas of non-perfusion (Fig 1). OCT measured a central macular thickness of 735  $\mu$ m in the RE and 589  $\mu$ m in the LE (Fig 2A). Owing to the poor visual outcome in the RE with observation, the patient was offered an intravitreal injection of triamcinolone acetonide (Apothecon, Princeton, NJ, USA) in the LE. Topical 0.5% amethocaine (tetracaine, Novartis, Atlanta, GA, USA) was used for anaesthesia. Two drops were applied three times, 5 minutes apart. Betadine (povidone-iodine) 5% (Alcon, Ft Worth, TX, USA) was then applied to the conjunctiva. An injection of 4 mg (0.1 ml) triamcinolone was performed using a sharp 27 gauge, half inch needle through the inferior pars plana, 3.5 mm from the corneal limbus appropriate for her pseudophakic status.

Six weeks post-injection, visual acuity was 20/80 in the LE. Central macular thickness measured 160  $\mu$ m with a normal foveal contour (Fig 2B). Visual acuity was 20/30 after 3 months. Central macular thickness remained normal by OCT. Six months post-injection, visual acuity declined to 20/400 because of recurrence of macular oedema.



**Figure 2** (A) Optical coherence tomography of the left eye before first intravitreal triamcinolone acetonide injection demonstrating marked macular oedema with intraretinal cysts. (B) Resolution of macular oedema with restoration of normal foveal contour 6 weeks after intravitreal triamcinolone injection.

measuring 834  $\mu\text{m}$  by OCT. A second injection was performed in the LE. One month later, visual acuity was 20/50; central macular thickness measured 158  $\mu\text{m}$  with restoration of a normal foveal contour.

Given the significant response in the LE, an intravitreal triamcinolone injection was performed in the RE. The macular oedema responded promptly (735–195  $\mu\text{m}$  central macular thickness) with restoration of normal macular anatomy, but no visual benefit was appreciated. There was no significant elevation in IOP in either eye during the follow up period.

Macular oedema due to CRVO generally carries a poor visual prognosis. After 3 years, 58% of eyes will have vision worse than 20/100.<sup>1</sup> Less than 20% of eyes will gain two or more lines of visual acuity. In addition, there are no proved treatment options. The Central Vein Occlusion Study demonstrated that grid photocoagulation had no significant impact on the final visual acuity of eyes with CRVO and macular oedema.<sup>1</sup>

In this case, a patient with an acute CRVO and macular oedema had significant improvement in visual acuity and complete resolution of macular oedema after each of two intravitreal injections of triamcinolone. A chronic CRVO with macular oedema in the other eye showed an anatomical response without visual improvement. Thus, early treatment may be necessary for visual improvement, before longstanding macular oedema results in irreversible photoreceptor damage. The mechanism by which this modality induces resolution of macular oedema in eyes with CRVO is unclear, though stabilisation of the blood-retinal barrier may play a significant part.<sup>2</sup>

The safety and efficacy of intravitreal triamcinolone has been well studied in animal models.<sup>2,3</sup> It has also been used in humans for the treatment of choroidal neovascularisation and cystoid macular oedema due to uveitis.<sup>4,5</sup> IOP elevation may occur in up to 25% of eyes after corticosteroid injection.<sup>6</sup> Other potential risks of the procedure include cataract development, retinal detachment, and endophthalmitis.

This case suggests that the use of intravitreal triamcinolone acetate for the treatment of macular oedema due to CRVO warrants further study.

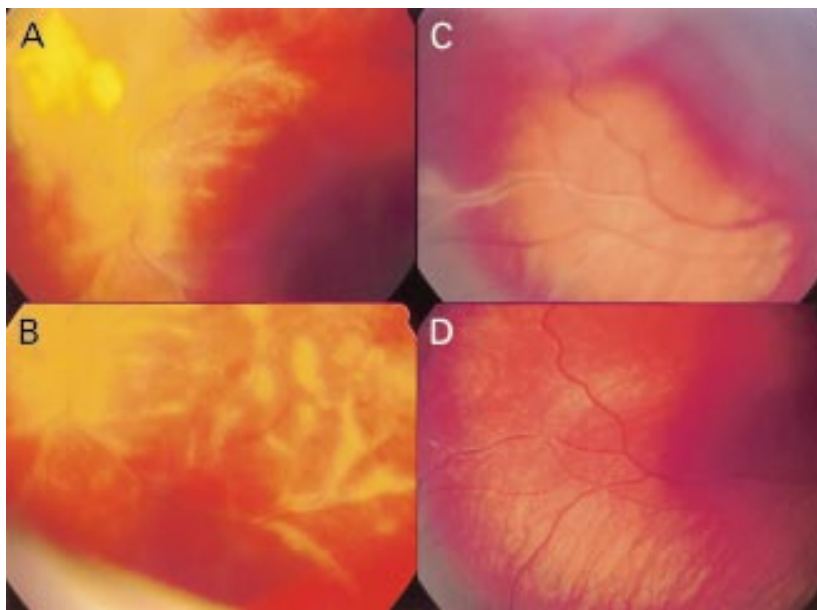
**Paul B Greenberg, Adam Martidis, Adam H Rogers, Jay S Duker, Elias Reichel**

New England Eye Center, Tufts University School of Medicine, Boston, MA, USA

Correspondence to: Elias Reichel, MD, New England Eye Center, Tufts University School of Medicine, 750 Washington Street, Box 450, Boston, MA 02111, USA; [ereichel@lifespan.org](mailto:ereichel@lifespan.org)  
Accepted for publication 23 July 2001

## References

- 1 **The Central Vein Occlusion Study Group.** Evaluation of grid pattern photocoagulation for macular edema in central vein occlusion. *Ophthalmology* 1995;**102**:1425–33.
- 2 **Wilson CA, Berkowitz BA, Sato Y, et al.** Treatment with intravitreal steroid reduces blood-retinal barrier breakdown due to retinal photocoagulation. *Arch Ophthalmol* 1992;**110**:1155–9.
- 3 **Tano Y, Chandler BS, Machemer R.** Treatment of intraocular proliferation with intravitreal injection of triamcinolone acetate. *Am J Ophthalmol* 1980;**90**:810–16.
- 4 **Danis RP, Ciulla TA, Pratt LM, et al.** Intravitreal triamcinolone acetate in exudative age-related macular degeneration. *Retina* 2000;**20**:244–50.



**Figure 1** (A, B) Fundus photographs of the left eye showing active CMV retinitis, with a necrotic area over the disc and several haemorrhages and sheathing on the superotemporal and inferotemporal arcade. (C) Fundus photograph of the right eye showing active CMV retinitis with sheathing and exudation on the inferotemporal arcade of the right eye. (D) Same area of the fundus of the right eye showing improvement of the picture after 1 week of treatment.

5 **Antcliff RJ, Spalton DJ, Stanford MR, et al.** Intravitreal triamcinolone for uveitic cystoid macular edema: an optical coherence tomography study. *Ophthalmology* 2001;**108**:765–72.

## Should active CMV retinitis in non-immunocompromised newborn babies be treated?

Cytomegalovirus (CMV) retinitis in children with congenital CMV infection is known to differ from that described in immunocompromised subjects, because it is present at birth and does not progress postnatally if the child is otherwise immunocompetent. Regarding treatment, there are limited data in infants with symptomatic congenital CMV infection and it is not known whether antiviral drugs alter the prognosis. We describe a case of congenital CMV retinitis that progressed postnatally and our treatment regimen.

### Case report

A 9 day old baby was referred to the eye clinic after having been diagnosed with congenital symptomatic CMV infection.

During pregnancy, at 34 weeks, poor growth and ventriculomegaly were noted and a scan at 35 weeks showed bilateral cysts in the occipital horn of the lateral ventricles. He was born at 40 weeks by emergency caesarean section. The mother was a healthy 18 year old woman. His birth weight was 2.1 kg and his head circumference 31.5 cm, both of which were below the 0.4th centile. Brain magnetic resonance imaging confirmed the presence of bilateral occipital cysts and periventricular calcification. Serology and urine tests showed congenital CMV infection. The child had a normal immune system for his age.

Eye examination revealed sheathing of the retinal vessels and haemorrhages, which involved the arcades and were more marked in the left eye (Fig 1A, B, C). Exudates were

present in both eyes superior to the disc (Fig 1A). The following day the vasculitis in the left eye had progressed and was involving the macula. Treatment with ganciclovir 5 mg/kg/day intravenously was started in view of the active retinitis. One week after treatment the haemorrhages and exudation in both eyes were resolving and 2 weeks after treatment complete resolution of the ocular infection occurred (Fig 1D). The macula of the right eye remained unaffected, but scarring occurred in the periphery of both eyes and the left macula. Ganciclovir was stopped 3 weeks after initiation.

Electrodiagnostic tests were performed at 4 months and suggested moderate vision in the right eye and poor vision in the left.

On last examination at 5 months the baby would not fixate with the left eye and had developed a divergent squint while he was fixing on bright objects with his right eye. Fundus examination revealed a pale optic disc on the left, vascular attenuation in the left eye, pigmented scars superiorly in both eyes, and right macular gliosis. There was no gross refractive error.

His growth followed a centile just below the 0.4th with delayed development and microcephaly.

### Comment

Cytomegalovirus is the most common cause of congenital and perinatal viral infections throughout the world.<sup>1</sup> The incidence of congenital infection ranges from 0.2–2.4% of all live births, with higher rates in populations with a lower standard of living. The fetus may become infected as a consequence of primary and recurrent maternal infection. The risk of fetal infection is greatest with maternal primary CMV infection (40%) and much less likely with recurrent infection (1%). Only 5% of all congenitally infected children have severe disease, another 5% have mild involvement, and 90% are born with subclinical but chronic CMV infection.<sup>2</sup> The most characteristic signs include intrauterine growth retardation, prematurity, hepatosplenomegaly and

jaundice, thrombocytopenia and purpura, and microcephaly and intracranial calcifications. Neurological problems include mild increase in cerebrospinal fluid protein, sensorineural hearing loss, and chorioretinitis. Among the most severely affected infants, mortality may be as high as 30% and death may occur in the neonatal period or months later.<sup>2</sup> The likelihood that infants who survive symptomatic congenital CMV infection will have normal hearing and intellectual development is small.<sup>3</sup> In infants with subclinical infection, the outlook is much better.<sup>4</sup>

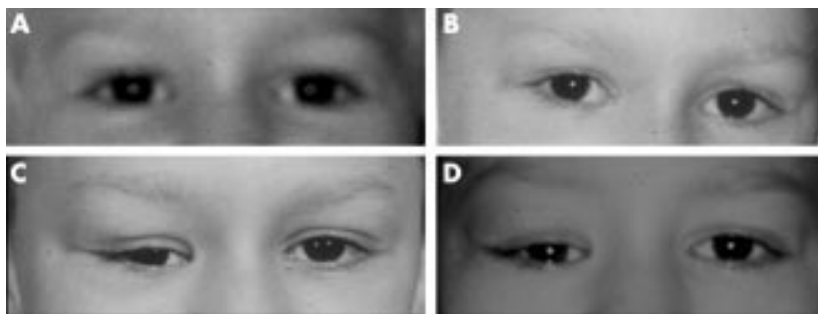
Active CMV infection is best demonstrated by virus isolation from urine, saliva, bronchoalveolar washings, breast milk, cervical secretions, and tissues obtained with biopsy. The definitive method for diagnosis of congenital CMV infection is isolation of the virus in urine or saliva. This must be done shortly after birth. Intrauterine, perinatal, or early postnatal acquisition of CMV characteristically causes a more chronic infection with regard to virus excretion than does infection acquired later in life. Virus is shed into the urine for approximately 5 years and frequently into the nasopharynx for 2–4 years. The quantity of virus excreted in these sites is much greater than that found in infected older children and adults. Immaturity of the immune response of the fetus and of young infants is believed to be the major determinant of virulence of the congenital and early postnatally acquired infections. Still, the extent and exact nature of the immune defect in congenitally infected infants have yet to be resolved.<sup>5</sup> CMV can also be diagnosed in utero by isolation of the virus in the amniotic fluid.

CMV retinitis is known to occur in immunosuppressed adults and its incidence has increased in the last years as a result of acquired immunodeficiency syndrome (AIDS).<sup>6</sup> However, the occurrence of CMV retinitis in immunocompromised children is unusual and only few cases have been reported in the literature.<sup>7</sup>

Congenital CMV infection may also be associated with retinitis. The precise incidence of CMV retinitis has been reported to be up to 25% of infants with severely symptomatic congenital CMV and in approximately 1% of infants who are asymptomatic and congenitally infected.<sup>8,9</sup> The retinitis in congenitally infected children differs from that described in immunocompromised subjects because it usually does not progress after birth if the child is otherwise immunocompetent.<sup>7,10</sup>

Delayed onset and reactivation of chorioretinitis in children with congenital CMV infection has been described in a series of seven patients. Progression occurred later in life, the age ranging from 3 to 11 years. Only one child had a positive urine culture for CMV and no treatment was administered.<sup>11</sup>

The baby we treated presented to us at 9 days of age with active progressive bilateral CMV retinitis and congenital symptomatic CMV infection. He was not immunosuppressed. Diagnosis was made by the clinical picture and blood and urine cultures, from which the virus was isolated. The optimal treatment for CMV retinitis in children has not yet been established. There are limited data regarding ganciclovir treatment in infants with symptomatic congenital CMV infection and it is not known whether antiviral drugs alter the prognosis. We prescribed the currently recommended therapeutic regimens of ganciclovir which are identical to those used in adults, with drug doses adjusted for body weight.<sup>12</sup> In our case dramatic improvement of the retinitis occurred within



**Figure 1** Photographs taken at (A) 6 years, (B) 8 years, (C) 9 years, and (D) 11 years, showing inferonasal displacement of the right globe, right ptosis, and superolateral orbital swelling present for at least 2 years before presentation.

1 week of treatment and ganciclovir was stopped after 3 weeks, as the child was otherwise immunocompetent. We cannot be sure to what extent the treatment contributed to the resolution of the retinitis as the natural history of the disease is not known. However, despite the rapid resolution of the retinitis, the visual outcome was not ideal. Based on current evidence it would seem appropriate to recommend early treatment of active retinitis.

It is important to be aware that active and progressive CMV retinitis can occur in children with symptomatic congenital CMV infection who are not otherwise immunocompromised. The associated retinal vasculitis can result in significant visual impairment. Urgent assessment and prompt initiation of treatment is recommended as it is likely to improve the visual prognosis by arresting the necrotising retinitis from spreading to the posterior pole, or the contralateral eye.

Reporting such rare cases should raise awareness of this serious condition with potentially devastating ocular sequelae. It may in time clarify the spectrum of the disease and help in establishing the best way to manage its complications.

**F Barampouti, M Rajan, W Aclimandos**

Department of Ophthalmology, King's College Hospital, Denmark Hill, London SE5 9RS, UK

Correspondence to: W Aclimandos; fayebart@hotmail.com

Accepted for publication 15 August 2001

## References

- 1 **Weller TH.** The cytomegaloviruses: ubiquitous agents with protean clinical manifestations. Second of two parts. *N Engl J Med* 1971; **285**:203–14, 267–74.
- 2 **Pass RF, Stagno S, Myers GJ, et al.** Outcome of symptomatic congenital CMV infection: results of long term longitudinal follow-up. *Pediatrics* 1980; **66**:758–62.
- 3 **Weller TH, Hanshaw JB.** Virological and clinical observations on cytomegalic inclusion disease. *N Engl J Med* 1964; **266**:1233–44.
- 4 **Stagno S.** Cytomegalovirus. In: Nelson, Alford CA, eds. *Textbook of paediatrics*. 16th ed.
- 5 **Stagno S, Pass RF, Britt WJ.** Congenital and perinatal CMV infections. *Rev Infect Dis* 1990; **12**(S7):45–53.
- 6 **Studies of ocular complications of AIDS research group,** in collaboration with the AIDS clinical trials group. Mortality in patients with the acquired immunodeficiency syndrome treated with either foscarnet or ganciclovir for CMV retinitis. *N Engl J Med* 1992; **326**: 213–20.
- 7 **Baumal C, Levin A, Kavalec C, et al.** Screening for CMV retinitis in children. *Arch Paediatr Adolesc Med* 1996; **150**.
- 8 **Stagno S, Pass RF, Dworsky ME, et al.** Congenital and perinatal CMV infections. *Semin Perinatol* 1983; **7**:31–42.
- 9 **Istas AS, Demmler GJ, Dobbins JG, et al.** The national congenital CMV disease registry, Collaborating group. Surveillance for CMV disease: a report from the National Congenital CMV disease registry. *Clin Infect Dis* 1995; **20**:665–70.
- 10 **Stagno S, Reynolds D, Amos C, et al.** Auditory and visual defects resulting from symptomatic and subclinical congenital CMV and Toxoplasma infections. *Paediatrics* 1977; **59**:No 5.
- 11 **Boppna S, Amos C, Britt W, et al.** Late onset reactivation of chorioretinitis in children with congenital CMV infection. *Pediatr Infect Dis J* 1994; **13**:1139–42.
- 12 **Baumal C, Levin A, Read S.** CMV retinitis in immunosuppressed children. *Am J Ophthalmol* 1999; **127**:550–8.

## Pleomorphic adenoma of the lacrimal gland in a 10 year old girl

Pleomorphic adenoma is the most common epithelial tumour of the lacrimal gland, representing 12% of lacrimal fossa lesions.<sup>1</sup> It typically presents in middle age and is rare in children under the age of 16 years, with only a few previously reported cases.<sup>2–6</sup> We present an additional case in a 10 year old girl with photographic documentation of longstanding orbital asymmetry.

## Case report

A 10 year old girl was referred with a 3 month history of painless right eyelid swelling, presumed to be allergic in nature. The unaided right visual acuity was 6/24, improving to 6/9 with correction of astigmatism (+1.00/–2.25 × 020) and the unaided left visual acuity was 6/5. Pupil responses and colour perception were normal. Ocular motility was normal but there was 3 mm of right proptosis, with inferonasal globe displacement, and a non-tender lacrimal gland mass. Periorbital sensation was intact and ocular examination was otherwise unremarkable. Family photographs demonstrated an asymmetry in appearance of the two eyes for at least 2 years previously (Fig 1).

Computed tomograph (CT) scan demonstrated a well defined 1.8 × 1.8 cm mass arising from the right lacrimal gland with mild smooth bony erosion of the lacrimal fossa, consistent with a pleomorphic adenoma. Lateral orbitotomy was performed under general anaesthetic with intact excision of the orbital lobe of the right lacrimal gland. Histology confirmed benign pleomorphic adenoma with intact pseudocapsule.

## Comment

Pleomorphic adenoma of the lacrimal gland is rare in children with only few previously

reported cases. Nevertheless, even in the paediatric age group, it is important to consider the diagnosis in the presence of a painless, gradually progressive lacrimal gland mass. A published system for evaluation of lacrimal gland masses scores the duration of symptoms, presence of persistent pain or sensory loss, as well as radiological features, in order to determine the appropriate surgical management.<sup>7</sup> The case described scored the maximum 8 points, where a score higher than 3 suggests pleomorphic adenoma requiring excision without previous incisional biopsy. Complete excision with an intact pseudocapsule has prognostic importance in avoiding later pervasive recurrence and malignant transformation.

**Carolyn A Cates, Ruth M Manners**

Southampton Eye Unit,  
Southampton SO16 6YD, UK

**Geoffrey E Rose**

Moorfields Eye Hospital, London EC1V 2PD, UK

Correspondence to: Mrs C A Cates;  
[ccates@doctors.org.uk](mailto:ccates@doctors.org.uk)

Accepted for publication 15 August 2001

## References

- 1 **Shields CL**, Shields JA, Eagle RC, *et al*. Clinicopathologic review of 142 cases of lacrimal gland lesions. *Ophthalmology* 1989;**96**:431–5.
- 2 **Sanders TE**. Mixed tumor of the lacrimal gland. *Arch Ophthalmol* 1939;**21**:239–60.
- 3 **Font RL**, Gamel JW. Epithelial tumors of the lacrimal gland: an analysis of 265 cases. In: Jakobiec FA, ed. *Ocular and adnexal tumors*. Birmingham: Aesculapian, 1978:787–805.
- 4 **Tsunoda S**, Yabuno T, Sakaki T, *et al*. Pleomorphic adenoma of the lacrimal gland manifesting as exophthalmos in adolescence. *Neurol Med Chir* 1994;**34**:814–16.
- 5 **Faktorovich EG**, Crawford JB, Char DH, *et al*. Benign mixed tumor (pleomorphic adenoma) of the lacrimal gland in a 6-year-old boy. *Am J Ophthalmol* 1996;**122**:446–7.
- 6 **Mercado GJV**, Gündüz K, Shields CL, *et al*. Pleomorphic adenoma of the lacrimal gland in a teenager. *Arch Ophthalmol* 1998;**116**:962–3.
- 7 **Rose GE**, Wright JE. Pleomorphic adenoma of the lacrimal gland. *Br J Ophthalmol* 1992;**76**:395–400.

## Surgical performance for specialties undertaking temporal artery biopsies: who should perform them?

The management of temporal arteritis carries a large burden on resources and commits the patient to long term anti-inflammatory medication with its concomitant side effects. We undertook a retrospective survey of the recent surgical practice at King's College Hospital, London. This was to compare performance for the specialties involved in biopsying temporal arteries. We are unaware of any previous publication specifically addressing surgical efficiency. Biopsies of long specimens could help reduce morbidity and mortality associated with false negative results and avoid further unnecessary and expensive investigation.<sup>1–3</sup> Information was obtained by cross referencing clinical, surgical, and histopathological records for all the temporal artery biopsies done during a 2 year period from March 1998 to March 2000. Arterial specimen length was taken as the performance indicator. Analysis of the biopsy rates for years 1 and 2 was done and then individual lengths were compared.

**Table 1** Annual biopsy rates per department

	Year 1	Year 2	Total	Percentage
Ophthalmology	3	11	14	34.15
Neurosurgery	5	9	14	34.15
Maxillofacial	5	1	6	14.6
General surgery	1	4	5	12.2
Vascular surgery	0	2	2	4.9
Total	14	27	41	

## Results

Thirty nine patients underwent 41 biopsies, yielding an average of 19.5 per year or 1.6 per month. Of these, six were positive. This implies a 14.6% positive biopsy rate. Of the two re-biopsies, one revealed a repeat negative result and the other a positive result. The five departments performing surgery were: ophthalmology—14 biopsies (34%) from 13 patients; neurosurgery—14 biopsies (34%); maxillofacial surgery (MFS)—six biopsies (14.6%) from five patients; general surgery (GS)—five biopsies (12.2%); and vascular surgery (VS)—two biopsies (4.9%). For analysis MFS, GS, and VS are grouped together as they performed relatively few biopsies. Analysis of biopsy rates is depicted in Table 1. Overall, 14 biopsies were done in year 1, with an average length of 13.8 mm, and 27 in year 2, with an average of 13.1 mm. Regarding specimen lengths, ophthalmology averaged 15 mm in year 1 and 16.4 mm in year 2. Total average was 16.1 mm. This ranged from 5 mm to 30 mm. The 5 mm specimen was deemed too short and re-biopsy yielded a specimen of 23 mm. There were no failed biopsies. Neurosurgeons averaged 10.8 mm in year 1 and 9 mm in year 2, with a total average of 9.6 mm. Specimens ranged from no artery to 20 mm. No re-biopsy of the unsuccessful sample took place. The last group averaged 15.7 mm in year 1 with one specimen containing no artery and 13.1 mm in year 2, also with one unsuccessful procedure. Total average length was 14.3 mm with a range of no artery to 28 mm. These data are summarised in Table 2. The average across all 41 specimens was 13.3 mm. The average length of the six positive results was 16 mm with a range of 10 to 28 mm. The average length of the 35 negative results was 12.9 mm.

## Comment

It would appear that our ophthalmology unit is best suited to perform the majority of biopsies. They already perform one third of all biopsies and achieve the longest average length. They also re-biopsy when specimen length is inappropriately short. Our hospital supplies a relatively large neuroscience service, thus the finding that they perform 34% of biopsies may be a regional bias. The third

group is not regularly performing biopsies. The biopsy rates done by ophthalmology and the neurosciences were increased in year 2. This may represent a trend that they are performing an increasing proportion of biopsies. The average length of 13.3 mm is disappointing considering the well known “skip lesion” phenomenon.<sup>4,5</sup> One obviously would like a length as long as possible but realistically an average length of 20 mm should be sufficient. Miller also recommends 20 mm.<sup>6</sup> In summary, we propose that the ophthalmology service should perform a larger proportion of biopsies. This would increase our diagnostic efficiency and reduce the impact that temporal arteritis has on our resources.

**Gavin D Galloway**

Ophthalmology Department, West Suffolk Hospital,  
Bury St Edmunds, IP33 3QZ, UK

**Bernhard Klebe**

Department of Internal Medicine, Kent and  
Canterbury Hospital, Canterbury CT1 3NG, UK

**Paul Riordan-Eva**

Department of Ophthalmology, King's College  
Hospital, London SE5 9RS, UK

Correspondence to: Mr Gavin Galloway;  
[gavgal@doctors.org.uk](mailto:gavgal@doctors.org.uk)

Accepted for publication 15 August 2001

## References

- 1 **Mason JC**, Walport MJ. Giant cell arteritis. Probably under diagnosed and over treated. *BMJ* 1992;**305**:68–9.
- 2 **Hedges TR 3d**, Gieger GL, Albert DM. The clinical value of negative temporal artery biopsy specimens. *Arch Ophthalmol* 1983;**101**:1251–4.
- 3 **Swannell AJ**. Polymyalgia rheumatica and temporal arteritis: diagnosis and management. *BMJ* 1997;**314**:1329–32.
- 4 **Poller DN**, van Wyk Q, Jeffrey MJ. The importance of skip lesions in temporal arteritis. *J Clin Pathol* 2000;**53**:137–9.
- 5 **Albert DM**, Ruchman MC, Kellner JL. Skip areas in temporal arteritis. *Arch Ophthalmol* 1976;**94**:2072–7.
- 6 **Miller N**. *Walsh and Hoyt's clinical neuro-ophthalmology*. 5th ed. Vol 3. Baltimore: Williams and Wilkins, 1998.

**Table 2** Performance indicator—average arterial length (mm)

	Year 1	Year 2	Total	Range
Ophthalmology	15	16.4	16.1	5–30
Neurosurgery	10.8	9	9.6	no artery–20
Maxillofacial	15.8	no artery	13.2	no artery–28
General surgery	15	11.8	12.4	8–17
Vascular surgery	none	22.5	22.5	22–23
Total	13.8	13.1	13.3	no artery–30

## BOOK REVIEW



**Essential Medical Ophthalmology. A problem oriented approach.** By John Ferris. £49.99; Pp 304. Oxford: Butterworth-Heinemann, 2001. ISBN 0-7506-4937-2.

For quite some time there has been a plethora of problem orientated approach learning texts available in medicine. They are liked enormously because of their practical approach, often excellent illustrations, readability, and because they can be a great text for quick reference and, indispensably, revision for membership examinations. Ophthalmology has also enjoyed similar textbook approaches except that they have been more didactic and nearly always skewed to surgical conditions. John Ferris is to be congratulated in providing a first class book, which I am sure, is eagerly awaited.

I can imagine the book could become essential for the ophthalmology exams as well as being very useful for the MRCP short cases. The book bravely, and in the main successfully, covers the broad spectrum of medical ophthalmology, including neurology. What is exciting is that he brings in systemic features—for example, the hands and face, into ophthalmic learning, further emphasising that ophthalmologists need to look outside the eye. I particularly like the chapters on laboratory tests and radiology, essential for problem oriented approach to learning.

In general, the illustrations are good and the text apt for this stage in learning, although by no means complete, as I am sure each subspecialist may argue unnecessarily. Nevertheless, for exam purposes, I find that this book fulfils its requirements and I would recommend it to all trainees for their exams.

**Andrew D Dick**  
University of Bristol

## NOTICES

### Glaucoma

The latest issue of Community Eye Health (No 39) discusses the glaucomas, with an editorial by Professor Gordon J Johnson, director of the International Centre for Eye Health. For further information please contact: Journal of Community Eye Health, International Centre for Eye Health, Institute of Ophthalmology, 11-43 Bath Street, London EC1V 9EL, UK (tel: +44 (0)20 7608 6910; fax: +44 (0)20 7250 3207; email: [eyeresource@ucl.ac.uk](mailto:eyeresource@ucl.ac.uk); website:

[www.jceh.co.uk](http://www.jceh.co.uk)). Annual subscription (4 issues) UKE25/US\$40. Free to workers in developing countries.

### International Centre for Eye Health

The International Centre for Eye Health has published a new edition of the *Standard List of Medicines, Equipment, Instruments and Optical Supplies* (2001) for eye care services in developing countries. It is compiled by the Task Force of the International Agency for the Prevention of Blindness. Further details: Sue Stevens, International Centre for Eye Health, 11-43 Bath Street, London EC1V 9EL, UK (tel: +44 (0)20 7608 6910; email: [eyeresource@ucl.ac.uk](mailto:eyeresource@ucl.ac.uk)).

### Second Sight

Second Sight, a UK based charity whose aims are to eliminate the backlog of cataract blind in India by the year 2020 and to establish strong links between Indian and British ophthalmologists, is regularly sending volunteer surgeons to India. Details can be found at the charity website ([www.secondsight.org.uk](http://www.secondsight.org.uk)) or by contacting Dr Lucy Mathen ([lucymathen@yahoo.com](mailto:lucymathen@yahoo.com)).

### Specific Eye ConditionS (SPECS)

Specific Eye ConditionS (SPECS) is a not for profit organisation which acts as an umbrella organisation for support groups of any conditions or syndrome with an integral eye disorder. SPECS represents over fifty different organisations related to eye disorders ranging from conditions that are relatively common to very rare syndromes. We also include groups who offer support of a more general nature to visually impaired and blind people. Support groups meet regularly in the Boardroom at Moorfields Eye Hospital to offer support to each other, share experiences and explore new ways of working together. The web site [www.eyeconditions.org.uk](http://www.eyeconditions.org.uk) acts as a portal giving direct access to support groups own sites. The SPECS web page is a valuable resource for professionals and may also be of interest to people with a visual impairment or who are blind. For further details about SPECS contact: Kay Parkinson, SPECS Development Officer (tel: +44 (0)1803 524 238; email: [k@eyeconditions.org.uk](mailto:k@eyeconditions.org.uk); website: [www.eyeconditions.org.uk](http://www.eyeconditions.org.uk)).

### 4th International Conference on the Adjuvant Therapy of Malignant Melanoma

The 4th International Conference on the adjuvant therapy of malignant melanoma will be held at The Royal College of Physicians, London on 15-16 March 2002. Further details: Conference Secretariat, CCI Ltd, 2 Palmerston Court, Palmerston Way, London SW8 4AJ, UK (tel: + 44 (0)20 7720 0600; fax: + 44 (0)20 7720 7177; email: [melanoma@confcomm.co.uk](mailto:melanoma@confcomm.co.uk); website: [www.confcomm.co.uk/Melanoma](http://www.confcomm.co.uk/Melanoma)).

### EUPO 2002 Course Retina

A course on retina will be held on 15-17 March 2002 at Erlangen, Germany, where European professors will teach European residents. Further details: Priv Doz Dr Ulrich Schonherr, Friedrich-Alexander-University of Erlangen-Nuemberg, Department of Ophthalmology, Schwabachanlage 6 (Kopflinikum), D-91054 Erlangen, Germany (tel: +49 9131 853 4379; fax: +49 9131 853 4332; email: [ulrich-schoenherr@augen.imed.uni-erlangen.de](mailto:ulrich-schoenherr@augen.imed.uni-erlangen.de)).

### XXIXth International Congress of Ophthalmology

The XXIXth International Congress of Ophthalmology will be held on 21-25 April 2002 in Sydney, Australia. Further details: Congress Secretariat, C/- ICMS Australia Pty Ltd, GPO Box 2609, Sydney, NSW 2001, Australia (tel: +61 2 9241 1478; fax: +61 2 9251 3552; email: [ophthal@icmsaust.com.au](mailto:ophthal@icmsaust.com.au); website: [www.ophthalmology.aust.com](http://www.ophthalmology.aust.com)).

### 12th Meeting of the European Association for the Study of Diabetic Eye Complications (EASDEC)

The 12th meeting of the EASDEC will be held on 24-26 May 2002 in Udine, Italy. The deadline for abstracts is 15 February 2002. Three travel grants for young members (less than 35 years of age at the time of the meeting) are available. For information on the travel grants, please contact Pr CD Agardh, President of EASDEC, Malmö University Hospital, SE-205 02 Malmö, Sweden (tel +46 40 33 10 16; fax: +46 40 33 73 66; email: [carl-david.agardh@endo.mas.lu.se](mailto:carl-david.agardh@endo.mas.lu.se)). Further details: NORD EST CONGRESSI, Via Aquilea, 21-33100 Udine, Italy (tel: +30 0432 21391; fax: +39 0432 50687; email: [nordest.congressi@ud.nettuno.it](mailto:nordest.congressi@ud.nettuno.it)).

### International Society for Behçet's Disease

The 10th International Congress on Behçet's Disease will be held in Berlin 27-29 June 2002. Further details: Professor Ch Zouboulis (email: [zoubbere@zedat.fu-berlin.de](mailto:zoubbere@zedat.fu-berlin.de)).

### Singapore National Eye Centre 5th International Meeting

The Singapore National Eye Centre 5th International Meeting will be held on 3-5 August 2002 in Singapore. Further details: Ms Amy Lim, Organising Secretariat, Singapore National Eye Centre, 11 Third Hospital Avenue, Singapore 168751 (tel: (65) 322 8374; fax: (65) 227 7290; email: [Amy\\_Lim@snecc.com.sg](mailto:Amy_Lim@snecc.com.sg)).

### BEAVRS Meeting

The next BEAVRS meeting will be held in the Dalmahoy Hotel near Edinburgh on 31 October to 1 November 2002. Further details: Susan Campbell, Medical Secretary, Gartnavel General Hospital (email: [susan.j.campbell.wg@northglasgow.scot.nhs.uk](mailto:susan.j.campbell.wg@northglasgow.scot.nhs.uk)).



## Pleomorphic adenoma of the lacrimal gland in a 10 year old girl

Carolyn A Cates, Ruth M Manners and Geoffrey E Rose

*Br J Ophthalmol* 2002 86: 249-250

doi: 10.1136/bjo.86.2.249

---

Updated information and services can be found at:

<http://bjo.bmj.com/content/86/2/249.full.html>

---

### References

*These include:*

This article cites 6 articles, 1 of which can be accessed free at:

<http://bjo.bmj.com/content/86/2/249.full.html#ref-list-1>

Article cited in:

<http://bjo.bmj.com/content/86/2/249.full.html#related-urls>

### Email alerting service

Receive free email alerts when new articles cite this article. Sign up in the box at the top right corner of the online article.

---

### Notes

---

To request permissions go to:

<http://group.bmj.com/group/rights-licensing/permissions>

To order reprints go to:

<http://journals.bmj.com/cgi/reprintform>

To subscribe to BMJ go to:

<http://group.bmj.com/subscribe/>