

BJO at a glance

Creig Hoyt, Editor

WHAT DO WE DO ABOUT DIABETES?


Despite improvements in the medical management of patients with diabetes, as well as improved surgical and laser techniques to treat diabetic retinopathy, visual loss related to diabetes remains a major healthcare problem. Understanding the mechanism of diabetic retinopathy may be important in order to develop new treatments. Adamis outlines the case for diabetic retinopathy having a prominent inflammatory component. He cautions that much work is yet to be done but makes a strong case for inflammation playing a major part in the vast changes related to diabetes. Anti-inflammatory drug testing in human diabetic retinopathy is already under way.

Klein and Klein detail the case for more careful management of hypertension associated with diabetes: 30% of younger patients with diabetes and 70% of older patients with diabetes suffer from hypertension. The Kleins make the case that better control of hypertension will lessen the impact of diabetic retinopathy. A large randomised controlled clinical trial DIRECT study is under way to examine the efficacy of ACE inhibitors in reducing the incidence of progression of retinopathy with people associated with diabetes mellitus.

See pp 363 and 365

CORNEAL TATTOOING FOR DISFIGURING CORNEAL SCARS

The use of tattooing methods to mask corneal scars has been documented in



See pp 400–403.

the medical literature for nearly 2000 years. With improved microsurgical techniques as well as the development of excellent cosmetic contact lenses the problem of treating unsightly corneal disease has become easier. Nevertheless, Pitz and co-authors make the case that in a small but important group of patients corneal tattooing may be the appropriate way to treat some types of unsightly corneal scarring. Using commercially available drawing ink the results in 11 patients are encouraging. The procedure seems to be relatively straightforward, simple, and with few or no complications.

See p 397

ADDRESSING THE PROBLEM OF DONOR MATERIAL FOR PENETRATING KERATOPLASTY

The shortage of donor organs for transplantation continues to be a problem in most developed countries. Although the problem is less severe for corneal tissue than it is for many other organs there continues to be a shortage of cornea donor material in most countries. Epstein and co-workers challenge a widely held notion that eyes with posterior chamber IOLs should be excluded from the potential donor pool. Using an organ culture technique the authors report on three parameters of corneal endothelial morphology and find that corneas from pseudophakic eyes compared favourably with those that were phakic. The authors suggest that corneas from pseudophakic eyes should not be routinely disqualified for transplantation.

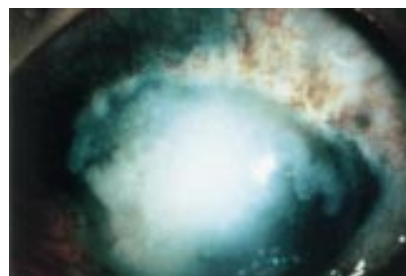
Gain and co-workers suggest in a comparable fashion that corneas from very old donors should not routinely be excluded from consideration. In this study very old was defined as 85 years of age and over. Although the corneas of very old donors have a poorer macroscopic appearance at procurement, and even during surgery, overall graft survival in this group of patients did not differ from survival in those who received material from younger patients.

See pp 400 and 404

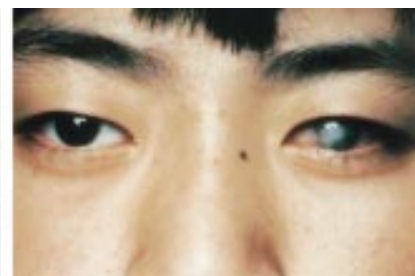THE PROBLEM OF PRESERVATIVES AND TOPICAL MEDICATIONS

Medical therapy for the treatment of glaucoma is often complicated by adverse side effects to topically applied drugs. Some of these side effects are directly related to the toxicity of the specific pharmaceutical agent being used to lower intraocular pressure. Yet a growing body of evidence suggests that preservatives in the topical applied solutions are a major factor in producing adverse side effects. Pisella *et al* report a prospective epidemiology study of 249 ophthalmologists and 4107 patients being treated with glaucoma medications. Their findings suggest that a significant proportion of the side effects reported with topical glaucoma medications are related to the preservatives and the use of preservative eye drops reduces the complications significantly.

See p 418



See pp 397–399.



www.bjophthalmol.com



BJO at a glance

Creig Hoyt

Br J Ophthalmol 2002 86: 363
doi: 10.1136/bjo.86.4.363-a

Updated information and services can be found at:
<http://bjo.bmj.com/content/86/4/363.2.full.html>

These include:

**Email alerting
service**

Receive free email alerts when new articles cite this article. Sign up in the box at the top right corner of the online article.

Notes

To request permissions go to:
<http://group.bmj.com/group/rights-licensing/permissions>

To order reprints go to:
<http://journals.bmj.com/cgi/reprintform>

To subscribe to BMJ go to:
<http://group.bmj.com/subscribe/>