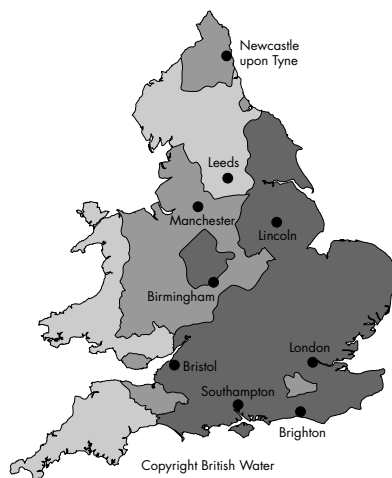


BJO at a glance

Creig Hoyt, Editor

THE CONTINUING PROBLEM OF ACANTHAMOEBA KERATITIS

The problem of acanthamoeba keratitis continues in most Western societies. Although it is a relatively rare infection it still results in significant visual loss in up to 15% of patients affected. It is well known that acanthamoeba keratitis is primarily associated with contact lens wear. Previous studies have documented that risk factors predisposing to acanthamoeba keratitis in contact lens wearers include non-sterile contact lens solutions, swimming in contact lenses, and inadequate disinfection. Radford and coworkers report on the British ophthalmic surveillance unit reporting system. Their findings reinforce previous studies concerning the problems of swimming in contact lenses, irregular disinfection of contact lenses, and inadequate sterilisation especially with the one step hydrogen peroxide and chloride release systems. In addition, they identify a risk factor not previously documented. The risk of acanthamoeba keratitis in this study was much greater in the southern region of England and the authors attribute this to water quality (hard water). This suggests of course that



See p 541

www.bjophthol.com

contact lens wearers must be allowing tap water to come in contact with their lenses or storage cases. Continuing education for contact lens wearers on the risk of acanthamoeba keratitis is obviously necessary.

See p 536

IS SCLERA SAFE?

Prusiner's notion of self replicating proteins or prions was extremely controversial when introduced two decades ago. Now it is widely accepted in medicine that prions may be important in the pathogenesis of several diseases. A case in point is Creutzfeldt-Jakob disease (CJD), a devastating encephalopathy. Transmission of CJD has been documented to occur infrequently as the result of corneal transplantation surgery. Mehta and Franks review the relative risks of the use of sclera in ophthalmic surgery and methods to minimise the potential transmission of CJD. They emphasise that the use of sclera in ophthalmology has increased significantly over the past decade. Because the risk of transmission of CJD has yet to be fully defined they suggest that it may be prudent for ophthalmologists to seek an alternative material whenever possible.

See p 587

TESTING VISUAL ACUITY IN YOUNG CHILDREN

Testing the visual acuity levels of patients at any age is a fundamental aspect of the ophthalmic examination. Over the past two decades significant additions to the testing possibilities of young children have been seen. The use of forced choice preferential looking techniques as well as visually evoked potentials have provided a means of estimating the visual acuity even in preverbal children. Regrettably, both of these techniques have a tendency to overestimate the visual acuity the amblyopic child. Over the past several years many paediatric ophthalmologists have begun to use the Lea symbols in establishing visual acuity measurements in children between 2 and 4 years of age. Many ophthalmologists have found them to be particularly useful in this age group. Becker and coworkers studied 385 children from the age of 21 to 93 months using the Lea symbol acuity measurement. Successful completion of the examination could be accomplished in over 50% of the patients and in the age group above 36 months the success rate was 76%. That the Lea test can be successfully administered seems clear. However, careful comparative studies assessing the Lea symbols *v* Landolt C test and others should be encouraged. Previous studies have suggested that Lea symbols also overestimate the visual acuity in amblyopic eyes as compared to the Landolt C test.

See p 489 and p 513

THE RISKS OF CATARACT SURGERY IN THE PATIENT WITH DIABETES

It has been generally held that diabetic retinopathy may become more severe following cataract surgery. The evidence for this is based primarily on retrospective studies. Squirrel and coworkers completed a prospective trial of 50 type 2 diabetics undergoing monocular phacoemulsification surgery by a single consultant surgeon. They studied retinopathy progression in these patients postoperatively. In 11 of the 50 patients the diabetic retinopathy progressed following cataract surgery. In seven the progression was in both eyes. Only in three did it progress in the operated eye alone. In 13 of the pseudophakic eyes macular oedema was observed. Progression of macular oedema was documented in five patients, but in both eyes. In four patients only the operated eye showed progression of the macular oedema. In two patients the macular oedema progressed in the non-operated eye. This study suggests that uncomplicated phacoemulsification cataract surgery does not represent a significant risk to the patient with type 2 diabetes in terms of either accelerated diabetic retinopathy or maculopathy.

See p 565



BJO at a glance

Creig Hoyt

Br J Ophthalmol 2002 86: 489
doi: 10.1136/bjo.86.5.489-a

Updated information and services can be found at:
<http://bjo.bmj.com/content/86/5/489.2.full.html>

	<i>These include:</i>
References	Article cited in: http://bjo.bmj.com/content/86/5/489.2.full.html#related-urls
Email alerting service	Receive free email alerts when new articles cite this article. Sign up in the box at the top right corner of the online article.

Notes

To request permissions go to:
<http://group.bmj.com/group/rights-licensing/permissions>

To order reprints go to:
<http://journals.bmj.com/cgi/reprintform>

To subscribe to BMJ go to:
<http://group.bmj.com/subscribe/>