

SCIENTIFIC CORRESPONDENCE

High dose intravenous steroid therapy for severe posterior segment uveitis in Behçet's disease

E Toker, H Kazokoğlu, N Acar

Br J Ophthalmol 2002;**86**:521–523

Aim: To evaluate the safety and effectiveness of high dose intravenous steroid therapy (HDIST) in Behçet's disease patients with severe posterior segment uveitis attacks.

Methods: Five patients with ocular Behçet's disease were treated with HDIST for severe posterior segment attacks. Two patients had vasculitis, one patient had papillitis, and the other two had retinitis; four patients also had accompanying severe vitritis. The visual acuities and improvement in ocular signs after HDIST were evaluated.

Results: During HDIST, patients had no systemic complications caused by treatment. All patients responded to HDIST with evidence of a decrease in intraocular inflammatory activity and improved visual acuities within a mean time of 7 (1–15) days of commencing treatment. During follow up three out of five patients had new posterior segment attacks.

Conclusion: HDIST is effective in controlling severe, vision threatening acute posterior segment Behçet's uveitis attacks and in improving visual function in a short period of time

Posterior segment involvement, which is usually in the form of retinitis and retinal vasculitis in Behçet's disease, is a significant cause of severe visual loss unless diagnosed early and treated properly. High dose intravenous steroid treatment (HDIST) is a form of steroid therapy recommended as an initial treatment in optic neuritis,¹ for the treatment of uveitis in patients with multiple sclerosis,² Vogt-Koyanagi-Harada disease,³ and other serious inflammatory diseases.⁴ Its efficacy in the prevention of severe visual loss in acute Behçet's disease has also been reported.^{5,6}

We treated five patients with Behçet's disease with acute posterior segment involvement with high dose intravenous methylprednisolone between May 1994 and March 1999. Patients with serious posterior segment attack (retinitis, vasculitis, papillitis, vitritis) that threatened the vision profoundly were selected for the treatment. All patients met the international diagnostic criteria for Behçet's disease.⁷

Patients were admitted to hospital and underwent a detailed medical examination. Intravenous methylprednisolone, 1 g, was administered over 1 hour for 3 days followed by initiation of oral methylprednisolone, 1 mg/kg/day, which was gradually tapered and then either stopped or continued at a maintenance dose of 10 mg/day. Adjunctive immunosuppressive treatment was initiated in patients who were not already on immunosuppressants.

REPORT OF CASES

Case 1

A 31 year old woman presented with acute visual loss in the left eye. She had a right ocular prosthesis (traffic accident). She had had the diagnosis of non-ocular Behçet's disease for 3

years. Examination of the left eye revealed a visual acuity of 0.2 and an area of vasculitis at the temporal vascular arcade with accompanying vitritis and macular oedema. HDIST was administered followed by oral methylprednisolone. Azathioprine 2 mg/kg/day was initiated. After 15 days, vision in the left eye improved to 0.6 with regression of vasculitis and vitritis. The visual acuity improved to 1.0 by the first month. Oral methylprednisolone was gradually tapered and discontinued during the ensuing 4 months. During 6 years of follow up no new ocular attacks occurred. Immunosuppressive treatment was continued for 4 years to control her extraocular signs of Behçet's disease. Since she has had no ocular or extraocular signs for the past 2 years immunosuppressive treatment has been discontinued.

Case 2

A 46 year old woman, diagnosed with Behçet's disease 2.5 years ago, had a complaint of acute visual loss in the right eye. She had a history of several episodes of anterior uveitis in both eyes (seven times in the right eye, once in the left eye), all of which responded to topical steroid therapy. On examination her visual acuity was counting fingers at 1 foot in the right eye and 1.0 left eye. She had papillitis in the right eye. HDIST was administered followed by oral methylprednisolone. The visual acuity improved to 0.8 on the second day and to 1.0 after 3 days. At the end of the first week azathioprine 2 mg/kg/day was initiated. Oral methylprednisolone was tapered gradually and discontinued after 4 months. During 2.5 years of follow up she had papillitis once and anterior uveitis four times in the right eye while taking immunosuppressive treatment.

Case 3

A 52 year old woman, with the diagnosis of Behçet's disease for 3.5 years, presented with sudden decrease of vision in the left eye. She had a history of acute posterior uveitis attacks (six times) in the left eye and had been taking oral steroids and immunosuppressive treatment (cyclosporine A 200 mg/kg/day, azathioprine 100 mg/day). Her visual acuity was 0.7 right eye and hand movement left eye. Examination of the left eye disclosed vasculitis and accompanying vitritis. She had posterior subcapsular cataracts in both eyes. HDIST was administered followed by oral methylprednisolone. By the ninth day her vision was counting fingers at 1 foot with an improvement of posterior segment inflammation. At the end of the second week her visual acuity was 0.2, which had been recorded to be the best visual acuity during the remission period. Oral methylprednisolone was tapered gradually over 2 months and continued at the maintenance dose. Meanwhile she had been taking azathioprine and cyclosporine at the same doses. After she discontinued oral methylprednisolone by mistake she had a recurrence of the attack and presented with a visual acuity of counting fingers at 1.5 feet. On examination she had papillitis, retinitis, and severe vitritis. She was administered HDIST for the second time. The visual acuity in her left eye improved minimally by the fourth day (counting

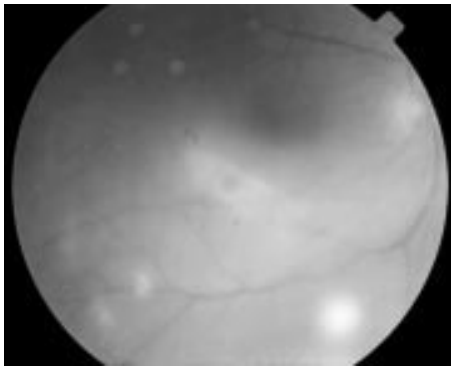


Figure 1 Fundus photograph of the right eye of case 4. Note multiple foci of retinitis along the inferior temporal vascular arcade accompanied by marked vitreous inflammation before initiation of HDIST.

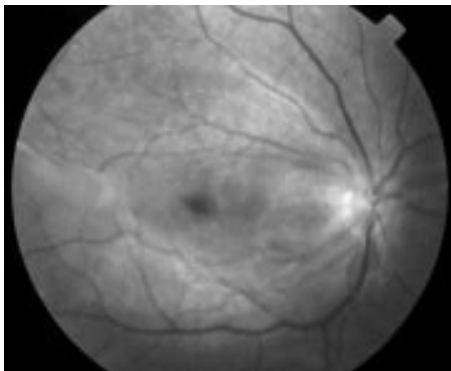


Figure 2 Fundus photograph of the same patient, after HDIST showing resolution of foci of retinitis and existing macular epiretinal membrane.

fingers at 5 feet) and after 7 weeks it was 0.05. She has been taking two immunosuppressive agents and oral steroid at the maintenance dose without any new attacks for the last 6 months.

Case 4

An 18 year old man presented with acute decrease of vision in both eyes. He had a history of blurred vision in his right eye a year ago for which he had taken no medical care. On examination he had retinitis and vitritis with a visual acuity of 0.05 right eye and 0.2 left eye (Fig 1). He was diagnosed with Behçet's disease based on recurrent oral aphthous ulcerations, folliculitis, uveitis, and HLA-B51 positivity. HDIST was administered followed by oral methylprednisolone. Azathioprine 2 mg/kg/day was added on the second day. By the fifth day the visual acuity improved to 0.2 right eye and 0.5 left eye with marked resolution of retinitis and vitritis. At the end of the second week visual acuity was 0.6 right eye and 1.0 left eye. In the right eye macular epiretinal membrane was observed (Fig 2). The oral methylprednisolone dose was gradually tapered to 10 mg/day over 3 months during which no new attacks occurred. He then moved to another city and was lost to follow up.

Case 5

A 29 year old man who had the diagnosis of ocular Behçet's disease and had been taking azathioprine 100 mg/day for a year presented with a sudden decrease of vision in the left eye. The visual acuity was 0.3 right eye and the funduscopy revealed a pale optic disc. The visual acuity of the left eye decreased to counting fingers at 2 feet which had been recorded to be 0.3 previously, and the examination disclosed

retinitis and vitritis. He also had bilateral posterior subcapsular cataracts. HDIST was administered followed by oral methylprednisolone. Azathioprine was continued at the same dose. By the sixth day the visual acuity improved to counting fingers at 5 feet and by the 12th day it increased to 0.3 with resolution of retinitis. Oral methylprednisolone dose was tapered over 4 months and continued at the maintenance dose of 10 mg/day for 3 months. During 3 years of follow up he had retinitis once in the left eye, but HDIST was not considered necessary as the visual acuity was not significantly affected.

DISCUSSION

The clinical course of Behçet's disease is characterised by exacerbations and remissions of unpredictable duration and frequency. The retinal disease is the most disquieting aspect of Behçet's disease. Attacks of inflammation may occur as frequently as every few weeks. These recurrent retinal vascular occlusive episodes ultimately lead to irreversible alterations and widespread retinal atrophy. Vision in patients with untreated Behçet's disease is usually lost, on average, 3.4 years after onset of eye symptoms.⁸

Many different treatment schedules have been tried in Behçet's disease. Corticosteroids (topical, periocular injection and systemic routes) have a beneficial effect on the acute manifestations of inflammation.⁹ Though the disease may initially respond to treatment with systemic corticosteroids, it will invariably become resistant with the need for additional treatments.¹⁰ Moreover, there is no proof that prolonged treatment with corticosteroids prevents the long term visual decline typical of this disorder. Because of the poor results of corticosteroid therapy, immunosuppressive drugs were tried in the early 1970s. The use of immunosuppressive drugs has generally resulted in an arrest of the disease process and induced a long term remission.^{11 12}

The efficacy of high dose methylprednisolone treatment in neuro-Behçet¹³ and many other inflammatory diseases⁴ has been documented. In a case report of a patient presenting with acute Behçet's retinitis threatening the fovea, Reed and associates⁵ pointed out that HDIST is effective in controlling the inflammation and reversing severe visual loss. In this series of five Behçet's disease cases, severe posterior segment uveitis attacks were effectively controlled with HDIST. Regression in clinical findings was seen within a mean time of 7 days (1–15 days) and best corrected visual acuities were achieved within a mean time of 15 days (3–30 days).

Wakefield and associates⁴ reported that pulse methylprednisolone therapy given on an intermittent basis in various severe ocular inflammatory diseases could be effective in resolution of the inflammation and may be continued on a long term basis to maintain disease remission. In our case series, the treatment goal was to achieve prompt control of the acute attack and we did not apply this treatment scheme as a continuous intermittent therapy. For long term disease control we prefer initiation of immunosuppressive treatment. New posterior segment attacks occurred in three patients during the follow up period. Therefore, it is not clear whether short term HDIST prevents the occurrence of new acute attacks.

HDIST has been reported to be associated with severe complications, including sudden death.^{14 15} Potential side effects should be well recognised by the ophthalmologist and consultation with an internist should be performed when required.

In conclusion, we recommend HDIST as an initial therapy in severe acute posterior segment uveitis attacks in Behçet's disease with substantial visual impairment for prompt control of the inflammation and faster recovery of visual function. In our opinion, HDIST spares the potential side effects of high dose oral steroid treatment. In such cases of Behçet's disease with severe ocular involvement, the initial dosages of oral steroids which are started for the control of acute inflammation frequently exceed 100 mg prednisone per day. The initiation doses are higher and the tapering period is definitely

longer than the oral steroid regimen that we start after HDIST, thus making the patient more prone to long term side effects of steroid therapy. Besides, our clinical impression is that the response to high dose oral steroids is not as immediate as in HDIST. We initiate adjunctive immunosuppressive therapy for controlling the disease long term if the patient is not on immunosuppressants. Azathioprine is our drug of choice in the treatment of severe Behçet's uveitis. The onset of action of immunosuppressants, particularly azathioprine, is delayed and benefit begins 6–12 weeks after starting the medication.¹⁶ For this reason, oral steroids should be tapered rather slowly during this period. Azathioprine with its steroid sparing effect allows the dosage of oral steroids to be lowered to a more acceptable level.

Authors' affiliations

E Toker, H Kazokoğlu, N Acar, Marmara University Medical School, Department of Ophthalmology

Correspondence to: Ebru Toker, İnönü cad, Yıldız sok, STFA Blokları, B-6, Daire 13, Kozyatağı, 81090, İstanbul, Turkey; aetoker@superonline.com

We have no proprietary interests in this study.

Accepted for publication 8 November 2001

REFERENCES

- 1 **The Optic Neuritis Study Group**. Visual function 5 years after optic neuritis: experience of the Optic Neuritis Treatment Trial. *Arch Ophthalmol* 1997;**115**:1545–52.
- 2 **Wakefield D**, Jennings A, McCluskey PJ. Intravenous pulse methylprednisolone in the treatment of uveitis associated with multiple sclerosis. *Clin Exp Ophthalmol* 2000;**28**:103–6.
- 3 **Sasamoto Y**, Ohno S, Matsuda H. Studies on corticosteroid therapy in Vogt-Koyanagi-Harada disease. *Ophthalmologica* 1990;**201**:162–7.
- 4 **Wakefield D**, McCluskey P, Penny R. Intravenous pulse methylprednisolone therapy in severe inflammatory eye disease. *Arch Ophthalmol* 1986;**104**:847–51.
- 5 **Reed JB**, Morse LS, Schwab IR. High-dose intravenous pulse methylprednisolone hemisuccinate in acute Behçet retinitis. *Am J Ophthalmol* 1998;**125**:410–11.
- 6 **Postelmans L**, Verougstraete C, Libert J, *et al*. Intravenous corticosteroid megadose treatment in ocular Behçet disease. *Bull Soc Belge Ophthalmol* 1996;**262**:95–103.
- 7 **International Study Group for Behçet's Disease**. Criteria for diagnosis of Behçet's disease. *Lancet* 1990;**335**:1078–80.
- 8 **Mamo JG**. The rate of visual loss in Behçet's disease. *Arch Ophthalmol* 1970;**84**:451–2.
- 9 **Nussenblatt RB**, Palestine AG, eds. Behçet's disease and other retinal vasculitides. In: *Uveitis fundamentals and clinical practice*. Chicago: Year Book Medical, 1989:212–47.
- 10 **Benezra D**, Cohen E. Treatment and visual prognosis in Behçet's disease. *Br J Ophthalmol* 1986;**70**:589–92.
- 11 **Hamuryudan V**, Ozyazgan Y, Hizli N, *et al*. Azathioprine in Behçet's syndrome: effects on long-term prognosis. *Arthritis Rheum* 1997;**40**:769–74.
- 12 **Nussenblatt RB**, Palestine AG, Chan CC, *et al*. Effectiveness of cyclosporin therapy for Behçet's disease. *Arthritis Rheum* 1985;**67**:1–9.
- 13 **Tsunoda I**, Kanno H, Wantanabe M, *et al*. Acute simultaneous bilateral vestibulocochlear impairment in neuro-Behçet's disease: a case report. *Auris Nasus Larynx* 1994;**21**:243–7.
- 14 **Choruses GA**, Kattah JC, Beck RW, *et al*. Side effects of glucocorticoid treatment: experience of the optic neuritis treatment trial. *JAMA* 1993;**269**:2110–12.
- 15 **Moses RE**, McCormick A, Nickey W. Fatal arrhythmia after pulse methylprednisolone therapy (letter). *Ann Intern Med* 1981;**95**:781–2.
- 16 **Rosenbaum JT**. Immunosuppressive therapy of uveitis. In: Nozik RA, Michelson JB, eds. *Uveitis. Ophthalmology Clinics of North America*. Philadelphia: WB Saunders, 1993:167–75.



High dose intravenous steroid therapy for severe posterior segment uveitis in Behçet's disease

E Toker, H Kazokoglu and N Acar

Br J Ophthalmol 2002 86: 521-523

doi: 10.1136/bjo.86.5.521

Updated information and services can be found at:

<http://bjo.bmj.com/content/86/5/521.full.html>

These include:

References

This article cites 12 articles, 5 of which can be accessed free at:

<http://bjo.bmj.com/content/86/5/521.full.html#ref-list-1>

Article cited in:

<http://bjo.bmj.com/content/86/5/521.full.html#related-urls>

Email alerting service

Receive free email alerts when new articles cite this article. Sign up in the box at the top right corner of the online article.

Topic Collections

Articles on similar topics can be found in the following collections

[Retina](#) (1207 articles)

Notes

To request permissions go to:

<http://group.bmj.com/group/rights-licensing/permissions>

To order reprints go to:

<http://journals.bmj.com/cgi/reprintform>

To subscribe to BMJ go to:

<http://group.bmj.com/subscribe/>