

CLINICAL SCIENCE

Optic disc cup slope and visual field indices in normal, ocular hypertensive and early glaucomatous eyes

A B Cullinane, A Waldoek, J P Diamond, J M Sparrow

Br J Ophthalmol 2002;**86**:555-559

See end of article for authors' affiliations

Correspondence to:
Mr A Cullinane, Bristol Eye Hospital, Lower Maudlin Street, Bristol BS1 2LX, UK; abcullinane@hotmail.comAccepted for publication
7 January 2002**Aim:** To evaluate the correlation between internal slope analysis of the optic nerve head and visual field changes in normal eyes and those with ocular hypertension (OHT) and early glaucoma (POAG).**Methods:** One eye of each of 22 normal subjects, 21 patients with ocular hypertension, and 50 patients with glaucoma were examined using the TopSS scanning laser ophthalmoscope. A series of topographic parameters measuring the internal features of the optic discs of these patients were obtained. These findings were compared with the Humphrey visual field analysis of these patients.**Results:** Global topographic average slope and cup to disc ratio could discriminate between groups of normal and OHT patients ($p = 0.02$). All global and sector analysis parameters could discriminate normal subjects from POAG patients. The average slope parameter provided the best separation with a receiver operating characteristic curve area of 0.88. Visual field mean deviation (MD) was most closely correlated with global average slope ($r = -0.60$, $p < 10^{-7}$) and cup to disc ratio ($r = -0.40$, $p < 0.001$). Visual field MD was also well correlated ($r = -0.50$, $p < 0.0001$) with slope parameters for sectors S8, S2, and S1.**Conclusion:** Average slope, a parameter independent of reference planes and magnification effects, is capable of discriminating groups of OHT and POAG patients from a group of normal subjects. This topographic parameter is also well correlated with the visual field MD. Sector slope analysis suggests early glaucomatous damage may occur in the inferotemporal region of the optic disc.

Current literature suggests that a significant degree of optic nerve fibre loss precedes visual field defect formation in patients with glaucomatous optic neuropathy.¹⁻³ A study by Sommer *et al*⁴ found that nerve fibre layer defects were detectable up to 6 years before visual field loss could be clinically demonstrated. In order to examine for optic nerve head changes, the confocal scanning laser ophthalmoscope (SLO) has become a useful tool in the morphological assessment of the optic nerve head.⁵ Area and volume derived topographic parameters have been studied extensively for their ability to discriminate normal eyes from those with glaucoma,⁶⁻⁸ but only a handful of studies have examined the slope measurement parameter of the optic disc cup. Dong *et al*,⁹ using sector based slope, and Caprioli *et al*,¹⁰ using peripapillary slope measurements, have examined this function in separating normal from glaucomatous eyes. However, the correlation between visual field indices and slope values have not been previously examined. In the knowledge that disc slope changes may occur before visual field change, this study examines for the relation between this parameter and visual field indices in a population of normal, ocular hypertensive, and early glaucoma patients, all having a visual field mean deviation better than -4 dB.

PATIENTS AND METHODS

Three age and sex matched white groups consisting of normal subjects ($n = 22$) and patients with ocular hypertension (OHT) ($n = 21$) and primary open angle glaucoma (POAG) ($n = 50$) were recruited at Bristol Eye Hospital. Patients with OHT and POAG were recruited from the glaucoma clinic, while normal subjects were recruited following advertisements in the local media. These had an age range from 49 to 89 years. The mean age for each group was 62 years (normal), 67 years (ocular hypertensives), and 68 years (glaucoma) respectively. This prospective cross sectional study was approved by the ethics committee for the United Bristol Healthcare Trust and

informed consent was obtained from all of the patients. One eye was randomly selected from each subject before entry into the study and only eyes with a spherical equivalent between -5 and $+5$ dioptres were included.

Normal subjects were included in the study if there was no family history of glaucoma and they had had no intraocular pressure rise or ocular trauma in the past, a best corrected visual acuity of 6/12 or better, normal anterior segments on slit lamp biomicroscopy, intraocular pressure of less than 22 mm Hg (Goldmann tonometer), normal optic nerve head appearances on stereoscopic optic disc photography, and no glaucomatous visual field defects on Humphrey 24-2 full threshold automated perimetry. Ocular hypertensive subjects were the same as for the group of normals but with intraocular pressure greater than 21 mm Hg on two separate occasions.

Primary open angle glaucoma patients were included if they had a best corrected visual acuity of 6/12 or better, anterior segment examination which confirmed open angles but did not demonstrate pseudoexfoliation or pigment dispersion, had glaucomatous changes to the appearance of their optic nerve heads on stereoscopic optic disc photography, and had visual field abnormalities consistent with glaucoma. These visual field defects were defined by at least three adjacent points 5 dB or more below the normal with a Humphrey 24-2 full threshold program.

Only patients with visual field deviation scores better than -4 dB were included. A reliable visual field test for study eyes in all groups was defined as one with fewer than 15% false positive responses, fewer than 15% false negative responses, and fewer than 20% fixation losses.

Abbreviations: CDR, cup-disc ratio; HRT, Heidelberg retinal tomograph; MD, mean deviation; NRR, neuroretinal rim area; OHT, ocular hypertension; PSD, pattern standard deviation; POAG, primary open angle glaucoma; ROC, receiver operating characteristic; SLO, scanning laser ophthalmoscope

Table 1 Global demographic data in normal (N), ocular hypertensive (OHT), and early glaucoma (POAG) subjects

	Normal (n=22)	OHT (n=21)	POAG (n=50)	p Value		
	Mean (SD)	Mean (SD)	Mean (SD)	N/POAG	OHT/POAG	N/OHT
Mean deviation	0.751 (0.74)	0.543 (1.11)	-1.637 (1.49)	<0.0001	<0.0001	NS
Pattern standard deviation	2.160 (0.51)	1.998 (0.54)	3.652 (1.74)	<0.0001	<0.0001	NS
Retinal sensitivity	1565 (68.8)	1525 (77.9)	1400 (86.5)	<0.0001	<0.0001	NS
Disc area	2.08 (0.47)	2.10 (0.34)	2.07 (0.48)	NS	NS	NS
Refractive error	+0.52 (1.79)	+0.72 (2.11)	+0.26 (2.11)	NS	NS	NS

Student's *t* test; NS = not significant.**Table 2** Global SLO topographical parameters in normal (N), ocular hypertensive (OHT), and early glaucoma (POAG) subjects

	Normal (n=22)	OHT (n=21)	POAG (n=50)	p Value		
	Mean (SD)	Mean (SD)	Mean (SD)	N/POAG	OHT/POAG	N/OHT
Average slope (degrees)	30.89 (6.76)	36.01 (7.11)	39.85 (5.07)	<10 ⁻⁸	<0.01	<0.05
Cup-disc ratio	0.308 (0.13)	0.403 (0.14)	0.487 (0.12)	<0.0001	<0.05	<0.05
Neuroretinal rim area (mm ²)	1.414 (0.317)	1.255 (0.338)	1.058 (0.33)	<0.0001	<0.05	NS
Effective area (mm ²)	0.666 (0.340)	0.850 (0.321)	1.013 (0.34)	<0.0001	NS	NS
Volume above (mm ³)	0.288 (0.069)	0.253 (0.250)	0.200 (0.08)	<0.0001	NS	NS
Volume below (mm ³)	-0.101 (0.330)	-0.253 (-0.256)	-0.325 (0.18)	<0.0001	NS	NS
Average depth (mm)	-2.174 (1.67)	-3.082 (1.72)	-3.585 (1.31)	<0.0001	NS	NS
Maximum depth (mm)	-4.898 (3.40)	-6.892 (4.36)	-8.256 (3.10)	<0.0001	NS	NS
Half depth area (mm ²)	0.165 (0.149)	0.216 (0.191)	0.303 (0.29)	<0.05	NS	NS
Half depth volume (mm ³)	-0.021 (0.031)	-0.041 (0.044)	-0.052 (0.05)	<0.05	NS	NS

Student's *t* test; NS = not significant.

The optic disc measurements were obtained by one examiner using the TopSS confocal scanning laser ophthalmoscope (Laser Diagnostic Technologies Inc, San Diego, CA, USA). The details of this imaging system have been described elsewhere.^{9,11} In this study the scan angle was set at 10° and scan depth and scan offset were adjusted to 3 mm and position 3 respectively. Baseline images were made using the average of three consecutive images. The optic disc margin was defined by changing the shape of an ellipse and fitting the best ellipse around the inner border of the scleral ring. The cup margin was defined by an offset of 100 µm below the retinal reference plane. The following optic disc parameters were obtained: mean contour depth, cup shape, cup area, half depth area, cup/disc ratio (CDR), area of neuroretinal rim, volume above, volume below, half depth volume, average depth, maximum depth, average slope, and maximum slope.

The defined area of interest (optic disc) was also divided into 12 equal sectors, thereby allowing a sector value for each of the aforementioned parameters to be calculated. Sector slope values were calculated as described previously.⁹ Briefly, the software calculates the central point of the defined area of interest (C1). A line that connects a measurement point or pixel, P1, with the centre of the area of interest C1 is then formed. Along this line, the software finds the depth values of the points that are at a horizontal distance of 60 µm central (P2) to and 60 µm peripheral (P3) to P1 along this line. Angular slope (degrees) is calculated using the formula: slope = abs (atan((P2 - P3)/120 µm)). This is repeated for all points and the values of the slope for every point within the global area of interest or sector are averaged to calculate the respective global average slope or sector slope values. Sector 1 was located in the superior nasal meridian of the disc; sectors 1-12 were numbered clockwise for right eyes and anticlockwise for left eyes. Receiver operating characteristic curves, Student's *t* test, and Pearson's correlation coefficient *r* were used in statistical analysis.

RESULTS

There was no statistically significant difference found in age or refractive error between the groups. The mean deviation

values measured by Humphrey 24-2 full threshold program ranged from +2.87 to -3.89 for the 93 subjects. The global demographic data for each group (mean (SD)) are presented in Table 1. The mean deviation values of the normal group and the groups with OHT and POAG were 0.75 (0.74) dB, 0.54 (1.11) dB and -1.6 (1.49) dB, respectively. Optic disc area failed to separate any of the groups. A significant difference was found in visual field mean deviation (MD) and pattern standard deviation (PSD) between normal and POAG patients ($p < 10^{-7}$ and $p < 10^{-5}$ respectively) and between OHT and POAG

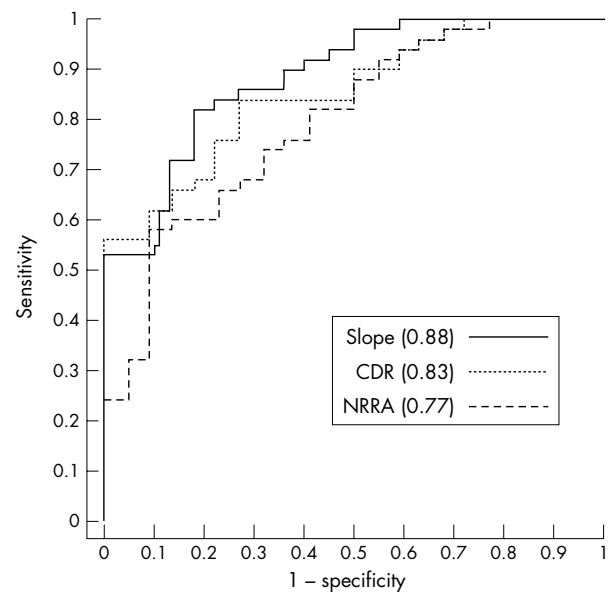


Figure 1 Receiver operating characteristic curves (and areas) for the best separating parameters between the normal and primary open angle glaucoma groups. (Global average slope (slope), continuous line; cup-disc ratio (CDR), dotted line; neuroretinal rim area (NRRA), broken line.)

Table 3 Individual sector slope data in normal (N), ocular hypertensive (OHT), and early glaucoma (POAG) subjects

	Normal (n=22)	OHT (n=21)	POAG (n=50)	p Value		
	Mean (SD)	Mean (SD)	Mean (SD)	N/POAG	OHT/POAG	N/OHT
Sector slope 1	31.15 (8.06)	34.70 (9.02)	41.52 (7.56)	<0.0001	<0.01	NS
Sector slope 2 (SN)	31.79 (9.15)	35.59 (8.93)	40.44 (6.81)	<0.0001	<0.05	NS
Sector slope 3	29.63 (7.98)	33.74 (9.31)	37.84 (7.21)	<0.0001	NS	NS
Sector slope 4	30.83 (7.91)	35.46 (7.70)	38.74 (7.55)	<0.0001	NS	NS
Sector slope 5 (IN)	33.86 (8.33)	37.51 (7.49)	41.27 (7.01)	<0.0001	NS	NS
Sector slope 6	34.99 (10.42)	37.78 (8.88)	42.08 (6.48)	<0.0001	<0.05	NS
Sector slope 7	31.92 (9.45)	35.86 (7.72)	42.18 (6.44)	<0.0001	<0.001	NS
Sector slope 8 (IT)	29.14 (9.23)	35.23 (7.87)	41.36 (7.80)	<0.0001	<0.005	<0.05
Sector slope 9	28.50 (8.33)	32.21 (9.28)	36.91 (7.74)	<0.0001	<0.05	NS
Sector slope 10	28.30 (7.25)	31.44 (9.41)	37.54 (6.58)	<0.0001	<0.01	NS
Sector slope 11 (ST)	30.76 (7.38)	33.58 (9.77)	39.02 (5.25)	<0.0001	<0.01	NS
Sector slope 12	29.80 (7.06)	33.21 (8.21)	39.26 (7.11)	<0.0001	<0.01	NS

Student's *t* test; NS = not significant; SN = superonasal; IN = inferonasal; IT = inferotemporal; ST = superotemporal.

Table 4 Sensitivity and specificity data of global topographical parameters between normal and early glaucoma subjects (n=72)

	Cut-off criterion	Specificity	Sensitivity
Average slope	36.5	80%	83%
Cup-disc ratio	0.39	76%	78%
Neuroretinal rim area	1.25	70%	73%

patients ($p < 10^{-6}$ and $p < 10^{-4}$ respectively). However, MD and PSD failed to significantly separate the normals from the OHT group. ($p = 0.5$ and $p = 0.3$ respectively).

Table 2 illustrates the global topographical data and demonstrates that discrimination of groups of normal from OHT patients was possible with the average slope parameter ($p = 0.017$) and cup to disc ratio ($p = 0.022$). All other global optic disc parameters could not discriminate between these two groups. Average slope, cup to disc ratio, and neuroretinal rim area significantly separated the OHT from the POAG groups ($p = 0.016$, $p = 0.013$, $p = 0.027$ respectively). There were statistically significant differences found between the normal eyes and those with POAG for all SLO global morphological parameters. The most highly significant difference ($p < 10^{-8}$) was found in the average slope values for the normal and POAG group. Specificity and sensitivity values were calculated using receiver operating characteristic (ROC) curve analysis. The largest ROC curve areas were found for global average

slope (0.88), cup-disc ratio (CDR) (0.83) and neuroretinal rim area (0.77). These findings are shown in Figure 1 and in Table 3.

Table 4 illustrates the results of sector data analysis. S8 slope (inferotemporal) is the only sector value which significantly discriminates the normal and ocular hypertensive groups ($p = 0.025$). All sector slope values separated the OHT from the POAG groups except sectors S3–S5, with sector 7 slope (inferotemporal) having the greatest separation ($p = 0.0009$). All sector slope parameters discriminated the normal group from the glaucoma group but this separation did not exceed that obtained with the global average slope parameter.

Table 5 presents the SLO parameters which demonstrate a statistically significant correlation (Pearson's *r*) with visual field indices. These included average slope, maximum depth, cup-disc ratio, average depth, neuroretinal rim area, effective area, volume above, and volume below. Disc area, half depth area, and half depth volume failed to show any correlation. Among the highest individual correlations found were those between visual field MD and cup-disc ratio ($r = -0.40$, $p < 0.001$) and MD and maximum depth ($r = 0.42$, $p < 0.001$), with MD and global average slope demonstrating the highest overall correlation ($r = -0.60$, $p < 10^{-7}$).

Sector data analysis (Table 6) illustrates moderate correlations between individual sector slopes and MD with S8, S2, and S1 having the higher correlation values ($r = -0.56$, $r = -0.53$ and $r = -0.52$ respectively ($p < 0.0001$)). All other SLO sector parameters were found to have a lower correlation with visual field indices than sector slope in terms of both Pearson's *r* value and significance (data not shown).

Table 5 Correlation between Humphrey visual field indices and global SLO topographical parameters in a population of normal, ocular hypertensive, and early glaucoma subjects (n=93)

	Pearson's <i>r</i>			
	Mean deviation		Pattern standard deviation	
Average slope	-0.600057	($p < 10^{-7}$)	0.365165	($p < 0.01$)
Cup-disc ratio	-0.404238	($p < 0.001$)	0.369586	($p < 0.01$)
Maximum depth	0.397377	($p < 0.001$)	-0.262692	($p < 0.01$)
Average depth	0.395438	($p < 0.001$)	-0.220046	($p < 0.01$)
Neuroretinal rim area	0.374840	($p < 0.005$)	-0.265067	($p < 0.01$)
Effective area	-0.303869	($p < 0.005$)	0.374903	($p < 0.01$)
Volume above	0.366774	($p < 0.01$)	-0.250912	($p < 0.01$)
Volume below	0.321084	($p < 0.02$)	-0.288503	($p < 0.01$)
Disc area	0.141585	NS	0.095362	NS
Half depth area	-0.137731	NS	-0.102548	NS
Half depth volume	-0.168311	NS	-0.153892	NS

NS = not significant.

Table 6 Correlation between Humphrey visual field indices and individual sector slope data in a population of normal, ocular hypertensive, and early glaucoma subjects (n=93)

	Pearson's r			
	Mean deviation		Pattern standard deviation	
Sector slope 1	-0.524437	(p<0.0001)	0.427514	(p<0.01)
Sector slope 2 (SN)	-0.531059	(p<0.0001)	0.305946	(p<0.01)
Sector slope 3	-0.479059	(p<0.001)	0.213582	(p<0.01)
Sector slope 4	-0.448887	(p<0.001)	0.197958	(p<0.05)
Sector slope 5 (IN)	-0.463868	(p<0.001)	0.217028	(p<0.01)
Sector slope 6	-0.464619	(p<0.001)	0.298773	(p<0.01)
Sector slope 7	-0.517950	(p<0.0001)	0.324095	(p<0.01)
Sector slope 8 (IT)	-0.563194	(p<0.0001)	0.303141	(p<0.01)
Sector slope 9	-0.483856	(p<0.001)	0.312517	(p<0.01)
Sector slope 10	-0.513723	(p<0.0001)	0.331678	(p<0.01)
Sector slope 11 (ST)	-0.470906	(p<0.001)	0.331556	(p<0.01)
Sector slope 12	-0.470643	(p<0.001)	0.318455	(p<0.01)

SN = superonasal; IN = inferonasal; IT = inferotemporal; ST = superotemporal.

DISCUSSION

Studies using the confocal SLO have previously demonstrated global optic disc parameters to be of use in discriminating normal from OHT or POAG eyes.¹²⁻¹⁴ However, many of these parameters have the limitation of being dependent upon the definition of a retinal reference plane or reference cap. It has previously been suggested that the retinal reference plane may be displaced downwards during glaucoma progression due to retinal nerve fibre layer thinning.¹⁰⁻¹¹ This may have the erroneous effect of increasing the value of volume parameters derived from height measurements. In addition, optic disc size and image magnification or minification secondary to refractive power of the eye may influence area dependent parameter calculations, in particular neuroretinal rim area, cup-disc ratio, and effective area.¹⁵⁻¹⁷

Dong *et al*⁹ have demonstrated the potential of the slope parameter in discriminating between normals and ocular hypertensives or glaucoma suspects. This parameter has the advantage over other parameters in that it is independent of all of the above variables. In this study we have assessed this parameter to discriminate between groups of normal, ocular hypertensive and early glaucoma patients. Furthermore, we have also evaluated the correlation between this independent parameter and visual field indices.

This study confirms that most global topographic parameters can discriminate between groups of normal and early glaucoma patients, the greatest separation being achieved by utilising the average slope parameter, which was found to have a ROC curve area value of 0.88. The ROC values found in our study are similar to those found in previous studies of comparable size which examined optic disc morphology using the Heidelberg retinal tomograph (HRT). Zangwill *et al*¹⁸ found that the mean height contour parameter had a ROC curve area value of 0.86, while Vihanninjoki *et al*¹⁹ found that CDR was the best separating parameter with an area of 0.88. In a large study involving 226 subjects, Iester *et al*²⁰ demonstrated that the largest ROC curve areas were found for cup shape measure (0.812), neuroretinal rim area (0.809), and CDR (0.804). It must be noted that in these studies, which used the HRT instrument, internal cup slope was not routinely calculated. Caprioli *et al*,¹⁰ however, in an attempt to create a parameter independent of the retinal reference plane calculated the slope of the peripapillary nerve fibre layer and found an ROC curve area of 0.86.

Only average slope and CDR could significantly separate the group of OHT patients from the group of normal subjects. These two parameters could also discriminate the POAG from the OHT groups. Although these parameters have been shown to be very reproducible,^{9,21} it is the average slope function

which has the advantage of being independent of the retinal reference plane and any possible magnification effects. In addition, in this study we have demonstrated a highly significant correlation between global average slope and visual field mean deviation. This outperforms all other global parameter measures including CDR.

Dong *et al*⁹ demonstrated that sector slope analysis is reproducible and may discriminate between groups of normal subjects and OHT or glaucoma patients. Our findings confirm that sector slope analysis can discriminate between groups of normals and early POAG patients. However, we have found that it is only the inferotemporal slope (sector 8) which significantly separates the ocular hypertensives from the normal group. Furthermore, this sector (S8) also has the highest correlation with visual field mean deviation on individual sector analysis.

This observation suggests that sector slope steepening in this area may be the first optic nerve head morphological change in early glaucoma. These findings are slightly different from Dong *et al*,⁹ who reported that steepening of the nasal inferior sector slopes (S5 and 6) may be the first indicator of glaucomatous nerve damage. Early inferotemporal slope change is consistent with the findings of Tuulonen and Airaksinen,²² as well as observations reported by Jonas in two studies.²³⁻²⁴ This pattern of early sector 8 slope steepening is also consistent with previous visual field studies where perimetric focal defects in early glaucoma have been found to begin in the upper nasal field quadrant.²⁵⁻²⁷

In summary, we have confirmed previous research highlighting the ability of internal cup slope to discriminate between groups of normal, OHT, and POAG eyes. This parameter performs better than other topographic parameters and it is independent of the limitations linked to those parameters. Furthermore, we have demonstrated its correlation with visual field mean deviation and the superiority over CDR in discriminating early POAG and OHT patients from normals. It also appears that all sector slope values are useful, in particular the inferotemporal sector slope, which may be an effective measurement parameter in the early detection of optic disc damage in glaucoma. The role of internal cup slope in the determination of glaucomatous progression is currently being evaluated.

Authors' affiliations

A B Cullinane, A Waldock, J P Diamond, J M Sparrow, Bristol Eye Hospital, Lower Maudlin Street, Bristol BS1 2LX, UK

REFERENCES

- 1 Quigley HA, Addicks EM, Green WR. Optic nerve damage in human glaucoma. III. Quantitative correlation of nerve fiber loss and visual field

- defect in glaucoma, ischemic neuropathy, papilledema, and toxic neuropathy. *Arch Ophthalmol* 1982;**100**:135–46.
- 2 **Sommer A**, Quigley HA, Robin AL, *et al*. Evaluation of nerve fiber layer assessment. *Arch Ophthalmol* 1984;**102**:1766–71.
 - 3 **Quigley HA**, Katz J, Derick RJ, *et al*. An evaluation of optic disc and nerve fiber layer examinations in monitoring progression of early glaucoma damage. *Ophthalmology* 1992;**99**:19–28.
 - 4 **Sommer A**, Katz J, Quigley HA, *et al*. Clinically detectable nerve fiber atrophy precedes the onset of glaucomatous field loss. *Arch Ophthalmol* 1991;**109**:77–83
 - 5 **Hatch WV**, Flanagan JG, EtcHELLS EE, *et al*. Laser scanning tomography of the optic nerve head in ocular hypertension and glaucoma. *Br J Ophthalmol* 1997;**81**:871–6.
 - 6 **King AJ**, Bolton N, Aspinall P, *et al*. Measurement of peripapillary retinal nerve fiber layer volume in glaucoma. *Am J Ophthalmol* 2000;**129**:599–607.
 - 7 **lester M**, De Ferrari R, Zanini M. Topographic analysis to discriminate glaucomatous from normal optic nerve heads with a confocal scanning laser: new optic disk analysis without any observer input. *Surv Ophthalmol* 1999;**44**(Suppl 1):S33–40.
 - 8 **Wollstein G**, Garway-Heath DF, Fontana L, *et al*. Identifying early glaucomatous changes. Comparison between expert clinical assessment of optic disc photographs and confocal scanning ophthalmoscopy. *Ophthalmology* 2000;**107**:2272–7.
 - 9 **Dong J**, Chihara E. Slope analysis of the optic disc in eyes with ocular hypertension and early normal tension glaucoma by confocal scanning laser ophthalmoscopy. *Br J Ophthalmol* 2001;**85**:56–62.
 - 10 **Caprioli J**, Park HJ, Ugurlu S, *et al*. Slope of the peripapillary nerve fiber layer surface in glaucoma. *Invest Ophthalmol Vis Sci* 1998;**39**:2321–8.
 - 11 **Ahn BS**, Kee C. Ability of a confocal scanning laser ophthalmoscope (TopSS) to detect early glaucomatous visual field defect. *Br J Ophthalmol* 2000;**84**:852–5.
 - 12 **Kamal DS**, Garway-Heath DF, Hitchings RA, *et al*. Use of sequential Heidelberg retina tomograph images to identify changes at the optic disc in ocular hypertensive patients at risk of developing glaucoma. *Br J Ophthalmol* 2000;**84**:993–8.
 - 13 **Wollstein G**, Garway-Heath DF, Hitchings RA. Identification of early glaucoma cases with the scanning laser ophthalmoscope. *Ophthalmology* 1998;**105**:1557–63.
 - 14 **lester M**, Broadway DC, Mikelberg FS, *et al*. A comparison of healthy, ocular hypertensive, and glaucomatous optic disc topographic parameters. *J Glaucoma* 1997;**6**:363–70.
 - 15 **Kee C**, Koo H, Ji Y, *et al*. Effect of optic disc size or age on evaluation of optic disc variables. *Br J Ophthalmol* 1997;**81**:1046–9.
 - 16 **lester M**, Mikelberg FS, Drance SM. The effect of optic disc size on diagnostic precision with the Heidelberg retina tomograph. *Ophthalmology* 1997;**104**:545–8.
 - 17 **Garway-Heath DF**, Rudnicka AR, Lowe T, *et al*. Measurement of optic disc size: equivalence of methods to correct for ocular magnification. *Br J Ophthalmol* 1998;**82**:643–9.
 - 18 **Zangwill LM**, Bowd C, Berry CC *et al*. Discriminating between normal and glaucomatous eyes using the Heidelberg retina tomograph, GDx nerve fiber analyzer, and optical coherence tomograph. *Arch Ophthalmol* 2001;**119**:985–93.
 - 19 **Vihanninjoki K**, Teesalu P, Burk RO, *et al*. Search for an optimal combination of structural and functional parameters for the diagnosis of glaucoma. Multivariate analysis of confocal scanning laser tomograph, blue-on-yellow visual field and retinal nerve fiber layer data. *Graefes Arch Clin Exp Ophthalmol* 2000;**238**:477–81.
 - 20 **lester M**, Mikelberg FS, Swindale NV, *et al*. ROC analysis of Heidelberg retina tomograph optic disc shape measures in glaucoma. *Can J Ophthalmol* 1997;**32**:382–8.
 - 21 **Geyer O**, Michaeli-Cohen A, Silver DM, *et al*. Reproducibility of topographic measures of the glaucomatous optic nerve head. *Br J Ophthalmol* 1998;**82**:14–17.
 - 22 **Tuulonen A**, Airaksinen PJ. Initial glaucomatous optic disc and retinal nerve fiber layer abnormalities and their progression. *Am J Ophthalmol* 1991;**111**:485–90.
 - 23 **Jonas JB**, Fernandez MC, Sturmer J. Pattern of glaucomatous neuroretinal rim loss. *Ophthalmology* 1993;**100**:63–8.
 - 24 **Jonas JB**, Gusek GC, Naumann GO. Optic disc morphometry in chronic primary open-angle glaucoma. II. Correlation of the intrapapillary morphometric data to visual field indices. *Graefes Arch Clin Exp Ophthalmol* 1988;**226**:531–8.
 - 25 **Drance SM**. The early field defects in glaucoma. *Invest Ophthalmol* 1969;**8**:84–91.
 - 26 **Caprioli J**, Sears M, Miller JM. Patterns of early visual field loss in open-angle glaucoma. *Am J Ophthalmol* 1987;**103**:512–17.
 - 27 **Goldberg I**. Optic disc and visual field changes in primary open angle glaucoma. *Aust J Ophthalmol* 1981;**9**:223–9.



Is your paper being cited?

CiteTrack service

CiteTrack will alert you by email whenever new content in the *British Journal of Ophthalmology* or a participating journal is published that matches criteria you want to track

Topics: Tell CiteTrack which words or subjects to watch for in new content

Authors: Be alerted whenever key authors you are following publish a new paper

Articles: Know whenever a paper of interest to you is referenced by another paper

www.bjophthalmol.com



Optic disc cup slope and visual field indices in normal, ocular hypertensive and early glaucomatous eyes

A B Cullinane, A Waldoock, J P Diamond, et al.

Br J Ophthalmol 2002 86: 555-559

doi: 10.1136/bjo.86.5.555

Updated information and services can be found at:

<http://bjo.bmj.com/content/86/5/555.full.html>

References

These include:

This article cites 26 articles, 13 of which can be accessed free at:

<http://bjo.bmj.com/content/86/5/555.full.html#ref-list-1>

Article cited in:

<http://bjo.bmj.com/content/86/5/555.full.html#related-urls>

Email alerting service

Receive free email alerts when new articles cite this article. Sign up in the box at the top right corner of the online article.

Topic Collections

Articles on similar topics can be found in the following collections

[Angle](#) (788 articles)

[Glaucoma](#) (776 articles)

[Intraocular pressure](#) (786 articles)

Notes

To request permissions go to:

<http://group.bmj.com/group/rights-licensing/permissions>

To order reprints go to:

<http://journals.bmj.com/cgi/reprintform>

To subscribe to BMJ go to:

<http://group.bmj.com/subscribe/>