

PostScript

LETTERS

If you have a burning desire to respond to a paper published in the *BJO*, why not make use of our "rapid response" option? Log on to our website (www.bjophthalmol.com), find the paper that interests you, and send your response via email by clicking on the "eLetters" option in the box at the top right hand corner.

Providing it isn't libellous or obscene, it will be posted within seven days. You can retrieve it by clicking on "read eLetters" on our homepage.

The editors will decide as before whether to also publish it in a future paper issue.

Needle aspiration of a traumatic subperiosteal haematoma of the orbit

Subperiosteal haematomas of the orbit are an uncommon cause of proptosis after trauma. Complications include diplopia, persisting mass, and compressive optic neuropathy. Treatment options include observation, needle aspiration, and surgical evacuation. In symptomatic patients without indications for orbital exploration, treatment with needle aspiration is less invasive than surgical drainage. We report a case of a traumatic subperiosteal haematoma successfully treated with needle aspiration, demonstrating that in appropriate patients, needle aspiration can result in resolution of symptoms without a more invasive procedure.

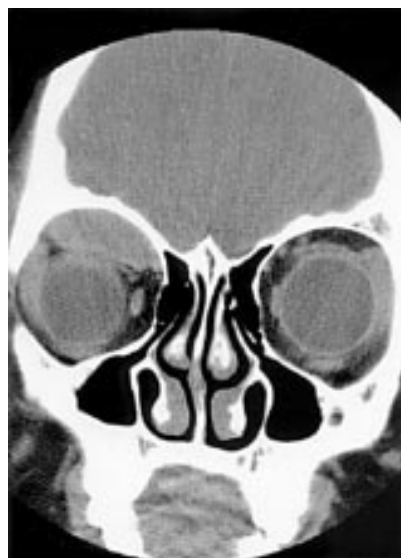

Figure 1 CT scan demonstrates a well circumscribed mass in the right superior orbit.

Case report

A 9 year old girl presented with diplopia 4 days after falling off a fence and striking the right side of her face. She denied decreased visual acuity, eye pain, or previous history of diplopia or proptosis. Her past medical and ocular histories were unremarkable.

On examination, her visual acuity was 6/6 in both eyes. Pupils were equal and reactive with no afferent pupillary defect. Intraocular pressure was normal in both eyes. Her right eye was displaced inferotemporally, and Hertel exophthalmometry showed 3 mm of proptosis of the right eye. The right eye was restricted in upgaze. External examination of the left eye, anterior segment examination of both eyes, and fundus examination of both eyes were normal.

Computed tomography (CT) of the orbits revealed an oval mass along the roof of the right orbit measuring 3.1 cm × 1.1 cm (Fig 1) with no bone discontinuity or fracture. Clinical history and CT were consistent with the diagnosis of subperiosteal haematoma. The patient was observed, and on follow up examination a week later she described increasing diplopia. Her eye continued to be displaced (Fig 2A), and there was restriction in upgaze, medial gaze, and lateral gaze. Treatment was recommended because of progression.

Drainage of the haematoma was performed by needle aspiration.^{1,2} With the patient under general anaesthesia, a 22 gauge, 1.5 inch needle on a syringe was advanced transcutaneously into the superior orbit lateral to the superior orbital notch until blood appeared in the syringe; 7 ml of dark red blood returned. The proptosis immediately resolved. On the first postoperative day, she had no proptosis or diplopia. Visual acuity was 6/6, and extraocular movements were full. She remained asymptomatic with a normal examination (Fig 2B) at the 6 month follow up visit.

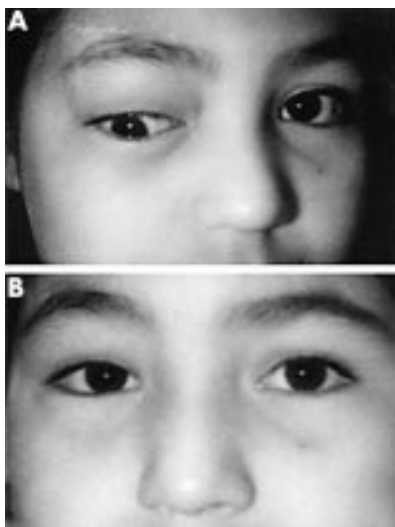


Figure 2 (A) Preoperative photograph shows proptosis and inferotemporal displacement of the right eye. (B) One week postoperative photograph demonstrates resolution of proptosis and displacement.

Comment

Orbital subperiosteal haemorrhages are rare, resulting from rupture of subperiosteal vessels or extension of subgaleal haematomas.^{2,3} Haematomas develop acutely or within days of orbital trauma. Clinical findings include acute proptosis, limitation of motility, and compressive optic neuropathy.³ Chronic complications may occur from infection, expansion, strabismus, choroidal folds, or persisting mass.¹ CT demonstrated a well defined, extraconal, blood dense mass adjacent to an orbital wall. Magnetic resonance imaging identified stages of blood degradation and differentiated blood from neoplasms. Differential diagnosis includes subperiosteal abscess, rhabdomyosarcoma, orbital pseudotumour, lymphangioma, carotid cavernous fistula, arteriovenous malformation, orbital haematoma, or frontal sinus mucocele.

Management options include observation, needle aspiration, and surgical evacuation. Small haemorrhages without decreased vision may be observed for spontaneous resolution. Intervention is recommended for compressive optic neuropathy, progressive proptosis, suspicion of a tumour, or rebleed.³ Drainage has been performed successfully through needle aspiration^{1,2} and surgical evacuation.⁴ Needle aspiration is less invasive, but does not remove clots or stop active bleeding. Orbital exploration allows removal of coagulated blood, drain placement, and fracture repair. In a review of 11 cases in the literature, six patients underwent needle aspiration, four patients underwent surgical evacuation, and one case spontaneously resolved after 6 months.³

Subperiosteal haematoma of the orbit must be considered in the differential diagnosis of unilateral proptosis after trauma. Haematomas can be observed when vision is not threatened. However, early intervention can hasten the resolution of symptoms and prevent chronic complications. Needle aspiration in appropriate cases is a successful and minimally invasive method of treatment.

M C Rojas

Department of Ophthalmology, Stanford University School of Medicine, Stanford, CA, USA

J A Eliason

Division of Ophthalmology, Santa Clara Valley Medical Center, San Jose, CA, USA

D R Fredrick

Department of Ophthalmology, Dartmouth-Hitchcock Medical Center, Lebanon, NH, USA

Correspondence to: Maria C Rojas, MD, Department of Ophthalmology, Stanford University School of Medicine, 300 Pasteur Drive, Suite A157, Stanford, CA 94305, USA; mrojas@pol.net

Accepted for publication 5 November 2001

References

- 1 Wolter JR, Leenhouts JA, Coulthard SW. Clinical picture and management of subperiosteal hematoma of the orbit. *J Pediatr Ophthalmol* 1976;12:136-8.
- 2 Wolter JR. Subperiosteal hematomas of the orbit in young males: a serious complication of trauma or surgery in the eye region. *Trans Am Ophthalmol Soc* 1979;77:104-20.
- 3 Pope-Pegram LD, Hamill MB. Post traumatic subgaleal hematoma with subperiosteal

orbital extension. *Surv Ophthalmol* 1986;**30**:258–62.

- 4 Landa MS, Landa EH, Levine MR. Subperiosteal hematoma of the orbit: case presentation. *Ophthalmic Plast Reconstr Surg* 1998;**14**:189–92.

Stellate tarsoconjunctival lesions in ocular adenoviral infection

Adenoviruses are a prevalent cause of viral conjunctivitis. Infected patients can present with a number of signs and symptoms, with varying degrees of clinical severity. Common examination findings include follicular conjunctivitis, serous discharge, keratitis, preauricular lymphadenopathy, and subconjunctival haemorrhages. Focal tarsal plate lesions have not previously been reported as being a feature of adenoviral conjunctivitis. We describe a case of adenoviral conjunctivitis in which the patient had distinctive stellate tarsal lesions in both eyes.

Case report

A 21 year old man presented with a 1 week history of bilateral red, painful eyes associated with photophobia, blurring of vision, and a mucous discharge. There was no history of respiratory tract infection, genitourinary symptoms or infectious contacts. Best corrected visual acuities were 6/6 bilaterally. On examination he was found to have unusual creamy white stellate lesions on his tarsal plates (Fig 1). These focal lesions were, on average, 1 × 1 mm in size and subepithelial in nature. In addition, both conjunctivae were hyperaemic, subepithelial corneal infiltrates were present, and there was a golden yellow brown mucous discharge.

A clinical diagnosis of adenoviral keratoconjunctivitis was made. The enzyme immunoassay test (Adenoclone, Cambridge Bioscience, Worcester, MA, USA) confirmed the presence of adenovirus in conjunctival swabs. Micro Trak HSV-1/ HSV-2 culture confirmation/typing test (Syva Co, Palo Alto, CA, USA) failed to isolate HSV from either eye and polymerase chain reaction (PCR) to detect *Chlamydia trachomatis* was also negative. No bacterial species were isolated.

The patient was initially treated with topical chlortetracycline ointment four times a day and prednisolone drops three times a day, to each eye. When reviewed 1 week later, there was a marginal improvement in symptoms, although best corrected visual acuities had fallen to 6/9 bilaterally. The topical prednisolone was replaced by fluorometholone and the chlortetracycline was discontinued. Two weeks later, the patient's symptoms had markedly improved and the topical steroid was reduced in frequency and then stopped. The visual acuities had by this time returned to 6/6 in both eyes. However, both the white tarsal

stellate lesions and the corneal subepithelial infiltrates have persisted 2 months after complete resolution of symptoms.

Comment

Corneal subepithelial infiltrates are a known complication of adenoviral conjunctivitis.¹ These lesions usually become apparent within 10–14 days after onset of symptoms and in some cases may persist for months or even years after the acute phase of the infection. Although the opacities gradually fade with time, those associated with reduced visual acuity may require a course of topical corticosteroids. However, return of the opacities can be seen with discontinuation of the corticosteroids.² In cases of prolonged follicular conjunctivitis, equivocal ocular signs, or suspected superimposed infections, specimen culture is an important tool to aid diagnosis.^{3,4}

Although small star-shaped ulcers (herpetic stellites) have been documented as a clinical manifestation seen in herpes simplex eye infections,⁵ these lesions have been confined to the corneal epithelium. To our knowledge, no such lesions have been documented in the tarsoconjunctiva, either in adenoviral or herpes simplex viral conjunctivitis, although pseudomembranes and symblepharon can occur.

S Sarangapani, M C Corbett

The Western Eye Hospital, 171 Marylebone Road, London NW1 5YE, UK

No sponsoring organisations, grants, or commercial interests were associated with this manuscript.

Correspondence to: Dr S Sarangapani; susan.sarangapani@blueyonder.co.uk

Accepted for publication 21 November 2001

References

- Hodge W, Wohl T, Whitcher JP, *et al*. Corneal subepithelial infiltrate recurrence sine adenovirus. *Cornea* 1995;**14**:324–5.
- Petit TH, Holland MM. Chronic keratoconjunctivitis associated with ocular adenovirus infection. *Am J Ophthalmol* 1979;**88**:748–51.
- Uchio E, Takeuchi S, Itoh N, *et al*. Clinical and epidemiological features of acute follicular conjunctivitis with special reference to that caused by herpes simplex virus type 1. *Br J Ophthalmol* 2000;**84**:968–72.
- Mellman-Rubin TL, Kowalski RP, Uhrin M, *et al*. Incidence of adenoviral chlamydial coinfection in acute follicular conjunctivitis. *Am J Ophthalmol* 1995;**119**:652–4.
- Dawson CR, Togni B. Herpes simplex eye infections: clinical manifestations, pathogenesis and management. *Surv Ophthalmol* 1976;**21**:121–35.

Drug induced acute myopia with supraciliary choroidal effusion in a patient with Wegener's granulomatosis

Acute transient myopia with shallowing of the anterior chamber is a rare idiosyncratic response to systemic and topical use of many medications¹ including sulphonamides.² Although many such cases have been reported in the past, they have been relatively rare in recent years. A-scan ultrasonography has been used to measure anterior chamber depth and lens thickness during the myopic phase.³ Ultrasound biomicroscopic (UBM) imaging during the acute phase has only been reported twice.^{4,5} We present a case of drug induced bilateral transient myopia with shallow anterior chambers, where UBM aided in the diagnosis and provided clues to the mechanism responsible for this reaction.

Case report

A 39 year old white woman complained of acute onset of blurry vision and decreased visual acuity at distance starting on the morning of the day she presented to her primary ophthalmologist. On examination by the primary ophthalmologist the patient was found to have a myopic shift of 7.00 dioptres in both eyes and was noted to have narrow angles. She was referred the same day to JD for treatment of bilateral angle closure.

Her medical history was significant for Wegener's granulomatosis diagnosed 1 year earlier and confirmed with a renal biopsy. She had been treated with Cytoxan and prednisone, despite which renal failure ensued. Approximately 4 months before presentation the patient had begun haemodialysis and 1 month before presentation she was started on peritoneal dialysis. The patient was maintained on a regimen of immunosuppressives, which included Cytoxan and prednisone. Twelve hours before presentation, she had received the first dose of Bactrim (160 mg trimethoprim and 800 mg sulphamethoxazole) as prophylaxis for *Pneumocystis carinii*.

Her examination was significant for mild dehydration. The patient had recently noted a negative fluid balance on peritoneal dialysis. The patient had a negative family history for glaucoma and her social history was not contributory. On examination (at approximately 4.30 pm on the day of presentation), visual acuity with her current correction of –6.00 –1.75 × 173° right eye and –4.00 –2.25 × 180° left eye was 20/200 both eyes. Manifest refraction improved visual acuity to 20/20 both eyes with –9.25 –2.00 × 180° right eye and –8.00 –2.25 × 180° left eye. Confrontational visual fields were intact. External examination revealed normal lids in both eyes. Conjunctival chemosis was present in both eyes. Pupils were 4 mm reactive in both eyes with no afferent pupillary defect. Slit lamp examination revealed normal corneas.

Anterior chambers were shallow in both eyes. Goldmann applanation tonometry revealed intraocular pressure (IOP) of 25 mm Hg right eye and 26 mm Hg left eye. Zeiss four mirror gonioscopy was performed and revealed slit angles in both eyes. Indentation gonioscopy opened the angle to +1 right eye. No PAS could be observed. Indentation gonioscopy of the left eye opened the angles slightly more, however only the top of the trabecular meshwork could be visualised. Undilated funduscopic examination with a 90 D lens revealed an intact posterior pole. The optic nerves appeared to have small central cups in both eyes.

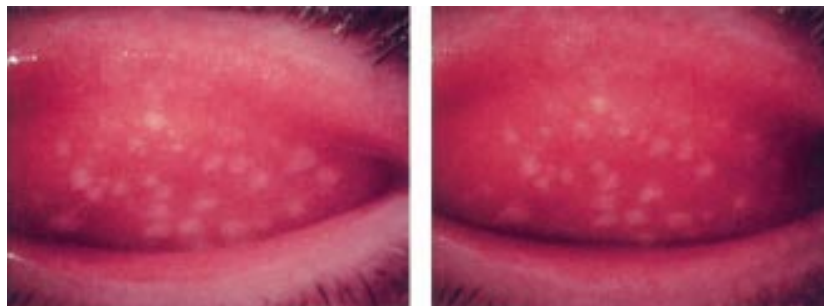

Figure 1 Creamy white stellate lesions on the tarsal plates.

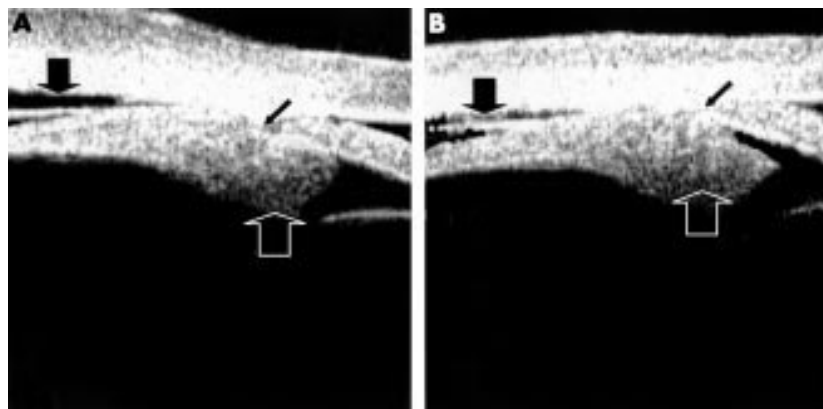


Figure 1 Ultrasound biomicroscopic images ((A) right eye, (B) left eye) of the angle and ciliary body during the acute phase. Anterior chamber angle (thin arrow) almost completely closed. Choroidal effusion (thick arrow) is present. The ciliary body (open arrow) is rotated anteriorly

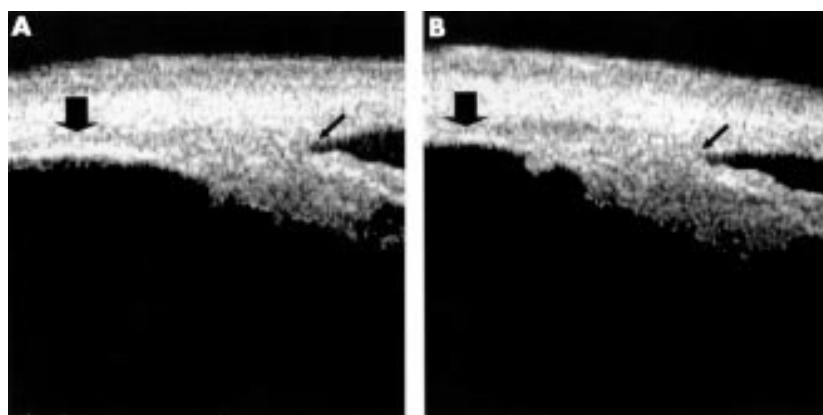


Figure 2 Ultrasound biomicroscopic images ((A) right eye, (B) left eye) of the angle and ciliary body during the convalescent phase. Anterior chamber angle (thin arrow) is now open. No choroidal effusion is present (thick arrow).

UBM was subsequently performed (Fig 1), and confirmed the presence of shallow anterior chambers with narrow angles in both eyes. The angle opening distance (AOD) (distance between the posterior corneal surface and anterior iris surface measured 500 μ m from the scleral spur) was measured on the UBM images according to Pavlin.⁶ AOD was less than 10 μ m in both eyes. In addition, anterior chamber depth (ACD) was measured in one available image right eye and was found to be 1.7 mm. A ciliochoroidal effusion extending in all quadrants was present in both eyes. The ciliary body appeared slightly engorged and rotated anteriorly.

The patient was advised to discontinue Bacrim and was treated with fluorometholone and topical aqueous suppressants. On the following day, the anterior chambers were slightly deeper and the myopic shift was now only 2.25D. This further decreased over the following days with progressive deepening of the anterior chamber. One week after discontinuation of Bacrim, the patient's visual acuity was 20/20 in both eyes with her old prescription. Zeiss four mirror gonioscopy revealed grade IV open angles with some very fine PAS in the inferior angle in both eyes. Goldmann applanation tonometry revealed IOP of 10 mm Hg in both eyes off aqueous suppressants. UBM was repeated (Fig 2), confirming complete resolution of the choroidal effusion and significant reduction in the size

of the ciliary body. AOD was 203 μ m right eye and 240 μ m left eye. Dilated fundus examination revealed normal periphery, normal discs with a cup to disc ratio approximately of 0.2 both eyes, and normal maculas in both eyes.

Comment

We report a case of acute transient myopia in a patient with renal failure secondary to Wegener's granulomatosis, treated with sulphonamides. The development of acute myopia in patients with renal failure from nephropathia epidemica (NE) cause by the Puumala virus has been documented.⁷ NE is the most common systemic condition associated with acute transient myopia. The Puumala virus multiplies in capillary endothelial cells, causing endothelial wall damage and increased capillary permeability to plasma and red blood cells. Leaky capillaries lead to ciliary body oedema and subsequent forward displacement of the iris-lens diaphragm, which is responsible for acute myopia, shallowing of the anterior chamber, and acute angle closure.

To our knowledge acute myopia and ciliary body oedema due to renal failure has not been described as an ocular manifestation of Wegener's granulomatosis, or as a direct consequence of acute renal failure in the presence of Wegener's granulomatosis. The onset of increased myopia immediately after the initiation of sulphonamide therapy and the resolution of symptoms after discontinuation of

Bacrim points to a causative relation between these agents and the acute myopic shift seen in our patient. Although a relation between Wegener's granulomatosis and the development of acute myopia cannot be completely ruled out, such a relation is unlikely. Nevertheless, one cannot rule out a possible interaction between the use of sulphonamides and any effects of Wegener's granulomatosis in the eye.

Transient myopia is a rare idiosyncratic reaction to systemic administration of sulphonamides. The myopic shift is usually bilateral and is completely reversible after discontinuation of the sulphonamide therapy. Various degrees of anterior chamber shallowing and angle narrowing have been reported. The proposed mechanisms responsible for this myopic shift are: (1) spasm of accommodation, (2) lens oedema, (3) ciliary body oedema with associated choroidal effusion.⁸

Of these proposed mechanisms, spasm of accommodation is the most unlikely, as cycloplegic instillation almost never abolishes the refractive error change in medication induced acute transient myopia.

Lens oedema can be partially responsible for the drug induced acute myopic shift. Such oedema can theoretically occur from osmotic changes or metabolic alterations produced by sulphonamides.⁹ However, lens oedema is not present in all cases of sulpha drug and other drug induced acute myopia.¹⁰ Even when lens oedema is present, it cannot always fully explain the change in refraction, which is sometimes up to 7 dioptres,⁸ and the degree of anterior chamber shallowing in some patients.³

Although we cannot completely rule out lens oedema as a possible mechanism, as we did not perform A-scan measurements, we believe that the anterior rotation and oedema of the ciliary body causing an anterior movement of the lens can fully explain the myopic shift seen in our patient.

The UBM images support this proposed mechanism for the pathogenesis of acute drug induced myopia. The oedematous ciliary body became anteriorly rotated secondary to a choroidal effusion. This caused anterior movement of the lens-iris diaphragm with subsequent narrowing of the angle. Oedema of the ciliary processes might have also caused relaxation of the zonules leading to an increase in lens thickness and forward displacement of the anterior lens surface further into the anterior chamber. AOD (a measure of angle dimensions) decreased almost to zero during the acute attack for our patient. In addition, ACD in the right eye was significantly decreased to only 1.7 mm. Upon resolution of the symptoms, AOD returned to what is considered to be a normal range (normal range 185–665 μ m).¹¹

This is the third reported case of acute myopia where ultrasound biomicroscopy has aided in the diagnosis of this extremely rare drug reaction. Although, this condition generally has a benign course if recognised early, it can potentially have devastating consequences if left untreated or misdiagnosed as primary angle closure glaucoma. Physicians should be aware of this side effect of sulphonamides and their derivatives and warn patients to report changes in their vision when initiating therapy with such agents.

Acknowledgements

Support: Eye Bank for Sight Restoration Glaucoma Research and Training Fund, unrestricted fund from Research to Prevent Blindness, May and Samuel Rudin Foundation, Inc.

J C Ramos-Esteban, S Goldberg,
J Danias

Department of Ophthalmology, Mount Sinai School
of Medicine, One Gustave L Levy Place, Box 1183,
New York, NY 10029-6574, USA

Correspondence to: John Danias, MD, PhD;
john.danias@mssm.edu

Accepted for publication 5 December 2001

References

- 1 Grant WM, Schuman JS. *Toxicology of the eye*. Springfield, IL: Charles C Thomas. 1993;4:22-4.
- 2 Wagener HP. Toxic effects of sulfonamides on the eyes. *Am J Med Sci* 1943;206:261-8
- 3 Grinbaum A, Ashkenazi I, Gutman I, et al. Suggested mechanism for acute transient myopia after sulfonamide treatment. *Ann Ophthalmol* 1993;25:224-6.
- 4 Postel EA, Assalian A, Epstein DL. Drug-induced transient myopia and angle-closure glaucoma associated with supraciliary choroidal effusion. *Am J Ophthalmol* 1993;122:110-12.
- 5 Sankar PS, Pasquale LR, Grosskreutz CL. Uveal effusion and secondary angle-closure glaucoma associated with topiramate use. *Arch Ophthalmol* 2001;119:1210.
- 6 Pavling CJ, Foster FS. Ultrasound biomicroscopy of the eye. *Acta Ophthalmol* 1992;204:S7-9.
- 7 Lontkanen M, Puustjarvi T, Kauppi P, et al. Ocular characteristics in nephropathia epidemica or Puumala virus infection. *Acta Ophthalmol Scand* 1996;74:621-5.
- 8 Muirhead JF, Scheie HG. Transient myopia after acetazolamide. *Arch Ophthalmol* 1960;63:315-18.
- 9 Alvaro ME. Effects other than anti-infectious of sulfonamide compounds on eye. *Arch Ophthalmol* 1943;29:615.
- 10 Bovino JA, Marcus DF. The mechanism of transient myopia induced by sulfonamide therapy. *Am J Ophthalmol* 1982;94:99-102.
- 11 Lo Presti L, Morgese A, Ravot M, et al. Ultrabiomicroscopic study of the effects of brimonidine, apraclonidine, latanoprost and ipopamine on the chamber angle and ciliary body. *Acta Ophthalmol Scand (Suppl)* 1998;227:32-4.

Cutaneous presentation of orbital follicular lymphoma: clinical differential diagnosis with lymphocytoma cutis

Cutaneous involvement from primary orbital lymphoma is uncommon. We report a patient with follicular lymphoma of the orbit who presented initially with cutaneous lesions clinically resembling lymphocytoma cutis which subsequently proved to be metastasis from the orbit.

Case report

A 75 year old woman presented to the dermatologist with a 6-7 month history of lumps on the right and left ears. Examination revealed two soft erythematous nodules, 2-3 cm in diameter behind the right ear and similar symmetrical lesions in both conchal bowls (Fig 1). There was no lymphadenopathy or hepatosplenomegaly. Full clinical examination, chest x ray, full blood counts, erythrocyte sedimentation rate, U&E, and liver function tests were normal. A biopsy was performed. The clinical impression was that of lymphocytoma cutis and the lesions were treated with intralesional steroids resulting in prompt resolution leaving behind only flat discoloured areas. However, histology showed a nodular dermal lymphoid infiltrate of centrocyte-like cells with only scanty scattered blasts. Immunophenotypically, the lesional cells were of B cell phenotype (CD20+,

CD79a+, CD10+, bcl6+, CD5-, CD43-, CD23-), overall in keeping with follicular lymphoma, grade 1. On staging investigations there was no evidence of lymphoma in other sites and the lesions were deemed to represent primary cutaneous disease.

Three months later the patient developed progressively enlarging conjunctival lesions near the medial canthus in both eyes (Fig 2A). On examination she had bilateral subconjunctival fleshy lesions measuring about 5 mm. A computed tomograph (CT) scan showed a mass in the inferomedial aspects of the right orbit, extending down the nasolacrimal duct to the nasal cavity and a soft tissue mass confined to left orbit (Fig 2B). The lesion was biopsied and histologically showed features identical to those in the biopsy of the skin lesion: sheets of centrocytes with scanty centroblasts. On immunoassay both the cutaneous and the orbital tumours showed the same immunophenotype (CD20+, CD10+, bcl6+, bcl2+, MT2+, CD5-, CD23, CD43-) in keeping with grade 1 follicular lymphoma. Polymerase chain reaction (PCR) analysis with primers for immunoglobulin heavy chain rearrangement revealed a prominent monoclonal band in an oligoclonal background. The initial biopsy of the cutaneous lesion on PCR analysis showed a monoclonal band of the same molecular weight. Staging confirmed this to be localised to the orbit but later another plaque-like cutaneous lesion (1 cm in diameter) appeared on her forehead with the same histological, immunophenotypic, and molecular genetic features. The patient was commenced on chlorambucil chemotherapy with prompt resolution of the orbital and cutaneous lesions. She remains well at 18 months of follow up.

Comment

In this unusual case of orbital lymphoma the initial presentation was in the skin. On clinical examination the cutaneous changes were deemed to represent lymphocytoma cutis. The term lymphocytoma cutis stands for a highly heterogeneous group of reactive lymphoid proliferations in the skin. These include

Borrelia burgdorferi associated lesions,¹ post-zoster scar reactions,² trauma,^{3,4} and those of unknown aetiology.^{3,4} Clinically, they are characterised by flesh coloured to plum red dermal and subcutaneous nodules and plaques as in our case. They can be solitary or multiple. It is more common females (F:M = 3:1),³ mostly involving the face (70%). Lymphocytoma cutis has also been reported with conjunctival lesions.⁵ We would like to stress that despite typical clinical appearance before diagnosis of lymphocytoma cutis is made, full pathological investigation with immunophenotyping and molecular genetic clonality analysis is essential.

In the interval before the clinical appearance of the orbital tumours in our patient the cutaneous lesions were considered to represent a primary follicular lymphoma at this site. This accounts for 10% of cutaneous B cell neoplasms and follows a very indolent clinical course during which it remains confined to the skin.⁶ Distinction between primary and secondary involvement is of paramount importance. Secondary cutaneous involvement by follicular lymphoma is not associated with such a favourable prognosis. Morphologically there is no difference between the two; however, the primary cutaneous type is usually bcl-2 negative on immunostaining and the t (14; 18) is hardly ever found. It is therefore regarded by some authors as part of the spectrum of cutaneous marginal zone lymphomas⁶ rather than follicular lymphoma.

At clinical presentation of the orbital tumours in our patient, as recommended by EORTC⁷ the lesions in the skin were deemed to represent secondary involvement from the primary site in the orbit though orbital lesions were recognised later. On PCR analysis for B cell clonality it was apparent that the two lesions represented the same tumour. Follicular lymphoma in the orbit accounts for 20%-33%⁸ of all lymphomas in this site. Its pathological features in the orbit are no

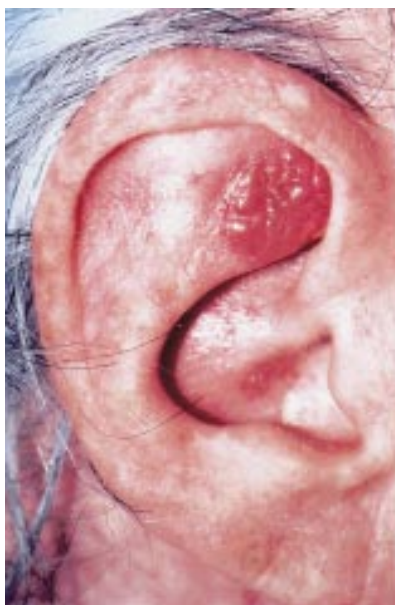

Figure 1 Photograph showing nodule in right conchal bowl with subconjunctival lesion.

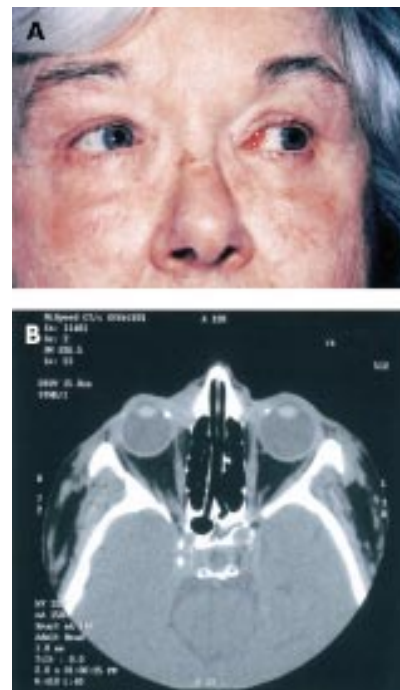


Figure 2 (A) Photograph showing subconjunctival lesion. (B) CT scan showing orbital involvement.

different from the lymph node counterparts and, unlike those in the skin, are bcl-2 positive and bare the t (14; 18). Early extraorbital spread is regarded a sign of more aggressive behaviour and a potential indicator for poorer prognosis. Secondary cutaneous involvement from a primary orbital lymphoma is an uncommon event with only one case described in the literature⁹ while the primary cutaneous lymphomas occurs more frequently.¹⁰

**R Goyal, R J Motley, S D Dojcinov,
C M Lane**

Department of Ophthalmology, Pathology and Dermatology, University Hospital of Wales, Cardiff, UK

Correspondence to: Mrs R Goyal
Accepted for publication 17 December 2001

References

- 1 **Albrecht S**, Hofstadter S, Artsob H, *et al*. Lymphadenosis benigna cutis resulting from Borrelia infection (Borrelia lymphocytoma). *J Am Acad Dermatol* 1991;**24**:621–5.
- 2 **Roo E**, Villegas C, Lopez-Bran E, *et al*. Postzoster cutaneous pseudolymphoma. *Arch Dermatol* 1994;**130**:661–3.
- 3 **Brodell RT**, Santa Cruz DJ. Cutaneous pseudolymphomas. *Dermatol Clin* 1985;**3**:719–34.
- 4 **Ploysangam T**, Breneman DL, Mutasim DF. Cutaneous pseudolymphomas. *J Am Acad Dermatol* 1998;**38**(6 Pt 1):877–95; quiz 896–7.
- 5 **Scarbrick JJ**, Orchard G, Russell-Jones R. Lymphocytoma cutis with conjunctival lesions. *Br J Ophthalmol* 1999;**83**:882.
- 6 **Kempf W**, Dummer R, Burg G. Approach to lymphoproliferative infiltrates of the skin. The difficult lesions. *Am J Clin Pathol* 1999;**111**(1 Suppl 1):S84–93.
- 7 **Willemze R**, Kerl H, Sterry W, *et al*. EORTC classification for primary cutaneous lymphomas: a proposal from the Cutaneous Lymphoma Study Group of the European Organization for Research and Treatment of Cancer. *Blood* 1997;**90**:354–71.
- 8 **Medeiros LJ**, Harris NL. Lymphoid infiltrates of the orbit and conjunctiva. A morphologic and immunophenotypic study of 99 cases. *Am J Surg Pathol* 1989;**13**:459–71.
- 9 **Jampol LM**, Marsh JC, Albert DM, *et al*. IgA associated lymphoplasmacytic tumor involving the conjunctiva, eyelid, and orbit. *Am J Ophthalmol* 1975;**79**:279–84.
- 10 **De la Fouchardiere A**, Balme B, Chouvet B, *et al*. Primary cutaneous marginal zone B-cell lymphoma: a report of 9 cases. *J Am Acad Dermatol* 1999;**41**(2 Pt 1):181–8.

NOTICES

Childhood blindness

The latest issue of *Community Eye Health* (No 40) discusses new issues in childhood blindness, with an editorial by Clare Gilbert, senior lecturer at the International Centre for Eye

Health. For further information please contact: Journal of Community Eye Health, International Centre for Eye Health, Institute of Ophthalmology, 11–43 Bath Street, London EC1V 9EL, UK (tel: +44 (0)20 7608 6910; fax: +44 (0)20 7250 3207; email: eyeresource@ucl.ac.uk; website: www.jceh.co.uk). Annual subscription (4 issues) UK£25/US\$40. Free to workers in developing countries.

International Centre for Eye Health

The International Centre for Eye Health has published a new edition of the *Standard List of Medicines, Equipment, Instruments and Optical Supplies* (2001) for eye care services in developing countries. It is compiled by the Task Force of the International Agency for the Prevention of Blindness. Further details: Sue Stevens, International Centre for Eye Health, 11–43 Bath Street, London EC1V 9EL, UK (tel: +44 (0)20 7608 6910; email: eyeresource@ucl.ac.uk).

Second Sight

Second Sight, a UK based charity whose aims are to eliminate the backlog of cataract blind in India by the year 2020 and to establish strong links between Indian and British ophthalmologists, is regularly sending volunteer surgeons to India. Details can be found at the charity website (www.secondsight.org.uk) or by contacting Dr Lucy Mathen (lucymathen@yahoo.com).

Specific Eye Conditions (SPECS)

Specific Eye ConditionS (SPECS) is a not for profit organisation which acts as an umbrella organisation for support groups of any conditions or syndrome with an integral eye disorder. SPECS represents over fifty different organisations related to eye disorders ranging from conditions that are relatively common to very rare syndromes. We also include groups who offer support of a more general nature to visually impaired and blind people. Support groups meet regularly in the Boardroom at Moorfields Eye Hospital to offer support to each other, share experiences and explore new ways of working together. The web site www.eyecconditions.org.uk acts as a portal giving direct access to support groups own sites. The SPECS web page is a valuable resource for professionals and may also be of interest to people with a visual impairment or who are blind. For further details about SPECS contact: Kay Parkinson, SPECS Development Officer (tel: +44 (0)1803 524238; email: k@eyeconditions.org.uk; www.eyecconditions.org.uk).

12th Meeting of the European Association for the Study of Diabetic Eye Complications (EASDEC)

The 12th meeting of the EASDEC will be held on 24–26 May 2002 in Udine, Italy. The dead-

line for abstracts is 15 February 2002. Three travel grants for young members (less than 35 years of age at the time of the meeting) are available. For information on the travel grants, please contact Pr CD Agardh, President of EASDEC, Malmö University Hospital, SE-205 02 Malmö, Sweden (tel +46 40 33 10 16; fax: +46 40 33 73 66; email: carl-david.agardh@endo.mas.lu.se). Further details: NORD EST CONGRESSI, Via Aquilea, 21.–33100 Udine, Italy (tel: +30 0432 21391; fax: +39 0432 50687; email: nordest.congressi@ud.nettuno.it)

3rd Interdisciplinary Symposium on the Treatment of Autoimmune Disorders

The 3rd Interdisciplinary Symposium on the Treatment of Autoimmune Disorders will be held in Leipzig, Germany on the 6–8 June 2002. Topics to be covered include: basic aspects of autoimmune diseases, experimental therapeutic concepts, and clinical studies providing novel concepts or novel focus on established therapies. There will also be the presentation of the Nils-Ilja-Richter Award (application deadline is April 2002, further details on the web site). Further details: Prof. Dr. med. Michael Sticherline, Department of Dermatology, University of Leipzig (email: sticm@medizin.uni-leipzig.de; website: www.autoimmun.org); Fördergesellschaft zur Therapie von Autoimmunerkrankungen e.V. (email: autoimmun.org@gmx.de)

International Society for Behçet's Disease

The 10th International Congress on Behçet's Disease will be held in Berlin 27–29 June 2002. Further details: Professor Ch Zouboulis (email: zoubbere@zedat.fu-berlin.de).

Singapore National Eye Centre 5th International Meeting

The Singapore National Eye Centre 5th International Meeting will be held on 3–5 August 2002 in Singapore. Further details: Ms Amy Lim, Organising Secretariat, Singapore National Eye Centre, 11 Third Hospital Avenue, Singapore 168751 (tel: (65) 322 8374; fax: (65) 227 7290; email: Amy_Lim@snecc.com.sg).

BEAVRS Meeting

The next BEAVRS meeting will be held in the Dalmahoy Hotel near Edinburgh on 31 October to 1 November 2002. Further details: Susan Campbell, Medical Secretary, Gartnavel General Hospital (email: susan.j.campbell.wg@northglasgow.scot.nhs.uk).



Needle aspiration of a traumatic subperiosteal haematoma of the orbit

M C Rojas, J A Eliason and D R Fredrick

Br J Ophthalmol 2002 86: 593-594

doi: 10.1136/bjo.86.5.593

Updated information and services can be found at:

<http://bjo.bmj.com/content/86/5/593.full.html>

References

These include:

This article cites 3 articles

<http://bjo.bmj.com/content/86/5/593.full.html#ref-list-1>

Email alerting service

Receive free email alerts when new articles cite this article. Sign up in the box at the top right corner of the online article.

Notes

To request permissions go to:

<http://group.bmj.com/group/rights-licensing/permissions>

To order reprints go to:

<http://journals.bmj.com/cgi/reprintform>

To subscribe to BMJ go to:

<http://group.bmj.com/subscribe/>