

## SCIENTIFIC CORRESPONDENCE

## 20 MHz high frequency ultrasound assessment of scleral and intraocular conjunctival squamous cell carcinoma

D H Char, G Kundert, R Bove, J B Crawford

*Br J Ophthalmol* 2002;**86**:632–635

**Aim:** To assess in a prospective manner, high frequency ultrasound diagnosis of deep invasion by conjunctival squamous cell carcinoma.

**Methods:** Prospective, non-randomised case series comparing 20 MHz high frequency ultrasonographic and clinicopathological data.

**Results:** 20 MHz high frequency ultrasound delineated the degree of deep involvement of this tumour into the sclera, globe, and orbit. The results of ultrasonography correlated with the clinicopathological results.

**Conclusions:** High frequency ultrasound is a useful diagnostic adjunctive test in patients with possible deep involvement by a conjunctival squamous cell carcinoma.

Conjunctival squamous carcinoma usually originates at the limbus. Most cases remain superficial to the sclera and rarely infiltrate beneath Bowman's membrane of the cornea. Intraocular invasion by conjunctival squamous cell carcinoma is uncommon and is noted in less than 5% of cases in first world countries.<sup>1,2</sup>

Before surgery, detection of scleral or intraocular invasion by squamous cell carcinoma is often not appreciated. Several clinical findings are suggestive of invasion into the globe or orbit, including an associated scleritis, broad based synechiae, anterior chamber cells, a contiguous intraocular mass, or spontaneous perforation of the globe.<sup>1-3</sup> The delineation of conjunctival squamous cell carcinoma invasiveness is important since it alters clinical management. Most of these tumours remain superficial to both sclera and Bowman's membrane; they can be stripped off, and with both frozen section control of horizontal margins and adjunctive cryotherapy result in more than 98% local tumour control.<sup>2</sup> In tumours that invade the eye, some can be salvaged with good vision, although most of those eyes are lost.<sup>1</sup> In cases with invasion into the orbit or those that diffusely involve the globe an anterior exenteration is required.

High frequency ultrasound, using between 20–100 MHz transducers, has been used to demonstrate several anatomical anterior segment details.<sup>4,5</sup> Higher frequency units achieve greater resolution (twofold to 10-fold depending on the MHz rating of the transducer) than the standard ophthalmic 10

MHz systems, with the disadvantage of shorter tissue penetration of the diagnostic beam.<sup>6</sup> We have performed a non-randomised prospective study to assess, with a 20 MHz commercially available unit, possible deep invasion before surgery, in cases of suspected orbital or intraocular invasion by conjunctival carcinoma.

## METHODS

We recently managed four patients with possibly highly invasive squamous cell carcinoma of the conjunctiva. All had high frequency ultrasound, using an I<sup>3</sup> system (Sacramento, CA, USA), as part of their preoperative evaluation. This commercially available unit uses a 20 MHz transducer that produces an approximately twofold increased resolution compared to a standard ophthalmic ultrasound device. In two patients, there were no findings of intraocular invasion but the possibility of scleral and orbital involvement was raised on clinical examination of one of these patients. In patients 3 and 4, there was a high clinical likelihood of intraocular invasion; both had an area of broad based anterior synechiae in the area of superficial tumour with the pupil "peaked" in that direction. Neither of these latter two patients had an obvious intraocular mass on clinical examination. Pertinent clinical features of these four patients are shown in Table 1.

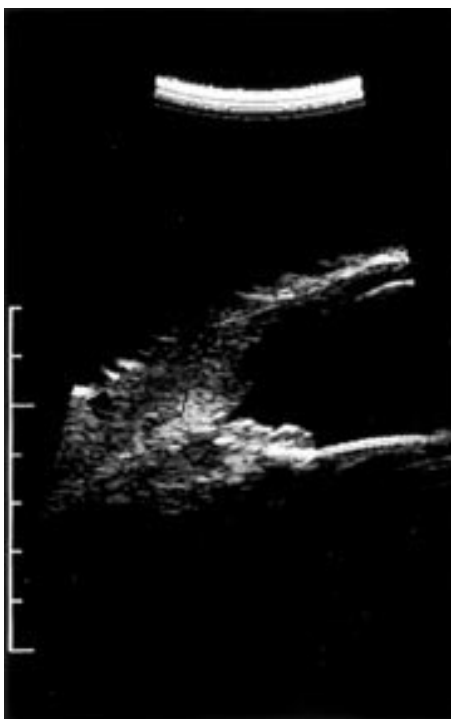
All patients were scanned in a supine position using a standoff, balloon contained, fluid immersion system. We had previously observed (unpublished data) that the balloon system appeared to give us at least as good photographs as fluid contained directly over the eye if the bubbles are carefully removed from the fluid-ultrasound interface. Two directional B-scan images were obtained in the ocular area of involvement, adjacent to it and 180 degrees away from the tumour. Ultrasonographic, clinical, and pathological data were analysed.

## RESULTS

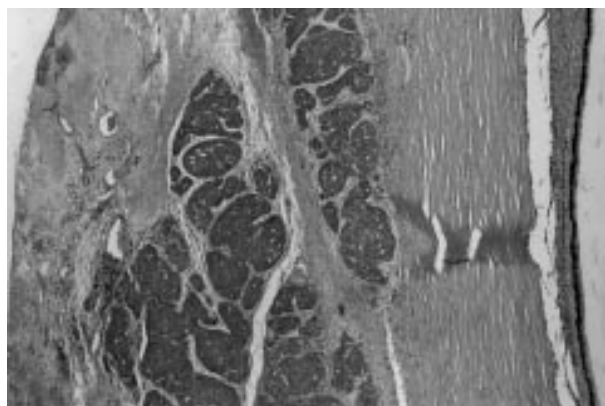
Patient 1 was referred for possible deep invasion from a conjunctival squamous cell carcinoma. There was no evidence of either intraocular or scleral invasion on high frequency ultrasound, and these findings mirrored the pathological diagnosis of invasive squamous cell carcinoma confined to the conjunctiva. The lesion was treated with conventional management, (resection with frozen section control and cryotherapy) and it has not recurred.

Table 1 Clinical features

Patient	Age	Clock hours involved	Preoperative visual acuity	Anterior synechiae	Diffuse scleral involvement
1	66	5:30–9:00	20/25	–	–
2	57	12	20/40	–	+
3	31	8:00–2:30	20/200	+	–
4	80	6:00–10:00	20/50	+	–

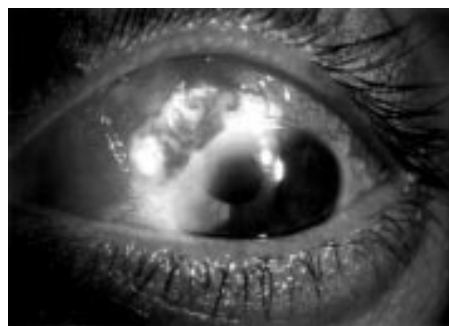

**Figure 1** 20 MHz high frequency ultrasound demonstrates approximately a doubling of normal scleral (open arrow) and episcleral (solid arrow) thickness in case 2. As shown in Figure 2 this increase was mainly due to tumour invasion.

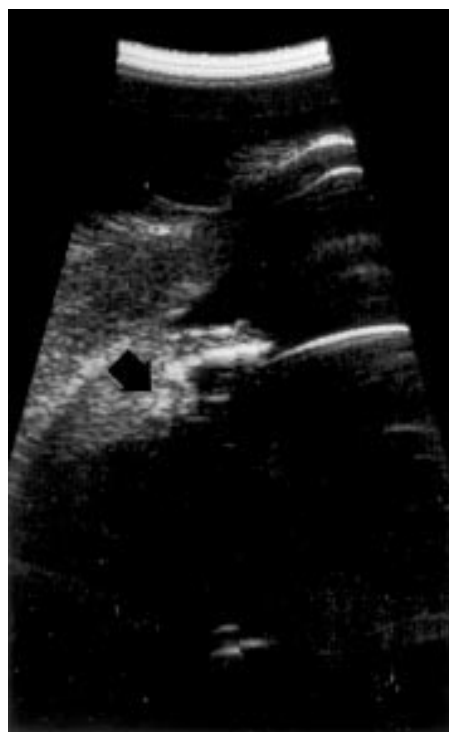

**Figure 2** Case 2 had an area of 360 degrees of scleral involvement by the squamous cell carcinoma (10 $\times$ ). In addition to the carcinoma, which produced approximately three quarters of the increased scleral and episcleral thickness, there is fibrosis and some inflammation.

In patient 2, the initial diagnosis was uncertain. He was managed elsewhere with a presumptive diagnosis of an atypical, diffuse scleritis, but when it did not respond to oral corticosteroids, a biopsy was obtained that demonstrated full thickness conjunctival squamous cell carcinoma. We saw the patient in consultation. He had a diffuse inflammation of the bulbar conjunctiva and sclera without an obvious mass. On high frequency ultrasound there was diffuse scleral thickening (Fig 1). On full thickness conjunctival map biopsies no residual tumour was noted, but the scleral surface had an atypically fibrotic component and biopsies from multiple sites circumferentially in the area just anterior to the muscle insertions demonstrated carcinoma. He had an anterior lid sparing exenteration. Histological examination showed episcleral involvement of this neoplasm for 360 degrees and secondary inflammatory scleritis (Fig 2).

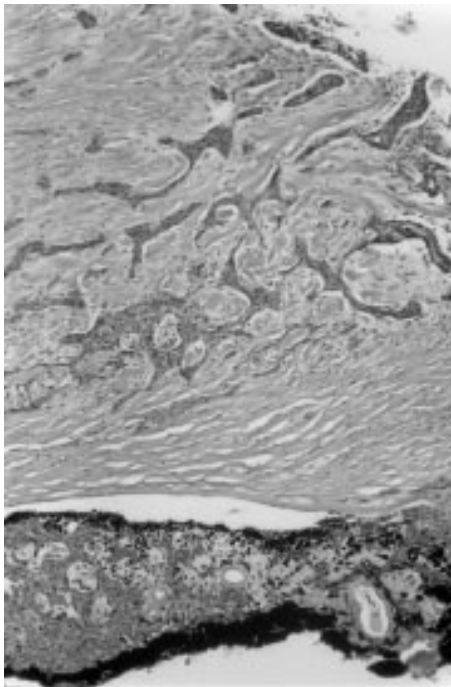


**Figure 3** Clinical photograph of case 3 with widespread conjunctival-scleral tumour involvement. There was intraocular penetration of the tumour with a broad based anterior synechia; the latter finding was not evident in the photograph.

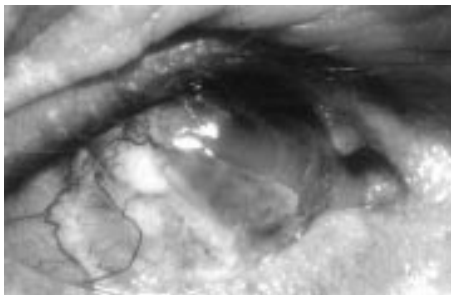


**Figure 4** 20 MHz high frequency ultrasound demonstrates tumour invasion into the ciliary body with thickening of both structures (arrow).

Patient 3 was managed elsewhere with an atypical area of presumed scleritis. He was also placed on high dose oral corticosteroids without effect. He developed an area of presumed scleral loss near the limbus and we were asked to manage his care. The patient had a large superficial tumour with clinical evidence of intraocular invasion (Fig 3). High frequency ultrasound also demonstrated invasion into the anterior uvea (Fig 4). It was elected to try to resect the tumour and retain the globe. Using frozen section control the conjunctiva and sclera from approximately 8 o'clock, clockwise, to 2 o'clock was resected. A 5 clock hour iris-ciliary body-choroidal resection, with removal of 3 mm of distal cornea, was performed. The eye was reconstructed using a large allogeneic scleral graft. An autologous buccal membrane graft was used to cover the conjunctival defect. Unfortunately, permanent sections showed invasion of a squamous cell carcinoma, both to the surgical line of corneal resection and the edge of the uveal resection (Fig 5). The eye was removed in a latter procedure.



**Figure 5** Corneal involvement at the scleral margin, approximately 3 mm from the limbus (10 $\times$ ). In retrospect, we felt that the ultrasound showed some slight thickening of the cornea in that area but we were not able to make that diagnosis before resection.

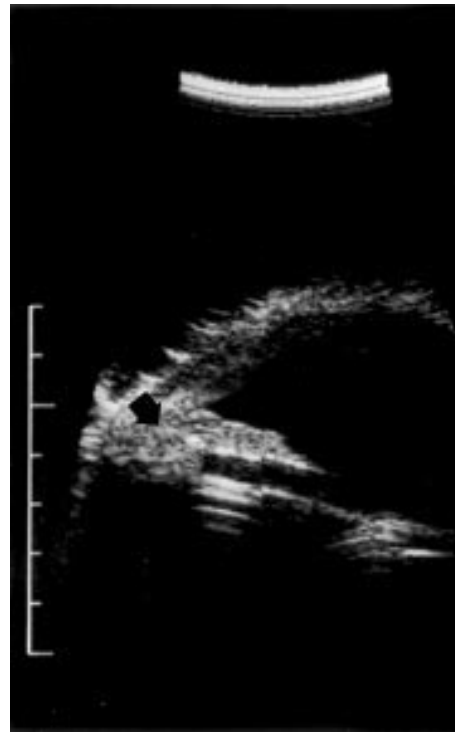


**Figure 6** Intraocular invasion by a squamous cell carcinoma that had undergone several previous resections. Note the scleral thinning.

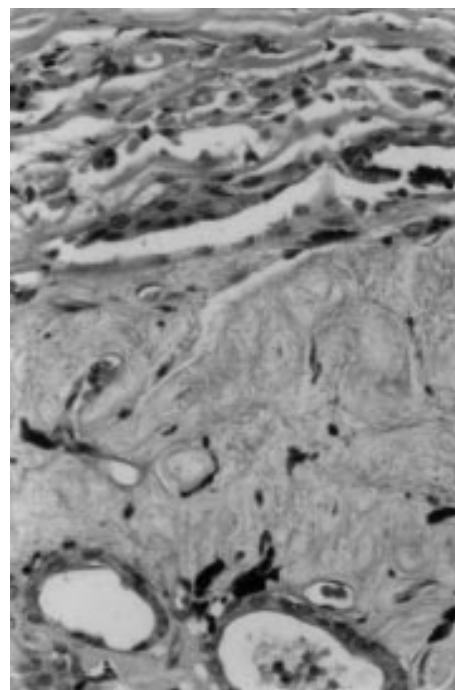
Patient 4 had multiple recurrences of a temporal limbal “atypical pterygium.” Approximately 6 months previously a biopsy demonstrated squamous cell carcinoma; that conjunctival area was removed and treated with cryotherapy. Unfortunately he presented with a 2 month history of recurrent mass and marked thinning of sclera in that area with a peaked pupil towards the area of involvement (Fig 6). We were then asked to manage his care. High frequency ultrasound was suggestive of intraocular invasion by the tumour (Fig 7). Surgically free conjunctival and scleral margins were obtained with frozen section control between 5 and 9.30 clock hours. A smaller sclera-iris-ciliary body resection was performed in the area of involvement (Fig 8) and the eye was reconstructed with a free allogeneic scleral graft and an overlying autologous buccal membrane graft. Histological assessment of the uveal tissue demonstrated an invasive mucoepidermoid conjunctival carcinoma with clear margins.

## DISCUSSION

Conjunctival squamous cell carcinoma usually presents in older patients as a superficial tumour that is readily diagnosed and treated with retention of the eye.<sup>3</sup> In less than 5% of cases there is invasion into sclera, globe, or orbit.<sup>1, 2, 7-11</sup>



**Figure 7** High frequency ultrasound of a patient with probable intraocular invasion. The ciliary body is enlarged as well as there being slight thickening of the iris root (arrow). These structures are >50% larger than those 180 degrees away from the area of involvement.



**Figure 8** Tumour invading the sclera, iris, and angle in case 4 (10 $\times$ ).

The reasons for deep invasion of a conjunctival carcinoma are varied.<sup>1-3</sup> Rarely, cases are misdiagnosed as a benign process and a long delay in diagnosis may result in invasion. More commonly we have noted invasion in association with two variant processes. One, in patients in which the tumour

produces a necrotising scleritis, such as in case 3, we and others have noted intraocular invasion.<sup>3 12 13</sup> In our case, as well as a previous ones in the literature, this constellation of findings may be associated with human immunodeficiency syndrome.<sup>13</sup> As reviewed elsewhere, when a patient presents with conjunctival carcinoma at less than 50 years old, the possibility of HIV disease should be explored.<sup>3</sup> In case 3, there was no history of risk factors or symptoms of HIV disease, but we tested for and established that diagnosis because of the relatively young age of the patient. Two, in either spindle cell or mucoepidermoid variants of conjunctival carcinoma there is a higher incidence of more aggressive disease than conventional squamous cell carcinoma.<sup>14-22</sup> Several of these reports document a much higher incidence of deep invasion than is observed with squamous cell carcinoma. In case 4, the mucoepidermoid pathology noted intraocularly, compared with the previous superficial resections, would be consistent with these previous reports.

In these relatively uncommon cases of orbital or intraocular involvement, both the diagnosis of conjunctival carcinoma as well as delineation of deep invasion can be difficult; this is evident by the delay in diagnosis of several months for cases 2 and 3 that were managed in excellent centres. As has been cited by many authors, the possibility of a masquerade syndrome should be raised in a patient with chronic diffuse, unilateral scleritis, especially if there are no systemic risk factors such as rheumatological diseases.<sup>23</sup>

The utility of high frequency ultrasound in the evaluation of most squamous cell carcinomas of the conjunctiva is limited. The vast majority of conjunctival carcinomas do not produce orbital or intraocular invasion and do not require this type of study. In patients with possible invasion, high frequency ultrasound is useful to substantiate the clinical impression. This ancillary technique is probably most useful in centres that do not manage a large number of patients with this disease. In each case the adjuvant use of high frequency ultrasound combined with the clinical data allowed us to predict whether or not deep involvement was present. Several caveats apply. Since this was a prospective study, it is unlikely that observer bias entered into the results. It is, however, a very small series, and we do not know what is the lower limit of sensitivity of this technique for detecting either scleral or intraocular penetration. It is also uncertain how accurate this ancillary diagnostic technique is, either to distinguish other forms of scleral or uveal tract involvement from carcinoma, or to determine the boundaries of invasion. The latter point was germane in that while we were able to salvage the eye in case 4, we were not aware, based on ultrasound data, what the precise extent of intraocular or deep corneal involvement was in case 3. The eye had to be removed when the extent of the tumour was demonstrated histologically. Probably the latter issue is a result of the diffusely invasive nature of this tumour. In contrast, several groups have documented that high frequency ultrasound is relatively accurate at assessment of margins of focal tumours such as melanomas or benign cystic lesions.<sup>24-26</sup>

Several investigators have demonstrated that intraocular tumours can be imaged with high frequency ultrasound. Similar to those reports we have also now shown that invasive squamous cell carcinoma can be imaged when it invades the globe; however, the tissue type diagnostic accuracy of this technique remains unclear.

## ACKNOWLEDGEMENTS

Supported in part by a grant from the Tumori Foundation (DHC, GK, RB) and University of San Francisco, California (JBC).

## Authors' affiliations

**D H Char**, Stanford University and Tumori Foundation, CA 94114, USA  
**G Kunderl**, **R Bove**, Tumori Foundation, CA, USA  
**J B Crawford**, UCSF, CA, USA

Correspondence to: Devron H Char, MD, Tumori Foundation, 45 Castro Street, Suite 309, San Francisco, CA 94114, USA; [devron@tumori.org](mailto:devron@tumori.org)

Accepted for publication 17 January 2002

## REFERENCES

- 1 **Char DH**, Crawford JB, Howes EL Jr, *et al*. Resection of intraocular squamous cell carcinoma. *Br J Ophthalmol* 1992;**76**:123-5.
- 2 **Tunc M**, Char DH, Crawford JB, *et al*. Intraepithelial and invasive squamous cell carcinoma of the conjunctiva: analysis of 60 cases. *Br J Ophthalmol* 1999;**83**:98-103.
- 3 **Char DH**. *Tumors of the eye and ocular adnexa*. Hamilton, Ontario: BC Decker, 2001:57-91.
- 4 **Pavlin CJ**, McWhae J, McGowan H, *et al*. Ultrasound biomicroscopy of anterior segment ocular tumors. *Ophthalmology* 1992;**99**:1220-8.
- 5 **Pavlin CJ**, Sherar MD, Harasiewicz K, *et al*. Clinical use of ultrasound biomicroscopy. *Ophthalmology* 1991;**98**:287.
- 6 **Pavlin CJ**, Foster FS. Ultrasound biomicroscopy, high frequency ultrasound imaging of the eye at microscopic resolution. *Radiol Clin North Am* 1998;**36**:1047-57.
- 7 **Iliff WJ**, Marback R, Green WR. Invasive squamous cell carcinoma of the conjunctiva. *Arch Ophthalmol* 1975;**93**:119-22.
- 8 **Li WW**, Pettit TH, Zakka KA. Intraocular invasion by papillary squamous cell carcinoma of the conjunctiva. *Am J Ophthalmol* 1980;**90**:697-701.
- 9 **Wexler SA**, Wallow IH. Squamous cell carcinoma of the conjunctiva presenting with intraocular extension. *Arch Ophthalmol* 1985;**103**:1175-7.
- 10 **De Felice GP**, Viale G, Caroli R. Deeply invasive squamous cell carcinoma of the conjunctiva. *Int Ophthalmol* 1990;**14**:241-4.
- 11 **Cable MM**, Lyon DB, Rupani M, *et al*. Case reports and small case series: primary basal cell carcinoma of the conjunctiva with intraocular invasion. *Arch Ophthalmol* 2000;**118**:1296-8.
- 12 **Lindenmuth KA**, Sugar A, Kincaid MC, *et al*. Invasive squamous cell carcinoma of the conjunctiva presenting as necrotizing scleritis with scleral perforation and uveal prolapse. *Surv Ophthalmol* 1988;**33**:50-4.
- 13 **Kim RY**, Sieff SR, Howes EL Jr, *et al*. Necrotizing scleritis secondary to conjunctival squamous cell carcinoma in acquired immunodeficiency syndrome. *Am J Ophthalmol* 1990;**109**:231-3.
- 14 **Brownstein S**. Mucoepidermoid carcinoma of the conjunctiva with intraocular invasion. *Ophthalmology* 1981;**88**:1226-30.
- 15 **Searl SS**, Krigstein HJ, Albert DM, *et al*. Invasive squamous cell carcinoma with intraocular mucoepidermoid features. Conjunctival carcinoma with intraocular invasion and diphasic morphology. *Arch Ophthalmol* 1982;**100**:109-11.
- 16 **Carrau RL**, Stillman E, Canaan RE. Mucoepidermoid carcinoma of the conjunctiva. *Ophthalm Plast Reconstr* 1994;**10**:163-8.
- 17 **Lacour S**, Legeais JM, D'Hermies F, *et al*. Mucoepidermoid carcinoma of the conjunctiva with intraocular invasion, apropos of a case. *J Fr Ophthalmol* 1991;**14**:349-52.
- 18 **Seitz B**, Henke V. Mucoepidermoid carcinoma of the epibulbar connective tissue with diffuse intraocular epithelial invasion. *Klin Monatsbl Augenheilkd* 1995;**207**:264-5.
- 19 **Soong HK**, Feil SH, Elnor VM, *et al*. Conjunctival mucoepidermoid carcinoma in a young HIV-infected man. *Am J Ophthalmol* 1999;**128**:640-3.
- 20 **Hwang IP**, Jordan DR, Brownstein S, *et al*. Mucoepidermoid carcinoma of the conjunctiva: a series of three cases. *Ophthalmology* 2000;**107**:801-5.
- 21 **Gunduz K**, Shields CL, Shields JA, *et al*. Intraocular neoplastic cyst from mucoepidermoid carcinoma of the conjunctiva. *Arch Ophthalmol* 1998;**116**:521-3.
- 22 **Shields JA**, Shields CL, Gunduz K, *et al*. The 1998 Pan American Lecture. Intraocular invasion of the conjunctiva squamous cell carcinoma in five patients. *Ophthalm Plast Reconstr Surg* 1999;**15**:153-60.
- 23 **Char DH**. Intraocular masquerade syndromes. In: Tasman W, Jaeger E, eds. *Duane's clinical ophthalmology*. Philadelphia: JB Lippincott, 1989, chapter 53.
- 24 **Gentile RC**, Liebmann JM, Tello C, *et al*. Ciliary body enlargement and cyst formation in uveitis. *Br J Ophthalmol* 1996;**80**:895-9.
- 25 **Cusumano A**, Coleman DJ, Silverman RH, *et al*. Three-dimensional ultrasound imaging. *Ophthalmology* 1998;**105**:300-6.
- 26 **Buchwald HJ**, Spraul CW, Wagner P, *et al*. Ultrasound biomicroscopy in iris lesion. *Der Ophthalmol* 1999;**96**:108-13.



## 20 MHz high frequency ultrasound assessment of scleral and intraocular conjunctival squamous cell carcinoma

D H Char, G Kundert, R Bove, et al.

*Br J Ophthalmol* 2002 86: 632-635

doi: 10.1136/bjo.86.6.632

---

Updated information and services can be found at:

<http://bjo.bmj.com/content/86/6/632.full.html>

---

*These include:*

### References

This article cites 23 articles, 8 of which can be accessed free at:

<http://bjo.bmj.com/content/86/6/632.full.html#ref-list-1>

Article cited in:

<http://bjo.bmj.com/content/86/6/632.full.html#related-urls>

### Email alerting service

Receive free email alerts when new articles cite this article. Sign up in the box at the top right corner of the online article.

---

### Notes

---

To request permissions go to:

<http://group.bmj.com/group/rights-licensing/permissions>

To order reprints go to:

<http://journals.bmj.com/cgi/reprintform>

To subscribe to BMJ go to:

<http://group.bmj.com/subscribe/>