

## LABORATORY SCIENCE

## Automated tri-image analysis of stored corneal endothelium

P Gain, G Thuret, L Kodjikian, Y Gavet, P H Turc, C Theillere, S Acquart, J C Le Petit, J Maugery, L Campos

*Br J Ophthalmol* 2002;86:801-808

See end of article for authors' affiliations

Correspondence to: Professor Philippe Gain, Service d'Ophthalmologie (pavillon 50A), CHRU de Bellevue, 25 Boulevard Pasteur, 42055 Saint-Etienne Cedex 2, France; philippe.gain@univ-st-etienne.fr

Accepted for publication 8 February 2002

**Background:** Endothelial examination of organ culture stored corneas is usually done manually and on several mosaic zones. Some banks use an image analyser that takes account of only one zone. This method is restricted by image quality, and may be inaccurate if endothelial cell density (ECD) within the mosaic is not homogeneous. The authors have developed an analyser that has tools for automatic error detection and correction, and can measure ECD and perform morphometry on multiple zones of three images of the endothelial mosaic.

**Methods:** 60 human corneas were divided into two equal groups: group 1 with homogeneous mosaics, group 2 with heterogeneous ones. Three standard microscopy video images of the endothelium, graded by quality, were analysed either in isolation (so called mono-image analysis) or simultaneously (so called tri-image analysis), with 50 or 300 endothelial cells (ECs) counted. The automated analysis was compared with the manual analysis, which concerned 10 non-adjacent zones and about 300 cells. For each analysis method, failures and durations were studied according to image quality.

**Results:** All corneas were able to undergo analysis, in about 2 or 7.5 minutes for 50 and 300 ECs respectively. The tri-image analysis did not increase analysis time and never failed, even with mediocre images. The tri-image analysis of 300 ECs was always most highly correlated with the manual count, particularly in the heterogeneous cornea group ( $r=0.94$ ,  $p<0.001$ ) and prevented serious count errors.

**Conclusions:** This analyser allows reliable and rapid analysis of ECD, even for heterogeneous endothelia mosaics and mediocre images.

Cornea storage techniques, whether short or long term, require analysis of endothelial cell density (ECD). In most eye banks, cornea delivery for grafting is authorised only if ECD is greater than 2000 cells/mm<sup>2</sup> after storage. This cell count is done either by specular microscopy during short term storage at +4°C or by standard microscopy during organ culture,<sup>1</sup> the most common technique in Europe.<sup>2</sup> In Europe, counting is most often done manually. Study of the 1999 register<sup>3</sup> of French cornea banks (Table 1) which lists the data of 2425 corneas stored in organ culture at +31°C, showed a substantial difference in ECDs between banks. This was 32.6% (mean 2634 (SD 231), median 2675, range 2140-3030) at the start of storage and 30.3% (mean 2430, SD 219, median 2360, range 1986-2848) at delivery. It is important to note that all ECDs had been evaluated manually, except in bank 4, which had a semiautomated analysis system that required a technician to digitise the cell contours visible on the screen. Such differences in ECDs were not justified by differences in mean donor age (64.0 years, SD 6.2, range 49-71.5), mean death procurement time (13.7 hours, SD 7.2, range 8-29.4), or mean storage time (17.6 days, SD 2.2, range 14-21). It was legitimate to think that these large ECD differences between banks were due to manual count errors and/or errors in calibration, as may occur in any measuring system.<sup>4,5</sup>

We believe the use of an effective, automated cell counting system is indispensable. Existing systems are of only limited use, especially because of difficulties when the image of the endothelial mosaic under analysis is mediocre. This is often the case with standard microscopy, and requires either numerous contour touch ups or a simple marking of the presumed cell centres. Moreover, whereas the technician manually observes and analyses several non-adjacent zones of the mosaic (generally 5-10 zones, depending on the bank), and a large number of cells, current analysers only take account of

one endothelial zone with a limited number of cells, approximately 50 to 100. The operator's choice of a single zone of analysis may thus be responsible for a selection bias, especially if ECD within the cornea is not uniform. We present a prototype analyser with automatic error detection and correction tools, which is able to measure ECD simultaneously on several endothelial images. Its purpose is to be effective even when images are medium or only adequate, and to limit measurement error when mosaics are heterogeneous.

## MATERIAL AND METHODS

## Manual counts

These were done after making visible the intercellular spaces by incubation for 4 minutes with 0.9% sodium chloride, through a graduated reticle (reference 519966, Leica, Wetzlar, Germany) placed in the ocular of a Leica Laborlux S standard direct optical microscope (Leica). At the moment when the cell contours were most visible, the technician counted the ECs, contained in one microsquare of the reticle, excluding those touching two adjacent borders. He conducted an overall screening of the mosaic of the central 8 mm. This consisted of 10 counts on 10 non-adjacent zones of each cornea, avoiding the folds, which cause overcounting because of parallax error. He then multiplied the mean of his 10 measurements by a corrective factor derived from calibrating the microscope with a micrometric slide (Merkeurolab, Strasbourg, France) in order to obtain the ECD in cells/mm<sup>2</sup>. All counts were done by the same experienced technician (over 3000 counts).

## Image quality and mosaic homogeneity

At the same time, when the intercellular spaces seemed well dilated (neither too much nor too little), he took three video images (Sony SC 75 CE mono CCD) of wide field (width 1000 µm, height 750 µm) of three zones, chosen at random but

**Table 1** Mean endothelial cell densities (ECD) at the start and end of storage, from 17 French cornea banks using organ culture storage (for 1999, source: French storage centre register<sup>3</sup>)

Cornea bank	Corneas delivered (number)	Donor age (years)	Death-procurement time (hours)	ECD at start of organ culture (cells/mm <sup>2</sup> )	Organ culture time (days)	ECD at delivery (cells/mm <sup>2</sup> )
1	126	62.0	9.25	2140	15.4	1986
2	102	67.2	14.2	2441	15.5	2131
3	31	54.0	NA	2316	19	2190
4	288	71.5	29.4	nd	18.5	2218
5	85	58.0	14	NA	16	2300
6	211	66.0	NA	2390	16	2308
7	73	68.0	11	2660	18.5	2340
8	64	64.0	11	NA	16	2496
9	91	50.0	8	2680	16	2540
10	93	49.4	12.4	2748	14.5	2561
11	152	NA	12	2675	16	2567
12	267	61.0	8	2800	17.3	2600
13	107	70.7	13.4	2738	21	2643
14	49	64.0	9.75	2806	17.3	2710
15	133	67.5	11.7	2645	14	2745
16	142	64.4	8.3	3030	18	2848
17	411	NA	NA	NA	NA	NA

\*Only bank 4 used a computer aided analysis tool based on digitisation by tracing with the mouse the perimeter of 100 cells visible on the screen, an objective but laborious and time consuming method. The ECDs of our bank (number 2) and of the 15 others were measured manually during this period. Since our bank has been using our prototype analyser, our mean ECDs have increased a mean 4% (data not presented) and now approach those of bank 4. ECD = endothelial cell density, NA = data not available, nd = analysis not done

**Table 2** Image quality.

Image quality	Score	Criteria
Good	2	Excellent view of cell contours Low background noise Cells visible on over ⅓ of image area
Medium	1	Good view of cell contours Moderate background noise Cells visible on ⅓ to ⅔ of image area
Adequate	0	Poor view of cell contours High background noise Cells visible on less than ⅓ of image area

For the analyses in tri-image mode, overall image quality was graded "good" if the three images obtained scores of 2/2/2 or 2/2/1, "medium" if the scores were 2/1/1, 2/1/0, or 1/1/1, and "adequate" if the scores were 1/1/0, 1/0/0, or 0/0/0

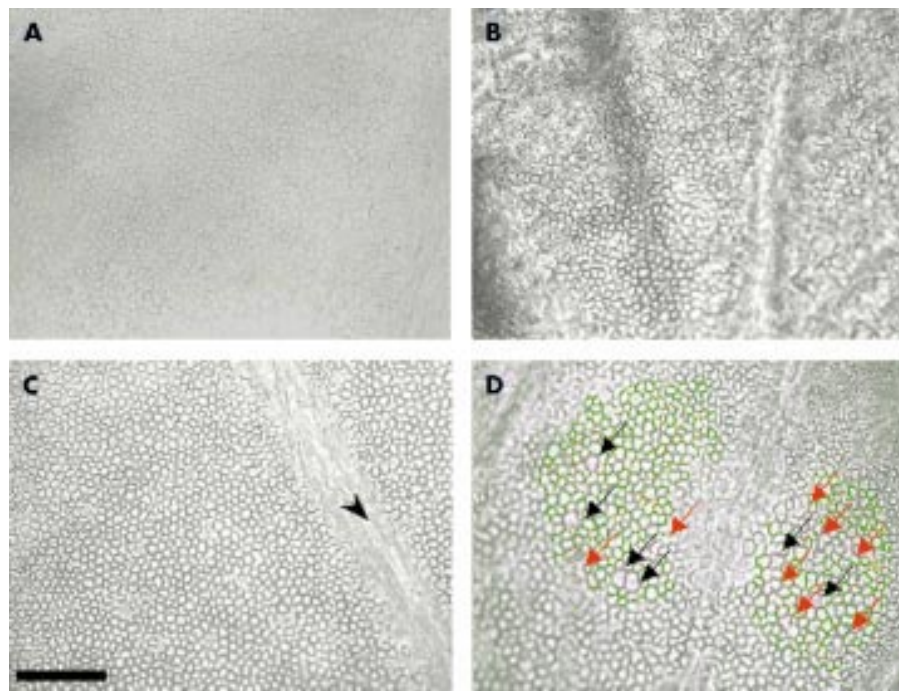
non-adjacent, of the paracentral endothelium. These images were saved in a tagged image format file (TIFF). Each image was examined blind and quality graded (Table 2) "adequate," "medium," or "good" (Figs 1A, B, C). In addition, each cornea was graded "homogeneous" if the ECDs between the three images and within each image appeared similar, or "heterogeneous" otherwise. We analysed 60 corneas, divided into two equal groups: group 1 of homogeneous corneas (30 corneas, 3 × 30 images) and group 2 of heterogeneous corneas (30 corneas, 3 × 30 images). The corneas all came from phakic eyes, and had undergone mean storage of 14 days (SD 4, range 7–31) at +31°C in Inosol (Opsia, Toulouse, France). They were first counted manually, then with our analyser.

#### Analyser and automatic analysis procedures

Our prototype analyser comprised an IBM compatible PC, 800 MHz Pentium, 256 Mb RAM, equipped with a video frame grabber (Data translation DT 3155, Malboro, MA, USA) installed on the same microscope as used for the manual counts. Calibration was done with the same micrometric slide. The three mosaic images were viewed side by side on a 22 inch monitor. The analysis program, written in C++, was based on a generalist image analysis software, ImageTool (University of Texas Health Science Center, San Antonio, TX, USA, available at [ftp://maxrad6.uthscsa](http://ftp://maxrad6.uthscsa)) and specifically adapted to human

corneal endothelium. In particular, it took account of the frequently poor quality of images, with the following functions: selection on one image of several zones of interest according to free forms; automatic elimination of surface artefacts smaller than 50 µm<sup>2</sup>; automatic detection of probable errors in contour recognition (EC of area greater than 1500 µm<sup>2</sup> or whose longest length was more than twice the shortest width that could correspond to poorly separated ECs). The automated analysis went as follows. Each selected zone on each image was successively subject to thresholding, which transformed the starting image, formed of 256 grey levels, into a binary image. The analyser then automatically eliminated the artefacts, and with another colour underlined EC contours that were too wide or too long (Fig 1D). If necessary, the technician then did touch ups by tracing and/or erasing contour segments. These touch ups were made easier by a zoom lens, by the possibility to return to the original image, and by the real time display of the number of ECs taken into account. The final analysis report was then printed and archived in hypertext markup language (HTML) for remote transmission to the surgeon. The report included all parameters of counting (ECD, number of ECs counted) and of morphometry (Fig 2).

For each cornea two analyses methods were compared, with precisely 50 or 300 ECs being taken into account in each method: the "mono-image" method, which analysed one or more zones of a single image (Fig 2A), and the "tri-image" method, which simultaneously analysed one or more zones of three images of the mosaic (Fig 2B). In total, eight automatic analyses (three mono-image 50, three mono-image 300, one tri-image 50, one tri-image 300) were done for each cornea and compared with the manual count. The percentage of severe discrepancy in ECD, as defined by a deviation of plus or minus 20% between the manual and automated counts ((manual ECD – automated ECD)/manual ECD) was compared in each group according to the count method. The tri-image 300 method reproduced most faithfully the strategy of global screening of the mosaic done by the technician during the manual count. The technician timed each analysis (from opening the image files to final printout of the report). The duration and percentage failure of the analysis methods were compared according to the quality of 180 images. The morphometric data, though supplied by the analyser, were not considered for this study and will be the subject of a subsequent study.



**Figure 1** Different grades of standard microscopy video image of the endothelium. These very wide field images ( $750\,000\ \mu\text{m}^2$ ) were archived in TIFF format. (A) Adequate quality image with poorly delineated cell contours, mediocre contrast, large blocks of invisible cells. (B) Medium quality image with fairly well delineated cell contours but high background noise and large blocks of invisible cells. (C) Good quality image with well delineated cell contours, no background noise, cells visible on practically all the image except one fold zone (arrow). (D) Automated error detection tool. The contours of cells exceeding  $1500\ \mu\text{m}^2$  or the form of which is unrealistic (longest length greater than double the shortest width) appear violet to alert the technician. He could then either validate the cells if he deemed them acceptable, or touch them up by adding or erasing certain segments. In this example, six cells were genuinely large in area (black arrows), the others needed touching up (red arrows). Scale bar  $200\ \mu\text{m}$

### Statistics

Comparison of the ECDs and durations of each method was done with Student's *t* test for paired samples. The correlations between the different methods of automated and manual analysis were studied (Pearson's *r* coefficient) and tested against the null hypothesis of no correlation ( $r=0$ ). In all the statistical tests,  $p<0.05$  was deemed significant.

## RESULTS

### Image appearance, analysis failure, and duration (Table 3)

The 60 corneas could be analysed by at least one of the eight automated methods. Of a total of 480 theoretical analyses, 464 (97%) could be done. Analysis failures were encountered only in mono-image 300 mode. Images were judged "adequate," "medium," or "good" in respectively 10% ( $n=17$ ), 44% ( $n=79$ ), and 46% ( $n=84$ ) of cases. When images were of good quality, especially when 50 cells were counted, touch ups were not necessary. Analysis of the "adequate" images required more touch ups and lasted longer. The mean duration, (not including the time to capture the three images, which took about 1 minute), was less than 2 minutes for 50 cells and 7.5 minutes for 300 cells. The tri-image method was no slower than the mono-image method. On the contrary, it tended to be faster in the case of only adequate images (difference not significant). Manual analyses lasted about 10–15 minutes, comprising 5–7 minutes to count and a similar time to write the report.

### Comparison of analysis methods and manual count

In manual mode, the technician counted a mean of 339 cells (SD 56, range 192–476). The ECDs provided by the automated analysis methods, in group 1 of homogeneous corneas and group 2 of heterogeneous corneas, are presented respectively

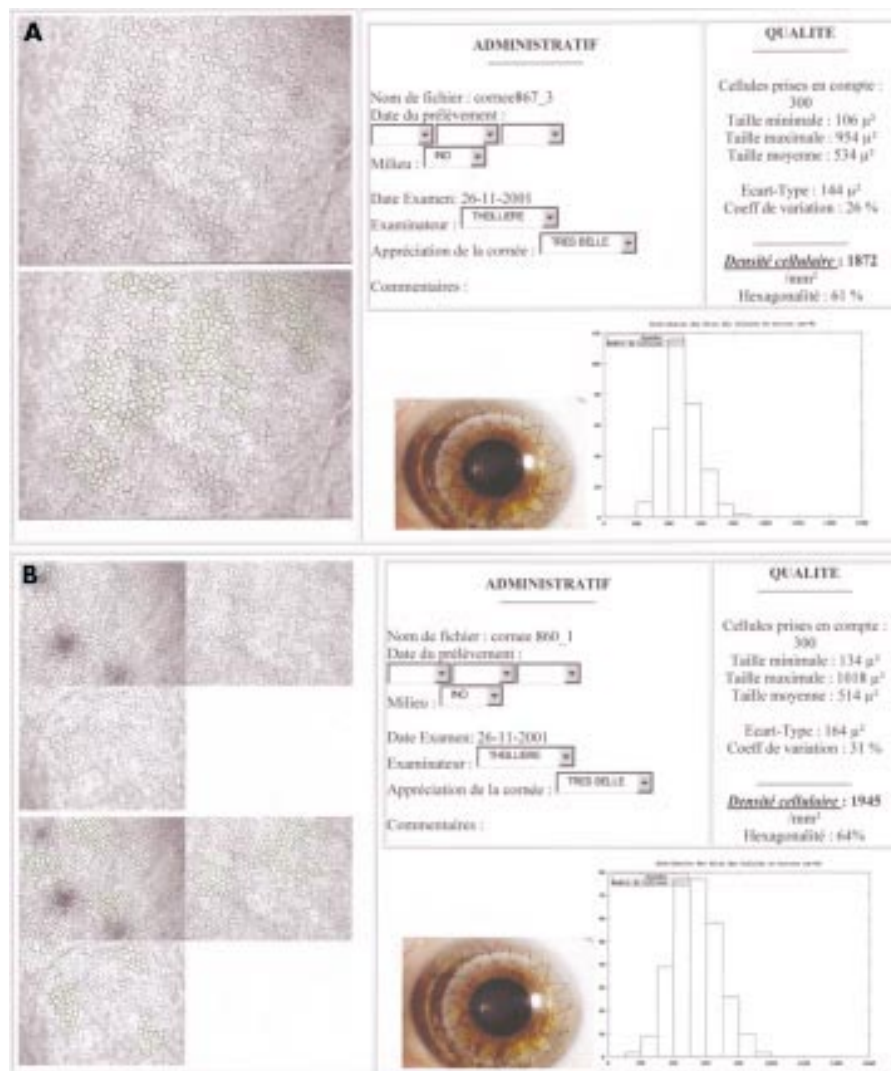
in Tables 4 and 5. The manual count always slightly underestimated ECD, by mean values of 3.8% (group 1) and 7.1% (group 2) in comparison with all the automated analyses. In group 1, all the automated analysis methods were strongly correlated with the manual count ( $r$  between 0.78 and 0.93,  $p<0.001$ ) (Fig 3). But in group 2 (Fig 4), the strongest correlations with the manual count were in tri-image 300 mode ( $r = 0.94$ ,  $p < 0.001$ ), and the weakest were in mono-image 50 mode ( $r = 0.54$ ,  $p < 0.001$ ) and then mono-image 300 mode ( $r = 0.59$ ,  $p < 0.001$ ).

Serious discrepancies in ECD measurement (of 20% and more) between manual and automatic methods were observed for heterogeneous corneas in 31.1% and 29.1% of cases in mono-image 50 or 300 mode respectively, but less often in tri-image 50 or 300 modes (respectively 3.3% of cases,  $p<0.006$ , and 6.7% of cases,  $p<0.01$ ). In group 1 such serious discrepancies were far rarer (only three out of 240 analyses) irrespective of the analysis method and the number of cells counted.

## DISCUSSION

We developed a prototype automated analyser which, using three standard microscopy video images, allows rapid and effective measurement of ECD and morphometry of organ culture stored corneas, even with adequate or medium quality images and heterogeneous mosaics. It reduces the human bias that exists with other analysers, which only analyse one mosaic zone chosen by the technician.

The use of computerised image analysis tools reduces inter-individual and intraindividual variability by lowering the risk of error, and saves time compared to manual counting.<sup>6–8</sup> Such tools were originally developed for in vivo analysis of specular microscopy images<sup>9–17</sup> and then for endothelial examination during short term storage at  $+4^\circ\text{C}$ .<sup>18–19</sup> The contours of ECs



**Figure 2** Final result of analyses in mono-image (A) and tri-image (B) modes, sent by the cornea bank to the surgeon. This document, saved in HTML format, can be remotely transmitted. It contained all quantitative data (ECD, cell count) and morphometric data (area variation coefficient, min/max/mean/standard deviation of cell area, histogram of relative frequency distribution of cell areas, percentage of hexagonality). The one or three non-analysed and analysed video images of the endothelium are also printed, as is a non-specified image (in our case, an example of a graft). The technician also had a text box to note any comments.

viewed in specular mode are non modified and relatively well contrasted. The moderate descemetic folds and stromal oedema seen in short storage allow generation of easy to analyse images. However, some authors stress that the accuracy of automated specular image analysers remains linked to image quality<sup>13 15 16 20</sup> and to the size of the visible field.<sup>10</sup>

Automated analysis of the mosaic in optical microscopy, the most common technique in European banks that use organ culture, is more difficult given the often poorer image quality.<sup>6,21</sup> EC contours can only be viewed after osmotically induced dilation of the intercellular spaces, typically by a solution of 0.9% NaCl.<sup>22</sup> This dilation varies from one cornea to another and between zones of the same cornea.<sup>6</sup> It must not be excessive, because analysis of too retracted cells is very difficult. The use of 0.9% NaCl for about 4 minutes helped us obtain medium (44%) and good (46%) images without recourse to other osmotic agents liable to enhance viewing of the cell contours, such as 1.8% sucrose.<sup>23</sup> Furthermore, the technician must capture the images when the intercellular spaces are well dilated, and adjust the focus, light, and the microscope condenser to improve contour definition and contrast and the percentage of visible cells, and to limit background noise. Thresholding, which is done independently

on each zone of each image, must also receive special attention since it reduces the need for touch ups. When images were of good quality, very limited and sometimes no touch ups were needed. Prolonging organ culture increases the number of folds<sup>23</sup> and the stromal oedema,<sup>24</sup> and can also degrade images. Barisani, with his mono-image analyser, had 44% failure beyond 21 days' organ culture.<sup>6</sup> This was not the case in our study, because even in the case of prolonged storage (up to 31 days in our series), analysis was always possible in tri-image mode, even with a high cell count (300). The possibility to choose several zones on the same image according to the free forms, avoiding zones where the mosaic was not visible, and to repeat the operation on the three images, prevented failure even with mediocre images. Lastly, direct acquisition of the video images, without an intermediate photographic stage, limited information loss and eliminated the risk of errors linked to image magnification,<sup>16 18</sup> because the entire optical and computing chain was directly calibrated.

All automated analysers currently used in optical and specular microscopy select a single parallelepipedic zone for analysis. This has two drawbacks: (1) this form does not always allow elimination from analysis of zones where the

**Table 3** Durations and failure percentages of the different analysis methods according to image quality (excluding image capture, which lasted about 1 minute)

Analysis method	"Adequate" image			"Medium" image			"Good" image			All grades		
	Time	Failures	No	Time	Failures	No	Time	Failures	No	Time	Failures	No
Mono-image 50	174 (98, 69–387)	0%	17	110 (86, 43–600)	0%	79	79 (27, 38–168)	0%	84	101 (72, 38–600)	0%	180
Tri-image 50	141 (49, 95–260)	0%	11	124 (49, 59–243)	0%	23	96 (26, 62–141)	0%	26	115 (44, 59–260)	0%	60
Mono-image 300	698 (287, 405–1230)	59%	17	547 (234, 240–1200)	8%	79	356 (126, 145–781)	0%	84	456 (216, 145–1230)	9%	180
Tri-image 300	577 (147, 399–767)	0%	11	486 (110, 258–689)	0%	23	367 (140, 138–693)	0%	26	451 (152, 138–767)	0%	60

Mean time required was just under 2 minutes to count 50 cells and 7.5 minutes to count 300. With rare exceptions, automated analysis was far shorter than a manual count, which took 10–15 minutes. It should be noted that video image capture time allows the cornea to be returned very quickly to its storage medium. In the case of good images, analysis times were significantly shortened, falling to about 1.5 minutes for 50 cells ( $p < 0.001$ ) and to 6 minutes for 300 cells ( $p < 0.001$ ). Analysis time in tri-image mode was not longer than in mono-image mode, whichever the cell count. On the contrary, analysis time was substantially shorter for adequate images (not significant) because of multiple zone selection or a properly visible mosaic, which reduced the need for touch ups. Note finally that the only failed analyses were in mono-image 300 mode ( $p = 0.014$ ) and for medium or adequate images. Mean durations are expressed in seconds (SD, range).

**Table 4** Endothelial cell density (ECD) of homogeneous corneas (group 1,  $n = 30$ ) by automated analysis method: mono-image (each of the three images is analysed in isolation) or tri-image (the three images are analysed simultaneously) for 50 and 300 cells, and comparisons with manual count

Analysis method	No	Mean ECD (cells/mm <sup>2</sup> (SD, range)	Mean ECD (cells/mm <sup>2</sup> ) discrepancy with manual count (p)	Pearson's $r^*$
Mono 50 (image 1)	30	2473 (389, 1773–3816)	139 ( $p = 0.003$ )	0.81
Mono 50 (image 2)	30	2400 (357, 1805–3460)	66 ( $p = 0.123$ )	0.78
Mono 50 (image 3)	30	2381 (329, 1912–3344)	47 ( $p = 0.172$ )	0.83
Mono 300 (image 1)	28†	2480 (363, 1782–3533)	128 ( $p = 0.001$ )	0.88
Mono 300 (image 2)	28†	2390 (324, 1814–3367)	76 ( $p = 0.040$ )	0.82
Mono 300 (image 3)	29†	2398 (313, 1897–3174)	63 ( $p = 0.032$ )	0.88
Tri image 50	30	2447 (363, 1865–3636)	113 ( $p = 0.002$ )	0.90
Tri image 300	30	2422 (312, 1862–3448)	87 ( $p = 0.001$ )	0.93
Manual count	30	2334 (245, 1781–2990)	–	–

\*all  $p$  values  $< 0.001$ .

†Missing data: 300 cells uncountable due to adequate or medium image quality. ‡‡The manual count underestimated ECD by a mean 3.8% (mean: 90 cells/mm<sup>2</sup>, range 47–139) in comparison with the automated analyses. Correlations between automated-analysis methods and manual count were good ( $r = 0.78$ – $0.88$ ) in mono-image and excellent ( $r = 0.90$ – $0.93$ ) in tri-image.

ECD = endothelial cell density, SD = standard deviation, Mono 50 = analysis of one image and 50 cells, Mono 300 = analysis of one image and 300 cells, Tri-image 50 = analysis of three images simultaneously and 50 cells, tri-image 300 = analysis of three images simultaneously and 300 cells.

image is worst, as stated above, or of zones of folds responsible for ECD overestimation due to parallax error; (2) since there is only one zone, which is often limited in size, this reduces accordingly the number of cells counted and the accuracy of the ECD measurement. Hirst points out that such an analysis is only representative of the whole endothelium in cases where the mosaic is particularly homogeneous.<sup>11–14</sup> Development of wide field specular microscopy, enabling 2000 to 3000 cells to be viewed,<sup>25</sup> allowed better mosaic sampling and analysis of a very large number of cells (over 400).<sup>12</sup> However, the technology of the time limited its use because of excessive analysis time, close to 30 minutes, and was only suited to in vivo specular microscopy. With our analyser, selection of several zones on three wide field optical microscopy images makes it theoretically possible to analyse between 4000 and 6000 cells on a corneal area of 2.25 mm<sup>2</sup>, constituting a sample of over 4% of the central 8 mm area (50.26 mm<sup>2</sup>). This is the widest field analysed in the literature. We have thus shown that analysis of a single image of 50 or even 300 cells could be faulted, especially if the mosaic is heterogeneous. This was not the case with our original analysis method, which considers three images simultaneously.

Corneas with a heterogeneous endothelium are not rare. Observation of thousands of consecutive images of endothelial mosaics led us to note that about one cornea in five may be

deemed heterogeneous (data not shown). Some zones, where polymegethism and pleomorphism are greatest, may have a lower ECD than others where the mosaic is more uniform. This was shown by cartographic studies evaluating the spacial variations of the ECD in corneal pathologies such as keratoconus.<sup>26</sup> This has also been noted in scarring procedures (especially cataract surgery)<sup>27</sup> which are generally excluded from procurement. However, ageing is a factor in heterogeneity<sup>28–30</sup> that banks increasingly face, and particularly in Europe, where donor age is high.<sup>31–32</sup> In our series, in tri-image 300 mode the 30 heterogeneous corneas had a mean ECD of 2204 cells/mm<sup>2</sup> (SD 412, range 1545–2994) and 19 of these (63%) were grafted. In this group, mono-image analysis gave substantial discrepancies in ECD measurement, more than 20% (greater or less) than the manual count, for nearly a third of the corneas. These could thus have been wrongly eliminated or delivered. The possibility, in tri-image 300 mode, to analyse simultaneously several non-adjacent zones on several images and a large number of cells limits technician bias in selecting a single mosaic zone: it reproduces his strategy of overall screening of multiple mosaic zones and takes account of 300 cells as when he counts manually. This analysis method is most strongly correlated with manual analysis, particularly for heterogeneous corneas ( $r = 0.94$ ), but also for homogeneous ones ( $r = 0.93$ ).

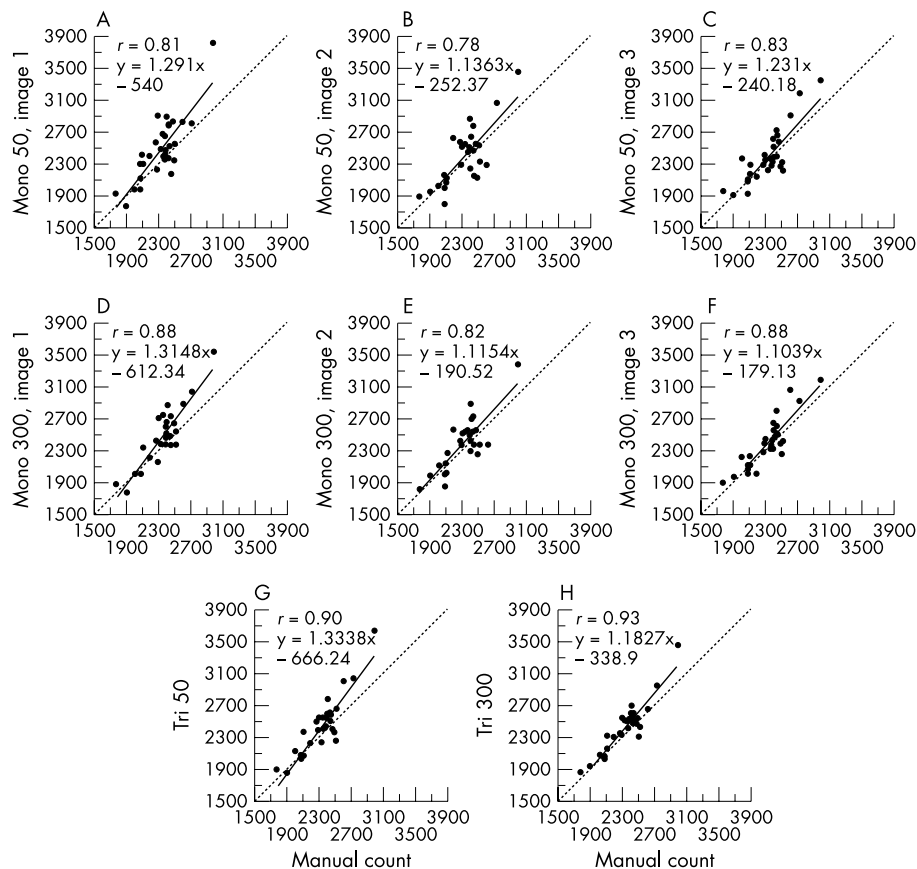
**Table 5** Endothelial cell density (ECD) of heterogeneous corneas (group 2, n=30) by automated analysis method: mono-image (each of the three images is analysed in isolation) or tri-image (the images are analysed simultaneously) for 50 and 300 cells, and comparison with manual count

Analysis method	No	Mean ECD (SD, range) Cells/mm <sup>2</sup>	Mean ECD discrepancy with manual count (cells/mm <sup>2</sup> , p)	Pearson's r*
Mono 50 (image 1)	30	2139 (581, 921–3134)	66 (p=0.35)	0.76
Mono 50 (image 2)	30	2220 (455, 1464–3184)	147 (p=0.064)	0.54
Mono 50 (image 3)	30	2273 (633, 937–3754)	200 (p=0.007)	0.82
Mono 300 (image 1)	26†	2265 (452, 1259–2923)	155 (p=0.007)	0.81
Mono 300 (image 2)	28†	2296 (514, 1555–3484)	229 (p=0.009)	0.59
Mono 300 (image 3)	25†	2241 (526, 933–3246)	183 (p=0.012)	0.77
Tri image 50	30	2159 (442, 1410–2932)	86 (p=0.019)	0.91
Tri image 300	30	2204 (412, 1545–2994)	131 (p=0.001)	0.94
Manual count	–	2073 (420, 1248–3094)	–	–

†Missing data: 300 cells uncountable due to adequate or medium image quality. ‡As with the group 1 corneas, the manual count underestimated ECD by a mean 7.1% (mean: 148 cells/mm<sup>2</sup>, range 66–229) in comparison with the automated analyses. The best correlations with manual analysis were obtained in tri-image mode with a 300 cells count ( $r = 0.94$ ), then in tri-image 50 mode ( $r = 0.91$ ). However, the correlations were weaker in mono-image mode and even poor in some modes ( $r = 0.54$  and  $r = 0.59$ ).

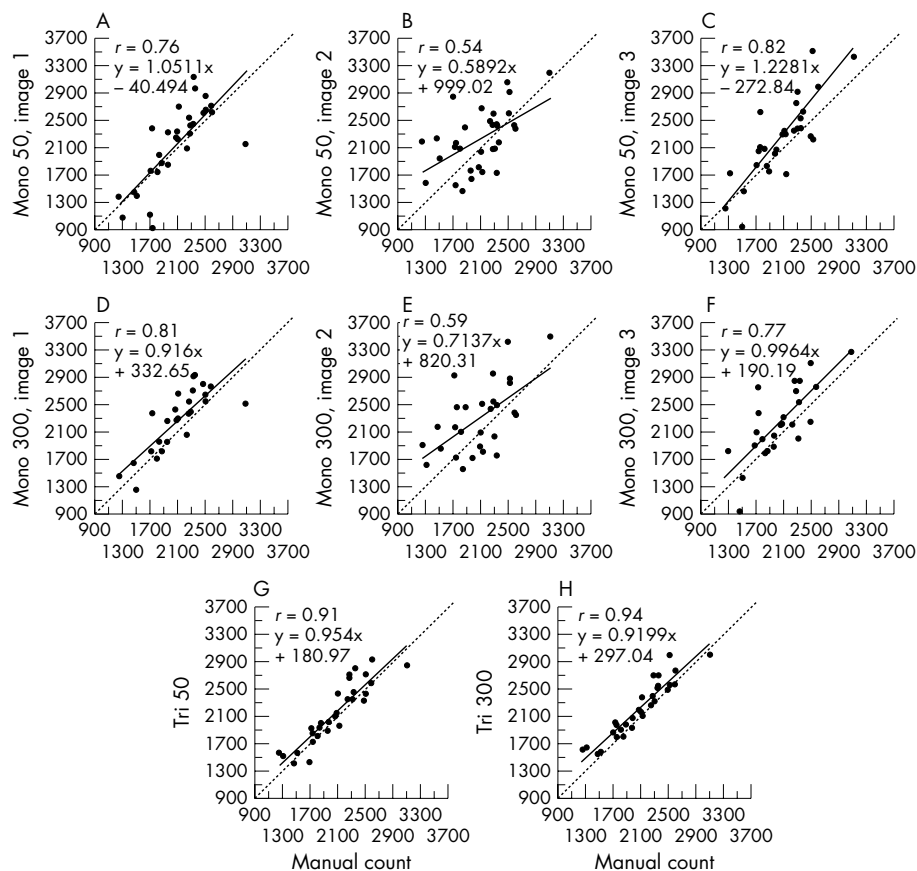
ECD = endothelial cell density, SD = standard deviation, Mono 50 = analysis of one image and 50 cells, Mono 300 = analysis of one image and 300 cells, tri-image 50 = analysis of three images simultaneously and 50 cells, tri-image 300 = analysis of three images simultaneously and 300 cells.

\*all p values <0.001.

**Figure 3** The relations between each of the eight automated analysis methods and manual count for homogeneous corneas (group 1, n=30). Whatever the analysis method, discrepancies with the manual count were rare. Correlations were best with the tri-image mode, for 300 and even 50 cells. For all correlations, p was <0.001.

Analysis time is necessarily lengthened by counting of a large number of cells. While the number of ECs counted increases the validity of ECD measurement through improved sampling, it also increases the risk of touch up related error, the laboriousness of the operation, and the cost of analysis. Most authors thus deemed counting of 75 to 100 ECs, in specular<sup>33–35</sup> and optical<sup>35–36</sup> microscopy, a good compromise, assuming the endothelial mosaic is relatively homogeneous. Moreover, the tools of that time could typically analyse only a

relatively restricted field of the mosaic, and computers were slower and did not offer automated error detection or correction. Time is saved by programming these features, in particular the elimination of surfaces smaller than 50  $\mu\text{m}^2$  corresponding to debris, nuclei, or contour artefacts. Likewise, automatic detection of probable contour recognition error enables touch ups to be guided, thus making them more rapid and accurate, an appreciable factor in morphometric validity. Our mean analysis time was just under 7.5 minutes for 300



**Figure 4** The relations between each of the eight automated analysis methods and manual count for heterogeneous corneas (group 1, n=30). The mono-image 50 or 300 counts often gave rise to serious discrepancies. Correlations were best ( $r=0.94$ ) in mono-image 300 and tri-image 50 modes ( $r=0.91$ ). For all correlations,  $p$  was  $<0.001$ .

cells. We felt it unreasonable to design a process exceeding 10 minutes, the duration of a manual analysis, in order to make the analyser routinely available to the technician. The choice of three images, rather than four, five or even more, was partly imposed by this time constraint. The tri-image mode does not increase analysis time; and in the case of mediocre images substantially shortens it by allowing selection of multiple zones of interest where the mosaic is clearly visible. Furthermore, these error detection and correction tools enhance system user friendliness and make learning to use it easier, a skill acquired after a few counts. Lastly, two major benefits should be emphasised: (1) because analysis can be deferred, capture of the three images takes about 1 minute, which considerably reduces the time spent by the corneas out of the storage medium; (2) image archiving (in TIFF format) and results transmission via a computer network (thanks to the HTML format) save considerable time.

## CONCLUSIONS

Since January 2001 our analyser has been routinely used in our bank, and analysis in tri-image mode of 300 cells is now our gold standard for cornea delivery. This analysis method has markedly increased our cornea delivery rate, but also allowed more stringent selection, especially for heterogeneous mosaics. This is important for our clinical research, where accurate ECD data at delivery are required for postoperative study of diminishing ECDs. More recently, our laboratory's acquisition of a second analyser has proved particularly useful in the experimental evaluation of new storage media, where slight ECD and morphometric variations must be highlighted. Provision of this system to Europe's ophthalmological community may represent a step towards the standardisation

and improvement of endothelial examination within and between cornea banks.

## Authors' affiliations

**P Gain, G Thuret, L Kodjikian, J Maugery**, Ophthalmology Department, Bellevue Hospital, 25 Bd Pasteur, 42055 Saint-Etienne Cedex 2, France

**P Gain, G Thuret, Y Gavet, P H Turc**, Ecole Nationale Supérieure des Mines de Saint-Etienne, 42000 Saint-Etienne, France

**P Gain, G Thuret, C Theillere, S Acquart, J C Le Petit**, French Blood Center, Cornea Bank of St-Etienne (Loire/Auvergne region), 25 Bd Pasteur, 42055 Saint-Etienne Cedex 2, France

**P Gain, G Thuret, L Campos**, "Cell Death and Neoplasia" Research Group (EA 3063), Faculty of Medicine, 15 rue Ambroise Paré, 42023 Saint-Etienne Cedex, France

## ACKNOWLEDGEMENTS

We thank the AIRE association (which supports local medical research) for funding (2000–01 research programme)

Part of this paper was presented at the 14th annual meeting of the European Eye Bank Association, held on 18–19 January 2002 in Paris, France. It won the best oral presentation award.

Proprietary interest: none.

## REFERENCES

- 1 Delbosc B, Borderie V. Methods of preservation of the human corneas. *J Fr Ophthalmol* 1997;**20**:221–40.
- 2 Maas-Reijs J, Pels E, Tullio AB. Eye banking in Europe 1991–1995. *Acta Ophthalmol Scand* 1997;**75**:541–3.
- 3 French directory of corneal storage centres. 7th ed. 1999.
- 4 Ohno K, Nelson LR, McLaren JW, et al. Comparison of recording systems and analysis methods in specular microscopy. *Cornea* 1999;**18**:416–23.

- 5 **Benetz BA**, Diaconu E, Bowlin SJ, *et al*. Comparison of corneal endothelial image analysis by Konan SP8000 noncontact and Bio-Optics Bambi systems. *Cornea* 1999;**18**:67–72.
- 6 **Barisani-Asenbauer T**, Baumgartner I, Grabner G, *et al*. Automated digital image analysis of organ culture preserved donor corneas. *Ophthalmic Res* 1993;**25**:94–9.
- 7 **Seitz B**, Muller EE, Langenbucher A, *et al*. Reproducibility and validity of a new automatic method of specular microscopy analysis of corneal endothelium. *Ophthalmologie* 1997;**94**:127–35.
- 8 **Reinhard T**, Spelsberg H, Holzwarth D, *et al*. Endothelial evaluation of corneal transplants by digital imaging. *Klin Monatsbl Augenheilkd* 1999;**214**:407–11.
- 9 **Rao GN**, Waldron WR, Aquavella JV. Morphology of graft endothelium and donor age. *Br J Ophthalmol* 1980;**64**:523–7.
- 10 **Lester JM**, McFarland JL, Bursell SE, *et al*. Automated morphometric analysis of corneal endothelial cells. *Invest Ophthalmol Vis Sci* 1981;**20**:407–10.
- 11 **Hirst LW**, Auer C, Abbey H, *et al*. Quantitative analysis of wide-field endothelial specular photomicrographs. *Am J Ophthalmol* 1984;**97**:488–95.
- 12 **Hirst LW**, Sterner RE, Grant DG. Automated analysis of wide-field specular photomicrographs. *Cornea* 1984;**3**:83–7.
- 13 **Nishi O**, Hanasaki K. Automated morphometry of corneal endothelial cell: use of video camera and video tape recorder. *Br J Ophthalmol* 1988;**72**:68–73.
- 14 **Hirst LW**, Yamauchi K, Enger C, *et al*. Quantitative analysis of wide-field specular microscopy. II. Precision of sampling from the central corneal endothelium. *Invest Ophthalmol Vis Sci* 1989;**30**:1972–9.
- 15 **Nishi O**, Hanasaki K. Automated determination of polygonality of corneal endothelial cells. *Cornea* 1989;**8**:54–7.
- 16 **Siertsema JV**, Landesz M, van den Brom H, *et al*. Automated video image morphometry of the corneal endothelium. *Doc Ophthalmol* 1993;**85**:35–44.
- 17 **Landesz M**, Siertsema JV, Van Rij G. Comparative study of three semiautomated specular microscopes. *J Cataract Refract Surg* 1995;**21**:409–16.
- 18 **Hartmann C**, Koditz W. Automated morphometric endothelial analysis combined with video specular microscopy. *Cornea* 1984;**3**:155–67.
- 19 **Matsuda M**, Yee RW, Glasser DB, *et al*. Specular microscopic evaluation of donor corneal endothelium. *Arch Ophthalmol* 1986;**104**:259–62.
- 20 **Fabian E**, Mertz M, Koditz W. Morphometry of the endothelium using automated television image analysis. *Klin Monatsbl Augenheilkd* 1983;**182**:218–23.
- 21 **Delbosc B**, Cantenot L, Fellmann D, *et al*. In vitro semi-automated morphometry of preserved human corneal endothelium. *J Fr Ophthalmol* 1986;**9**:445–54.
- 22 **Sperling S**. Evaluation of the endothelium of human donor corneas by induced dilation of intercellular spaces and trypan blue. *Graefes Arch Clin Exp Ophthalmol* 1986;**224**:428–34.
- 23 **Pels E**, Schuchard Y. Organ-culture preservation of human corneas. *Doc Ophthalmol* 1983;**56**:147–53.
- 24 **Muller LJ**, Pels E, Vrensen GF. The effects of organ-culture on the density of keratocytes and collagen fibers in human corneas. *Cornea* 2001;**20**:86–95.
- 25 **Koester CJ**, Roberts CW, Donn A, *et al*. Wide field specular microscopy. Clinical and research applications. *Ophthalmology* 1980;**87**:849–60.
- 26 **Corkidi G**, Marquez J, Garcia-Ruiz M, *et al*. Cartographic system for spatial distribution analysis of corneal endothelial cells. *Med Biol Eng Comput* 1994;**32**:421–6.
- 27 **Mishima S**. Clinical investigations on the corneal endothelium-XXXVIII Edward Jackson Memorial Lecture. *Am J Ophthalmol* 1982;**93**:1–29.
- 28 **Yee RW**, Matsuda M, Schultz RO, *et al*. Changes in the normal corneal endothelial cellular pattern as a function of age. *Curr Eye Res* 1985;**4**:671–8.
- 29 **Sherrard ES**, Novakovic P, Speedwell L. Age-related changes of the corneal endothelium and stroma as seen in vivo by specular microscopy. *Eye* 1987;**1**:197–203.
- 30 **Bourne WM**, Nelson LR, Hodge DO. Central corneal endothelial cell changes over a ten-year period. *Invest Ophthalmol Vis Sci* 1997;**38**:779–82.
- 31 **Borderie VM**, Scheer S, Touzeau O, *et al*. Donor organ cultured corneal tissue selection before penetrating keratoplasty. *Br J Ophthalmol* 1998;**82**:382–8.
- 32 **Gain P**, Thuret G, Chiquet C, *et al*. Cornea procurement from very old donors: post organ culture cornea outcome, and recipient graft outcome. *Br J Ophthalmol* 2002;**86**:404–11.
- 33 **Sugar A**. Clinical specular microscopy. *Surv Ophthalmol* 1979;**24**:21–32.
- 34 **Waring GOd**, Bourne WM, Edelhauser HF, *et al*. The corneal endothelium. Normal and pathologic structure and function. *Ophthalmology* 1982;**89**:531–90.
- 35 **Geroski DH**, Edelhauser HF. Morphometric analysis of the corneal endothelium. Specular microscopy vs alizarin red staining. *Invest Ophthalmol Vis Sci* 1989;**30**:254–9.
- 36 **Doughty MJ**, Fonn D, Trang Nguyen K. Assessment of the reliability of calculations of the coefficient of variation for normal and polymegathous human corneal endothelium. *Optom Vis Sci* 1993;**70**:759–70.

### Call for peer reviewers

*Clinical Evidence* is a regularly updated evidence based journal available world wide both as a paper version and on the internet. *Clinical Evidence* urgently needs to recruit a number of new contributors. Contributors are health care professionals or epidemiologists with experience in evidence based medicine and the ability to write in a concise and structured way.

*Clinical Evidence* needs to recruit a number of new peer reviewers. Peer reviewers are health care professionals or epidemiologists with experience in evidence based medicine. As a peer reviewer you would be asked for your views on the clinical relevance, validity and accessibility of specific topics within the journal, and their usefulness to the intended audience (international generalists and health care professionals, possibly with limited statistical knowledge). Topics are usually 2000–3000 words in length and we would ask you to review between 2–5 topics per year. The peer review process takes place throughout the year, and our turnaround time for each review is ideally 10–14 days.

If you are interested in becoming a peer reviewer for *Clinical Evidence*, please complete the peer review questionnaire at [www.clinicalevidence.com](http://www.clinicalevidence.com) or contact Polly Brown ([pbrown@bmjgroup.com](mailto:pbrown@bmjgroup.com)).



## Automated tri-image analysis of stored corneal endothelium

P Gain, G Thuret, L Kodjikian, et al.

*Br J Ophthalmol* 2002 86: 801-808

doi: 10.1136/bjo.86.7.801

---

Updated information and services can be found at:

<http://bjo.bmj.com/content/86/7/801.full.html>

---

### References

*These include:*

This article cites 34 articles, 9 of which can be accessed free at:

<http://bjo.bmj.com/content/86/7/801.full.html#ref-list-1>

Article cited in:

<http://bjo.bmj.com/content/86/7/801.full.html#related-urls>

### Email alerting service

Receive free email alerts when new articles cite this article. Sign up in the box at the top right corner of the online article.

---

### Notes

---

To request permissions go to:

<http://group.bmj.com/group/rights-licensing/permissions>

To order reprints go to:

<http://journals.bmj.com/cgi/reprintform>

To subscribe to BMJ go to:

<http://group.bmj.com/subscribe/>