

PostScript

LETTERS

If you have a burning desire to respond to a paper published in the *BJO*, why not make use of our "rapid response" option? Log on to our website (www.bjophthalmol.com), find the paper that interests you, and send your response via email by clicking on the "eLetters" option in the box at the top right hand corner.

Providing it isn't libellous or obscene, it will be posted within seven days. You can retrieve it by clicking on "read eLetters" on our homepage.

The editors will decide as before whether to also publish it in a future paper issue.

Histopathological findings in filtering blebs with recurrent blebitis

We report clinical courses and histopathological findings of excised blebs from two patients with recurrent blebitis.

Case reports

Case 1

A 79 year old man with a past history of lung cancer and diabetes mellitus underwent trabeculectomy with 5-fluorouracil in his right eye for a diagnosis of primary open angle glaucoma (POAG) in 1989. In January 1994, bleb leakage from an avascular bleb was confirmed for the first time and prophylactic topical erythromycin had been applied. In September 1994, he experienced ocular pain and hyperaemia in his right eye and blebitis was diagnosed. Culture of aqueous humour was positive for enterococcus. He was treated with topical ofloxacin, micronomicin, and a subconjunctival injection of amikacin and the infection resolved. After then, bleb leak was not observed at any regular visit. In March 1998, blebitis occurred with a bleb leak in the same position. Although infection was controlled with almost same medication as before, the leak did not stop after any conservative therapies. In October 1998, the bleb was resected and the free conjunctival flap was transplanted. Histology of the excised bleb indicated a one to two layered thin epithelium with goblet cell depletion and a poor inflammatory response (Fig 1).

Case 2

An 89 year old man underwent a Scheie procedure (thermal sclerostomy) in his left eye for a diagnosis of POAG in June 1980. Avascular bleb was observed but he was unable to visit the hospital for periodic examination because of his age. In August 1998, he presented with ocular pain and discharge in his left eye and blebitis was diagnosed. Culture from conjunctival scraping grew *Staphylococcus aureus*. The infection was successfully treated with anterior chamber irrigation with gentamicin (8 mg/l) and topical ofloxacin. The bleb leak persisted, however,

and topical ofloxacin was prophylactically applied thereafter. In January 2001, blebitis occurred in the same position. Topically applied SBPC, ofloxacin, and micronomicin abolished the infection.

Because the bleb leak persisted, the bleb was resected to prevent reinfection and anterior advancement of the conjunctiva was performed in February 2001. Histological examination of the bleb specimen revealed an attenuated epithelium with goblet cell depletion and hyaline change with a loss of inflammatory responses in the lamina propria.

Comment

According to previous reports, the epithelia of leaking blebs following adjunctive use of antimetabolites shows focal or general thinning.^{1,2} In cases of leaking bleb after filtering surgery without the use of antimetabolites, Sinnreich *et al*³ reported similar epithelial thinning, while Addicks *et al*⁴ reported normal epithelium. Both of our cases were similar to the former. Moreover, there was goblet cell depletion in both of our cases. Mucin is a highly adhesive substance secreted from goblet cells and mostly forms as surface mucin over the cornea or conjunctiva, which has an important function as a physical, biological barrier on the ocular surface, such as elimination of foreign bodies or control of micro-organisms.⁵ Thus, histological findings of these two cases of recurrent bleb infection are compatible with dysfunction against bacterial infection.

Inflammatory reaction in the stroma of the bleb is decreased with the use of mitomycin C,^{1,2,6-8} while cases of leaking blebs without antimetabolites reportedly show moderate subconjunctival inflammation.³ Case 2 in the

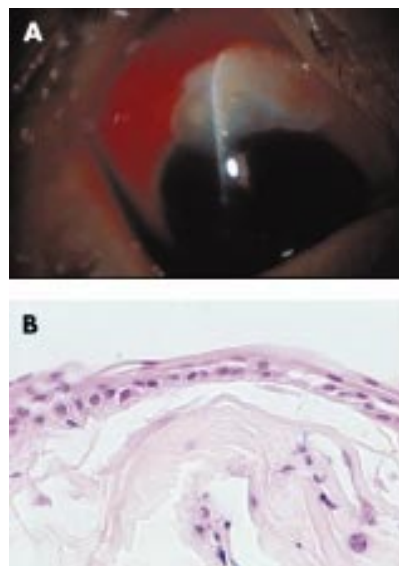


Figure 1 (A) Recurrent blebitis in case 1. Note the infiltrates inside the avascular, transparent bleb. (B) The histological study of the excised bleb from case 1 shows a one to two layered thin epithelium with goblet cell depletion and a poor inflammatory response (haematoxylin and eosin, original magnification, $\times 150$)

present study, without the use of antimetabolites, had a low inflammatory reaction. Poor immune response may be related to the poor blood supply in these ischaemic blebs and compatible with the poor immune response to bacterial infection.

Waheed and his colleagues reported clinical characteristics of 12 eyes with recurrent bleb related infections and they concluded that eyes that have been successfully treated for bleb related infection remain at risk for recurrent infection.⁹ Histopathological findings showing thinning and breakdown of epithelial structures in the present study may explain this findings.

H Matsuo, G Tomita, M Araie, Y Suzuki, Y Kaji

Department of Ophthalmology, The University of Tokyo School of Medicine, Tokyo, Japan

H Obata

Department of Ophthalmology, Jichi Medical School, Tochigi, Japan

S Tanaka

Department of Ophthalmology, Teikyo University School of Medicine Ichihara Hospital, Chiba, Japan

Correspondence to: Hiroshi Matsuo, MD, Department of Ophthalmology, The University of Tokyo School of Medicine, 7-3-1 Hongo, Bunkyo-ku, Tokyo, 113-8655, Japan; hmatsuo-ky@umin.ac.jp

The authors have no proprietary interest in the development and marketing of any products mentioned in this article.

Accepted for publication 18 January 2002

References

- 1 Hutchinson AK, Grossniklaus HE, Brown RH, *et al*. Clinicopathologic features of excised mitomycin filtering blebs. *Arch Ophthalmol* 1994;**112**:74-9.
- 2 Belyea DA, Dan JA, Stamper RL, *et al*. Late onset of sequential multifocal bleb leaks after glaucoma filtration surgery with 5-fluorouracil and mitomycin C. *Am J Ophthalmol* 1997;**124**:40-5.
- 3 Sinnreich Z, Barishak R, Stein R. Leaking filtering blebs. *Am J Ophthalmol* 1978;**86**:345-9.
- 4 Addicks EM, Quigley HA, Green WR, *et al*. Histologic characteristics of filtering blebs in glaucomatous eyes. *Arch Ophthalmol* 1983;**101**:795-8.
- 5 Bron AJ, Seal DV. The defences of the ocular surface. *Trans Ophthalmol Soc UK* 1986;**105**:18-25.
- 6 Bergstrom TJ, Wilkinson WS, Skuta GL, *et al*. The effects of subconjunctival mitomycin-C on glaucoma filtration surgery in rabbits. *Arch Ophthalmol* 1991;**109**:1725-30.
- 7 Nuyts RM, Felten PC, Pels E, *et al*. Histopathologic effects of mitomycin C after trabeculectomy in human glaucomatous eyes with persistent hypotony. *Am J Ophthalmol* 1994;**118**:225-37.
- 8 Pasquale LR, Thibault D, Dorman-Pease ME, *et al*. Effect of topical mitomycin C on glaucoma filtering surgery in monkeys. *Ophthalmology* 1992;**99**:14-18.
- 9 Waheed S, Liebmann JM, Greenfield DS, *et al*. Recurrent bleb infections. *Br J Ophthalmol* 1998;**82**:926-9.

Retinal detachment surgery in district general hospitals: an audit of changing practice

Despite advances in the techniques of vitreoretinal surgery, rhegmatogenous retinal detachment (RRD) continues to pose a serious

Table 1 Characteristics of primary RRD in the south west subregion during 1999

Characteristics	No (% of retinal detachments)
Macula attached	60 (47)
Phakic	97 (76)
>6D myopia	33 (26)
Single retinal break	72 (57)
Inferior retinal breaks*	29 (23)
PVR (grade C1 or worse) ³	6 (5)
Total retinal detachment	11 (9)
Types of retinal breaks:	
Horseshoe tears	83 (65)
Round holes	22 (17)
Dialysis	8 (6)
Combined schisis detachment	3 (2)
Giant tear	3 (2)

PVR = proliferative vitreoretinopathy.
*Breaks in the 4 clock hours from 4 to 8 o'clock.

threat to vision. In the past, general ophthalmologists in the United Kingdom undertook most RRD surgery, with only the more "complex" cases being referred to retinal specialists. The recent trend towards subspecialisation has led to increasing numbers of primary RRD being managed by vitreoretinal surgeons in tertiary referral centres.¹

We conducted an audit to determine the current success rate of primary RRD surgery in our subregion (south west subregion, SWSR). SWSR consists of the catchments of four district general hospitals (DGH) in Devon and Somerset (population 1.2 million). A previous subregional audit in 1991 showed that all consultant ophthalmologists undertook primary RRD repair, achieving a success rate of 71% with one operation.² Since then, retinal subspecialisation has meant that all RRDs are managed by three retinal specialists (CJ, PS, RG) in their individual DGHs, providing a subregional surgical retinal service. An informal cross cover arrangement exists between the three DGHs, with the result that patients are very rarely referred out of the subregion.

Case notes of all patients who underwent surgery for primary RRD from January to December 1999 were retrospectively reviewed. Case ascertainment was achieved by reviewing theatre logbooks and identifying all vitreoretinal procedures that took place during 1999. A single investigator (RL) collected details of all the patients; 1999 was chosen so that there was a minimum of 1 year follow up. Retinal reattachment was assumed to be stable in the absence of any history of further retinal surgery in the notes.

The main outcome measures were (1) primary success: retinal reattachment with one operation, with no re-intervention during follow up, (2) final success: retinal reattachment with or without further intervention during follow up, and (3) visual acuity outcome.

The retrieval rate for case notes was 99%. A total of 127 cases (DGH A 36%, DGH B 41%, DGH C 23%) were treated in 1999, with a mean age of 59.6 years (range 14–95).

Table 1 shows the characteristics of the retinal detachments at presentation. There was no significant difference in any of the characteristics listed in Table 1 between the three DGHs (χ^2 test, $p>0.05$). A total of 102 (80%) patients were operated on within 48 hours of presentation. Detachment subtypes in the 20% of operations delayed for more than 48

Table 2 Preoperative and postoperative logMAR visual acuity

	Preop Median (SD)	Postop Median (SD)
Overall (n=127)	0.78 (0.88)	0.18 (0.65)*
Macula attached (n=60)	0.21 (0.62)	0.16 (0.35)*
Macula detached (n=67)	1.83 (0.90)	0.85 (0.65)*
Primary success (n=108)	0.60 (0.88)	0.18 (0.54)*
Primary failures following successful reintervention (n=15)	0.78 (0.90)	0.60 (0.99)

* $p<0.05$, Wilcoxon test.

hours included chronic macula-off detachments (13), chronic inferior detachments with atrophic holes (eight), chronic dialyses (three), and inferior combined schisis detachment (one). No patients with macula-on detachment developed macular detachment before surgery.

Overall, 74 (58%) cases had primary vitrectomy. The three DGHs differed significantly in their surgical approach (primary vitrectomy rate: DGH A 65%, DGH B 40%, DGH C 79%). Consultants performed 85% of all operations, while trainees performed the remainder under supervision.

The primary success rate of retinal reattachment was 85% overall, with a mean of actual documented follow up of 8.2 months (2–25 months). This was a significant improvement from the 71% primary success in 107 cases of primary RRDs in the previous subregional audit ($p<0.05$, χ^2 test). There was no significant difference between the three DGHs in their individual primary success rate (DGH A 87%, DGH B 85%, DGH C 83%). Included in the primary success were three vitrectomy/oil cases that had not undergone oil removal at final follow up.

There were 19 (15%) primary failures. 11 were "early failures" (mean interval to re-detachment 8 days) whose retinas did not reattach, or immediately re-detached after absorption of gas tamponade. They were due to inadequate retinopexy/adhesion (five), new/missed breaks (four), inadequate buckle (one), and proliferative vitreoretinopathy (one). In contrast, the eight "late failures" (mean interval to re-detachment 69 days) all had successful initial reattachment, but subsequently re-detached due to proliferative vitreoretinopathy. Logistic regression with success or "late failures" as the dependent variable found retinal break in a superior position (from 10 to 2 o'clock), myopia >-6 dioptres, and "aphakia"/pseudophakia without an intact posterior capsule, to be significant predictors of "late failures" ($p<0.05$).

A total of 15 primary failures underwent further retinal surgery; 14 patients were reattached with one further operation (one needed two further procedures). The final success rate was 97%. This was not significantly different from the 93% of the previous audit ($p>0.05$, χ^2 test).

Table 2 summarises the visual outcome of our patients, represented by changes in logMAR visual acuity. Visual acuity was significantly improved in the primary success, macula attached and macula detached subgroups ($p<0.05$, the Wilcoxon test). Seventy per cent of primary success patients achieved a Snellen acuity of 6/18 or better at discharge.

Comment

In 1991, all consultant ophthalmologists in our subregion undertook primary RRD surgery, each managing on average 8.2 cases per

year. In the current audit cycle, the caseload had increased to 42 cases per consultant, with three retinal specialists managing all the RRD. Assuming there was no significant change in the detachment case mix between 1991 and 1999, the improvement in the primary success rate is most likely to be associated with the advent of vitreoretinal subspecialisation.³

Results of RRD surgery from three vitreoretinal units (VRU) in the United Kingdom^{1,4,5} provided indicators for comparison. With the exception of pseudophakic rate (Cambridge 12%, SWSR 24%), our case mix was most comparable to the Cambridge subregion,¹ with both series describing RRD from geographically well defined populations. Initially, there would appear to be significant differences in the primary success rate between the four studies (Cambridge VRU 90%, SWSR 85%, St Thomas's 84%, Moorfields 80%, $p<0.05$, χ^2 test). However, it is debatable whether retinal reattachment achieved with silicon oil in situ can be considered "stable." After excluding eyes with silicon oil still in situ, the "oil-out primary success rate" was comparable (Cambridge VRU 80%, SWSR 83%, $p>0.05$, χ^2 test).

The primary success rate, although significantly improved, was not 100%. Improvement on our "early" failures, mostly due to "technical" errors, can be achieved by appropriate choice of surgical technique. For the "late" failures, all consequence of PVR, improvement may depend on the identification of "at-risk" cases,⁶ and the selective use of an "anti-PVR cocktail."⁷

To conclude, we have shown that the primary success rate of RRD surgery has improved following a change in practice towards retinal subspecialisation in our subregion. The anatomical success and functional outcome were comparable to results from other VRUs in the United Kingdom.^{1,4,5} The benefits of providing a local vitreoretinal service, in contrast to referring patients to a VRU in a tertiary centre, include prompt on-site surgical access, and the availability of support from family and friends locally to aid visual rehabilitation in the postoperative period.

R Ling, C James

Department of Ophthalmology, Torbay Hospital, Torquay, UK

P Simcock

West of England Eye Unit, Royal Devon & Exeter Hospital, Exeter, UK

R Gray

Department of Ophthalmology, Musgrave Park Hospital, Taunton, UK

S Shaw

Department of Mathematics and Statistics, University of Plymouth, Plymouth, UK

Correspondence to: Mr R Ling, Department of Ophthalmology, Torbay Hospital, Lawes Bridge, Torquay TQ2 7AA, UK; roland@linghl.fsnet.co.uk

Accepted for publication 11 February 2002

References

- 1 **Comer MB**, Newman DK, George ND, *et al*. Who should manage primary retinal detachments? *Eye* 2000;**14**:572–8.
- 2 **James C**. Results of primary retinal detachment surgery in the south west subregion, September 1990 to August 1991. Presented at the British & Eire Association of Vitreo-Retinal Surgeons meeting, 1992.
- 3 **Retinal Society Terminology Committee**. The classification of retinal detachment with proliferative vitreoretinopathy. *Ophthalmology* 1983;**90**:121–5.
- 4 **Sullivan PM**, Luff AJ, Aylward GW. Results of primary retinal reattachment surgery: a prospective audit. *Eye* 1997;**11**:869–71.
- 5 **Minihan M**, Tanner V, Williamson TH. Primary rhegmatogenous retinal detachment: 20 years of change. *Br J Ophthalmol* 2001;**85**:546–8.
- 6 **Asaria RHY**, Kon CH, Bunce C, *et al*. How to predict proliferative vitreoretinopathy. A prospective study. *Ophthalmology* 2001;**108**:1184–6.
- 7 **Asaria RHY**, Kon CH, Bunce C, *et al*. Adjuvant 5-fluorouracil and heparin prevents proliferative vitreoretinopathy. Results from a randomised, double-blind, controlled clinical trial. *Ophthalmology* 2001;**108**:1179–83.

Do climatic variables influence the development of posterior vitreous detachment?

Posterior vitreous detachment (PVD) is a common condition after the fifth decade of life.¹ Synchysis of the vitreous progresses in proportion to age, creating holes in the posterior hyaloid membrane and allowing PVD to occur.² The incidence of rhegmatogenous retinal detachment is generally accepted to be season dependent, with a higher incidence in the summer months.^{3,4} However, there is no evidence that PVD is season dependent. We performed this study to determine whether there is any correlation between ambient temperatures, humidity, or solar radiance on the incidence of PVD.

Case report

Patients were selected for this study from the eye casualty database at Oxford Eye Hospital. All patient records, which have been diagnostically coded as acute PVD over a 2 year period, were reviewed. Cases where there was a precipitating cause for PVD such as blunt trauma, retinal vascular disease, diabetic retinopathy, previous surgery, or laser treatment were excluded. Only cases with spontaneous PVD were included in the study.

We used three environmental variables—mean daily temperatures in degrees centigrade (°C), percentage relative humidity (both averaged over measurements taken every 10 seconds), and total solar radiation in the day (0.3–3.0 nm) measured in mega joules per square metre (MJ/m²). These data were obtained from the environmental change network site at Wytham, Oxford, UK.⁵ In order to reduce short term variation, we aggregated the occurrences of PVD cases and thus considered the number of cases observed in each week. We also averaged the daily data for environmental variables over each week.

We considered 567 cases with a mean age of 63 years (range 36–89 years). Of these, 319 (53%) were referred by general practitioner, 170 (30%) were self referred, 68 (11.4%) were optician referrals, and the remaining 10

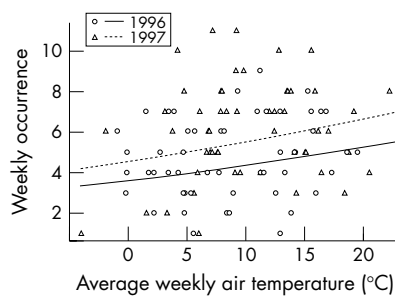


Figure 1 The relation between air temperature and occurrences of PVD.

(1.6%) were referred from another hospital. The average number of new patients attending the eye casualty department at Oxford was 876 per month (range 763–965). The average total number of patients attending the eye casualty department during summer months (April to September) was 912 compared to 839 in the colder months (October to March). Even though there were more visitors in the warmer months compared to the colder months, this difference was not significant (Wilcoxon-Mann-Whitney test p value = 0.1). We also fitted a sine/cosine linear model to test for a seasonal pattern, but did not find it supportive ($p = 0.32$). We also examined the effect of a cyclical pattern for the weekly or monthly occurrences—for instance, the numbers of cases for June, July, and August were 60, 42, and 44 respectively; for December, January, and February they were 27, 48, and 49 respectively. Thus, we proceeded to model the number of PVD cases directly as a function of environmental variables.

There was a significant increase in the average number of occurrences of PVD from 4.23 to 5.49 cases per week between 1996 and 1997 (t test, $p = 0.0019$), so we included year in all models (Fig 1).

We first fitted a model including relative humidity, air temperature, solar radiation, and year. There was evidence of a strong association ($p = 0.035$) between weekly averaged air temperature and the number of occurrences of PVD (Fig 1). However, we did not find a significant association between weekly occurrences of PVD and relative humidity or solar radiation.

We found a significant increase in the variance of the number of occurrences of PVD with increasing weekly temperatures. Accordingly, we used the natural logarithm of occurrences as our response variable; this transformation stabilised the variances. We then fitted a generalised linear model using air temperatures and year as explanatory variables. Both had a significant and direct effect on the log number of occurrences; the regression coefficients were 0.118 (95% confidence interval = 0.022, 0.214) for year and 0.0189 (confidence interval = 0.0015, 0.036) for air temperature. This means that the weekly number of PVD cases increased faster for higher temperatures—for example, for an increase from 5–6 degrees in average air temperature, the rate of increase in weekly number of PVD cases was 0.09 per week and for a temperature change from 20 to 21 it was 0.12. We did not find any evidence of an interaction between air temperature and year; thus, the effect of year was only additive, and the rate of change of log occurrences with respect to air temperatures was the same for both years.

We also found a strong association ($p = 0.028$) between the air temperatures of

the previous week and the number of weekly occurrences and the results were very similar to the same week.

Comment

Vitreous liquefaction, which advances with increasing age, is an important event in the pathogenesis of PVD.⁶

In our study there was no evidence of a cyclical pattern for the weekly or monthly occurrences, therefore we modelled the number of PVD cases directly as a function of the air temperature. Our data suggest a highly significant correlation between weekly average temperatures and the incidence of PVD.

The lack of any previous literature on this subject makes it difficult to draw any conclusions about the mechanism for an increase in PVD occurrences with increasing temperatures. However, we postulate that increasing physical activity and dehydration associated with increasing temperatures may have a role to play.

Further work is necessary in order to investigate the effect of increasing temperatures and/or dehydration on the biochemical structure of the vitreous.

R Rahman, K Ikram, P H Rosen
Oxford Eye Hospital, Oxford, UK

M Cortina-Borja
Department of Statistics, University of Oxford,
Oxford UK

M E Taylor
NERC Centre for Ecology and Hydrology, Oxford
University Field Laboratory, Wytham, Oxford, UK

Correspondence to: Mr Paul H Rosen, Oxford Eye Hospital, Woodstock Road, Oxford OX2 6HE, UK; phrosen@compuserve.com

Accepted for publication 21 November 2001

References

- 1 **Byer NE**. Natural history of posterior vitreous detachment with early management as the premier line of defence against retinal detachment. *Ophthalmology* 1994;**101**:1503–13.
- 2 **Foos RY**, Wheeler NC. Vitreoretinal junction: synchysis senilis and posterior vitreous detachment. *Ophthalmology* 1982;**82**:1502–12.
- 3 **Jonkers GH**. Seasonal variations in the frequency of detachment of the retina. *Ophthalmologica* 1952;**124**:374–6.
- 4 **Paavola M**, Chehova S, Forsius H. Seasonal variations in retinal detachment in northern Finland and Novosibirsk. *Acta Ophthalmol* 1983;**61**:806–12.
- 5 **Morecroft MD**, Taylor ME, Oliver HR. Air and soil microclimates of deciduous woodland compared to an open site. *Agriculture and Forest Meteorology* 1998;**90**:141–56.
- 6 **Sebag J**. *The vitreous: structure, function and pathology*. New York: Springer-Verlag, 1989.

Ocular and systemic posaconazole (SCH-56592) treatment of invasive *Fusarium solani* keratitis and endophthalmitis

An emmetropic 42 year old immunocompetent woman with 6/6 vision developed left eye pain while wearing cosmetic soft contact lenses. She presented on 28 July 2000 to her ophthalmologist, who noted deep stromal infiltration accompanying a 2 × 3 mm pericentral corneal ulcer. Cultures yielded *Staphylococcus aureus*, *Streptococcus viridans*, and

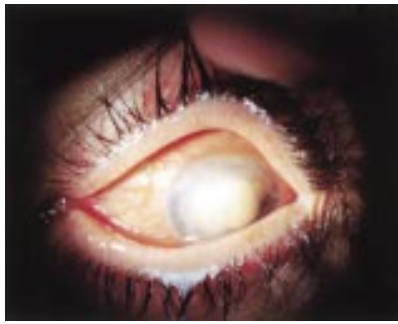

Figure 1 Left eye of 42 year old woman with invasive *Fusarium solani* keratitis/endophthalmitis after 8 weeks of maximal tolerated therapy with natamycin and amphotericin B.

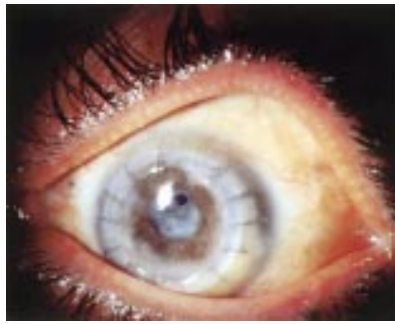

Figure 2 Eye shown in Figure 1 after successful treatment with topical and systemic posaconazole. Status post-penetrating keratoplasty and extracapsular cataract extraction with planned pseudophakia. The removed lens cortex contained fungal hyphae on histopathological assessment.

Fusarium solani. Initial therapy with tobramycin was followed by high dose topical hydroquinolones, whereafter the infection, continuing unabated, was construed to be fungal keratitis. High doses of amphotericin B both topical and intravenously, natamycin, and ketoconazole were administered, along with topical fortified cephalosporin, neosporin, and atropine. Despite these, the lesion spread to involve much of the corneal periphery (Fig 1), and repeat corneal cultures confirmed the presence of amphotericin B resistant *Fusarium spp* (MIC 24:48 hours in µg/ml: amphotericin B 2:2; natamycin 32:32; posaconazole 1:8).

On 1 September 2000, the anterior chamber was filled with fibrin with a central corneal descemetocoele and near total corneal infiltration, affording only a hazy view of the peripheral iris. The fibrin clot was integrated with the central iris, and the lens was not visible. Ultrasonography suggested anterior segment involvement only. Posaconazole (SCH-56592),¹⁻⁶ an investigational broad spectrum triazole, was obtained from Schering-Plough Research Corporation and administered at 200 mg four times daily orally, with hourly topical ocular application of the same suspension (10 mg/0.1 ml). A compassionate use investigational new drug (IND) approval for topical ocular application of posaconazole was requested from, and promptly issued by, the Federal Drug Administration, and informed consent was obtained through an institutional review board approved protocol. Treatment commenced 5 September 2000, when aqueous tap reconfirmed presence of *Fusarium*, which was susceptible in vitro to posaconazole.

Within the first week of 2 hourly topical application of posaconazole oral suspension (100 mg/ml), along with 800 mg orally of the same daily, there was significant clearing of the corneal periphery. The fibrin clot melted concentrically, revealing its attachment to the descemetocoele anteriorly and central iris posteriorly.

With further clearing of the infectious inflammatory clot, the anterior descemetocoele became effectively unplugged. The globe decompressed through the open corneal ulcer providing the impetus for urgent penetrating keratoplasty on 20 September 2000. Histology revealed innumerable septate branching fungi within the corneal and iris stroma.

One week later, further remarkable improvement was noted. Despite the ominous surgical histology, >90% of the fibrin clot had cleared. Diagnostic vitrectomy yielded posaconazole at a concentration of 0.25 µg/ml in the vitreous (and 1.2 µg/ml in the plasma) on 26

September 2000. Vision improved markedly, with good projection to confrontational light throughout the periphery. The clarity of the transplant and anterior chamber now revealed a dense white cortical cataract, with residual fibrin clot inferior to the graft-host interface. Topical corticosteroid therapy was cautiously introduced. By 30 October 2000 the patient's condition was further improved, and elective combined phacoemulsification with planned aphakia was carried out on 11 January 2001. Branching elements of the *Fusarium* were histologically confirmed to have penetrated the surgically removed anterior lens cortex and capsule, but all subsequent cultures were negative, and aqueous tap confirmed posaconazole to be present at a level of 0.9 µg/ml, with a plasma level of 1.6 µl/ml.

At 16 months, on 4 December 2001, vision remained stable with good colour vision and 360 degree peripheral visual function. The visual axis was clear, with two small clear operculi in the otherwise opaque residual posterior capsule (Fig 2). Visual acuity was 6/30 using aphakic correction, with no afferent pupil defect. Prognosis for eventual lens replacement, posterior capsulotomy, and visual rehabilitation of this eye now appeared very good. This excellent outcome is not anticipated for invasive *Fusarium* of the eye.⁷⁻¹⁰

In summary, a healthy woman with amphotericin and natamycin resistant *Fusarium spp* keratitis, progressing to invasive endophthalmitis, recovered with good retinal function via an apparently rapid response of the *Fusarium* to systemic and/or topical posaconazole. The ocular penetration of posaconazole was confirmed on separate occasions by aqueous and vitreous analysis.

Acknowledgements

Investigative new drug evaluation under UTHSCSA IRB P00041 (6/28/98; modified open label treatment protocol for the safety and efficacy of SCH 56592 (posaconazole) in the treatment of refractory mycoses).

The authors gratefully acknowledge the assistance of Gilbert Viprao in coordinating this study, and Schering-Plough for providing the study drug and funding for Mr Viprao.

Supported in part by an unrestricted grant from Research to Prevent Blindness, New York, USA.

The authors have no proprietary interest in any products used in this assessment.

W E Sponsel

Department of Ophthalmology, University of Texas Health Science Center, San Antonio, Texas, USA

J R Graybill

Division of Infectious Diseases in the Department of Medicine

H L Nevarez

Vista Eye Associates

D Dang

Department of Ophthalmology, University of Texas Health Science Center

Correspondence to: William Sponsel, Director of Clinical Research, Ophthalmology, 7703 Floyd Curl Drive, San Antonio, TX 78229-3900, USA; sponsel@uthscsa.edu

Accepted for publication 8 February 2002

References

- Cacciapuoti A, Loebenberg D, Corcoran E, et al. In vitro and in vivo activities of SCH 56592 (posaconazole), a new triazole antifungal agent, against *Aspergillus* and *Candida*. *Antimicrob Agents Chemother* 2000;**44**:2017-22.
- Feng W, Liu H, Chen G, et al. Structural characterization of the oxidative degradation products of an antifungal agent SCH 56592 by LC-NMR and LOC-MS. *J Pharm Biomed Anal* 2001;**25**:545-57.
- Walsh TJ, Viviani MA, Arathoon E, et al. New targets and delivery systems for antifungal therapy. *Med Mycol* 2000;**38**:335-47.
- Graybill JR. Changing strategies for treatment of systemic mycoses. *Braz J Inf Dis* 2000;**4**:47-54.
- Hossain MA, Ghannoum MA. New investigational antifungal agents for treating invasive fungal infections. *Expert Opin Investig Drugs* 2000;**9**:1797-813.
- Uchida K, Yokota N, Yamaguchi H. In vitro antifungal activity of posaconazole against various pathogenic fungi. *Int J Antimicrob Agents* 2001;**18**:167-72.
- Cheikh-Rouhou F, Makni F, Ayadi A, et al. Ocular parasitoses and mycoses: cases diagnosed in the Central University Hospital of Sfax between 1996 and 1999. *Bull Soc Pathol Exot* 2001;**94**:11-13.
- Gupta V, Dada T, Vajpayee RB, et al. Polymicrobial keratitis after laser in situ keratomileusis. *J Refract Surg* 2000;**17**:147-8.
- Faroozan R, Eagle RC Jr, Cohen EJ. Fungal keratitis in a soft contact lens wearer. *CLAO J* 2000;**26**:166-8.
- Guarro J, Pujol I, Mayayo E. In vitro and in vivo experimental activities of antifungal agents against *Fusarium solani*. *Antimicrob Agents Chemother* 1999;**43**:1256-7.

World Sight Day and cataract blindness

Age related cataract remains the major cause of blindness throughout the world.¹ It is estimated that the present number of 20 million of cataract blind will double by the year 2020. The main reasons for low uptake of cataract surgery in developing countries are poor surgical outcome² and high cost. Various strategies have been suggested by the global initiative "Vision 2020: the right to sight" to reduce cataract blindness.³

In Nepal, on "World Sight Day," Lahan Eye Hospital and Tilganga Eye Centre jointly convened a one week cataract surgical "workshop" from 8-13 October 2001. A total of 1542 patients with operable cataract were identified in 49 screening camps in rural areas of south east Nepal and transported to Lahan Eye Hospital. During 6 days 2292 eye operations were performed, of which 2167 were cataract extractions (range 286-594 per day).

The operations were performed by a six experienced eye surgeons using a situreless non-phaco technique, removing the nucleus

Table 1 Uncorrected visual acuity at discharge

Acuity	Number	%
6/6–6/18	1054	49.9
<6/18–6/60	997	47.1
<6/60	64	3.0

Table 2 Reasons for poor visual outcome at discharge (<6/60)

Cause	Number	%
Pre-existing eye disease	34	1.6
Surgical complication	25	1.2
Refractive error	4	0.2
Unknown	1	<0.1
Total	64	3.0

through a self sealing corneoscleral tunnel. Biometry was performed and a calculated PC IOL inserted in 374 (18%) cases; the remaining 1741 (82%) received a +22 dioptre PC IOL.

After excluding 23 cataract operations on children, 21 combined glaucoma procedures, and eight lens induced glaucoma surgeries, the surgical outcome on the remaining 2115 cataract extractions was evaluated.

The uncorrected visual acuity at discharge (94% on first postoperative day) was 6/6–6/18 in 49.9% and less than 6/60 in 3.0% of eyes (Table 1). The reasons for poor outcome are shown in Table 2.

The cost of consumables including IOL, medicines, anaesthesia, viscoelastic, irrigation solution, disinfectant, and dressings was less than \$10 per cataract operation.

Well organised cataract screening camps combined with efficient base hospital surgery, using a safe surgical technique which provides early and good visual outcome, can be a strategy to reduce the backlog of cataract blindness in rural communities in developing countries.

**A Hennig, J Kumar, A K Singh,
A Ansari, S Singh**

Sagamatha Choudhary Eye Hospital, Lahan,
Nepal

R Gurung

Tilganga Eye Centre, Kathmandu, Nepal

A Foster

Clinical Research Unit, London School Hygiene and
Tropical Medicine, London WC1E 7HT, UK

Correspondence to: Allen Foster

Accepted for publication 5 December 2001

References

- 1 **Thylefors B**, Negrel A-D, Pararajasegaram R, *et al*. Global data on blindness. *Bull World Health Org* 1995;**73**:115–21.
- 2 **Shrestha JK**, Pradhan YM, Snellingen T. Outcomes of extracapsular surgery in eye camps of eastern Nepal. *Br J Ophthalmol* 2001;**85**:635–7, and 648–52.
- 3 **Foster A**. Cataract and “Vision 2020—the right to sight” initiative. *Br J Ophthalmol* 2001;**85**:635–7.

MAILBOX

Failure of amniotic membrane transplantation in the treatment of acute ocular burns

We read with interest the article by Joseph *et al*.¹ It is to be appreciated that they have come forward to report the negative results of their study along with the need of an upgraded classification for the chemical burn. The authors must be congratulated for highlighting the pitfalls of amniotic membrane transplantation (AMT) in acute cases with sufficient scientific explanation.

Whenever a new technique is described it is aggressively followed without realising the consequences. The authors have very rightly suggested that the most important strategy for the management of thermal and chemical burns in the acute stage is to reduce inflammation, promote vascularisation of the ischaemic ocular surface, and epithelialisation of the cornea. It is reported in the literature that AMT does help in all these three conditions at the acute stage of burns for which the procedure is advocated,² but when and to what stage? It is essential to have some amount of healthy conjunctival tissue for graft to take up. Further, rather than performing the AMT at an acute stage, there should be some time lag between burn and surgery. This may help to reduce inflammation, thus allowing the surgeons to perform an elective surgery. Regarding the stage of the chemical burn, the authors have rightly pointed out that there is a remarkable limitation in modified Roper Hall's classification at grade IV.³ Do the eyes with 100% limbal ischaemia behave in the same way as those with 55% ischaemia?¹

It was thought of back in 1984 and a modified classification was suggested in these eyes before keratoplasty as a prognostic factor.⁴ However, the same factor was restricted to healed lesions and now the time has come for the modification to be needed for acute lesions.

Once again we would like to commend the authors for their boldness and wonder how many other corneal surgeons would have felt the same.

A Panda, S K Nainiwal, R Sudan

Dr Rajendra Prasad Centre for Ophthalmic Sciences, All India Institute of Medical Sciences, New Delhi - 110029, India

Correspondence to: Dr Anita Panda, DII/36, Ansari Nagar, All India Institute of Medical Sciences, New Delhi 29, India; anitap49@yahoo.com

References

- 1 **Joseph A**, Dua HS, King AJ. Failure of amniotic membrane transplantation in the treatment of acute ocular burns. *Br J Ophthalmol* 2001;**85**:1065–9.
- 2 **Mellor D**, Renato TF, Pires, *et al*. AMT for acute chemical or thermal burns. *Ophthalmology* 2001;**107**:980–90.
- 3 **Roper Hall MJ**. Thermal and chemical burns. *Trans Ophthalmol Soc UK* 1965;**85**:631–40.
- 4 **Panda A**, Mohan M, Gupta AK, *et al*. Keratoplasty in alkali burned corneas. *Indian J Ophthalmol* 1984;**32**:441–6.

“No-needle” sub-Tenon's anaesthesia

We read with interest the letter from Amin *et al*,¹ suggesting a modification of the sub-Tenon local anaesthetic injection procedure. They advocate the use of a Venflon needle to penetrate the conjunctiva, with subsequent advancement of the cannula before anaesthetic injection. We are concerned that the use

of a sharp needle should be recommended so close to the eye. Amin *et al* point out that the needle tip is clearly visible at all times and therefore at “minimal risk” of puncturing the eye. However, once under the conjunctiva, the needle is not necessarily “clearly” visible, and if subconjunctival haemorrhage should occur then it will quickly become obscured. We do not think it sensible to place a sharp needle this close to the eye when an effective and well proved alternative delivery system has already stood the test of time.²

In his editorial on local anaesthetic injection techniques for cataract surgery, Smerdon³ rightly emphasises the risk of ocular penetration for all techniques involving needles, and highlights the Royal College of Ophthalmologists' local anaesthesia survey⁴ which demonstrated the relative safety of sub-Tenon's and topical anaesthesia. We agree with him that when discussing an anaesthetic technique with a potential for high volume, it is not the expert anaesthetist/ophthalmologist who should be borne in mind, but rather the less skilled person, possibly less familiar with ophthalmic anaesthetic techniques, or in training, who may be required to administer a block. It is in this setting that the use of a needle very close to the eye is, in our opinion, an unwarranted risk. Surely the “no needle” sub-Tenon's technique is just as effective, and safer.

R Gray

Department of Ophthalmology, Taunton and Somerset NHS Trust, Musgrove Park, Taunton TA1 5DA, UK

J Lucas

Department of Anaesthesia

References

- 1 **Amin S**, Minihan M, Lesnik-Oberstein S, *et al*. A new technique for delivering sub-Tenon's anaesthesia in ophthalmic surgery. *Br J Ophthalmol* 2002;**86**:119.
- 2 **Stevens JD**. A new local anaesthesia technique for cataract extraction by one quadrant sub-tenon's infiltration. *Br J Ophthalmol* 1992;**76**:670–4.
- 3 **Smerdon D**. Needle local anaesthesia for cataract surgery: a chip off the old block? *Eye* 2001;**15**:439–40.
- 4 **Eke T**, Thompson JR. The national survey of local anaesthesia for ocular surgery. II. Safety profiles of local anaesthesia techniques. *Eye* 1999;**13**:196–204.

Trachoma and recurrent trichiasis

It was with great interest that I read the recent article by al Arab and co-workers.¹ This work clearly shows that endemic blinding trachoma continues to be a major health problem in this area of the Nile Delta, quite close to Cairo.

My attention was particularly drawn to the high rate of recurrence among those who had had trichiasis surgery. Overall, 44% of cases who had had surgery had recurrent trichiasis. It would be most interesting to look at the time that had elapsed between surgery and the time of examination. Some have argued that the recurrence rate from trichiasis reflects poor or inadequate surgery. Others have alluded to the fact that the tarsal scarring trachoma is of a progressive nature and that trichiasis is likely to recur because of ongoing scarring, even after otherwise successful surgery. Information of the elapsed time would help explore the scenario.

H R Taylor AC

Centre for Eye Research Australia, University of Melbourne, 32 Gisborne Street, East Melbourne 3002, Australia; h.taylor@unimelb.edu.au

Reference

- 1 **Al Arab GE**, Tawfik N, El Gendy R, *et al*. The burden of trachoma in the rural Nile Delta of Egypt; a survey of Menofiya governorate. *Br J Ophthalmol* 2001;**85**:1406–10.

Role of autologous serum in persistent epithelial defects

Poon *et al*¹ in their excellent article have reiterated the efficacy of autologous serum in the treatment of persistent epithelial defects (PEDs) of the cornea. We would like to invite the attention of the authors to certain aspects of the study.

The authors have considered a period of 1 week for labelling an epithelial defect to be persistent. However, most studies on a similar subject have taken the criterion to be 2 weeks.²

It is generally recommended that a “wash-out” period of at least 2 weeks be given with preservative free artificial tears³ and only those epithelial defects that remain either static or demonstrate an increase in size in this period be included in the study. The authors have not mentioned such a washout period being included in the protocol. When using autologous serum drops most investigators have not used any other therapeutic modality at the same time to enhance epithelialisation, apart from preservative free lubricants. The use of therapeutic contact lenses in five cases by the authors makes it difficult to evaluate the actual contribution of serum drops in the healing of the epithelial defect in these cases. Further, the use of serum drops in the immediate postoperative period in two patients with poor ocular surface undergoing keratoplasty without waiting for the corneal epithelial defect to heal by itself cannot be extrapolated to making a comment on the beneficial effect of autologous serum. Also the rationale behind the use of 100% serum when previous studies have proved the efficacy of a 20% solution² is not understandable. This concentrated serum can cause stickiness, which would be inconvenient to the patients and may reduce the compliance. The use of the slit lamp micrometre by the authors for measuring the epithelial defects may not be accurate because of its inherent interobserver and intraobserver variations. A better method would be measuring the area of the defect instead of the greatest dimensions by the use of digital photographs and area measuring software such as Image Pro Plus available from Media Cybernetics.

N Mukerji, R Sinha, R B Vajpayee

Rajendra Prasad Centre for Ophthalmic Sciences,
All India Institute of Medical Sciences,
New Delhi, India

Correspondence to: Rasik B Vajpayee, RP Centre for Ophthalmic Sciences, All India Institute of Medical Sciences, New Delhi - 110029, India; rasikvajpayee@rediffmail.com

References

- 1 **Poon AC**, Geerling G, Dart JKG, *et al*. Autologous serum eyedrops for dry eyes and epithelial defects: clinical and in vitro toxicity studies. *Br J Ophthalmol* 2001;**85**:1188–97.
- 2 **Tsubota K**, Goto E, Shimmura S, *et al*. Treatment of persistent epithelial defect by autologous serum application. *Ophthalmology* 1999;**106**:1984–9.
- 3 **Gordon JF**, Johnson P, Musch DC. Topical fibronectin ophthalmic solution in the treatment of persistent defects of the corneal epithelium. *Am J Ophthalmol* 1995;**119**:281–7.

A re-analysis of astigmatism correction

In a recent perspective by Morlet *et al*¹ there are a number of omissions and fundamental errors of content that lead to erroneous conclusions. These significant inaccuracies overlooked in the review process compromise the article's broad contribution.

In Morlet *et al*'s attempt to detail “the use and limitations of vectors . . . for the analysis of change in astigmatism” (p 1127) they display an incomplete understanding of the subject. They have made a valiant attempt to assemble an abundance of historical and contemporary references on a subject of significant interest, but key material has been omitted or misquoted. This has resulted in leading statements in the article, in both the body of the text and even the conclusion, that require re-evaluation and substantial revision.

The most obvious omission is the paper's absence of any discussion of the difference vector, a precise *absolute* measure of surgical error described in reference 70.² When the difference vector is related to the treatment (that is, TIA or target induced astigmatism vector) one has an extremely useful *relative* value of success of astigmatism treatment. Morlet *et al* have overlooked this key vectorial entity and struggle to find any useful alternative. In sharp contrast Dr Doug Koch, editor of the *Journal of Cataract and Refractive Surgery*, in his editorial introduction to the analysing astigmatism issue of January 2001³ described the difference vector and the index of success as “remarkably useful and intuitive means of understanding the effects of the surgery.”

The authors state more than once for their principal foundation of the article that “Vector analysis alone does not provide any indication of the relative value of the surgical procedure” (p 1132). These statements are erroneous, and the authors' failure to discuss or dispute the value of the difference vector and index of success leaves the assertion unsupported and lacking credibility. If the surgical induced astigmatism vector (SIA) (and its further translation) was the only product of vector analysis, indeed vector analysis would be a limited tool. This seems to be Morlet *et al*'s contention. This is far from the truth and as a result the restatement in the conclusion that “vector analysis does not give a measure of outcome” (p 1134) is factually inaccurate.

In addition, their interpretation that the off-axis effects of treatment at 45° to the surgical plane are deemed to be rotation, would more accurately be termed “torque,” the component of the SIA that has been ineffective in reducing astigmatism. The relevant reference⁴ describing flattening, steepening, torque, and effect of off-axis treatments has been omitted from the attempt at a comprehensive list of relevant published material. The phenomena of rotation and torque are fundamentally different physical processes. The polar value at 45° to the “surgical plane” (p 1131) quantifies the torque which causes an increase in the existing astigmatism associated with its change in orientation. It does not properly gauge the cylinder rotation where no concurrent change in the amount of existing astigmatism occurs. Rotation includes some associated flattening (or steepening) effect occurring as a result of the SIA.

The article's conclusion that “a better evaluation of the effect of astigmatism axis requires the use of the ‘by the rule’ or mirror equivalent axis notation, or by a manual scoring method to produce an outcome summary measure” (p 1134) is convoluted and unwork-

able. If implemented this would adversely affect the comprehension of astigmatism outcome analysis by the average general ophthalmic or refractive surgeon.

It is unfortunate the reviewers of this paper did not direct the author to other significant fallacies that merited revision. The statement “vector analysis is only valid in the early post-operative period” because “the healing response has modified the initial result of the surgery” (p 1131) shows the authors' failure to understand that the healing response cannot be divorced from the surgical process. It is part of it. The amount of astigmatism correction (SIA/TIA) achieved shows consistent trends over time when examining aggregate data, and this phenomenon requires surgeons to examine outcomes facilitating adjustment of nomograms based on long term (at least 6 months) and not immediate outcomes. The later statement “the use of vector analysis over time is conceptually invalid, because unlike the initial surgical event, the wound healing process is continuous” (p 1132) is seriously flawed. Vector analysis is an essential component of this refinement process. In fact, vector analysis could be used to determine the astigmatic effect of the healing process itself by comparison of data at various stages in the postoperative period.

The recommendations promoted by Morlet *et al* introduce greater complexity to an already complicated subject. For example, mixing negative and positive cylinder notation is unnecessary. The technique put forward (p 1131 and equation 20) does not address the changes that occur in corneal shape as measured by keratometry and topography, and cannot be readily applied when targeting non-zero goals associated with incomplete or off-axis refractive astigmatism treatments.

It is probable that the authors are careless in raising phantom “problems” (p 1128) for planning techniques based on incorrect quoting of information (such as reference 33).⁶ The merits of this customised treatment technique are that refractive as well as keratometric data are employed (contrary to its misrepresentation that the technique “only uses keratometric data for the planning of refractive surgery” (p 1128)).

Morlet *et al*'s unfortunate statement of opinion that “a lack of critical evaluation” has resulted in “the surgical vector's adoption as the de facto standard used in most reports concerning the surgical management of astigmatism” (p 1132) is not shared by many experienced investigative surgeons in the field. This has been shown by its admitted prevalence by the authors, and the usefulness of vectorial analysis in understanding the surgical process.⁵ Indeed, many of the erroneous statements and omissions in the Perspective article might lead one to ask where the “lack of critical evaluation” actually lies.

N Alpins

7 Chesterville Road, Cheltenham 3192, Australia

References

- 1 **Morlet N**, Minassian D, Dart J. Astigmatism and the analysis of its surgical correction. *Br J Ophthalmol* 2001;**85**:1127–38.
- 2 **Alpins NA**. A new method of analysing vectors for changes in astigmatism. *J Cataract Refract Surg* 1993;**19**:524–33.
- 3 **Koch DD**. How should we analyze astigmatic data? *J Cataract Refract Surg* 2001;**27**:1–3.
- 4 **Alpins NA**. Vector analysis of astigmatism changes by flattening, steepening and torque. *J Cataract Refract Surg* 1997;**23**:1503–14.
- 5 **Alpins NA**. Astigmatism analysis by the Alpins method. *J Cataract Refract Surg* 2001;**27**:31–49.
- 6 **Alpins NA**. New method of targeting vectors to treat astigmatism. *J Cataract Refract Surg* 1997;**23**:63–75.

BOOK REVIEW



The Hole In My Vision: An Artist's View of His Own Macular Degeneration.

Lee Alien, H Stanley Thompson, James C Folk. Pp 117; \$100. The Penfield Press, University of Iowa, 2000. ISBN 1-57216-085-3 (cloth), 1-57216-084-5 (paper).

This text provides an illuminating and unique insight into the entoptic phenomena induced by the development of age related macular degeneration. Written primarily by a distinguished ophthalmic artist and photographer, it records his visual impressions of the development of age related macular degeneration in his own retinas during a 10 year period. His method of inducing and illustrating his entoptic phenomena is fascinating and the correlation with the clinical fundus findings of his attending ophthalmologists quite remarkable. The effect of laser photocoagulation is clearly described from a patient's perspective.

This book is written in large print for the lay sufferer and ophthalmic professional alike. It is an easy read with plentiful illustrations and should occupy the bookshelf of all concerned with this potentially blinding disorder. Profits derived from the sale of this book will be used to support age related macular degeneration research.

R McFadzean

Department of Neuro-ophthalmology, Institute of Neurological Sciences, Glasgow, UK

NOTICES

Childhood blindness

The latest issue of *Community Eye Health* (No 40) discusses new issues in childhood blindness, with an editorial by Clare Gilbert, senior lecturer at the International Centre for Eye Health. For further information please contact: Journal of Community Eye Health, International Centre for Eye Health, Institute of Ophthalmology, 11-43 Bath Street, London EC1V 9EL, UK (tel: +44 (0)20 7608 6910;

fax: +44 (0)20 7250 3207; email: eyeresource@ucl.ac.uk; website: www.jceh.co.uk. Annual subscription (4 issues) UK£25/US\$40. Free to workers in developing countries.

International Centre for Eye Health

The International Centre for Eye Health has published a new edition of the *Standard List of Medicines, Equipment, Instruments and Optical Supplies* (2001) for eye care services in developing countries. It is compiled by the Task Force of the International Agency for the Prevention of Blindness. Further details: Sue Stevens, International Centre for Eye Health, 11-43 Bath Street, London EC1V 9EL, UK (tel: +44 (0)20 7608 6910; email: eyeresource@ucl.ac.uk).

Second Sight

Second Sight, a UK based charity whose aims are to eliminate the backlog of cataract blind in India by the year 2020 and to establish strong links between Indian and British ophthalmologists, is regularly sending volunteer surgeons to India. Details can be found at the charity website (www.secondsight.org.uk) or by contacting Dr Lucy Mathen (lucymathen@yahoo.com).

Specific Eye ConditionS (SPECS)

Specific Eye ConditionS (SPECS) is a not for profit organisation which acts as an umbrella organisation for support groups of any conditions or syndrome with an integral eye disorder. SPECS represents over fifty different organisations related to eye disorders ranging from conditions that are relatively common to very rare syndromes. We also include groups who offer support of a more general nature to visually impaired and blind people. Support groups meet regularly in the Boardroom at Moorfields Eye Hospital to offer support to each other, share experiences and explore new ways of working together. The web site www.eyeconditions.org.uk acts as a portal giving direct access to support groups own sites. The SPECS web page is a valuable resource for professionals and may also be of interest to people with a visual impairment or who are blind. For further details about SPECS contact: Kay Parkinson, SPECS Development Officer (tel: +44 (0)1803 524238; email: k@eyeconditions.org.uk; www.eyeconditions.org.uk).

The British Retinitis Pigmentosa Society

The British Retinitis Pigmentosa Society (BRPS) was formed in 1975 to bring together people with retinitis pigmentosa and their families. The principle aims of BRPS are to raise funds to support the programme of medical research into an eventual cure for this hereditary disease, and through the BRPS welfare service, help members and their families cope with the everyday concerns caused by retinitis pigmentosa. Part of the welfare service is the telephone helpline (+44 (0)1280 860 363), which is a useful resource for any queries or worries relating to the problems retinitis pigmentosa can bring. This service is especially valuable for those recently diagnosed with retinitis pigmentosa, and all calls are taken in the strictest confidence. Many people with retinitis pigmentosa have found the Society helpful, providing encouragement, and support through the Helpline, the welfare network and the BRPS branches throughout the UK. (tel: +44 (0)1280 821 334; email: lynda@brps.demon.co.uk; web site: www.brps.demon.co.uk)

Singapore National Eye Centre 5th International Meeting

The Singapore National Eye Centre 5th International Meeting will be held on 3-5 August 2002 in Singapore. Further details: Ms Amy Lim, Organising Secretariat, Singapore National Eye Centre, 11 Third Hospital Avenue, Singapore 168751 (tel: (65) 322 8374; fax: (65) 227 7290; email: Amy_Lim@snecc.com.sg).

Ophthalmic Anesthesia Society (OAS) 16th Scientific Meeting

The 16th Scientific Meeting of the OAS will be held on 4-6 October 2002 in The Westin, Michigan Avenue, 909 North Michigan Avenue, Chicago, USA (reservations +1 800 228 3000). Further details: OAS, 793-A Foothill Blvd, PMB 110, San Luis Obispo, CA 93405, USA (tel: +1 805 771 8300; web site: www.eyeanesthesia.org).

BEAVRS Meeting

The next BEAVRS meeting will be held in the Dalmahey Hotel near Edinburgh on 31 October to 1 November 2002. Further details: Susan Campbell, Medical Secretary, Gartnavel General Hospital (email: susan.j.campbell.wg@northglasgow.scot.nhs.uk).



Retinal detachment surgery in district general hospitals: an audit of changing practice

R Ling, C James, P Simcock, et al.

Br J Ophthalmol 2002 86: 827-829

doi: 10.1136/bjo.86.7.827-a

Updated information and services can be found at:

<http://bjo.bmj.com/content/86/7/827.2.full.html>

These include:

References

This article cites 4 articles, 1 of which can be accessed free at:

<http://bjo.bmj.com/content/86/7/827.2.full.html#ref-list-1>

Email alerting service

Receive free email alerts when new articles cite this article. Sign up in the box at the top right corner of the online article.

Notes

To request permissions go to:

<http://group.bmj.com/group/rights-licensing/permissions>

To order reprints go to:

<http://journals.bmj.com/cgi/reprintform>

To subscribe to BMJ go to:

<http://group.bmj.com/subscribe/>