

## SCIENTIFIC CORRESPONDENCE

# Trypan blue assisted phacoemulsification in corneal opacities

P Bhartiya, N Sharma, M Ray, R Sinha, R B Vajpayee

*Br J Ophthalmol* 2002;**86**:857–859

**Aim:** To evaluate the efficacy of trypan blue for enhancing visualisation during phacoemulsification and foldable lens implantation in cases of cataract with corneal opacities.

**Methods:** 11 eyes of 11 patients with nebulomacular corneal opacities involving the visual axis with partially and visually debilitating cataract underwent trypan blue assisted phacoemulsification with foldable intraocular lens implantation. The patients were followed at the first day, first week, first month, and third month postoperatively. Completion of capsulorhexis, phacoemulsification with foldable lens implantation, and postoperative best corrected visual acuity were measured.

**Results:** The dye improved visualisation of the anterior capsule and a complete capsulorhexis could be performed successfully in all eyes. In all but one eye phacoemulsification was accomplished successfully. In one eye with Fuchs' dystrophy penetrating keratoplasty was performed later. Visual acuity was  $\leq 6/60$  preoperatively in all eyes and improved to  $\geq 6/24$  in eight eyes postoperatively.

**Conclusion:** Trypan blue assisted phacoemulsification may be performed in selected cases of corneal haze/opacification with cataract. It provides acceptable visual outcome in cases awaiting penetrating keratoplasty or in cases where it is not feasible or promising.

Trypan blue is used to stain the capsule for better visibility during capsulorhexis in white cataracts.<sup>1,2</sup> Trypan blue 0.1% has been used clinically to examine endothelial cell damage after cataract extraction without adverse effects during 8 years of follow up.<sup>3</sup> Furthermore, trypan blue is routinely used to examine the endothelial cell layer of donor corneoscleral buttons before corneal transplantation.<sup>4</sup> Trypan blue 0.1% has not been found to be harmful to the endothelium in a clinical study in which endothelial counts and morphology were evaluated both preoperatively and postoperatively.<sup>5</sup> It is unlikely to have a toxic effect on the endothelium or other intraocular structures especially since it is washed out immediately. However, its use in pregnant women or in children is still controversial because of the possible teratogenic effect. Besides white cataract, capsular staining is helpful where the red reflex is poor or visualisation of the capsule is compromised. These may include situations such as asteroid hyalosis, corneal scarring, corneal oedema, or a dark brunescient nucleus. Corneal haze can impede adequate visibility even in the presence of an adequate fundus glow. We had been performing routine extracapsular cataract extraction and a 6.5 mm optic poly(methylmethacrylate) (PMMA) intraocular lens implantation in those cases of cataract with corneal opacification where it was not possible to clearly visualise the anterior capsule to be able to perform a capsulorhexis. The role of capsular staining for such cases with impaired visualisation due to corneal haze has not been previously described. We report our experience in these cases.

## METHODS

Eleven eyes of 11 patients with cataract and nebulomacular corneal opacities due to various aetiologies (Table 1) were recruited prospectively from the cornea service of the Dr Rajendra Prasad Centre for Ophthalmic Sciences, New Delhi, a tertiary eye care referral centre.

Inclusion criteria consisted of the presence of corneal opacification involving the visual axis partially, along with the presence of visually debilitating cataract. Only those cases where the anterior capsule and the pupillary margin were visible with the brightest illumination of the slit lamp were taken. A final decision to perform dye assisted capsulorhexis and subsequent phacoemulsification surgery was taken only in those cases where the surgeon felt that even with the brightest illumination of the microscope, the anterior capsule is not sufficiently visible to facilitate a capsulorhexis without the dye. These patients had not been subjected to the combined surgery of simultaneous penetrating keratoplasty with cataract extraction as they were waiting their turn for corneal transplantation or in view of poor graft survival, poor patient compliance, and inability to follow up on a long term basis. Eyes in which dense leucomatous corneal opacification was present in the direct visual axis were excluded.

A complete history was taken in all patients and all eyes had an ambulatory vision before the onset of cataract. A thorough ocular examination under a slit lamp microscope was performed in all eyes. A posterior segment evaluation was done on ultrasonography to rule out any posterior segment pathology as the fundus examination was not possible because of media haze from corneal and lenticular haze. The preoperative factors evaluated were, the aetiology of the corneal opacification, the type of cataract, and the preoperative best corrected visual acuity.

All surgeries were performed under peribulbar lidocaine (Xylocaine 2%, Astra-IDL) and bupivacaine (Sensoricaine 0.5%, Astra-IDL) (1:1) anaesthesia. A side port was made and a clear corneal tunnel was fashioned at the 12 o'clock meridian. Sterile air was injected into the anterior chamber through the side port incision. A volume of 0.1 ml of 0.1% trypan blue (Vision Blue, Dorc International, Netherlands) was injected under the air bubble over the anterior capsule with a 27 gauge cannula. The anterior chamber was deepened with air to allow even contact of the dye with the lens capsule and then washed with balanced salt solution after waiting for 10 seconds. High viscosity viscoelastic (Healon GV; Pharmacia Upjohn, Kalamazoo, USA) was injected into the anterior chamber. Capsulorhexis was initiated with a bent 26 gauge needle and a capsulorhexis forceps was used for completing a continuous curvilinear capsulorhexis. Following hydro procedures, phacoemulsification was accomplished by a "stop and chop" manoeuvre using a Venturi based machine (Protégé; Bausch and Lomb, Surrey). Automated irrigation and aspiration was done and a foldable three piece acrylic lens (Acrysof; Alcon Labs, Fort Worth, TX, USA) was implanted using a holder and folder. Viscoelastic was then aspirated using an automated irrigation and aspiration. Stromal hydration of the wound and

**Table 1** Clinical characteristics and surgical details of the patients

Case	Age (years)	Sex	Eye	Aetiology	Type of cataract	Preoperative BCVA	Postoperative BCVA	Comments
1	48	M	RE	Granular dystrophy	Posterior subcapsular cataract	3/60	6/18	–
2	35	F	LE	Operated lamellar graft for Stevens-Johnson syndrome	Hypermaturation white cataract	Counting fingers	6/60	–
3	52	M	RE	Fuchs' dystrophy with trichomatous scarring	Nuclear cataract	3/60	Counting fingers	Increase in haze intraoperatively and postoperatively. Visual acuity 6/36 after penetrating keratoplasty
4	62	F	LE	Operated patch graft	Cortical cataract	5/60	6/24	–
5	53	M	LE	Healed viral keratitis	Cortical cataract	6/60	6/18	–
6	78	M	RE	Ocular surface disorder	Corticocapsular cataract	4/60	6/12	–
7	65	F	LE	Healed keratitis with posterior crocodile shagreen	Nuclear cataract	6/36	6/9	–
8	62	F	RE	Bilateral healed viral keratouveitis	Cortical and posterior subcapsular cataract	6/60	6/12	–
9	75	M	LE	Healed keratitis	Nuclear cataract	4/60	6/18	–
10	62	M	RE	Healed keratitis	Cortical cataract	Counting fingers	6/24	–
11	70	F	RE	Post trichomatous central scarring	Cataracta brunescence	Counting fingers	6/36	Capsulorhexis completed, converted to ECCE + IOL due to intraoperative haze

BCVA = best corrected visual acuity, ECCE + IOL = extracapsular cataract extraction with intraocular lens implantation.

the side port was done and the wound was left unsutured. Subconjunctival gentamicin (Gentamicin, Centaur) 20 mg and dexamethasone (Dexona, Zyclus Cadilla) 1 mg was injected. Postoperatively, patients received betamethasone sodium phosphate eye drops (Betnesol, Glaxo) 0.1% in 2 hourly dosage and ciprofloxacin eye drops (Cifran, Ranbaxy) 0.3% four times a day. Cycloplegics (Tmide, Sante Vision) were given to all patients and timolol maleate 0.5% eye drops (Iotim, FDC) were given, wherever required.

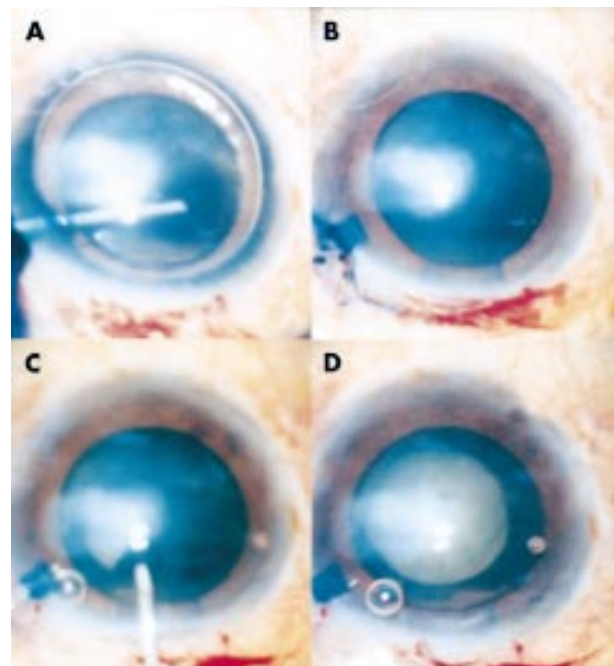
### Main outcome measures

The parameters assessed during the surgery included the completion of capsulorhexis, phacoemulsification, and foldable intraocular lens implantation and the presence of complications, if any. Furthermore, any increase in the intensity of the corneal haze intraoperatively was also noted. Patients were followed up postoperatively on day 1, week 1, month 1, and month 3. Postoperative assessment included the record of the corneal clarity, position of the intraocular lens, and best corrected visual acuity and complications, if any.

### RESULTS

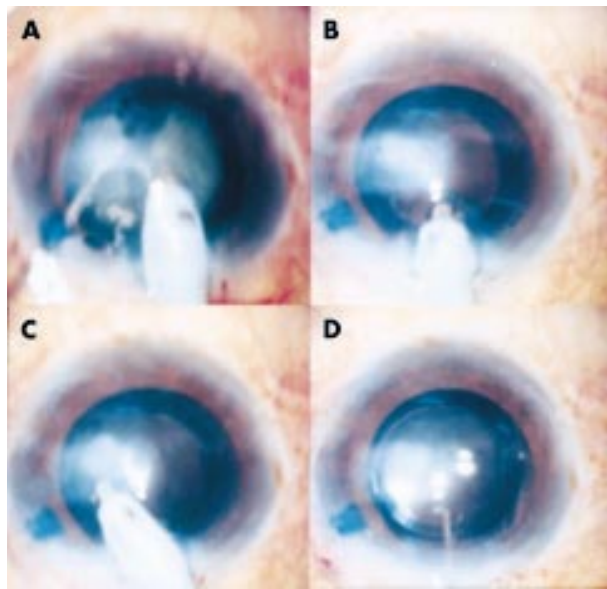
The mean age of the patients was 60.18 (SD 12.52) years (range 35–78 years). There were six males and five females. Most patients had corneal opacity due to healed keratitis (Table 1). Two eyes had undergone previous corneal surgery in the form of a lamellar graft or a tectonic patch graft and one patient had features of both trichomatous keratopathy and Fuchs' dystrophy. Nuclear and cortical cataracts were encountered most often in the study (Table 1). All but one eye had a preoperative visual acuity of  $\leq 6/60$ .

The main incision and the side port were stained in all eyes. The anterior capsule was stained in all eyes sufficiently so that the capsulorhexis was successfully completed without any complication in all eyes (Fig 1). No extension of the capsulorhexis occurred in any of the cases. Hydroprocedures were done in all eyes after tenting the stained capsular margin. Phacoemulsification of the nucleus with stop and chop manoeuvre and aspiration of the cortical material was uneventful. The capsulorhexis margin was visualised throughout the procedure and the stained peripheral anterior capsular rim aided in the emulsification of the fragments with the chopper (Fig 2A). In two eyes the anterior cortical fibres were stained again with the dye. The stained feathery cortical fibres



**Figure 1** (A) Trypan blue injection under air bubble. (B) Anterior capsule stained with trypan blue. (C) Needle capsulorhexis being performed. (D) Capsulorhexis completed.

were visualised better in the presence of the corneal haze (Fig 2B, C). In one eye following completion of capsulorhexis, the phacoemulsification was not attempted because of increased corneal haze intraoperatively in the presence of hard cataract (case 11). In this case, relaxing incisions in the capsulorhexis margin were given and extracapsular cataract extraction with a PMMA intraocular lens implantation was done. Foldable lenses were implanted in the bag in all (Fig 2D) but this case. The visibility also deteriorated in case 3 as the surgery progressed. This eye had a combination of trichomatous keratopathy and Fuchs' dystrophy so that the corneal haze increased postoperatively, necessitating a penetrating keratoplasty 3 months later. The patient's best corrected visual acuity in this eye at the last follow up was 6/36.



**Figure 2** (A) Phaco chop nucleotomy. (B, C) Automated irrigation aspiration being done. Stained subincisional cortical material being aspirated. (D) Intraocular lens implantation.

On the postoperative day 1, there was no residual staining of the anterior capsule and all eyes showed a quiet anterior chamber with normal intraocular pressure. The best corrected visual acuity at the last follow up was  $\geq 6/24$  in eight eyes (Table 1). All but one patient had an ambulatory visual acuity of 6/60 or more postoperatively.

## DISCUSSION

A combined penetrating keratoplasty with cataract surgery is the method of choice for a patient with corneal opacity with cataract. Factors like graft rejection and infections may impede the chances of successful penetrating keratoplasty. This may be especially true in one eyed patients, elderly patients with poor dexterity, and those who are less likely to comply with the meticulous follow up following keratoplasty such as those patients from rural areas in developing countries like India.

Patients with nebulomacular corneal opacities and a visually debilitating cataract may become ambulatory with cataract surgery alone. Phacoemulsification is the preferred technique of cataract surgery at present<sup>6</sup> and it allows early visual rehabilitation. However, a successful phacoemulsification may be difficult in cases of corneal haze because of poor or suboptimal visualisation of the lenticular morphology caused by the presence of corneal opacification/haze. Vital steps such as capsulorhexis, nuclear emulsification, residual cortex removal, and foldable intraocular lens implantation are dependent upon the ability to visualise the capsular bag anatomy. Capsular staining has been used previously in various studies in mature white cataracts<sup>1,2</sup> and for learning the initial steps of phacoemulsification during training.<sup>7,8</sup> Its role as described here in enhancing the safety of phacoemulsification surgery in the presence of corneal opacities has not been evaluated elsewhere.

Trypan blue 0.1% facilitated the delineation of the lenticular morphology in all eyes. It helped in performing the rhexis and its visualisation during phacoemulsification in cases of

corneal opacities. In all cases, quick homogeneous staining of the anterior capsule was obtained, so that the blue stained capsular rim—that is, the unexcised, peripheral portion of the anterior capsule, could be clearly distinguished from the grey lenticular mass underlying the excised, central portion of the capsule. Additionally, the stained peripheral rim remained clearly visible during phacoemulsification, so that the proper positioning of the depth of the chopper tip was visualised and circular rhexis was maintained without any inadvertent ripping.

In two eyes, the dye was injected again so that the anterior cortical fibres were stained in a feathery and irregular pattern and, hence, were visualised better in the presence of corneal haze and aspirated subsequently. This finding has also been reported by Pandey *et al* in postmortem human eyes.<sup>8</sup> One case had posterior involvement of the cornea in the form of Fuchs' dystrophy for which a penetrating keratoplasty had to be performed. Postoperative visual acuity following penetrating keratoplasty was 6/36 in this case; hence, the use of trypan blue did not preclude a further full thickness graft or increase the risk of a subsequent graft failure. This may be of special relevance in developing countries like India, where patients have to wait for a keratoplasty because of a paucity of good quality donor material.

Although the visual outcome in these cases was less than optimal, all patients had enough vision to enable them to carry out their daily activities. Trypan blue assisted phacoemulsification in selected cases of corneal opacities with cataract is safe and feasible, both as a primary therapeutic option in cases where penetrating keratoplasty is not promising or possible, and as an interim procedure in cases of patients awaiting keratoplasty, conferring early visual rehabilitation.

## Authors' affiliations

**P Bhariya, N Sharma, M Ray, R Sinha, R B Vajpayee**, Dr Rajendra Prasad Centre for Ophthalmic Sciences, All India Institute of Medical Sciences, India

Correspondence to: Rasik B Vajpayee, MBBS, MS, R P Centre for Ophthalmic Sciences, All India Institute of Medical Sciences, New Delhi-110029, India; [rasikvajpayee@rediffmail.com](mailto:rasikvajpayee@rediffmail.com)

The authors have no proprietary interest in any of the products mentioned in this study.

Accepted for publication 26 March 2002

## REFERENCES

- 1 **Melles GRJ**, de Waard PWT, Pameyer JH, *et al*. Trypan blue capsular staining to visualize the capsulorhexis in cataract surgery. *J Cataract Refract Surg* 1999;**25**:7–9.
- 2 **Pandey SK**, Werner L, Escobar-Gomez M, *et al*. Dye-enhanced cataract surgery. Part 1: Anterior capsule staining for capsulorhexis in advanced/white cataract. *J Cataract Refract Surg* 2000;**26**:1052–9.
- 3 **Norn MS**. Preoperative trypan blue vital staining of corneal endothelium; eight years' follow up. *Acta Ophthalmol* 1980;**58**:550–5.
- 4 **Pels E**, Schuchand Y. Organ Culture and endothelial evaluation as a preservative method in corneas. In: Brightbill FS, ed. *Corneal surgery; theory, technique and tissue*. St Louis: CV Mosby, 1986;**93**:102.
- 5 **Kothari K**, Jain SS, Shah NJ. Anterior capsular staining with trypan blue in mature and hypermature cataract: a preliminary study. *Indian J Ophthalmol* 2001;**49**:177–80.
- 6 **Leaming DV**. Practice styles and preferences of ASCRS members—2000 survey. American Society and Refractive Surgery. *J Cataract Refract Surg* 2001;**27**:748–55.
- 7 **Werner L**, Pandey SK, Escobar-Gomez M, *et al*. Dye-enhanced cataract surgery. Part 2: Learning critical steps of phacoemulsification. *J Cataract Refract Surg* 2000;**26**:1060–5.
- 8 **Pandey SK**, Werner L, Escobar-Gomez M, *et al*. Dye-enhanced cataract surgery. Part 3: Posterior capsule staining to learn posterior continuous curvilinear capsulorhexis. *J Cataract Refract Surg* 2000;**26**:1066–71



## Trypan blue assisted phacoemulsification in corneal opacities

P Bhartiya, N Sharma, M Ray, et al.

*Br J Ophthalmol* 2002 86: 857-859

doi: 10.1136/bjo.86.8.857

---

Updated information and services can be found at:

<http://bjo.bmj.com/content/86/8/857.full.html>

---

### References

*These include:*

This article cites 6 articles

<http://bjo.bmj.com/content/86/8/857.full.html#ref-list-1>

Article cited in:

<http://bjo.bmj.com/content/86/8/857.full.html#related-urls>

### Email alerting service

Receive free email alerts when new articles cite this article. Sign up in the box at the top right corner of the online article.

---

### Topic Collections

Articles on similar topics can be found in the following collections

[Ophthalmologic surgical procedures](#) (971 articles)

[Lens and zonules](#) (642 articles)

[Cornea](#) (383 articles)

[Ocular surface](#) (455 articles)

---

### Notes

---

To request permissions go to:

<http://group.bmj.com/group/rights-licensing/permissions>

To order reprints go to:

<http://journals.bmj.com/cgi/reprintform>

To subscribe to BMJ go to:

<http://group.bmj.com/subscribe/>