

## SCIENTIFIC CORRESPONDENCE

# Ultrasound biomicroscopic study of sclerotomy sites after implantation of sustained release drug devices

S Kunimatsu, Y Fujino, Y Nagata, K Ono, M Mochizuki, J Numaga, H Kawashima, M Araie

*Br J Ophthalmol* 2002;**86**:869–871

**Background/aims:** To evaluate the potential of ultrasound biomicroscopy (UBM) as a tool to study the precise location and changes of sclerotomy sites of the eye with an intraocular drug delivery device.

**Methods:** Eight eyes of six patients (13 sites) who received ganciclovir implants were examined by UBM. Examinations were performed 1–26 months (mean 12.8 months) postoperatively. Serial transverse and radial sections of the anterior ciliary body around the sclerotomy sites were obtained.

**Results:** The ganciclovir implant contour was successfully viewed using an UBM with high reflectivity. Three implants were deviated anteriorly and they were very close to the ciliary body and the lens (anterior deviation), while four implants were deviated posteriorly and away from the lens (posterior deviation). The other six implants were located at the appropriate position as intended. A solitary homogeneous mass with a medium reflectivity around the suture tab was observed at 12 out of 13 sites in seven eyes. Thick membranes extending from sclerotomy sites to the ora serrata were found at two sites in two eyes.

**Conclusion:** UBM is helpful in detecting abnormal manifestations around ganciclovir implants and is a valuable tool to assess the changes of the sclerotomy sites of the sustained released intraocular devices.

Recently, several intraocular sustained drug delivery devices for ganciclovir,<sup>1–3</sup> corticosteroid,<sup>4,6</sup> and cyclosporin<sup>7</sup> have been developed to overcome poor penetration of externally (topically or systemically) administered drugs into the eye and to maintain therapeutic levels for a prolonged period of time without unintended adverse side effects. Representative devices include sustained release ganciclovir implants<sup>1–3</sup> for the treatment of cytomegalovirus retinitis, and a dexamethasone drug delivery system (Surodex, Oculex Pharmaceuticals, Inc, Sunnyvale, CA, USA)<sup>4,5</sup> that is reported to be effective in suppressing postoperative inflammation after cataract surgery. Previous clinical reports showed that these drug delivery devices seem to be a promising and effective therapy for treating severe uveitis, postoperative inflammation, and allergic reaction.<sup>1–7</sup> Indications for the intraocular drug delivery system may expand to many ocular diseases in the near future.

Since Surodex are inserted into the anterior chamber (6 o'clock angle), clinical observation of the device can be easily performed using a slit lamp biomicroscope or gonioscope.<sup>4,5</sup> On the other hand, intravitreal sustained release devices are difficult to monitor once they are inserted into the vitreous cavity. Therefore, an additional method of monitoring these devices *in vivo* may be useful in certain eyes.

Ultrasound biomicroscope (UBM), using a high frequency transducer, permits non-invasive examination of the anterior

segment anatomy at high resolution (40  $\mu\text{m}$ ).<sup>8–10</sup> This technique has made it possible to observe anatomical alterations of tumours in the anterior segment,<sup>11</sup> the ocular angle,<sup>12</sup> and glaucoma.<sup>13</sup> UBM can be used not only for the anterior chamber observation, but also for the observation of ciliary body cysts,<sup>14</sup> non-pigmented ciliary epithelial detachments,<sup>15</sup> and sclerotomy sites after pars plana vitrectomy.<sup>16</sup>

Although histopathological studies have been performed on the enucleated eyes treated with ganciclovir implants,<sup>17,18</sup> no *in vivo* studies are available to demonstrate the precise location and changes of the sclerotomy sites in eyes treated with sustained release ganciclovir implants. This study demonstrated for the first time the usefulness of UBM to examine and monitor the site of intraocular ganciclovir implants in patients with cytomegalovirus retinitis.

## MATERIALS AND METHODS

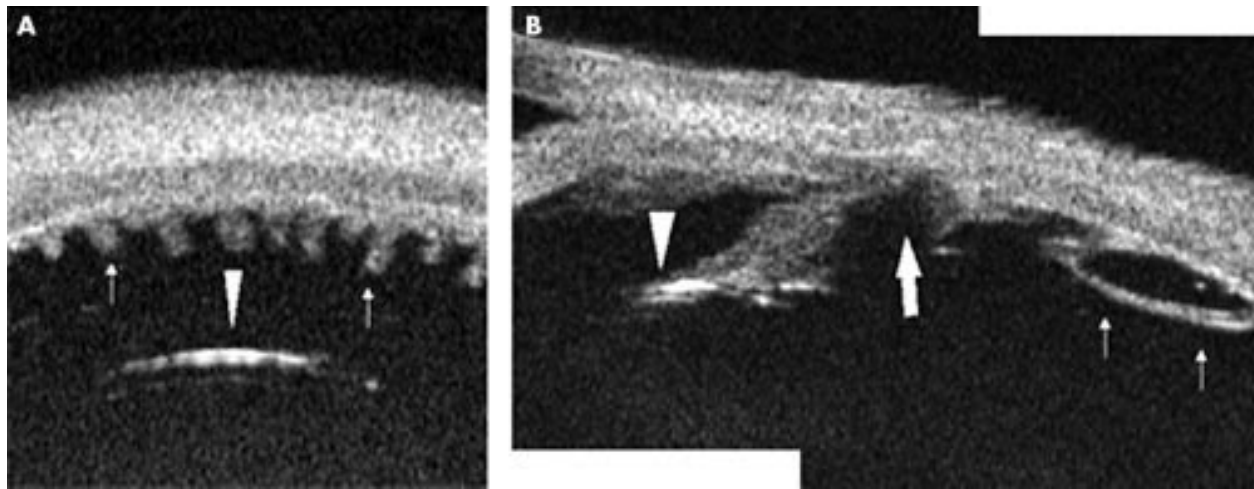
Sixteen sustained release ganciclovir implants (Vitrasert, Chiron Vision Co, Claremont, CA, USA) were installed in eight eyes of six patients (one implant in three eyes, two implants in two eyes, and three implants in three eyes). The first implant was placed in the inferotemporal quadrant; if the implant was inserted twice or more in the same eye, the second implant was placed in the inferonasal quadrant, and the third implant was placed after removing the first implant in the inferotemporal quadrant. Thirteen of these 16 implants (13 sites) were subjected to the current study.

We followed the surgical procedure described by Martin and associates.<sup>2</sup> Briefly, a conjunctival peritomy was constructed in the inferotemporal or inferonasal quadrant, then a 5–6 mm pars plana incision was created 4 mm from the limbus, and prolapsed vitreous was removed using an automated vitrectomy device. A ganciclovir implant was inserted into the vitreous cavity with special attention being paid not to touch the lens surface, and sewn into place with an 8-0 Nylon suture. The wound was closed with running 8-0 Nylon sutures.

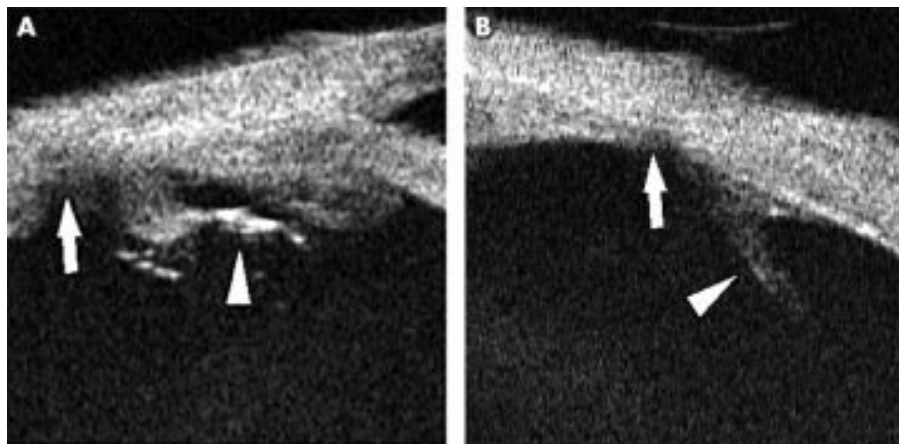
The sites were examined by UBM (model 840; Humphrey Research Division, San Leandro, CA, USA)<sup>8</sup> using a 50 MHz transducer. UBM examinations were performed 1–26 months (mean 12.8 months) postoperatively. After topical anaesthesia (oxybuprocaine hydrochloride 0.4%, Benoxil, Santen Pharmaceutical Co, Osaka, Japan), an eyecup containing hydroxyethyl cellulose (Scopisol, Senju Pharmaceutical Co, Osaka, Japan) and physiological saline was applied. Serial transverse and radial sections of the anterior ciliary body around the sclerotomy sites were obtained by UBM. One examiner (SK) performed all the examinations.

## RESULTS

The ganciclovir implant contour was successfully viewed using an UBM with high reflectivity. Typical UBM pattern of the implant is shown in Figure 1. A transverse section showed the anterior surface of the implant of high reflectivity away



**Figure 1** Ultrasound biomicroscopic images of ganciclovir implant placed in appropriate position. (A) A transverse section shows the anterior surface of the implant with a high reflectivity (arrowhead). Arrows indicate ciliary processes. (B) A radial section shows the anterior surface of the implant (arrowhead) found in the transverse section, solitary homogeneous mass with a medium reflectivity around the suture tab (arrow), and a thick membrane (small arrows) extending posteriorly from the sclerotomy sites.



**Figure 2** Anterior and posterior deviation of the implant. (A) Anterior deviation. The surface of the implant (arrowhead) with a high reflectivity was close to the ciliary processes. Solitary homogeneous mass with a medium reflectivity around the suture tag (arrow) is observed. (B) Posterior deviation. The surface of the implant cannot be visualised, and the suture tag with a linear low reflectivity (arrowhead) tilts over the pars plana. Solitary homogeneous mass with a medium reflectivity around the suture tag (arrow) is observed.

from ciliary processes. A radial section showed the anterior surface of the implant found in transverse section.

UBM examinations made it possible to identify the location of the implant in the vitreous and the deviation of the implant from the appropriate position. Of the 13 sites examined, three implants were deviated anteriorly and they were very close to the ciliary body and the lens (anterior deviation) (Fig 2A), while four implants were deviated posteriorly and away from the lens (posterior deviation) (Fig 2B). The other six implants were located at the appropriate position as intended. A solitary homogeneous mass with a medium reflectivity around the suture tab was observed at 12 out of 13 sites in seven eyes. Thick membranes extending from the sclerotomy sites to the ora serrata were found at two sites out of 13 sites in two eyes. A summary of the results is shown in Table 1.

## DISCUSSION

The present study clearly demonstrated that UBM made it possible to record the sustained release drug devices that were implanted in the vitreous cavity. UBM is a newly developed technique using a frequency ultrasound with a high resolution. Because of the high resolution, the exact position of the implant in the vitreous cavity and post-surgical changes of the vitreous near the device were clearly demonstrated.

Although all 13 implants were inserted into the centre of the vitreous cavity, three implants were deviated anteriorly and four implants were deviated posteriorly. A solitary homogeneous mass around the suture tag and thick membranes extending from the sclerotomy sites were also observed. These findings cannot be detected by slit lamp biomicroscopy.

The treatment of various ocular diseases is hindered by poor penetration of topically or systemically administered drugs into the eye. For example, in the case of corticosteroids, topical application is not effective in the treatment of intermediate or posterior uveitis because of poor permeability into the vitreous cavity. After systemic administration, there exist at least two major barriers that lie in the tight junctions of retinal pigmented epithelial cells and retinal capillaries. Furthermore, extended systemic use of corticosteroids could well induce numerous unwanted side effects. To overcome the disadvantages of these drug delivery routes, intraocular sustained drug delivery systems were sought.

Ocular complications such as vitreous haemorrhage and retinal detachment, have been reported after ganciclovir implantation.<sup>2, 3, 19</sup> These complications occur more often after exchange procedures when the implant is depleted of the drug.<sup>18</sup> The exact causes of the complications are not known, yet information about the precise locations of the implants,

**Table 1** Summary of clinical results

Case	R/L eye	Surgical site	Reimplant	Deviation	Homogeneous mass	Thick membranes
1	L	T	-	anterior	+	-
2	R	T	-	posterior	+	-
	L	N	-	-	+	-
3	R	T	-	anterior	+	-
	R	N	+	-	+	+
4	R	T	-	posterior	-	-
	R	T	-	-	+	-
5	R	T	+	posterior	+	-
	L	N	-	-	+	-
6	L	T	-	posterior	+	-
	L	N	-	-	+	-
	L	T	+	-	+	-
		N	-	anterior	+	+

T = temporal inferior, N = nasal inferior, + = positive, - = negative.

any abnormal manifestations around them, and the sclerotomy sites are essential to understand the cause.

Histologically, Charles and Steiner<sup>18</sup> found that the implant was supported by fibrous tissue that emerges from a surgical coloboma of the pars plana ciliaris in four eyes of three patients. Morley *et al*<sup>20</sup> also found a fibrous sheath encasing the strut and the suture during the ganciclovir exchange, which made extraction of the implant more difficult. Although no necropsy or histological study has been performed in the patients in the present study, the structural changes—that is, homogeneous masses and thick membranes demonstrated by UBM, are compatible with their findings.

The devices observed in the current study did not develop serious complications. We speculate that structural changes at the site of implantation may be related to vitreous haemorrhages or retinal detachments that have been described previously.<sup>2,3</sup> Furthermore, the homogeneous masses and thick membranes observed by UBM may be related to complications during and after the exchange operation. More data are needed to clarify the clinical implications of these findings by UBM.

The intraocular drug delivery system may become mainstream in delivering various drugs, such as corticosteroids, cyclosporin, and antibiotics that can yield better concentrations in the vitreous than conventional systemic or topical instillation.<sup>1</sup> A certain proportion of them will be replaced or removed during an extended period of time and surgical complications may occur during or after an exchange operation. On balance, we believe that UBM can become a useful tool for evaluating abnormal manifestations around intraocular drug delivery devices after implantation.

#### Authors' affiliations

**S Kunimatsu, K Ono, H Kawashima, M Araie**, Department of Ophthalmology, University of Tokyo, Graduate School of Medicine, Tokyo, Japan

**Y Fujino**, Department of Ophthalmology, Tokyo Kousei Nenkin Hospital, Tokyo, Japan

**Y Nagata**, AIDS Clinical Center, International Medical Center of Japan, Tokyo, Japan

**M Machizuki**, Department of Ophthalmology and Visual Science, Tokyo Medical and Dental University, Graduate School, Tokyo, Japan

**J Numaga**, Division of Ophthalmology, Tokyo Metropolitan Geriatric Center, Tokyo, Japan

Correspondence to: Shiho Kunimatsu, MD, Department of Ophthalmology, University of Tokyo, Graduate School of Medicine, 7-3-1 Hongo, Bunkyo-ku, Tokyo, 113-8655, Japan; QWR11150@nifty.ne.jp

Accepted for publication 1 April 2002

#### REFERENCES

- 1 Ashton P, Blandford DL, Pearson PA, *et al*. Review: implants. *J Ocul Pharmacol Ther* 1994;4:691-701.
- 2 Martin DF, Parks DJ, Mellow SD, *et al*. Treatment of cytomegalovirus retinitis with an intraocular sustained-release ganciclovir implant. A randomized controlled clinical trial. *Arch Ophthalmol* 1994;112:1531-9.
- 3 Marx JL, Kapusta MA, Patel SS, *et al*. Use of the ganciclovir implant in the treatment of recurrent cytomegalovirus retinitis. *Arch Ophthalmol* 1996;114:815-20.
- 4 Tan DTH, Chee SP, Lim L, *et al*. Randomized clinical trial of a new dexamethasone delivery system (Surodex) for treatment of post-cataract surgery inflammation. *Ophthalmology* 1999;106:223-31.
- 5 Chang DF, Garcia IH, Hunkeler JD, *et al*. Phase II results of an intraocular steroid delivery system for cataract surgery. *Ophthalmology* 1999;106:1172-7.
- 6 Jaffe GJ, Ben-nun J, Guo H, *et al*. Fluocinolone acetonide sustained drug delivery device to treat severe uveitis. *Ophthalmology* 2000;107:2024-33.
- 7 Jaffe GJ, Yang CS, Wang XC, *et al*. Intravitreal sustained-release cyclosporine in the treatment of experimental uveitis. *Ophthalmology* 1998;105:46-56.
- 8 Pavlin CJ, Sherar MD, Foster FS. Subsurface ultrasound biomicroscopic imaging of the intact eye. *Ophthalmology* 1990;97:244-50.
- 9 Pavlin CJ, Harasiewicz K, Sherar MD, *et al*. Clinical use of ultrasound biomicroscopy. *Ophthalmology* 1991;98:287-95.
- 10 Pavlin CJ, Foster FS. *Ultrasound biomicroscopy of the eye*. New York: Springer-Verlag, 1995.
- 11 Pavlin CJ, McWhae JA, McGowan HD, *et al*. Ultrasound biomicroscopy of anterior segment tumors. *Ophthalmology* 1992;99:1220-8.
- 12 Pavlin CJ, Ritch R, Foster FS. Ultrasound biomicroscopy in plateau iris syndrome. *Am J Ophthalmol* 1992;113:390-5.
- 13 Pavlin CJ, Harasiewicz K, Foster FS. Ultrasound biomicroscopy of anterior segment structures in normal and glaucomatous eyes. *Am J Ophthalmol* 1992;113:381-9.
- 14 Kunimatsu S, Araie M, Ohara K, *et al*. Ultrasound biomicroscopy of ciliary body cysts. *Am J Ophthalmol* 1999;127:48-55.
- 15 Tanaka S, Takeuchi S, Ideta H. Ultrasound biomicroscopy for detection of breaks and detachment of the ciliary epithelium. *Am J Ophthalmol* 1999;128:466-71.
- 16 Bhende M, Agraharam SG, Gopal L, *et al*. Ultrasound biomicroscopy of sclerotomy sites after pars plana vitrectomy for diabetic vitreous hemorrhage. *Ophthalmology* 2000;107:1729-36.
- 17 Anand R, Font RL, Fish RH, *et al*. Pathology of cytomegalovirus retinitis treated with sustained release intravitreal ganciclovir. *Ophthalmology* 1993;100:1032-9.
- 18 Charles NC, Steiner GC. Ganciclovir intraocular implant. A clinicopathologic study. *Ophthalmology* 1996;103:416-21.
- 19 Lim JJ, Wolitz RA, Dowling AH, *et al*. Visual and anatomic outcomes associated with posterior segment complications after ganciclovir implant procedures in patients with AIDS and cytomegalovirus retinitis. *Am J Ophthalmol* 1999;127:288-93.
- 20 Morley MG, Duker JS, Ashton P, *et al*. Replacing ganciclovir implants. *Ophthalmology* 1995;102:388-92.



## Ultrasound biomicroscopic study of sclerotomy sites after implantation of sustained release drug devices

S Kunimatsu, Y Fujino, Y Nagata, et al.

*Br J Ophthalmol* 2002 86: 869-871

doi: 10.1136/bjo.86.8.869

---

Updated information and services can be found at:

<http://bjo.bmj.com/content/86/8/869.full.html>

---

*These include:*

### References

This article cites 19 articles, 2 of which can be accessed free at:

<http://bjo.bmj.com/content/86/8/869.full.html#ref-list-1>

### Email alerting service

Receive free email alerts when new articles cite this article. Sign up in the box at the top right corner of the online article.

---

### Notes

---

To request permissions go to:

<http://group.bmj.com/group/rights-licensing/permissions>

To order reprints go to:

<http://journals.bmj.com/cgi/reprintform>

To subscribe to BMJ go to:

<http://group.bmj.com/subscribe/>