

PostScript

LETTERS

If you have a burning desire to respond to a paper published in the *BJO*, why not make use of our "rapid response" option? Log on to our website (www.bjophth.com), find the paper that interests you, and send your response via email by clicking on the "eLetters" option in the box at the top right hand corner.

Providing it isn't libellous or obscene, it will be posted within seven days. You can retrieve it by clicking on "read eLetters" on our homepage.

The editors will decide as before whether to also publish it in a future paper issue.

Conjunctival changes associated with yellow nail syndrome

The yellow nail syndrome (YNS) is a rare clinical entity characterised by slow growing yellow discoloured nails in association with peripheral lymphoedema, pulmonary manifestation (bronchiectasis, pleural effusions), and chronic sinusitis.¹ About 100 cases of YNS have been described in the literature but it has never been associated with ocular manifestations.² We report one patient with YNS in whom chronic chemosis and conjunctival degenerative lesion was observed.

Case report

A 61 year old man was referred with a 2 month history of ocular irritation in the left eye. His past medical history was significant for yellowish slow growing nails, chronic maxillary sinusitis, and bronchiectasis for 5 years diagnosed as YNS. On examination, nails of both hands and feet showed yellow discoloration and thickening (Fig 1). He also had oedema over the lower limbs and subacute bronchial infection for 2 months. On ocular examination, corrected visual acuity was 20/20 in both eyes. Slit lamp examination of the left eye revealed an area of conjunctival injection and thickening in the palpebral fissure adjacent to nasal limbus. A mild nasal chemosis and superficial corneal micropannus were also observed (Fig 2 top). Tear secretion was normal. Examination of the anterior

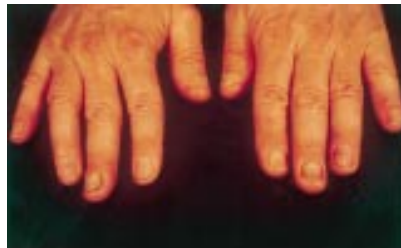

Figure 1 Yellow nail syndrome. Note yellow discoloration, increased curvature, and thickening of the nail plates in fingernails.

and posterior segment in both eyes was unremarkable. Treatment with topical corticosteroid (dexamethasone 0.1%, four times per day) and artificial tears was begun. Two weeks after presentation the patient reported an incomplete resolution of the irritation on the left eye and conjunctival lesion persisted. Computed tomographic scan of the brain and the orbits was normal. A conjunctival biopsy specimen showed multilayered epithelium, nuclear pleomorphism with malpighian differentiation. The underlying connective tissue was normal (Fig 2 bottom). Ocular symptoms improved rapidly and postoperative antibiotic and steroid eye drops were discontinued after 2 weeks. There was no recurrence of the conjunctival lesion but a mild chemosis persist in the left eye and appeared in the right eye.

Comment

YNS was first described by Samman and White in 1964.¹ The syndrome has been

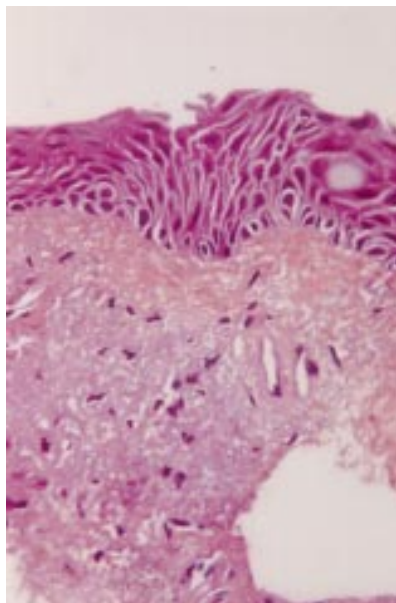
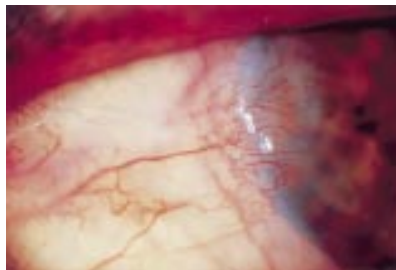

Figure 2 Anterior segment photograph of the left eye, showing conjunctival injection, conjunctiva thickening, and micropannus adjacent to nasal limbus. A mild nasal chemosis was also observed (top). Photomicrograph of conjunctival biopsy. The lesion shows multilayered epithelium, nuclear pleomorphism with malpighian differentiation. The underlying connective tissue was normal (haematoxylin-eosin-safran, magnification $\times 300$) (bottom).

defined as the complete triad of slow growing yellow nails, lymphoedema, and pleural effusions but today it is accepted that the presence of two of the three symptoms is sufficient to establish the diagnosis, even though the abnormalities may appear separately with intervals of several years.²

The aetiology of YNS is obscure, while pathogenesis seems to involve impaired lymphatic drainage.³ Ocular involvement has never been described in the YNS. However, conjunctival chemosis observed in our patient could be related to YNS which may involve the pleura, the lungs, but also other serosal or mucosal membranes such as the conjunctiva. Moreover, ocular symptoms and corneal micropannus appeared at the same time of a rise of pulmonary symptoms. An inflammatory component, which could alter blood flow and capillary permeability, has not been excluded and, interestingly, topical dexamethasone used to treat chemosis is efficient.

There is very little information on histopathological findings observed in the YNS. Nail biopsies demonstrated features of maturation disarray in the nail bed epithelium associated with dense, fibrous tissue replacing subungual stroma.⁴ The changes that we observed in the conjunctival epithelium are similar to that in the nail bed in YNS.

Since it appears that there is a pathogenic association between the YNS and ocular findings, this association is probably not coincidental and could be the first report of ocular manifestation of YNS.

T Bourcier, M Baudrimont, V Borderie, C Mayaud, L Laroche

Quinze-Vingts National Center of Ophthalmology and Department of Pneumology, Tenon Hospital, Paris, France

Correspondence to: Tristan Bourcier, MD, PhD, Service du Professeur Laroche, CHNO des Quinze-Vingts, 28 rue de Charenton 75012 Paris, France; bourcier@quinze-vingts.fr

Accepted for publication 28 January 2002

References

- 1 Samman PD, White WF. The "yellow nail syndrome." *Br J Dermatol* 1964;**76**:153-7.
- 2 Hershko A, Hirschberg B, Nahir M, et al. Yellow nail syndrome. *Postgrad Med J* 1997;**73**:466-8.
- 3 Bull RH, Fenton DA, Mortimer PS. Lymphatic function in the yellow nail syndrome. *Br J Dermatol* 1996;**134**:307-12.
- 4 DeCoste SD, Imber MJ, Baden HP. Yellow nail syndrome. *J Am Acad Dermatol* 1990;**22**:608-11.

Bilateral anterior uveitis as a presenting manifestation of sarcoidosis and syphilis

We report an unusual case of bilateral acute anterior uveitis in an asymptomatic patient in which ophthalmic examination and laboratory tests showed the diagnosis of syphilis and sarcoidosis.

Case report

A previously healthy 34 year old Hispanic woman with a 2 week history of blurred vision was referred for evaluation. The patient had no systemic complaints. On examination her best corrected visual acuity was 20/30 in

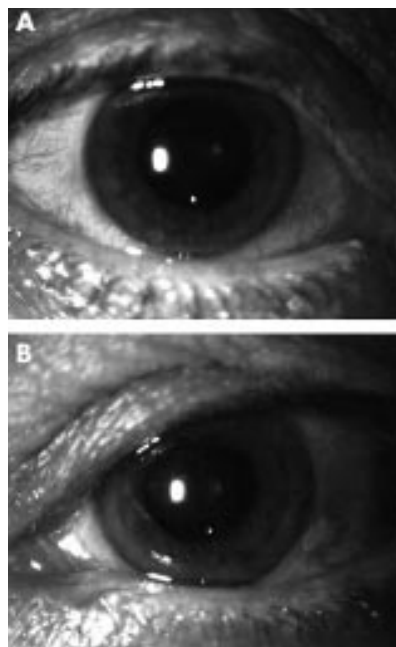


Figure 1 Acute anterior uveitis in (A) the right eye and (B) the left eye.

the right eye and 20/40 in the left. Slit lamp examination showed bilateral findings of moderate (2+) anterior chamber cells and non-granulomatous keratic precipitates (Fig 1). Fundus examination did not show any signs of vascular, retinal, or choroidal disease and a diagnosis of bilateral acute anterior uveitis was made. Treatment with topical prednisolone acetate and cyclopentolate drops resulted in mild improvement. Routine laboratory evaluation including complete blood count (CBC), blood chemistry, urinalysis, PPD, chest x ray, and syphilitic serology were performed. A markedly reactive serum FTA-ABS and low RPR titres (1:2) were obtained. Chest x ray showed bilateral hilar adenopathy and parenchymal infiltration (Fig 2A). HIV serological tests were negative. PPD test were also negative. Cerebrospinal fluid (CSF) examination was abnormal (mononuclear pleocytosis and increased protein concentration) with reactive VDRL. The patient was

treated with 12 million units of aqueous penicillin G intravenously daily for 14 days with resolution of the anterior segment inflammation. A chest computed tomograph (CT) confirmed the findings of the chest x ray (Fig 2B). A transbronchial lung biopsy showed non-caseating granulomas (Fig 2C), in which no micro-organisms could be found with Zhiel-Nielsen, PAS, Grocott's silver, or Wharthin-Starry stains and the diagnosis of sarcoidosis, stage 2 disease, was made. Pulmonary function tests were normal. No treatment was indicated for sarcoidosis because the patient was asymptomatic. The radiological lesions remained unchanged on the control performed after 6 months.

Comment

During the past decade, there has been a significant resurgence of syphilis, especially among black and Hispanic patients, and an increased number of patients with ocular syphilis has been reported.^{1,2} Syphilitic uveitis has no specific pattern of ocular involvement and, currently, it has been accepted that practically all patients with uveitis should be tested for syphilis. Sarcoidosis is another condition that can imitate any form of ocular inflammation.³ We are unaware of any previous reports of the association of sarcoidosis and syphilis in an asymptomatic patient with uveitis, and could find no reference to it in a computerised search using Medline.

The diagnosis of syphilitic uveitis requires a high index of suspicion and the patient's clinical picture should be taken into consideration.⁴ The polymerase chain reaction (PCR) assay has been used to detect *Treponema pallidum* in CSF and serum but has not been used in routine diagnosis.⁵ In this case, syphilis was presumed to be the cause of the ocular inflammation because there was an associated inflammatory pleocytosis in CSF and this structure is embryologically related to the aqueous humour and, additionally, there was a marked improvement in the anterior segment inflammation with the syphilitic treatment. Moreover, the association of both diseases in this patient could be coincidental; however, it might be possible that the energy induced by sarcoidosis could help the development of syphilis. We suggest a routine investigation in all cases of unexplained ocular inflammation including chest x ray and syphilitic serology to screen for sarcoidosis

and syphilis, owing to their great mimicry. Other laboratory tests should be performed following a tailored approach.

D Díaz-Valle, N Toledano

Cornea and Ocular Inflammation Unit, Department of Ophthalmology, Hospital General de Móstoles, Madrid, Spain

R Miguélez

Department of Rheumatology, Hospital General de Móstoles, Madrid, Spain

J M Benítez del Castillo

Cornea and Ocular Inflammation Unit, Department of Ophthalmology, Hospital Clínico San Carlos, Madrid, Spain

C Barros

Department of Internal Medicine, Hospital General de Móstoles, Madrid, Spain

Correspondence to: David Díaz-Valle, MD, PhD, Navahermosa 5, 2-A, 28230 Las Rozas, Madrid, Spain; ddiazval@nacom.es

Accepted for publication 5 February 2002

The authors acknowledge no financial or proprietary interest in the subjects of the paper.

References

- 1 Villanueva AV, Sahouri MJ, Ormerod LD, et al. Posterior uveitis in patients with positive serology for syphilis. *Clin Infect Dis* 2000;**30**:479–85.
- 2 Margo CE, Hamed LM. Ocular syphilis. *Surv Ophthalmol* 1992;**37**:203–20.
- 3 Nusseblatt RB, Whitcup SM, Palestine AG. Sarcoidosis. In: Nusseblatt RB, Whitcup SM, Palestine AG, eds. *Uveitis. Fundamentals and clinical practice*. St Louis: Mosby-Year Book, 1996:289–98.
- 4 Barile GR, Flynn TE. Syphilis exposure in patients with uveitis. *Ophthalmology* 1997;**104**:1605–9.
- 5 Burstain JM, Grimpel E, Lukehart SA, et al. Sensitive detection of *Treponema pallidum* by using the polymerase chain reaction. *J Clin Microbiol* 1991;**29**:62–9.

Tangent screens are still useful in the assessment of vigabatrin induced visual field defects

Vigabatrin induced constriction of peripheral visual fields was first reported in 1997.¹ The potential mechanisms of vigabatrin induced peripheral field constriction are many,² but in our opinion, not enough attention has been

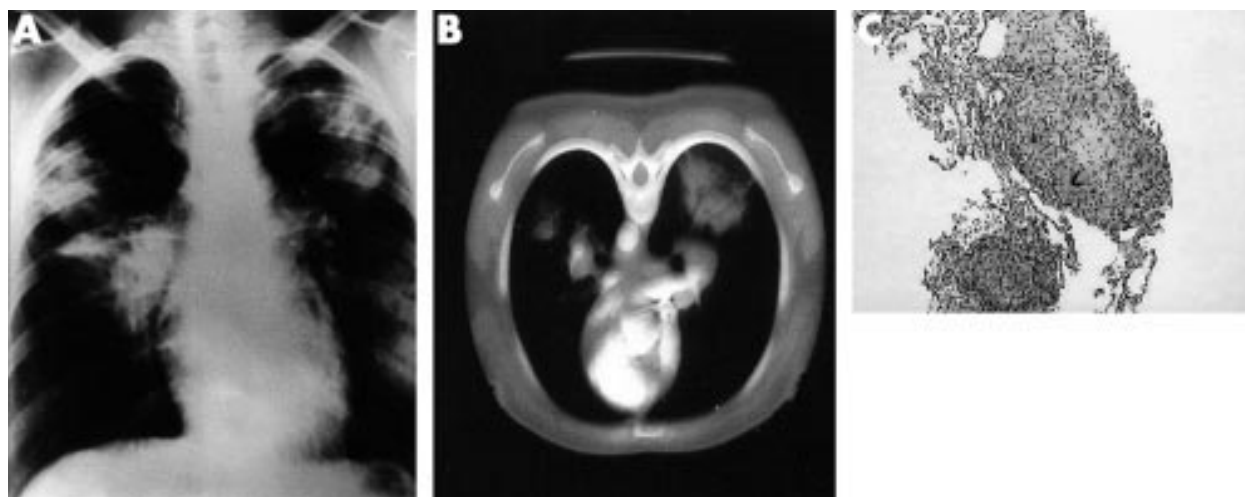


Figure 2 (A) Chest x ray, (B) chest CT. Bilateral hilar adenopathy and bilateral parenchymal infiltrates. (C) Histological section of the transbronchial lung biopsy showing non-caseating granuloma (haematoxylin and eosin, $\times 50$).

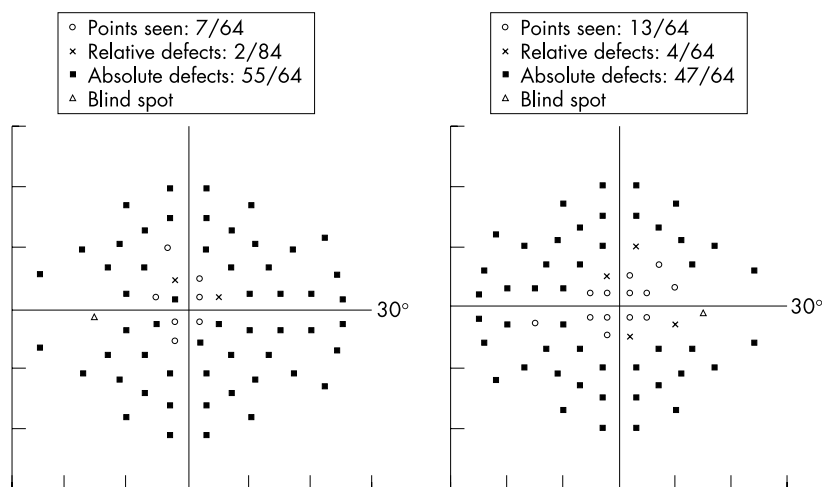


Figure 1 Automated perimetry of a patient taking vigabatrin. Left, 1990, right, 1998.

paid to the method and appropriateness of recording this constriction. Current recommendations for patients prescribed vigabatrin are that they are screened at regular intervals

by automated perimetry. Automated perimetry cannot, however, differentiate between pathological and functional (non-physiological) constriction of the visual field. Furthermore, automated perimetry, although deceptively simple for the operator to perform, is notoriously laborious and fatiguing for the patient. Although several safeguards are built into automated perimetry, in the form of reliability indices, there are traps for the unwary. This is clearly demonstrated in the recent case report where a 10 year old girl's visual field constriction apparently reversed on cessation of vigabatrin.³ Baseline visual fields, performed with automated perimetry, showed a classic artefact cloverleaf-shaped pattern⁴ that was not recognised by the authors. Automated threshold perimetry involves checking the visual threshold of the retina at set intervals. To reduce the number of presented stimuli starting points for threshold determinations are made at four quadrants 9 degrees from the horizontal and vertical meridians. Not infrequently, poorly cooperative patients are only attentive during this initial stage resulting in a cloverleaf-shaped field. In this situation the reliability indices are of little help as the suprathreshold false negative reliability indices are based on already fatigued thresholded locations.⁵

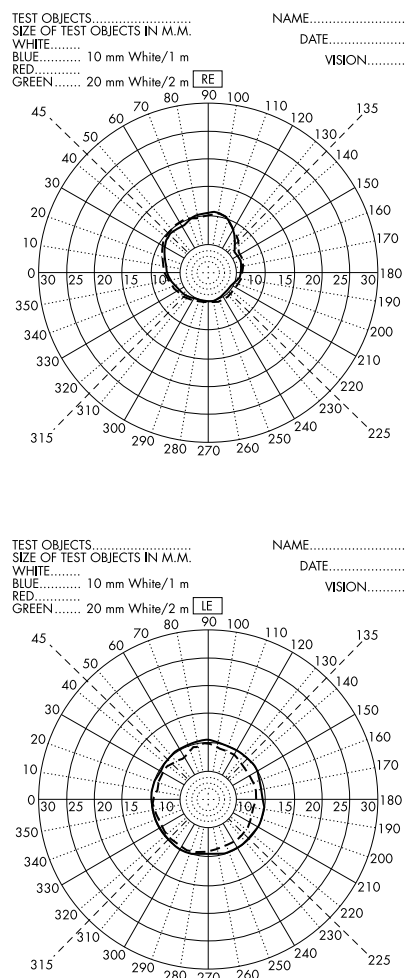


Figure 2 The corresponding tangent fields performed at 1 metre with a 1 mm (broken line) white object and 2 metres with a 2 mm object (solid line). The 2 mm isoptre lies within the 1 mm isoptre, which is a non-physiological finding. (Top) Right eye, (bottom) left eye.

Case report

A 30 year old woman was referred to the neuro-ophthalmology clinic in October 1998 for confirmation of vigabatrin induced constriction of visual fields. Her seizures had started at the age of 12 and consisted of sudden tonic posturing of the limbs preceded by left sided sensory symptoms. Initially she was having 12 seizures a week but by 1998 she was having 18 seizures a day. She was unable to tolerate phenytoin, valproate, carbamazepine, clobazam, lamotrigine, gabapentin, or topiramate and in 1990 had been started on vigabatrin. In 1998 she was referred for consideration of epilepsy surgery. At that time she complained of bumping into objects and she was noted on simple confrontation testing to have constricted visual fields. Automated perimetry was recommended and this was subsequently performed (Fig 1). Gross peripheral field constriction was noted but tangent screen examination at 1 and 2 metres revealed this to be non-physiological tubular visual field constriction (Fig 2).

Comment

The best way to ascertain whether visual constriction is pathological or not is to test the

patient at 1 and 2 metres using a wall mounted tangent screen.⁵ The visual field, whether constricted or not should be conical in shape and expand geometrically with increasing distances. Patients with functional visual field constriction can often be detected by the fact that on repeated testing of the visual field at an increased distance from the tangent screen they will not report this change in field diameter in an attempt to be consistent with their first field (tunnel visual field).⁵ This is not physiologically possible and is clear evidence of functional visual impairment.

Vigabatrin may well induce visual field constriction as a result of retinal toxicity but until studies are reported using tests of patients on vigabatrin at two viewing distances then this issue will remain open to debate.

JA Olson, AT Purdie, RJ Coleman

The Eye Clinic, Aberdeen Royal Infirmary, Forester Hill, Aberdeen

Correspondence to: Dr Olson; j.olson@arh.grampian.scot.nhs.uk

Accepted for publication 13 February 2002

References

- 1 Eke T, Talbot JF, Lawden MC. Severe persistent visual field constriction associated with vigabatrin. *BMJ* 1997;**314**:180-1.
- 2 Harding GFA. Severe persistent visual field constriction associated with vigabatrin-four possible explanations exists. *BMJ* 1997;**314**:1693.
- 3 Versino M, Veggioni P. Reversibility of vigabatrin-induced visual-field defect. *Lancet* 1999;**354**:486.
- 4 Walsh TJ, ed. *Visual fields: examination and interpretation*. 2nd ed. San Francisco: American Academy of Ophthalmology, 1996.
- 5 Glaser JS, ed. *Neuro-ophthalmology*. 2nd ed. Philadelphia: JB Lippincott, 1990.

Successful treatment of squamous cell carcinoma of the lower eyelid with intralesional cidofovir

Cidofovir (HPMPC), an acyclic nucleoside phosphonate analogue, is a promising drug that acts against a wide number of DNA viruses.¹ In 1997, the US Federal Food and Drug Administration approved cidofovir (for intravenous use only) for the treatment of cytomegalovirus retinitis in patients with AIDS.¹ Over the last few years, cidofovir in a 1-3% gel or cream vehicle has been found to be effective against unmanageable viral cutaneous lesions induced by herpes, pox, and papilloma families.² Recent studies have explored intralesional administration of cidofovir for the treatment of HPV related tumours, such as cervical epithelial neoplasia, oesophageal carcinomas, and HSV-8 induced Kaposi's sarcoma.³⁻⁶ We report a squamous cell carcinoma (SCC) of the eyelid which was successfully treated with intralesional cidofovir.

Case report

A 70 year old man presented with a nodular lesion 10 x 14 mm in size on his right lower eyelid, which had appeared 3 months earlier (Fig 1). The patient, who was otherwise in good general condition, reported a history of chronic, intense solar radiation exposure because he had lived in Somalia for many years. In the past 3 years he had been repeatedly treated with liquid nitrogen for multiple actinic keratosis of his forehead and upper eyelids. The clinical diagnosis of cutaneous

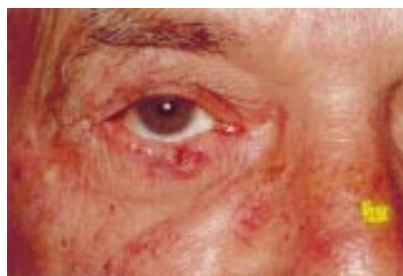

Figure 1 Cutaneous squamous cell carcinoma of the lower right eyelid.

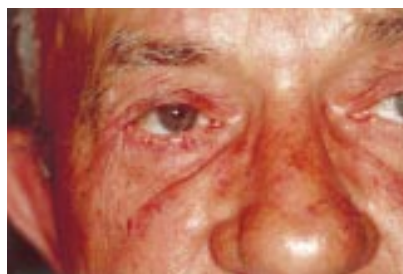

Figure 2 The same patient 24 months later.

SCC was confirmed by the histological examination of a punch biopsy. As the patient refused conventional surgery, after obtaining written consent the lesion was treated with a dose of cidofovir 0.1 ml (7.5 mg of active principle). The drug was injected both intralesionally and perilesionally with a fine needle (26 gauge). Care was taken to avoid intravascular inoculation. Erythema and ulceration were evident after 3 days, then the lesion became progressively smaller and flatter until it disappeared within the month. A skin punch biopsy was performed after 12 months on the previous lesional area, but revealed no presence of neoplastic cells. No systemic side effects were noted and the cosmetic result was excellent (Fig 2). The patient is free from recurrences after a 24 month follow up.

Comment

Surgical excision is the treatment of choice for SCC.⁷ Alternatively, liquid nitrogen, electrocautery, radiotherapy, or laser photocoagulation may be used. Decisions regarding treatment depend on the age of the patient, the location, extension, and severity of the neoplasm. For cases in which surgery or alternative cytoreductive techniques are not practical, local treatment with 5-fluorouracil, nitrogen mustard, bleomycin, mitomycin C, photodynamic therapy, or imiquimod may be considered as an alternative therapeutic option.⁷ Recent studies have showed that cidofovir exerts tumoricidal activity towards HPV related cervical intraepithelial neoplasia,³ oesophageal and respiratory papillomatous tumours,^{4,5} or HSV-8 related Kaposi's sarcoma.⁶ To our knowledge, the regression of SCC after the intraliesional injection of cidofovir has not previously been reported.

The mechanism of cidofovir as an anti-neoplastic agent is unknown. The involution of the neoplastic tissue could be due to the inhibition of rapidly proliferating cells through a decrease in DNA thymidine incorporation, the activation of tumour suppressor genes, the induction of apoptosis, and the inhibition of angiogenesis.⁸⁻¹⁰

Systemic administration of cidofovir is burdened with serious, dose related side effects.

Kidney toxicity is the most common but less frequently uveitis, macular oedema, neutropenia, thrombocytopenia, nausea, fever, hair loss, and muscle pain have also been observed.² When administered topically or intraliesionally cidofovir has not, to date, shown systemic toxicity.

Surgical excision remains the best possible treatment for SCC, as it is usually curative and permits the histopathological evaluation of margins. However, the successful outcome with intraliesional cidofovir in this case might be worth considering.

D Calista

Department of Dermatology, "M Bufalini" Hospital, Cesena, Italy

L Riccioni

Pathology Unit, "M Bufalini" Hospital

L Coccia

Private practice, ophthalmologist, Ascoli Piceno, Italy

Correspondence to: Donato Calista, MD, Department of Dermatology, "M Bufalini" Hospital, 47023 Cesena, Italy; calista@iol.it

Accepted for publication 15 February 2002

References

- 1 De Clercq E. Therapeutic potential of cidofovir for the treatment of DNA virus infection. *Verh K Acad Geneeskd Belg* 1996;**58**:19-49.
- 2 Zabawski EJ, Cockerell CJ. Topical and intraliesional cidofovir: a review of pharmacology and therapeutic effects. *J Am Acad Dermatol* 1998;**39**:741-5.
- 3 Snoeck R, Noel JC, Muller C, et al. Cidofovir, a new approach for the treatment of cervix intraepithelial neoplasia grade III (CIN III). *J Med Virol* 2000;**60**:205-9.
- 4 Van Cutsem E, Snoeck R, Van Ranst M, et al. Successful treatment of a squamous papilloma of the hypopharynx-oesophagus by local injections of [S]-1-(3-hydroxy-2-phosphonyl methoxypropyl) cytosine. *J Med Virol* 1995;**45**:230-5.
- 5 Pranky SM, Magit AE, Kearns DB, et al. Intraliesional cidofovir for recurrent respiratory papillomatosis in children. *Arch Otolaryngol Neck Surg* 1999;**125**:1143-8.
- 6 Fife K, Gill J, Bourbouli D, et al. Cidofovir for the treatment of Kaposi's sarcoma in an HIV negative homosexual man. *Br J Dermatol* 1999;**141**:1148-9.
- 7 Wennberg AM. Basal cell carcinoma: new aspects of diagnosis and treatment. *Acta Derm Venereol Suppl (Stockh)* 2000;**209**:5-25.
- 8 Andrei G, Snoeck R, Schols D, et al. Induction of apoptotic cell death following treatment of tumor cells with acyclic nucleoside phosphonate. 37th ICAAC, Toronto 28 September-1 October 1997. Poster 187-H.
- 9 DeClercq E, Andrei G, Balzarini J, et al. Antitumor potential of acyclic nucleoside phosphonates. *Nucleosides Nucleotides* 1999;**18**:759-71.
- 10 Liekens S, Andrei G, Vandeputte M, et al. Potent inhibition of hemangioma formation in rats by the acyclic nucleoside phosphonate analogue cidofovir. *Cancer Res* 1998;**58**:2562-7.

Multiple iridociliary cysts in patients with mucopolysaccharidoses

The mucopolysaccharidoses (MPSs) are rare hereditary diseases. They are classified into six types by the distinct lysosomal accumulations of glycosaminoglycans, which give rise to the progressive clinical features with involvement of multisystems. Ophthalmic complications, such as corneal stromal opacity, pigmentary

retinal degeneration, optic nerve atrophy, and glaucoma, are common in patients with MPSs.

Cysts in various organs have been reported in patients with MPSs—for example, multiple dentigerous cysts, multifocal large cysts in the white matter and arachnoid of the brain, and bone cysts.^{1,2} In the eye, membrane bound vacuoles in the non-pigmented epithelium of the ciliary processes have been observed by electron microscopy.³ However, iridociliary cysts have never been reported in patients with MPSs.

We present two cases of multiple iridociliary cysts in two patients with MPSs, one with Scheie syndrome and the other with Maroteaux-Lamy syndrome.

Case reports

Case 1

A 18 year old woman, who was diagnosed with Scheie syndrome (MPS type IS) by enzyme assay. The activity of α -L-iduronidase in peripheral blood lymphocytes was not detectable. She had bilateral corneal stromal opacities, shallow anterior chambers, and high intraocular pressures. On 6 April 1998 her corrected visual acuity was 20/50 in both eyes. Her right intraocular pressure was 24 mm Hg and the left was 20 mm Hg with topical medication. Ultrasound biomicroscopy revealed multiple round cystic lesions with uniformly low echogenic density similar to anterior chamber fluid in all quadrants of the posterior iris, iridociliary sulcus, and pars plicata of both eyes (Fig 1).

Case 2

A 23 year old woman, who was diagnosed with Maroteaux-Lamy syndrome (MPS type VI). The activity of arylsulphatase B in the peripheral blood lymphocytes was significantly low. At the age of 13 years, she underwent penetrating keratoplasty on her right eye because of corneal stromal opacity. At the age of 23 years, she underwent deep lamellar keratoplasty on her left eye. On 10 December 1997, slit lamp examination disclosed a clear graft and the shallow anterior chamber in both eyes. The corrected visual acuity in her right eye was 20/30 and left was 20/400. Her right intraocular pressure was 12 mm Hg and left was 18 mm Hg without medication.

Ultrasound biomicroscopy revealed multiple round low echogenic lesions in the posterior iris and ciliary body similar to case 1 in both eyes (Fig 2).

We examined an additional two patients with Scheie syndrome; however, no iridociliary cysts were found in either patient.

Comment

We have demonstrated the presence of multiple round cystic lesions. From this echographic finding, we interpret these lesions as multiple iridociliary cysts. In previous reports, there is a wide gap in the incidence of ciliary body cysts on the posterior ciliary body because of the difficulty in detecting them by conventional methods. Marigo *et al* retrospectively reported that cystic lesions were identified in 108 eyes of 88 out of 4632 patients by ultrasound biomicroscopy and the incidence of the multiple cysts occupying more than 180° was 13.3%.⁴ Kunimatsu *et al* studied the ciliary body in 232 eyes of 116 healthy people by ultrasound biomicroscopy. They reported that ciliary body cysts were detected in 54.3%, and all the cysts were located at the iridociliary sulcus or pars plicata.⁵ The cysts in our patients were located at the posterior iris as

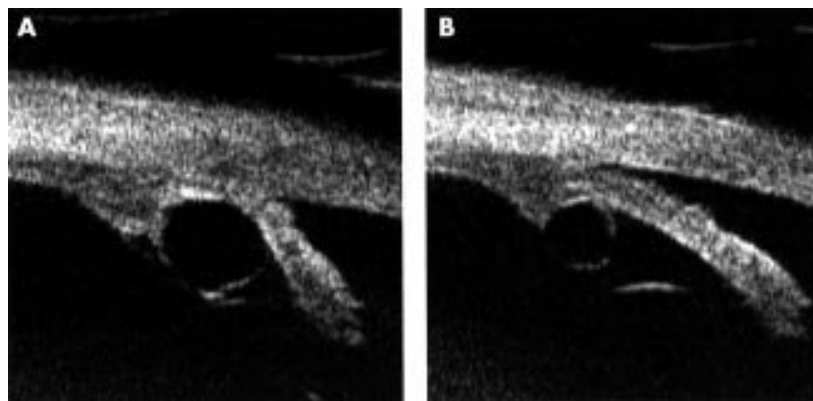


Figure 1 Cross sectional appearance of the iris by ultrasound biomicroscopy in case 1. Multiple iridociliary cysts are seen in the posterior iris of both eyes: (A) 1.2 mm diameter cyst in the right eye; (B) 0.8 mm diameter cyst in the left eye.

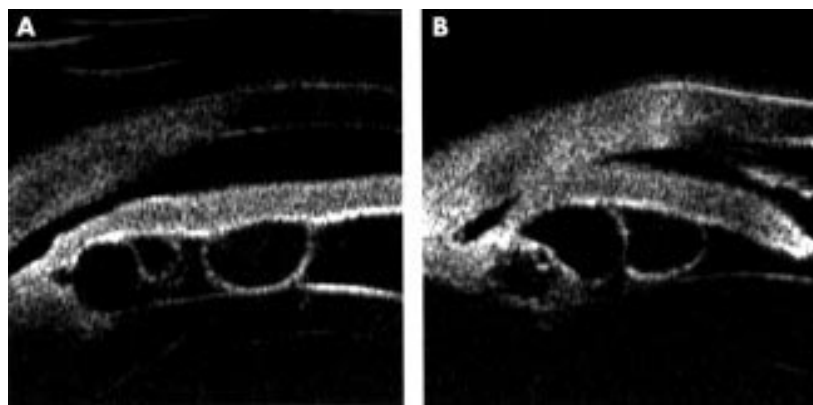


Figure 2 Cross sectional view of the iris by ultrasound biomicroscopy in case 2. Multiple iridociliary cysts are seen in the posterior iris of both eyes: (A) 0.8 mm, 0.4 mm, and 0.8 x 1.3 mm diameter cysts in the right eye; (B) 1.1 mm and 1.0 mm diameter cysts in the left eye.

well as in the iridociliary sulcus and pars plicata, and the number of cysts was much larger than that of healthy people in the previous reports.

Also, the reports concerning cysts in other organs in MPSs patients support the notion that iridociliary cysts in MPSs patients were different from usual cysts in normal patients. Because no evidence of the progression of the iris cysts was obtained, neither pathological examination nor the analysis of contents of cysts was performed in our cases.

All of our patients were diagnosed with glaucomas or ocular hypertension. It has been suggested that the high intraocular pressure was due to a blockage of the trabecular meshwork by the glycosaminoglycan, or a false high ocular pressure because of the higher rigidity of the cornea in the MPSs patients. On the other hand, angle closure that is caused by multiple iridociliary cysts in a patient without MPS has been reported.⁶ So we suggest that angle closure by the cysts may be another cause for the high intraocular pressure in some MPSs cases.

In summary, some of the patients with MPSs with shallow anterior chamber demonstrated the presence of multiple iridociliary cysts and ultrasound biomicroscopy is very useful tool for finding the cysts.

S Sato, N Maeda, H Watanabe, Y Tano
Department of Ophthalmology, Osaka University
Medical School, Japan

Y Inoue

Department of Ophthalmology, Tottori University
Faculty of Medicine, Japan

Y Shimomura

Department of Ophthalmology, Kinki University
Medical School, Japan

A Tanaka

Department of Pediatrics, Osaka City University
Graduate School of Medicine, Japan

Correspondence to: Shigeru Sato, MD, Department
of Ophthalmology, Osaka University Medical
School, Room E7, Yamadaoka 2-2, Suita, Osaka
565-0871, Japan; satoukun@silver.ocn.ne.jp

Accepted for publication 25 February 2002

References

- 1 **Roberts MW**, Barton NW, Constantopoulos G, *et al.* Occurrence of multiple dentigerous cysts in a patient with the Maroteaux-Lamy syndrome (mucopolysaccharidosis, type VI). *Oral Surg Oral Med Oral Pathol* 1984;**58**:169-75.
- 2 **Lamon JM**, Trojak JE, Abbott MA. Bone cysts in mucopolysaccharidosis IS (Scheie syndrome). *Johns Hopkins Med J* 1980;**146**:73-5.
- 3 **Topping TM**, Kenyon KR, Goldberg MF, *et al.* Ultrastructural ocular pathology of Hunter's syndrome. *Arch Ophthalmol* 1971;**86**:164-77.
- 4 **Marigo FA**, Esaki K. Differential diagnosis of anterior segment cysts by ultrasound biomicroscopy. *Ophthalmology* 1999;**106**:2131-5.

5 **Kunimatsu S**, Araie M. Ultrasound biomicroscopy of ciliary body cysts. *Am J Ophthalmol* 1999;**127**:48-55.

6 **Tanihara H**, Akita J, *et al.* Angle closure caused by multiple bilateral iridociliary cysts. *Acta Ophthalmol Scand* 1997;**75**:216-17.

A case of encephalocraniocutaneous lipomatosis

Encephalocraniocutaneous lipomatosis (ECCL) is a rare neurocutaneous syndrome characterised by cranial and facial asymmetry, cutaneous lesions, central nervous system abnormalities, and ocular abnormalities.

A case is described of a young man who presented with limbal dermoids, subcutaneous lipomas, and scalp alopecia. Further investigation revealed cranial and facial asymmetry, intracranial lipomas, and calcification and an arachnoid cyst, supporting a diagnosis of ECCL. This patient also had the additional ocular abnormality of bilateral optic disc colobomas, an association with ECCL not previously reported in the literature.

Case report

A 23 year old Asian man first presented to the eye clinic aged 16 with a left conjunctival lesion. On examination he had bilateral conjunctival dermolipomas, preauricular lipomas, and bilateral optic disc colobomas. Surgery was not advised at this time and no follow up was arranged, although photographs were taken (Fig 1). Aged 20, he presented to the eye clinic again. Before excision biopsy of the left conjunctival dermolipoma, a computed tomograph (CT) scan of the head was requested to delineate the posterior extent of the lesion. This revealed some asymmetry of the skull vault, intracranial calcification within the right cerebellar hemisphere, and a possible cystic lesion in the left parietal area (Fig 2 (left)). Subsequent examination by a neurologist was entirely normal with no stigmata of the phacomatoses. Histology of the conjunctival lesion confirmed a complex corneoscleral choristoma comprising collagenous tissue with fat and a focus of cartilage.

Three years later the patient was seen by a dermatologist complaining of a lesion on his left eyebrow, which was clinically a lipoma. Skull and facial x rays revealed asymmetry of the skull vault and facial bones including the zygomatic arches. Further investigation in the form of an magnetic resonance imaging (MRI) scan of the brain showed lipomas within the subcutaneous fat of the scalp and also intracranial lipomas. In addition, there was an arachnoid cyst anterior and inferior to the left temporal lobe (Fig 2 (right)). There was no connection between the soft tissue tumour on the left eyebrow and the intracranial cavity. Subsequent histology of the excised lesion revealed a lipoma.

Review of the patient's childhood medical records revealed that since birth he had had large patches of scalp alopecia and aged 7 he was noted to have a large suprapubic fat pad. A final diagnosis of ECCL was made based on the findings of limbal dermoids, subcutaneous lipomas, scalp alopecia, cranial and facial asymmetry, intracranial lipomas and calcification, and an arachnoid cyst.

Comment

ECCL is a rare neurocutaneous syndrome of unknown aetiology, first described by Haberland and Perou in 1970.¹ All cases described in the literature have been sporadic and there does not appear to be any geographic, racial,

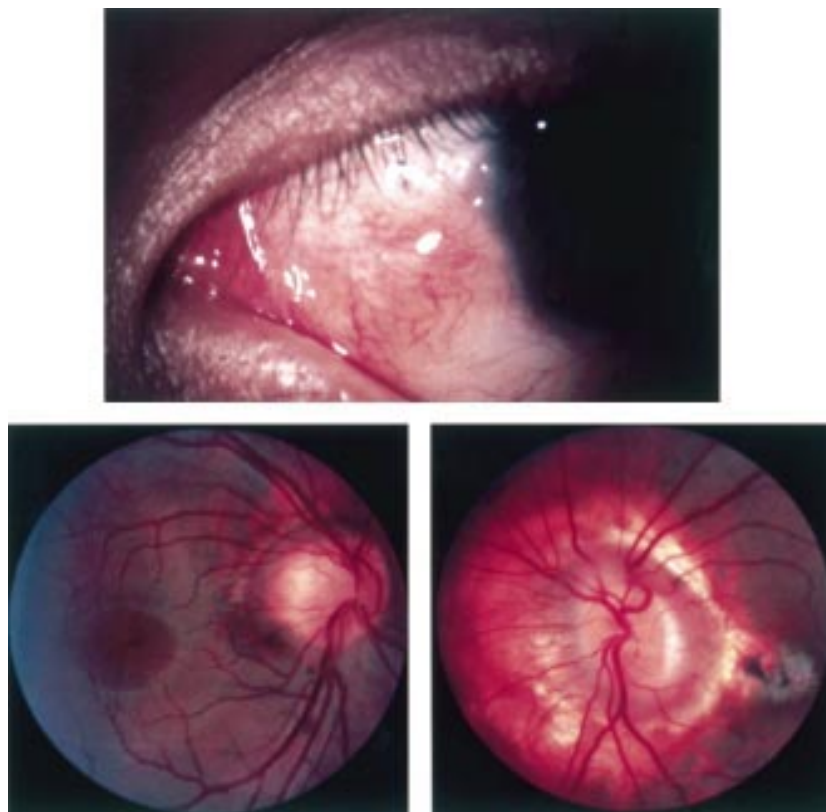


Figure 1 (Top) Photograph of left conjunctival dermolipoma. (Bottom) Photographs of right and left optic disc colobomas.

or sex predilection. The syndrome is characterised by cranial and facial asymmetry, cutaneous lesions, central nervous system abnormalities, ocular abnormalities, and occasionally visceral lipomas. The abnormalities tend to be unilateral, although bilateral involvement has been described.^{2,4}

Cutaneous lesions consist mainly of subcutaneous scalp lipomas with overlying alopecia but lipomas involving the limbs and

paravertebral areas have also been reported.^{1,2} Papular skin lesions are also common and histologically have been found to be lipomas, fibrolipomas, and angiofibromas.³ Central nervous system abnormalities are numerous and include cerebral lipomas, cerebral calcifications, ventricular dilatation, cerebral atrophy, arachnoid cysts, seizures, spasticity, and mental retardation.⁵ The most common ocular lesions in ECCL are epibulbar choristomas

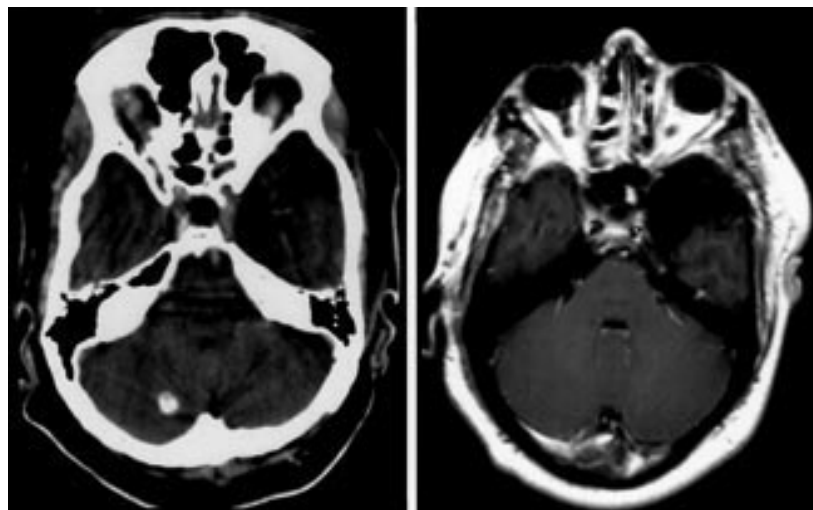


Figure 2 (Left) CT scan of the head showing asymmetry of the skull vault, intracranial calcification within the right cerebellar hemisphere, and a possible cystic lesion in the left parietal area. (Right) Magnetic resonance imaging (MRI) scan of the brain showing lipomas within the subcutaneous fat of the scalp, intracranial lipomas, and an arachnoid cyst anterior and inferior to the left temporal lobe.

and small skin nodules around the eyelids, which histologically represent connective tissue naevi.⁶ Other reported ocular abnormalities include a subcutaneous choristoma of the eyelid,¹ a small tag of tissue in the anterior chamber,⁷ a persistent posterior hyaloid system,⁷ a dysplastic iris,⁸ papilloedema,² and epicanthus inversus plus hypertelorism.⁴

The patient in this case report demonstrates the main features of ECCL; cranial and facial asymmetry, subcutaneous lipomas and scalp alopecia, intracranial calcification and lipomas, an arachnoid cyst, and limbal dermoids. There was also the additional finding of optic disc colobomas, an association with ECCL not previously reported in the literature. Other common findings in ECCL are seizures and mental retardation,⁵ but neither were apparent in this case and may explain the comparatively late presentation of this patient; most patients present in early childhood.^{1,3,4,8} The abnormalities in ECCL are usually unilateral but bilateral involvement does occur^{2,4} and was evident in this patient. Although epibulbar choristomas and limbal dermoids can occur sporadically in isolation or in a Mendelian inherited pattern^{9,10} there may be systemic associations such as Goldenhar's syndrome, the linear naevus sebaceous syndrome, or ECCL and the ophthalmologist should consider these diagnoses when a patient presents with an epibulbar choristoma or limbal dermoid.

**H B Chittenden, K E Harman,
F Robinson, E M Higgins**

Department of Ophthalmology, St Thomas's Hospital, Lambeth Palace Road, London SE1 7EH, UK

Correspondence to: Major H B Chittenden

Accepted for publication 11 February 2002

References

- Haberland C**, Perou M. Encephalocraniocutaneous lipomatosis. A new example of ectomesodermal dysgenesis. *Arch Neurol* 1970;**22**:144-55.
- Al-Mefty O**, Fox JL, Sakati N, *et al*. The multiple manifestations of the encephalocraniocutaneous lipomatosis syndrome. *Child's Nerv Syst* 1987;**3**:132-4.
- Sanchez NP**, Rhodes AR, Mandell F, *et al*. Encephalocraniocutaneous lipomatosis: a new neurocutaneous syndrome. *Br J Dermatol* 1981;**104**:89-96.
- Grimalt R**, Ermacora E, Mistura L, *et al*. Encephalocraniocutaneous lipomatosis: case report and review of the literature. *Paediatr Dermatol* 1993;**10**:164-8.
- Fishman MA**. Encephalocraniocutaneous lipomatosis. In: Gomez MR, ed. *Neurocutaneous diseases. A practical approach*. Boston: Butterworths, 1987;**39**:349-55.
- Kodsi SR**, Bloom KE, Egbert JE, *et al*. Ocular and systemic manifestations of encephalocraniocutaneous lipomatosis. *Am J Ophthalmol* 1994;**118**:77-82.
- Fishman MA**, Chang CSC, Miller JE. Encephalocraniocutaneous lipomatosis. *Paediatrics* 1978;**61**:580-2.
- Fishman MA**. Encephalocraniocutaneous lipomatosis. *J Child Neurol* 1987;**2**:186-93.
- Topilow HW**, Cykiert RC, Goldman K, *et al*. Bilateral corneal dermis-like choristomas. An X chromosome-linked disorder. *Arch Ophthalmol* 1981;**99**:1387-91.
- Mattos J**, Contreras F, O'Donnell FE. Ring dermoid syndrome. A new syndrome of autosomal dominantly inherited, bilateral, annular limbal dermoids with corneal and conjunctival extension. *Arch Ophthalmol* 1980;**98**:1059-61.

Bilateral non-specific orbital inflammation (orbital "pseudotumour"), posterior scleritis, and anterior uveitis associated with hypothyroidism in a child

Posterior scleritis and non-specific orbital inflammation (NSOI), also known as orbital "pseudotumour," are rarely seen in children.¹⁻³ Paediatric posterior scleritis and NSOI seldom have an underlying systemic association and, to our knowledge, hypothyroidism has not been reported as an association,¹⁻⁴ although thyroid abnormalities are recognised in adults.

We present a case of a child with bilateral anterior NSOI, posterior scleritis, and anterior uveitis who was also found to be hypothyroid.

Case report

A previously fit and well 13 year old girl presented with a 3 week history of bilateral red eyes and painless puffy left upper and lower lids for 1 week. She had had a headache for 10 days which had failed to respond to oral antibiotics. Systemic inquiry revealed a sore throat for 10 days but no other symptoms, in particular no thyroid related symptoms. Her visual acuity was 6/9 right, and 6/18 unaided, improving to 6/12 with pinhole in the left eye. She read all the Ishihara plates with the right eye, but missed three out of 17 plates with the left. No relative afferent pupillary defect (RAPD) was present. She had mild left periorbital swelling which was not erythematous or tender. There was no proptosis. She had full extraocular movements with no diplopia. The right eye had signs of mild anterior uveitis with 1+ of cells while the left eye had 2+ of cells in the anterior chamber. There was no evidence of posterior segment involvement, with normal vitreous and fundi.

She was commenced with 2 hourly dexamethasone eye drops to both eyes and on review 3 days later her vision improved to 6/6 in both eyes. A week later, she returned with pain and increasing periorbital swelling, left eye greater than right. Her visual acuity was reduced to 6/12 (right eye) and 6/60 improving to 6/18 with a pinhole (left eye). A mild left RAPD was present. Significant non-tender, mildly erythematous periorbital swelling was present in the left eye. She had 2 mm left relative proptosis, with generalised restriction of extraocular movements. There was mild bilateral anterior uveitis. The left disc was more swollen than the right and retinal striae were present in both eyes (Fig 1). There was no evidence of vitreous or chorioretinal inflammation. An orbital computed tomograph (CT)

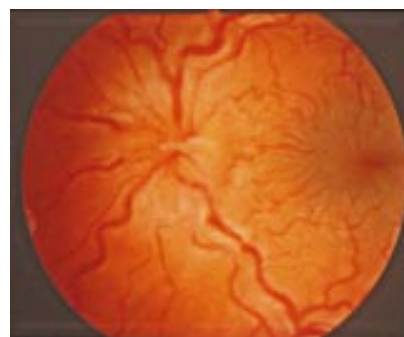


Figure 1 Fundus photograph of the left eye showing a swollen optic disc, tortuous retinal vessels, and multiple retinal striae.

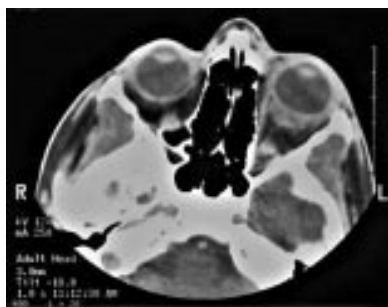


Figure 2 CT scan showing bilateral soft tissue thickening of the posterior coats of the globe and periocular tissues. This is predominantly intraocular and adjacent to the left globe. The extraocular muscles appear normal.

scan suggested a diagnosis of bilateral anterior NSOI without enlargement of the extraocular muscles (Fig 2). B-mode ultrasonography showed bilateral diffuse thickening of the posterior coats of the eyes (maximum left thickness of 4.4 mm) and fluid in Tenon's capsule consistent with scleritis.

Full blood count, urea, and electrolytes, liver function tests, serum angiotensin converting enzyme, serum calcium, autoantibodies (including ANA, ANCA, and rheumatoid factor), C reactive protein (CRP), and chest x ray were normal. She had negative serology for *Borrelia*, HTLV-1, and HTLV-2. Her erythrocyte sedimentation rate (ESR) was 32 mm in the first hour and a mildly raised Ig M was found. She was biochemically hypothyroid (raised TSH of 25.5 mU/l (0.4-4.0) and T4 of 10.6 pmol/l (9-20)) with positive anti-thyroid M antibodies. Thyrotrophin releasing hormone stimulation test confirmed primary hypothyroidism.

Treatment was commenced with prednisolone 50 mg which was reduced gradually over 3 months with resolution of her symptoms and signs. She had no relapse at 1 year follow up. She was also treated with thyroxine for her hypothyroidism.

Comment

The distinction between posterior scleritis and diffuse anterior NSOI is not always clear. As in this case, they commonly have evidence of inflammatory changes of the posterior coats of the eye and periocular tissues.^{2,4,5}

In a series of 29 paediatric NSOI cases, there was an association with peripheral blood eosinophilia, raised ESR, and positive ANA. Normal thyroid function tests (TFTs) were present in all of the nine children tested.⁴ Other reports of paediatric NSOI do not state whether TFTs were performed.^{6,7} Similarly, children with posterior scleritis tend not to have any clinical or laboratory evidence of associated systemic disease, but TFTs are not specifically mentioned.^{1,8} This is in contrast with our patient who was found to be biochemically hypothyroid. There is some evidence of thyroid autoimmunity in adult patients with NSOI, as shown by Atabay *et al* who found antibodies to eye muscle membrane antigens and thyroid microsomal antigen in patients with NSOI. Each of their cases was clinically and biochemically euthyroid.³

NSOI and scleritis in children may be associated with iritis, unlike the adult form of this disorder.^{6,9} Bloom *et al* report that children with NSOI and anterior uveitis tend to have a worse prognosis and increased recurrence.⁶ Our patient responded well to steroid treatment with no relapse at 1 year.

Scleritis with uveitis, although rare in children, should be recognised as part of the differential diagnosis of acute paediatric orbital inflammation. Hypothyroidism may be an incidental finding in our case, but the role of thyroid autoimmunity in children with NSOI and scleritis needs to be further investigated.

J M Uddin, C A Rennie, A T Moore

Department of Ophthalmology, Addenbrooke's Hospital, Cambridge, UK

Correspondence to: Jimmy Uddin, Department of Ophthalmology, Addenbrooke's Hospital, Hills Road, Cambridge CB2 2QQ, UK; jmuddin@aol.com

Accepted for publication 27 February 2002

References

- 1 Woon WH, Stanford MR, Graham EM. Severe idiopathic posterior scleritis in children. *Eye* 1995;**9**:570-4.
- 2 Benson WE. Posterior scleritis. *Surv Ophthalmol* 1988;**32**:297-316.
- 3 Atabay C, Tyutyunikov A, Scalise D, *et al*. Serum antibodies reactive with eye muscle membrane antigens are detected in patients with nonspecific orbital inflammation. *Ophthalmology* 1995;**102**:145-53.
- 4 Mottow-Lippa L, Jakobiec FA, Smith M. Idiopathic inflammatory orbital pseudotumor in childhood. II. Results of diagnostic tests and biopsies. *Ophthalmology* 1981;**88**:565-74.
- 5 Rootman J, Nugent R. The classification and management of acute orbital pseudotumors. *Ophthalmology* 1982;**89**:1040-8.
- 6 Bloom JN, Graviss ER, Byrne BJ. Orbital pseudotumor in the differential diagnosis of pediatric uveitis. *J Pediatr Ophthalmol Strabismus* 1992;**29**:59-63.
- 7 Hertle RW, Granet DB, Goyal AK, *et al*. Orbital pseudotumor in the differential diagnosis of pediatric uveitis. *J Pediatr Ophthalmol Strabismus* 1993;**30**:61.
- 8 Wald KJ, Spaide R, Patalano VJ, *et al*. Posterior scleritis in children. *Am J Ophthalmol* 1992;**113**:281-6.
- 9 McCluskey PJ, Watson PG, Lightman S, *et al*. Posterior scleritis: clinical features, systemic associations, and outcome in a large series of patients. *Ophthalmology* 1999;**106**:2380-6.

Unilateral enlargement of the blind spot: a diagnostic dilemma

Unilateral blind spot enlargement occurs as an isolated entity (acute idiopathic blind spot enlargement) or in association with other conditions such as multiple evanescent white dot syndrome, multifocal choroiditis with panuveitis, or punctate inner choroidopathy. It remains controversial whether blind spot enlargement in these conditions serves to unify them as a diagnostic group. The patient presented here had clinical features suggesting "diagnostic overlap" with some of these conditions, suggesting that diagnostic "lumping" of these diseases may have more logic than "splitting" them.

Case report

A 30 year old female patient presented to us in September 2000 with a blind spot close to the centre of vision in her left eye. She was uncertain as to how long it had been present, having noticed it only when the other eye was temporarily covered by chance. She was fit and well, with no recent viral illness or previous eye problems. Her acuity with myopic correction (-3.00 dioptre sphere right, -3.25 dioptre sphere left) was recorded at 6/6 right and left, and discrete foci of chorioretinal scarring were noted above and nasal to the optic disc in the left eye (Fig 1). There was no evidence of vitreous inflammatory activity in

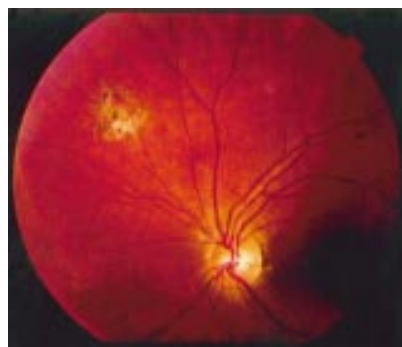

Figure 1 Fundus photograph, left eye. Chorioretinal scarring is present superonasally.

either eye. Humphrey C24-2 testing revealed an enlarged blind spot on the left (Fig 2), while on the right it was normal. Fluorescein angiography demonstrated window and masking defects consistent with chorioretinal scarring, and late leakage at the optic disc margin.

No treatment was given, and the blind spot has gradually decreased over 12 months.

Comment

Fletcher *et al*¹ were the first to describe a syndrome of acute idiopathic blind spot enlargement (AIBSE) without optic disc oedema in a series of seven patients. This phenomenon has since become well recognised both as an isolated finding, and in association with various forms of chorioretinitis including multiple evanescent white dot syndrome (MEWDS), multifocal choroiditis with panuveitis (MCP), acute macular neuroretinitis (AMN), diffuse subretinal fibrosis (DSF), and punctate inner choroidopathy (PIC). Together, these diagnoses span a wide spectrum of clinical disease expression, and it remains controversial whether blind spot enlargement serves to unify the group or whether other clinical features are sufficiently distinctive for them to be regarded as separate disorders. This patient is young, myopic and female, and presented with unilateral blind spot enlargement and chorioretinal scarring in the absence of acute symptoms such as photopsias. These features make it difficult to assign a specific diagnosis, as discussed below.

AIBSE and MEWDS share many common features. Both tend to present acutely with visual loss and photopsias in young myopic females, and follow a prodromal viral illness. They occasionally recur and can both be bilateral. The visual prognosis is good, with early disappearance of the white spots and later resolution of blind spot enlargement in most, though not all, cases. The principal distinguishing feature of MEWDS is the presence of white spots at the level of the outer retina or retinal pigment epithelium (RPE), and the variable presence of vitreous cells, retinal vascular sheathing, and optic disc swelling. Since the white spots can be fleeting and hard to see, it has led some to believe that AIBSE is really a subset of MEWDS patients first seen after resolution of the white spots. However, this has been strongly refuted by Hoyt and Imes,² who argued that, in contrast with MEWDS, the peripapillary visual loss in AIBSE is absolute in density and has steep edged margins. The presence of chorioretinal scarring in our patient would not be in keeping with either of these conditions.

In multifocal choroiditis with panuveitis (MCP), patients again present acutely with visual loss, scotomata, and/or photopsias.

SINGLE FIELD ANALYSIS

EYE: LEFT

NAME:	ID:	DOB: 26-06-1968
-------	-----	-----------------

CENTRAL 24-2 THRESHOLD TEST

FIXATION MONITOR: BLINDSPOT
 FIXATION TARGET: CENTRAL
 FIXATION LOSSES: 0/12
 FALSE POS ERRORS: 3%
 FALSE NEG ERRORS: 0%
 TEST DURATION: 04:13

STIMULUS: III, WHITE
 BACKGROUND: 31.5 ASB
 STRATEGY: SITA-FAST

PUPIL DIAMETER:
 VISUAL ACUITY:
 RX: DS DC X

DATE: 08-09-2000
 TIME: 3:10 PM
 AGE: 32

FOVEA: OFF

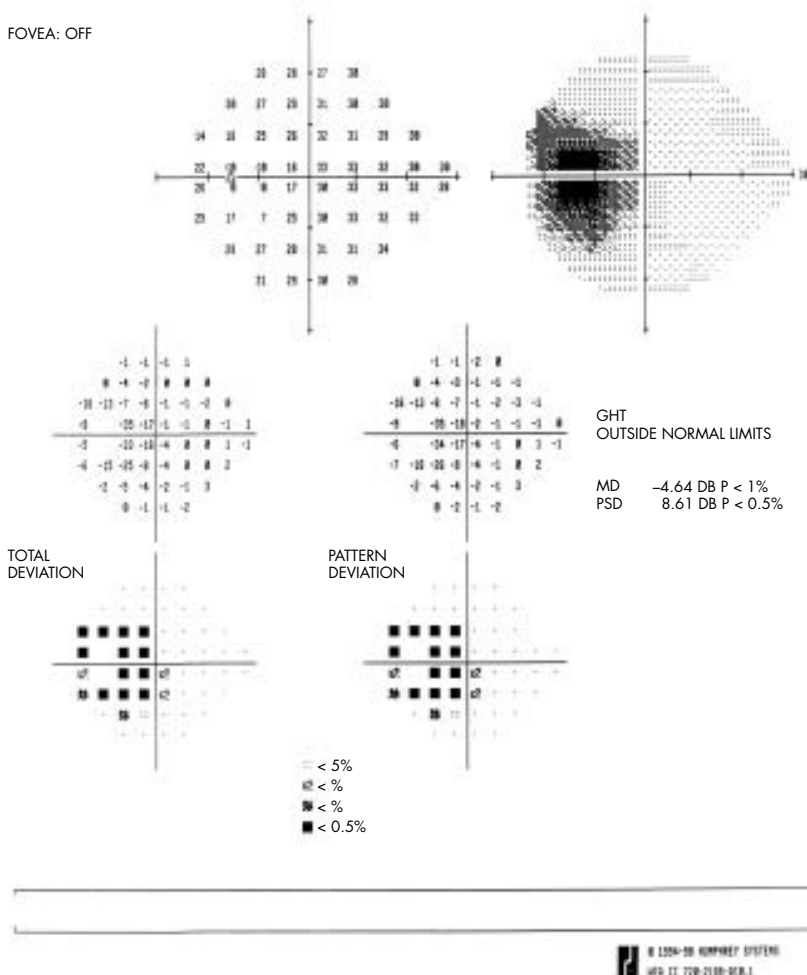


Figure 2 Humphrey C24-2 visual field test result, left eye. The enlarged blind spot is clearly seen.

Anterior and/or posterior uveitis is present and foci of chorioretinitis become apparent, most commonly in the peripapillary region. Inflammation leads to a variable degree of chorioretinal scarring, which can gradually enlarge and develop a subretinal component. Blind spot enlargement can occur, and does not always correlate with disc swelling or peripapillary chorioretinal scarring. MCP tends to be recurrent, with asymmetric bilaterality. Subfoveal choroidal neovascularisation (CNV) is the commonest cause of permanent vision loss, with resolution of blind spot enlargement occurring in most patients. Presumed ocular histoplasmosis syndrome (POHS) can cause similar chorioretinal scarring, but is not usually associated with uveitis or blind spot enlargement, and has no female preponderance. So called "pseudo POHS" has been linked with MEWDS, AMN, and AIBSE, though the absence of acute symptoms or vitreous inflammatory activity in our patient is at variance with most previous reports of patients with MCP or POHS.

Punctate inner choroidopathy (PIC) is similar to MCP in many ways, including the

presence of an enlarged blind spot in some cases. It is rarer than MCP and no cells or other signs of inflammation are seen in the vitreous or anterior chamber. Our patient would perhaps be closest to PIC in clinical findings, though again the lack of acute symptoms or bilaterality would be atypical.

AMN is less well associated with blind spot enlargement. It occurs predominantly in young adult females, and presents with rapid onset of dense paracentral scotomata. Reddish brown retinal lesions corresponding to the dense scotomata become evident, and are best seen with red free light. Uveitis is not present, and the scotomata diminish over months or years.

Diffuse subretinal fibrosis (DSF) is very rare and regarded by some as a variant of MCP. In addition to many of the clinical features of MCP already discussed, this condition is distinguished by widespread and progressive subretinal fibrosis not preceded by CNV.

The blind spot enlargement in AIBSE, MEWDS, MCP, PIC, AMN, and DSF, coupled with their tendency to present in young adult females, has led to a proposal that they be

grouped under the term "acute zonal occult outer retinopathy" (AZOOR).³ Added to the clinical similarities already described, Jacobsen *et al*⁴ demonstrated electroretinographic (ERG) abnormalities in a group of 24 AZOOR patients, though in some cases there were only subtle intereye differences detected. It was concluded that ERG findings help to unify this diagnostic group, as well as indicating that the primary pathophysiology lies at the level of the photoreceptor outer segment. This view was not supported by Jampol and Wiredu, who argued that the above entities were sufficiently distinctive to warrant "splitting" rather than "lumping."⁵

Our patient does not fit neatly into any of the diagnoses discussed above, and the principal clinical features of blind spot enlargement with chorioretinal scarring in the absence of acute symptoms or evidence of vitritis suggest that there is a degree of diagnostic overlap in her case. To the extent that a single case report can inform this debate, it does indicate that some patients do not fit neatly into diagnostic groups, strengthening the case for those who would "lump" these diagnoses rather than "split" them. Perhaps there are other cases which remain unreported because of this diagnostic uncertainty.

R H Gray

Taunton and Somerset Hospital, Musgrove Park,
Taunton TA1 5DA, UK

Accepted for publication 25 March 2002

References

- 1 Fletcher WA, Imes RK, Goodman D, *et al*. Acute idiopathic blind spot enlargement. A big blind spot syndrome without optic disc oedema. *Arch Ophthalmol* 1988;**106**:44-9.
- 2 Hoyt WF, Imes RK. Multiple evanescent white dot syndrome, reply to letter. *Arch Ophthalmol* 1988;**106**:1163.
- 3 Gass JDM. Acute zonal occult outer retinopathy. *J Clin Neuro-Ophthalmol* 1993;**13**:79-97.
- 4 Jacobson SG, Morales DS, Sun XK, *et al*. Pattern of retinal dysfunction in acute zonal occult outer retinopathy. *Ophthalmology* 1995;**102**:1187-98.
- 5 Jampol LM, Wiredu BS. MEWDS, MFC, PIC, AMN, AIBSE, and AZOOR: one disease or many. *Retina* 1995;**15**:373-8.

Acquired ocular toxoplasmosis in pregnancy

We describe the management of a case of acquired ocular toxoplasmosis that occurred in the first trimester of pregnancy.

Case report

A 27 year old apparently healthy Pakistani woman, at 9 weeks' gestation, presented to the Birmingham and Midland Eye Centre

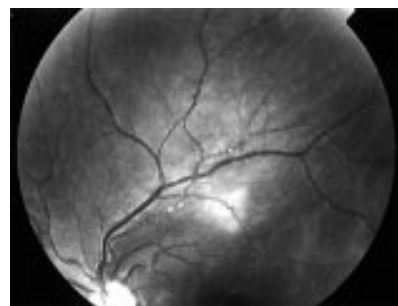

Figure 1 Left fundus showing active retinochoroiditis with retinal vasculitis.

Table 1 Serum dye test titres, IgM levels, and IgG avidity levels

Time (days) after onset of symptoms	Dye test titre	Dye test (IU/ml)	ELISA IgM	IgG avidity (%)
10	1/4096	2000	Positive	20
20	1/2048	1000	Positive	19
103	1/2048	1000	Positive	-

with a 1 week history of blurred vision in the left eye. She had no past ocular problems. Her first uncomplicated pregnancy was 2 years previously. On examination, the best corrected visual acuities were 6/6 in each eye. The anterior segments were normal and the intraocular pressures were 16 mm Hg right eye, 14 mm Hg left eye. Funduscopy showed a diffuse, elevated white lesion in the left retina half a disc diameter in size located one disc diameter superior to the fovea (Fig 1). There was an area of associated perivascular sheathing and minimal vitreous activity. An active left retinochoroiditis with associated retinal vasculitis was diagnosed. The right fundus was normal.

Serological testing revealed antibodies to *Toxoplasma gondii* at a titre of 1/4096 (2000 IU/ml) using the dye test and a toxoplasma IgM enzyme linked immunosorbent assay (ELISA) on the patient's peripheral blood was positive. Subsequent serological tests at the PHLs Toxoplasma Reference Unit, Swansea, confirmed these results and IgG avidity testing demonstrated that the infection was acute (Table 1). The polymerase chain reaction (PCR) on peripheral blood for *T gondii* was negative.

At 3 weeks after presentation (12 weeks' gestation), the patient's visual acuities were unchanged. There was now occlusion of a small retinal arteriole crossing the lesion. After consultation with the obstetrician the patient decided to proceed with the pregnancy. She was commenced on oral spiramycin 1 g three times daily.

Eight weeks after presentation (17 weeks' gestation) the vision remained the same and the focus of retinochoroiditis was beginning to scar. The patient underwent an amniocentesis for PCR against *T gondii*. This was negative suggesting the fetus was unaffected. Spiramycin was continued until the end of pregnancy. Sequential fetal ultrasounds were normal.

At term the patient gave birth to a healthy baby girl. Polymerase chain reaction (PCR) and culture for *T gondii* were negative on placental tissue. Nevertheless, the dye test on cord blood was positive at 500 IU/ml. As toxoplasma IgM ELISA, IgM, and IgA ISAGA on cord blood were negative, the positive dye test was probably detecting passively transferred maternal IgG. The mother's vision remained normal, and only a small, pigmented scar was present (Fig 2).

Comment

In the United Kingdom ocular toxoplasmosis is normally thought to occur through the congenital route, although recent evidence suggests that we may be underestimating the amount of acquired disease.¹⁻⁶

Overall, about 40% of primary maternal infections lead to congenital infection of children,⁷ with a transplacental transmission rate of *T gondii* reported to be 3% in the first trimester, 22% in the second, and 63% in the third.⁸

In our case the features supporting an acquired aetiology included lack retinal scars

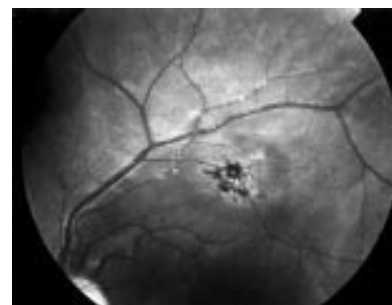


Figure 2 Left fundus showing healed area of previous retinochoroiditis.

from previous infection, and the positive IgM serology and IgG avidity results.⁹ Sera taken early in infection (<3 months) usually have avidity levels of less than 30%. Most sera taken later in infection (>6 months) have avidity levels of greater than 40%.

There are conflicting reports on the value of the PCR to detect toxoplasma DNA.¹⁰⁻¹² This may represent the different target DNA strands used in the studies. The negative PCR result on the mother's serum in our report is therefore not surprising. A negative PCR on amniotic fluid suggested that the fetus was not infected by toxoplasma, which was supported by the normal fetal ultrasounds.

Spiramycin is effective in reducing the risk of transmission to the fetus and therefore was given throughout pregnancy. This treatment may have contributed to the resultant good outcome for both mother and fetus.

Determining an aetiology of acquired *T gondii* infection was important in this patient as it allowed the most appropriate management plan to be initiated resulting in an excellent outcome. Acquired ocular toxoplasmosis occurring in pregnancy is rare and we hope this case report will raise the awareness of this unusual presentation.

M Ramchandani

Birmingham and Midland Eye Centre, City Hospital
NHS Trust, Dudley Road, Birmingham, UK

J B Weaver

Birmingham Women's Hospital, Metchley Park
Road, Birmingham, UK

D H M Joynson

Toxoplasma Reference Unit, Public Health
Laboratory, Singleton Hospital, Swansea, UK

P I Murray

Birmingham and Midland Eye Centre, City Hospital
NHS Trust, Dudley Road, Birmingham, UK

Correspondence to: Professor P I Murray, Academic
Unit of Ophthalmology, Birmingham and Midland
Eye Centre, City Hospital NHS Trust, Dudley Road,
Birmingham B18 7QU, UK;
P.I.Murray@bham.ac.uk

Accepted for publication 25 March 2002

References

- 1 Burnett AJ, Shortt SG, Isaac-Renron JL, et al. Multiple cases of acquired toxoplasmosis reinitis presenting in an outbreak. *Ophthalmology* 1998;**105**:1032–6.
- 2 Bowie WR, King AS, Werker DH, et al. Outbreak of toxoplasmosis associated with municipal drinking water. *Lancet* 1997;**350**:173–7.
- 3 Glasner PD, Silveira C, Kruszon-Moran D, et al. An unusually high prevalence of ocular toxoplasmosis in southern Brazil. *Am J Ophthalmol* 1992;**114**:136–44.
- 4 Holland GN. Perspective. Reconsidering the pathogenesis of ocular toxoplasmosis. *Am J Ophthalmol* 1999;**128**:502–5.
- 5 Gilbert RE, Dunn DT, Lightman S, et al. Incidence of symptomatic toxoplasma eye disease: aetiology and public health implications. *Epidemiol Infect* 1999;**123**:283–9.
- 6 Bosch-Driessen EH, Rothova A. Recurrent ocular disease in postnatally acquired toxoplasmosis. *Am J Ophthalmol* 1999;**128**:421–5.
- 7 Desmots G, Couvreur J. Congenital toxoplasmosis. *N Engl J Med* 1974;**290**:1110–6.
- 8 Wallon M, Dunn D, Slimani D, et al. Diagnosis of congenital toxoplasmosis at birth: what is the value of testing for IgM and IgA? *Eur J Pediatr* 1999;**158**:645–9.
- 9 Liesenfeld O, Montoya JG, Kinney S, et al. Effect of testing for IgG avidity in the diagnosis of *Toxoplasma gondii* infection in pregnant women: experience in a US reference laboratory. *J Infect Dis* 2001;**183**:1248–53.
- 10 Guy EC, Joynson DH. Potential of the polymerase chain reaction in the diagnosis of active *Toxoplasma* infection by detection of parasite in blood. *J Infect Dis* 1995;**172**:319–22.
- 11 Garweg J, Boehnke M, Koerner F. Restricted applicability of the polymerase chain reaction for the diagnosis of ocular toxoplasmosis. *Ger J Ophthalmol* 1996;**5**:104–8.
- 12 Bou G, Figueroa MS, Marti-Belda P, et al. Value of PCR for detection of toxoplasma gondii in aqueous humor and blood samples from immunocompetent patients with ocular toxoplasmosis. *J Clin Microbiol* 1999;**37**:3465–8.

Spontaneous reduction in myopic correction following varicella disciform stromal keratitis

We present the case of an 11 year old myopic girl who developed significant refractive changes due to corneal scarring following varicella disciform stromal keratitis in her right eye. This has markedly reduced the myopia in her right eye and resulted in significant anisometropia.

Case report

This 11 year old girl presented to her general practitioner with a red and painful right eye with reduced vision. She had had an uneventful episode of primary varicella zoster infection (chickenpox) 3 weeks earlier, from which she had made a full recovery. The

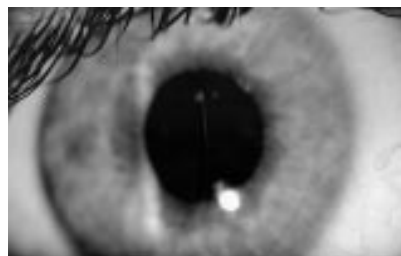

Figure 1 Anterior segment photograph of the right eye showing mild corneal scarring.

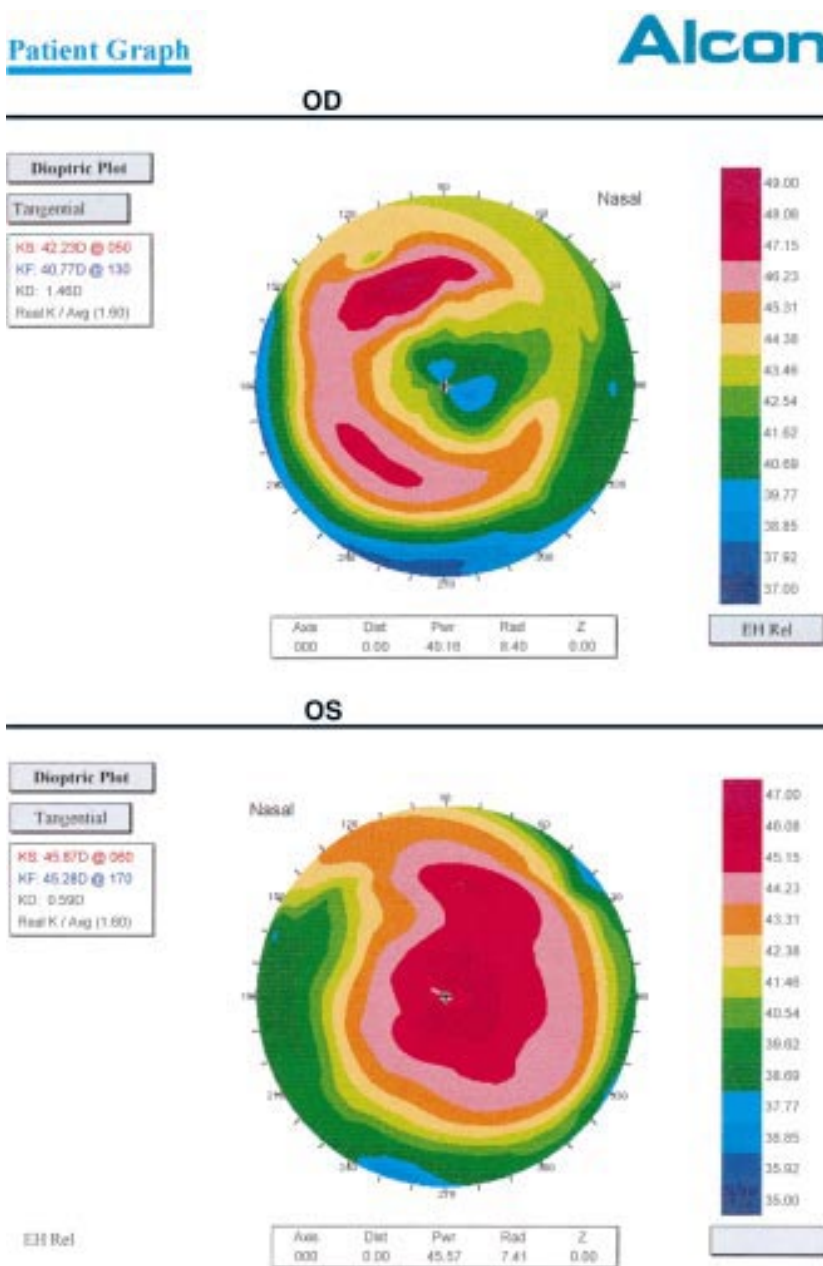


Figure 2 Corneal topography of the affected right eye (top) shows a flattening of the corneal surface secondary to disciform stromal corneal scar. Compare this with the unaffected myopic left eye, which has a steeper corneal surface (bottom).

general practitioner diagnosed her as having conjunctivitis and she was treated with topical chloramphenicol. One week later, the redness and pain had settled but her vision remained hazy. As a result she was referred to the eye department. Examination confirmed a reduction of visual acuity to 6/24 (Snellen) in the right eye and 6/6 in the left with spectacle correction. She was wearing a correction for myopia with a prescription of $-4.75/-0.75 \times 110^\circ$ in the right eye and $-6.00/-0.50 \times 90^\circ$ in the left eye. There was right superficial disciform stromal scar in the central cornea over the visual axis extending towards the periphery at 6 o'clock. Corneal sensation was intact and equal in both eyes. There was no active inflammation with white conjunctiva and quiet anterior chambers. The intraocular pressures were normal. Fundus examination revealed no abnormality. As there was no

active inflammation, she was not given any treatment. On review 2 months later, there was no change in her symptoms or in the clinical findings. One year later, she was seen again in the clinic and has a surprising Snellen visual acuity of 6/9–1 unaided, improving to 6/9+2 with $\infty/-1.75 \times 150^\circ$ in the right eye and 6/6 with -7.00 DS in the left. There was a reduction in opacity of the right corneal scar with stromal thinning (Fig 1). There was no ocular inflammation. Corneal topography showed a flattening of the right cornea surface, effectively reducing the degree of myopia in her right eye (Fig 2). This resulted in significant anisometropia and aniseikonia with full corrections to each eye. Despite this she was rather pleased and was coping well without glasses, relying on her "poorer" right eye for distant vision rather than wearing the full myopic correction in her left eye.

Comment

This is an unusual case of spontaneous myopia correction following corneal scarring secondary to varicella zoster disciform stromal keratitis. Primary varicella zoster infection (chickenpox) is a diffuse vesicular skin rash mainly affecting children and is usually self limiting. Common ocular findings are eyelid vesicles or marginal erosions and acute conjunctivitis.¹ Corneal changes are infrequent but can occur during the first week or two after the onset of chickenpox. Disciform stromal keratitis is an unusual but well recognised complication of primary varicella zoster infection.^{2,3} Varicella viral antigen and intracellular viral inclusions has been found in the corneal epithelium of affected eyes. Wilhemus *et al* reported five cases and reviewed the literature and found that this condition is typically unilateral, has a delayed onset, typically several weeks after the onset of skin rash.⁴ The complications following disciform stromal keratitis identified in this review are corneal scarring, neurotrophic keratopathy, iridocyclitis with secondary glaucoma, and iris stromal atrophy. The principal cause of loss of vision is corneal scarring. In our case, the corneal scarring had resulted in the flattening of the corneal surface thus reducing the degree of myopia significantly. This was highly unusual and had contributed to improving the unaided visual acuity in her affected eye. The effect on the cornea was similar to post LASIK (laser assisted in situ keratomileusis) and PRK (photorefractive keratectomy) in that the cornea appearance was similar as was the topography. In addition, the degree of cornea haze was limited and there had been a degree of stability for a period of over 1 year.

She was unable to tolerate the full refractive corrections because of the significant anisometropia and aniseikonia. Despite this she was pleased as she can see 6/9 unaided and would rather not wear her rather high myopic spectacle correction. In view of her young age, the uncertainty of the long term stability of her refractive state and her lack of visual complaint, contact lens and refractive surgery were not considered as appropriate treatment at present. However, they may have possible roles in her future management.

Topical corticosteroid therapy and antiviral agents have a role in the management of herpetic stromal disease following herpes simplex and herpes zoster infection.⁵ However, their roles in the treatment of stromal keratitis following primary varicella zoster are controversial and have not been determined.⁴ In our patient, the keratitis settled despite having neither topical corticosteroid nor antiviral agent.

Y F Choong, N R Hawksworth

Eye Department, Royal Glamorgan Hospital, Ynysmaerdy, Llantrisant, CF72 8XR, UK

Accepted for publication 29 October 2001

References

- 1 **Liesegang TJ.** The varicella-zoster virus: systemic and ocular features. *J Am Acad Dermatol* 1984;**11**(2 Pt 1):165-91.
- 2 **Uchida Y, Kaneko M, Hayashi K.** Varicella dendritic keratitis. *Am J Ophthalmol* 1980;**89**:259-62.
- 3 **Nesburn AB, Borit A, Pentelei-Molnar J, et al.** Varicella dendritic keratitis. *Invest Ophthalmol* 1974;**13**:764-70.
- 4 **Wilhelmus KR, Hamill MB, Jones DB.** Varicella disciform stromal keratitis. *Am J Ophthalmol* 1991;**111**:575-80.
- 5 **McGill J.** The enigma of herpes stromal disease. *Br J Ophthalmol* 1987;**71**:118-25.

Presumed ocular candidiasis in drug misusers after intravenous use of oral high dose buprenorphine (Subutex)

Heroin drug misusers are a high risk group for disseminated candidiasis.¹ Recently, an oral substitute for heroin with oral methadone or high dose sublingual buprenorphine tablets (Subutex) (HDSB) has proved to be effective in management of opioid addiction.² We report the first four cases of presumed candida endophthalmitis following intravenous injection of HDSB.

Case reports

Case 1

A 22 year old man, HIV negative, former heroin misuser, was seen complaining of blurry vision in his right eye. He used HDSB intravenously, after dissolution in saliva. One week following an injection, he presented with a febrile septicaemic syndrome associated with scalp nodules. Funduscopy revealed a moderate vitritis and a white tiny perifoveolar lesion with few white snowballs (Fig 1). The bacterial and fungal cultures from both blood and anterior chamber tap were negative. Treatment was begun with intravenous fluconazole associated with three intravitreal amphotericin B injections (IVT). After 15 days of therapy, he was discharged on oral fluconazole. Ten days later, the endophthalmitis relapsed with development of a second paramacular necrotising lesion. A posterior vitrectomy was performed. The vitreous cultures were negative for *Candida albicans*. He was treated again with intravenous amphotericin B, along with amphotericin B IVT with success.

Case 2

A 27 year old man, a former heroin misuser, was receiving HDSB substitution therapy.

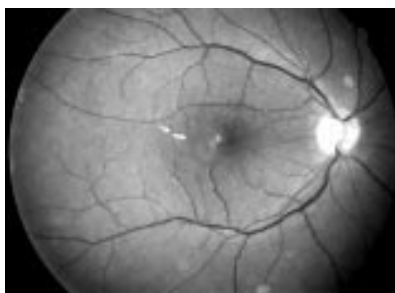


Figure 1 Case 1. Fundus photographs showing tiny white perifoveolar lesion with few white snowballs associated with a mild vitritis on his right eye.

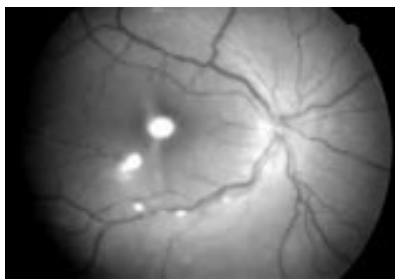

Figure 2 Case 2. Fundus photographs showing yellowish-white macular lesion, retinal vasculitis, and few white snowballs on his right eye.

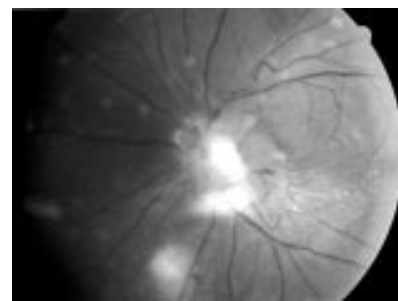


Figure 3 Case 3. Fundus photographs showing white lesion near the optic nerve and few white vitreous snowballs on his left eye.

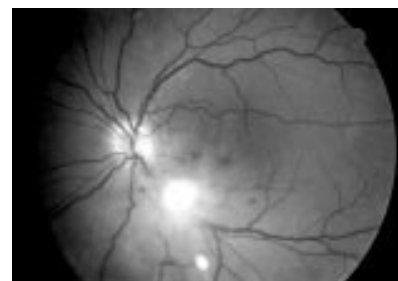


Figure 4 Case 4. Fundus photograph showing white chorioretinal lesion below the inferotemporal arcade associated with a marked vitritis.

Occasionally, he injected a preparation of HDSB diluted with preserved lemon juice. Two weeks following such an injection, he developed a skin abscess in which cultures revealed *C albicans*, posterior cervical lymphadenopathy, nodules of the scalp, and arthritis of the left wrist. Three weeks later he complained of decreased vision in his right eye. Funduscopy revealed a yellowish-white macular lesion and few white snowballs (Fig 2) Treatment was instituted with intravenous amphotericin B and flucytosine but the patient left the hospital against medical advice 4 days later.

Case 3

A 25 year old man, with history of heroin misuse, was referred for blurry vision and floaters in the right eye. His ocular symptoms started following an intravenous HDSB injection prepared with rotten lemon juice. Funduscopy revealed a parapapillary white lesion and few white vitreous snowballs (Fig 3) Improvement was obtained after 14 days of intravenous fluconazole and amphotericin B IVT.

Case 4

A 30 year old man, a former heroin misuser, was referred for decreased vision in the left eye. He had been using intravenous HDSB by dissolving the tablets in preserved lemon juice. Ten days earlier, he had a disseminated pustular rash with folliculitis over the chest, shoulders, and back. On funduscopy, there was a 2+ vitritis and a white chorioretinal lesion below the inferotemporal arcade (Fig 4). He improved after a treatment with intravenous amphotericin B rapidly switched to intravenous fluconazole combined with two amphotericin B IVT.

Comment

Endogenous candida endophthalmitis diagnosis is usually based on the combination of

clinical setting (febrile septicaemia following an intravenous injection, skin typical lesions) and typical fundus lesions.³ Isolation of the fungus from a vitrectomy specimen could provide a definitive diagnosis but this is not routinely performed or required.⁴ In our cases, the diagnosis of presumed candida endophthalmitis was based on (1) the characteristic clinical setting, (2) the typical ocular involvement that was characterised by creamy-white chorioretinal lesions with white balls and vitritis, and (3) the response to antifungal therapy. Vitrectomy was performed only in one case. It was not performed in three patients because they presented an isolated chorioretinitis or associated with a mild vitritis and a characteristic clinical presentation.^{5,6} Patients were treated with intravenous amphotericin B or intravenous fluconazole and intravitreal injections of amphotericin B, except in one patient who refused intraocular injections.

In the mid-1980s, in France, an outbreak of candidiasis followed the introduction on the drug market of a new brown heroin.⁷ The hypothesis that the lemon juice used to dissolve the heroin might have been contaminated with *C. albicans* was demonstrated.⁸ Our cases also seem to confirm that the fungi probably come from the lemon juice or the patient himself rather than from the buprenorphine itself. Since March 1995, substitution therapy with HDSB tablets (Subutex) is approved for licence in France. Unfortunately, 8% of the patients enrolled in substitution programmes continued to use the intravenous route.⁹ This drug is now widely prescribed in France. Recently, in Europe, this treatment obtained the authorisation for commercialisation in 13 European countries. Our report demonstrates the need to inform general practitioners, pharmacists, and patients of the risks involved with the intravenous use of substitute agents.

N Cassoux, B Bodaghi, P Lehoang

Department of Ophthalmology, Pitié-Salpêtrière Hospital 47-83 bd de l'Hôpital, 75651 Paris, cedex 13, Paris, France

Y Edel

Department of Public Health, ECIMUD (Hospitalised Drug Abusers Medical and Psychiatric Support Team) Pitié-Salpêtrière Hospital 47-83 bd de l'Hôpital, 75651 Paris, cedex 13, Paris, France

Correspondence to: Phuc Lehoang; nathalie.cassoux@psl.ap-hop-paris.fr

Accepted for publication 6 March 2002

References

- 1 **Mellinger M**, De Beauchamp O, Gallien C, *et al.* Epidemiological and clinical approach to the study of candidiasis caused by *Candida albicans* in heroin addicts in the Paris region: analysis of 35 observations. *Bull Narc* 1982;**34**:61-81.
- 2 **Bouchez J**, Beauverie P, Touzeau D. Substitution with buprenorphine in methadone- and morphine sulfate-dependent patients. Preliminary results. *Eur Addict Res* 1998;**4**(Suppl 1):8-12.
- 3 **Aguilar GL**, Blumenkrantz MS, Egbert PR, *et al.* *Candida* endophthalmitis after intravenous drug abuse. *Arch Ophthalmol* 1979;**97**:96-100.
- 4 **Pettit T**, JE Edwards, EP Purdy, *et al.* Endogenous fungal endophthalmitis. In: Pepose J, Holland G, Wilhelmus K, eds. *Ocular infection and immunity*. St Louis: Mosby, 1996:1262-85.
- 5 **Barza M**. Treatment options for candidal endophthalmitis. *Clin Infect Dis* 1998;**27**:1134-6.
- 6 **Martinez-Vazquez C**, Fernandez-Ulloa J, Bordon J, *et al.* *Candida albicans* endophthalmitis in brown heroin addicts: response to early vitrectomy preceded and followed by antifungal therapy. *Clin Infect Dis* 1998;**27**:1130-3.
- 7 **Dupont B**, Drouhet E. Cutaneous, ocular, and osteoarticular candidiasis in heroin addicts: new clinical and therapeutic aspects in 38 patients. *J Infect Dis* 1985;**152**:577-91.
- 8 **Leen CL**, Brettelle RP. Fungal infections in drug users. *J Antimicrob Chemother* 1991;**28**(Suppl A):83-96.
- 9 **Bouchez J**, Vignau J. The French experience—the pharmacist, general practitioner and patient perspective. *Eur Addict Res* 1998;**4**(Suppl 1):19-23.

Aetiology of microbial keratitis in northern Tanzania

The incidence of corneal blindness caused by microbial keratitis in the developing world is far higher than that in the developed world.¹ Microbial keratitis has become a more prominent cause of corneal blindness in east Africa as the uptake of measles immunisation

improves, reducing measles keratitis scarring, and with improved recognition and treatment of vitamin A deficiency, reducing its associated xerophthalmia and subsequent corneal scarring.

It has been shown that in tropical climates, keratitis of fungal aetiology is much more prevalent than in temperate climates.^{2,3} Little information is available about microbial keratitis in east Africa. The aim of this study was to identify the causative organisms of the condition seen in patients presenting to the Kilimanjaro Christian Medical Centre (KCMC) hospital in northern Tanzania, east Africa. KCMC is one of the largest hospitals in Tanzania, situated on the foothills of Mount Kilimanjaro, serving five regions in northern and central Tanzania—Kilimanjaro, Arusha, Singida, Tanga, and Dodoma with a population of approximately eight million people.

Clinical cases

Patients referred to, or presenting for the first time to, KCMC with clinical signs of microbial keratitis, were prospectively recruited to the study, between May 1997 and April 1998.

Table 1 Details of 44 patients presenting with microbial keratitis at KCMC

Characteristics	Range	Median
Age (years)	8-97	44
Time from onset of symptoms to presentation (days)	1-90	10
	Number	%
Sex		
Male	29	65.9
Female	15	34.1
Occupation		
Agricultural	22	50
Student/school	6	13.6
Driver/conductor	4	9.1
Maasai*	4	9.1
Retired	4	9.1
Soldier/guard	1	2.3
Miner	1	2.3
Teacher	1	2.3
Businessman	1	2.3
Treatment before presentation at KCMC of all cases (culture negative cases only)		
Nil	11 (6)	25
Local remedy	4 (2)	9.1
Inappropriate treatment	3 (1)	6.8
"Appropriate"† treatment, inadequate intensity	18 (5)	40.9
"Appropriate"† treatment	4 (2)	9.1
Unknown	4 (2)	9.1
History		
Vegetative trauma	14	32
All trauma	17	38.6
Previous corneal scar	14	32
Lid problems	2	4.6
Nil	11	25
Organisms cultured		
Fungi		
<i>Fusarium solani</i>	4	9.1
<i>Fusarium</i> sp	5	11.4
<i>Aspergillus fumigatus</i>	1	2.3
<i>Cladosporium</i> sp + <i>Bacillus</i> sp	1	2.3
Unidentified fungus + <i>Staph epidermidis</i>	1	2.3
All fungi	12	27.3
Gram positive bacteria		
<i>Staphylococcus epidermidis</i>	3	6.8
<i>Staphylococcus aureus</i>	2	4.6
Gram negative bacteria		
<i>Pseudomonas aeruginosa</i>	6	13.6
<i>Proteus</i> sp	1	2.3
No organism cultured	20	45.5

*Tribal herdsmen.

†Empirical treatment with broad spectrum topical antibiotic.

Patients with corneal ulceration without infiltration were excluded. These consisted of three patients with herpes simplex keratitis, two patients with Mooren's ulcer, and one patient with a neurotrophic ulcer. Two patients with secondary infection of a recent penetrating corneal injury were excluded. Two children were unable to undergo slit lamp examination and corneal scraping for microbiology specimens and were also excluded from the study.

Forty four corneal ulcers were seen. Thirty eight of the patients had visual acuity in the affected eye of 6/60 or worse, and the mean greatest diameter of the infiltrate on presentation was 5.1 mm. Organisms were cultured from 24 of the 44 ulcers (54.6%). Fifty per cent of positive cultures were fungal. Larger diameter ulcers were more likely to be culture positive and have poorer outcomes: mean ulcer diameter was 6.0 mm in culture positive ulcers and 3.7 mm in culture negative ulcers. Fungal growth had been predicted by positive microscopy for fungal elements in nine of the 12 cases that grew fungi (75%), and there was never positive fungal microscopy without fungal growth. All five Gram positive isolates had had Gram positive cocci identified on Gram staining initially but, in contrast, there were three cases where Gram positive cocci were initially seen on Gram staining, but cultures had grown other organisms (two fungi, one Gram negative bacilli). Full details are shown in Table 1.

Comment

In this study fungal keratitis accounted for 50% of culture positive cases of microbial keratitis in northern Tanzania, with the majority of these cases (42%) yielding pure fungal isolates on culture. These figures are similar to those published from west Africa, where 56% of microbial keratitis was caused alone or in part by fungi.³ As in studies from the United States,⁴ west Africa,³ and southern India,² the most common genus of fungus isolated was that of the filamentous fungus *Fusarium*.

There may have been a bias towards fungal ulcers in this study. KCMC is a referral centre, receiving severe ulcers from primary care centres, where topical antibacterial treatments are generally available and topical antifungal treatments are generally not. If the culture negative ulcers were predominantly bacterial ulcers, the relative frequency of fungal keratitis in this study would be artificially high. However culture negative ulcers had had a similar range of treatments to culture positive ulcers before presenting to KCMC, as can be seen from Table 1. There is no evidence to suggest the culture negative ulcers were predominantly of (treated) bacterial rather than fungal aetiology.

Study design limitations precluded any estimation of prevalence of microbial keratitis in the region, which would have been useful. The findings relate to northern and part of central Tanzania; with a similar climate, risk factors and primary care set up, the aetiology of microbial keratitis is likely to be similar in the wider region. The study set out to test for acanthamoeba antigen as part of the microbiological examination, but this became impossible after logistical difficulties.

The most important factor in outcome was the initial size of the ulcer on examination. Larger ulcers were more likely to be culture

positive and to have a poor outcome, such as a blinding corneal scar or requiring evisceration. Culture results were nevertheless useful in ascertaining antibiotic sensitivities, and in adding antifungal treatment where necessary. Any patient undergoing evisceration had usually been an inpatient for several weeks with a painful blind eye, had tried multiple treatment regimens, and had often requested evisceration himself. The overall rate of evisceration was 25%. Although there is little published material on outcomes of microbial keratitis in the developing world, this figure compares with a series of culture positive fungal ulcers in Madurai, India, where 20% were classified as "severe, with little prospect of recovery".⁵

Clearly, awareness of proper treatment regimens in northern Tanzania is paramount, particularly at the place of first contact, the village health centre, to prevent this overall picture of severe corneal ulcers with very poor visual prognosis. Treatment regimens should also take into account the high proportion of fungal keratitis. Microscopy looking specifically for fungal elements is a simple, quick, and useful test that could help direct initial treatment, along with clinical appearances suggestive of fungal infection. This might be more economically viable and practical than blanket coverage of all keratitis with an antifungal topical treatment in the first line therapy. Unfortunately consistently effective antifungal topical treatments are not widely available in this part of Africa.

Future studies could examine the efficacy of current treatments for fungal keratitis and how best to improve awareness of appropriate treatment regimens in the region.

Acknowledgements

This work was supported by grants from the British Council for the Prevention of Blindness and The Ulverscroft Foundation.

We are grateful to the hospital director, the staff, and the patients of KCMC for their collaboration in the above study.

T R G Poole, D L Hunter

Department of Ophthalmology, Kilimanjaro Christian Medical Centre, Moshi, Tanzania, Africa

E M K Maliwa

Department of Microbiology

A R C Ramsay

Clinical Laboratory

Correspondence to: Mr Poole; trgp@fish.co.uk

Accepted for publication 10 April 2002

References

- 1 **Whitcher JP**, Srinivasan M. Corneal ulceration in the developing world—a silent epidemic. *Br J Ophthalmol* 1997;**81**:622–3.
- 2 **Srinivasan M**, Gonzales CA, George C, *et al*. Epidemiology and aetiological diagnosis of corneal ulceration in Madurai, south India. *Br J Ophthalmol* 1997;**81**:965–71.
- 3 **Hagan M**, Wright E, Newman M, *et al*. Causes of suppurative keratitis in Ghana. *Br J Ophthalmol* 1995;**79**:1024–8.
- 4 **Leisegang TJ**, Forster RK. Spectrum of microbial keratitis in South Florida. *Am J Ophthalmol* 1980;**90**:38–47.
- 5 **Rahman MR**, Minassian DC, Srinivasan M, *et al*. Trial of chlorhexidine gluconate for fungal corneal ulcers. *Ophthalmic Epidemiol* 1997;**4**:141–9.

BOOK REVIEW



Oculoplastic Surgery Atlas. Eyelid Disorders. Eds Geoffrey J Gladstone, Evan H Black, Shoib Myint, Brian G Brazzo. Pp 130; £66.50. Heidelberg: Springer-Verlag, 2001. ISBN 0-387-95316-7.

This CD video atlas with accompanying text is the first in a series of three such atlases by these authors and is the first such oculoplastic atlas available. The atlas consists of 95 pages of text supplemented with black and white drawings in six chapters. Two CDs contain all the video sequences and these follow the same chapter layout as the text; surgical anatomy of the eyelid, entropion, ectropion, eyelid retraction, ptosis, and eyelid reconstruction.

There are a total of 17 video procedures typically lasting between 3 and 5 minutes and a 10 minute cadaveric anatomy sequence. The video quality is very acceptable for individual viewing but does not project as successfully. All sequences are well narrated and informative, covering basic and some more advanced oculoplastic procedures. The need for free skin grafting in one of the cases demonstrated is perhaps questionable but this does not detract from the educational value of the atlas. A number of associated procedures are covered in the videos—for example, harvesting skin/cartilage; however, these cannot be instantly located from the menus and an additional separate section including such procedures could perhaps have been usefully included.

The text is clearly written and concise but is not comprehensive and provides limited information relating to patient and procedure selection. A good deal of the text is covered in the narration accompanying the video.

The atlas is aimed at all those who have an interest in oculoplastic surgery but is particularly relevant to the ophthalmic surgeon. It will be a valuable asset for teaching residents and fellows and should make interesting viewing for all those routinely practising oculoplastic surgery.

From a personal point of view, I am always fascinated to watch other surgeons at work, as technical approaches to the same problem/operation are often quite diverse. This is one of the best ways to keep up to date and improve your own surgery.

Overall, this atlas will be a valuable asset to all those in training and a useful tool for those practising oculoplastic surgical procedures. I look forward to the next two atlases in the series and to further editions.

Garry Shuttleworth

NOTICES

Patient care

The latest issue of *Community Eye Health* (No 41) discusses patient care with both ophthalmologists' and patients' views given. For further information please contact: Journal of Community Eye Health, International Centre

for Eye Health, Institute of Ophthalmology, 11–43 Bath Street, London EC1V 9EL, UK (tel: +44 (0)20 7608 6910; fax: +44 (0)20 7250 3207; email: eyesource@ucl.ac.uk; website: www.jceh.co.uk). Annual subscription (4 issues) UK£25/US\$40. Free to workers in developing countries.

International Centre for Eye Health

The International Centre for Eye Health has published a new edition of the *Standard List of Medicines, Equipment, Instruments and Optical Supplies* (2001) for eye care services in developing countries. It is compiled by the Task Force of the International Agency for the Prevention of Blindness. Further details: Sue Stevens, International Centre for Eye Health, 11–43 Bath Street, London EC1V 9EL, UK (tel: +44 (0)20 7608 6910; email: eyesource@ucl.ac.uk).

Second Sight

Second Sight, a UK based charity whose aims are to eliminate the backlog of cataract blind in India by the year 2020 and to establish strong links between Indian and British ophthalmologists, is regularly sending volunteer surgeons to India. Details can be found at the charity website (www.secondsight.org.uk) or by contacting Dr Lucy Mathen (lucymathen@yahoo.com).

SPecific Eye ConditionS (SPECS)

SPecific Eye ConditionS (SPECS) is a not for profit organisation which acts as an umbrella organisation for support groups of any conditions or syndrome with an integral eye disorder. SPECS represents over fifty different organisations related to eye disorders ranging from conditions that are relatively common to very rare syndromes. We also include groups who offer support of a more general nature to visually impaired and blind people. Support

groups meet regularly in the Boardroom at Moorfields Eye Hospital to offer support to each other, share experiences and explore new ways of working together. The web site www.eyecconditions.org.uk acts as a portal giving direct access to support groups own sites. The SPECS web page is a valuable resource for professionals and may also be of interest to people with a visual impairment or who are blind. For further details about SPECS contact: Kay Parkinson, SPECS Development Officer (tel: +44 (0)1803 524238; email: k@eyeconditions.org.uk; www.eyecconditions.org.uk).

The British Retinitis Pigmentosa Society

The British Retinitis Pigmentosa Society (BRPS) was formed in 1975 to bring together people with retinitis pigmentosa and their families. The principle aims of BRPS are to raise funds to support the programme of medical research into an eventual cure for this hereditary disease, and through the BRPS welfare service, help members and their families cope with the everyday concerns caused by retinitis pigmentosa. Part of the welfare service is the telephone helpline (+44 (0)1280 860 363), which is a useful resource for any queries or worries relating to the problems retinitis pigmentosa can bring. This service is especially valuable for those recently diagnosed with retinitis pigmentosa, and all calls are taken in the strictest confidence. Many people with retinitis pigmentosa have found the Society helpful, providing encouragement, and support through the Helpline, the welfare network and the BRPS branches throughout the UK. (tel: +44 (0)1280 821 334; email: lynda@brps.demon.co.uk; web site: www.brps.demon.co.uk)

Ophthalmic Anesthesia Society (OAS) 16th Scientific Meeting

The 16th Scientific Meeting of the OAS will be held on 4–6 October 2002 in The Westin,

Michigan Avenue, 909 North Michigan Avenue, Chicago, USA (reservations +1 800 228 3000). Further details: OAS, 793-A Foothill Blvd, PMB 110, San Luis Obispo, CA 93405, USA (tel: +1 805 771 8300; web site: www.eyeanesthesia.org).

BEAVRS Meeting

The next BEAVRS meeting will be held in the Dalmahoy Hotel near Edinburgh on 31 October to 1 November 2002. Further details: Susan Campbell, Medical Secretary, Gartnavel General Hospital (email: susan.j.campbell.wg@northglasgow.scot.nhs.uk).

Cornea 2002—Celebrating 50 Years of Eyebanking

The Cornea 2002 meeting will be held in Le Meridien Hotel, London, Gatwick on 14–15 November 2002. Subjects to be covered will include eye banking, penetrating and lamellar keratoplasty, stem cell restoration, keratoprosthesis, advanced keratoplasty techniques, paediatric cornea, keratorefractive surgery, and intraocular refractive surgery. Spaces are limited and a beneficial package rate is available prior to 30 September 2002. Further details: CORNEA 2002 organiser at the Corneo Plastic Unit, The Queen Victoria Hospital, Holtye Road, East Grinstead, West Sussex, RH19 3DZ (tel: 01342 410 210 ext 560; fax: 01342 317 181; email: Cornea2002@hotmail.com).

CORRECTION

An error occurred in the article: Bilateral circumscribed haemangioma of the choroid not associated with systemic vascular syndrome. *Br J Ophthalmol* 2001;**85**:1260. The authors should have been listed as P Perri, C Incorvaia, C Costagliola, F Parmeggiani, G Lamberti, B Paduano, A Sebastiani.



Aetiology of microbial keratitis in northern Tanzania

T R G Poole, D L Hunter, E M K Maliwa, et al.

Br J Ophthalmol 2002 86: 941-942

doi: 10.1136/bjo.86.8.941

Updated information and services can be found at:

<http://bjo.bmj.com/content/86/8/941.full.html>

References

These include:

This article cites 5 articles, 3 of which can be accessed free at:

<http://bjo.bmj.com/content/86/8/941.full.html#ref-list-1>

Article cited in:

<http://bjo.bmj.com/content/86/8/941.full.html#related-urls>

Email alerting service

Receive free email alerts when new articles cite this article. Sign up in the box at the top right corner of the online article.

Notes

To request permissions go to:

<http://group.bmj.com/group/rights-licensing/permissions>

To order reprints go to:

<http://journals.bmj.com/cgi/reprintform>

To subscribe to BMJ go to:

<http://group.bmj.com/subscribe/>