

PostScript

LETTERS

If you have a burning desire to respond to a paper published in the *BJO*, why not make use of our "rapid response" option?

Log on to our website (www.bjophthalmol.com), find the paper that interests you, and send your response via email by clicking on the "eLetters" option in the box at the top right hand corner.

Providing it isn't libellous or obscene, it will be posted within seven days. You can retrieve it by clicking on "read eLetters" on our homepage.

The editors will decide as before whether to also publish it in a future paper issue.

Retinal arteriolar calcification in a patient with chronic renal failure

Extraskeletal calcification is a common complication of chronic renal failure. Numerous locations for metastatic calcification have been described. We present an unusual case of calcium deposition in the eye.

Case report

A 33 year old woman developed chronic renal failure at the age of 15 as a result of medullary cystic kidneys. She underwent a renal transplant at the age of 17, which failed 6 years later and so she was maintained on continuous ambulatory peritoneal dialysis.

The patient subsequently developed refractory secondary hyperparathyroidism with ectopic calcification and reduced bone density. Her serum biochemistry between 1992 and 1997 showed a persistently high calcium phosphate product ranging between 3.6 and 8.9 mmol/l (normal range 1.6-3.4 mmol/l) with hypercalcaemia (2.36-2.71 mmol/l (normal range 2.0-2.4 mmol/l)) and hyperphosphataemia (2.36-3.42 mmol/l (normal range 0.8-1.4 mmol/l)). Systemic complications of her disease included hypertension, avascular necrosis of both hips, and reduced left ventricular function. Total parathyroidectomy was performed in 1997 with the aim of controlling her biochemical abnormalities. As a result, her calcium phosphate product had improved to 4.4-4.8 mmol/l and a year later, her bone density had returned to normal.

She initially presented to the eye clinic in 1994 with ocular complications of hypercalcaemia. She had recurrent episodes of conjunctivitis, band keratopathy requiring multiple excimer laser therapy, and central posterior subcapsular lens opacities. Fundus examination revealed calcified and attenuated arterioles bilaterally with ischaemic changes (Fig 1). She developed secondary neovascularisation with subsequent bilateral vitreous haemorrhages, with vision of counting fingers in the right eye and hand movements in the left eye. Pars plana vitrectomy and cataract extractions were performed in each eye, followed by a YAG capsulotomy on her left eye

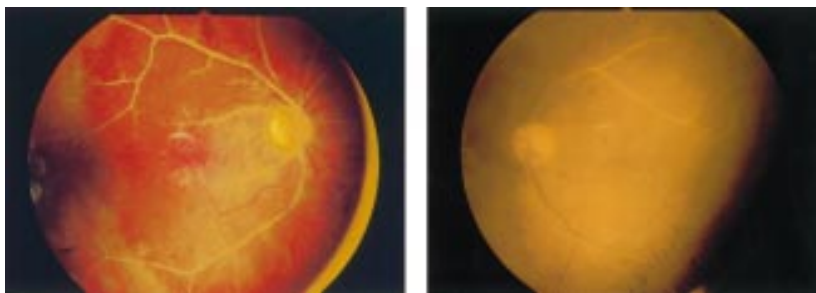


Figure 1 Bilateral retinal arteriolar calcification.

4 months postoperatively. Her most recent corrected visual acuity was 6/12 in each eye.

Comment

Metastatic calcification occurs as a result of biochemical abnormalities of calcium and phosphate. It is distinguished from dystrophic calcification, which occurs in previously damaged tissue.

Causes of metastatic calcification include abnormal dietary intake of calcium or vitamin D, extensive bone destruction as in osteomyelitis, or metastatic tumours. In patients with chronic renal failure, it is usually a consequence of secondary hyperparathyroidism. This is the physiological hypertrophy of the parathyroid glands, which occurs in response to hypocalcaemia. The resulting increase in parathyroid hormone levels causes increased bone resorption and hence a rise in serum calcium and phosphate levels.

An important factor affecting the incidence of soft tissue calcification is a high serum calcium phosphate product.¹ If the concentrations of calcium and phosphorus rise beyond a critical level, their solubility product is exceeded and precipitation occurs in tissues. Visceral deposits are an amorphous or microcrystalline compound composed of calcium, phosphate, or magnesium whereas arterial deposits consist of calcium hydroxyapatite crystals.² In arteries, calcium is principally deposited in the tunica media and internal elastic lamina.³

Common ocular sites of calcium deposition include the conjunctiva (a cause of red eyes in renal patients), and Bowman's membrane (band keratopathy). These deposits tend to increase in extent in patients treated with regular dialysis and regress in patients receiving transplanted kidneys.⁴ Posterior segment calcification is less common and tends to affect the sclera and choroid. Metastatic sclerochoroidal calcifications typically occur as bilateral, multifocal, yellow fundus lesions and are usually located superotemporally.⁵ Massive deposition of calcium hydroxyapatite in the previtreal space in a patient with chronic renal failure has also been reported.⁶

The present case exhibits a unique form of metastatic calcification. In the skin, a consequence of small vessel calcification is ischaemia, which occurs as a result of endovascular fibrosis, thrombosis, or calcific obliteration.⁷ Theoretically, our patient's ischaemic fundal changes may be attributed to both hypertensive retinopathy and the extensive deposition of calcium in the retinal arterioles.

This case demonstrates a dramatic and, to our knowledge, previously unreported ocular manifestation of metastatic calcification.

D V Patel, M P Snead, K Satchi

Vitreoretinal Service, Box 41, Addenbrooke's Hospital, Hills Road, Cambridge CB2 2QQ, UK

Correspondence to: Mr M P Snead

Accepted for publication 11 February 2002

References

- 1 Block GA. Prevalence and clinical consequences of elevated Ca x P product in hemodialysis patients. *Clin Nephrol* 2000;**54**:318-24.
- 2 Parfitt AM. Soft tissue calcification in uraemia. *Arch Intern Med* 1969;**124**:544-56.
- 3 Alfrey AC, Solomons CC, Ciricillo J. Extraosseous calcification-evidence for abnormal pyrophosphate metabolism in uraemia. *J Clin Invest* 1976;**57**:692-699.
- 4 Porter R, Crombie AL. Corneal and conjunctival calcification in chronic renal failure. *Br J Ophthalmol* 1973;**57**:339-43.
- 5 Goldstein BG, Miller J. Metastatic calcification of the choroid in a patient with primary hyperparathyroidism. *Retina* 1982;**2**:76-9.
- 6 Haddad R. Metastatic calcification to the peripheral fundus in chronic renal failure. *Ophthalmologica* 1979;**179**:178-83.
- 7 Fischer AH, Morris DJ. Pathogenesis of calciphylaxis: study of three cases with literature review. *Hum Pathol* 1995;**26**:1055-64.

Ophthalmic artery occlusion following pars plana vitrectomy in a patient with Terson's syndrome

Acute ophthalmic artery occlusion is rare and results in severe ocular dysfunction. We report a patient with Terson's syndrome who developed an acute ophthalmic artery occlusion after pars plana vitrectomy.

Case report

A 39 year old man suffered a stroke from a subarachnoid haemorrhage on 15 August 2000 and had clipping surgery for a brain aneurysm. The patient presented 3 weeks later, complaining of loss of vision in both eyes. He had had hypertension for 10 years and his sister had a subarachnoid haemorrhage and a cerebral infarction. Visual acuity was hand movements in both eyes, and the intraocular pressure was 10 mm Hg in both eyes. Slit lamp and ophthalmoscopic examination disclosed dense vitreous haemorrhage in both eyes, and the retinas were not visible. B-mode echography detected intravitreal haemorrhage and an incomplete posterior vitreous detachment but the retina was

attached bilaterally. The results of other routine laboratory examinations were within normal limits.

Pars plana vitrectomy was performed on the right eye on 30 October after retrobulbar anaesthesia, and the vitreous haemorrhage and epimacular membrane were removed successfully. The retina, retinal vessels, and optic disc appeared normal intraoperatively.

On postoperative day 1, the patient complained of ocular pain in the right eye and the intraocular pressure was 1 mm Hg in the right eye. Slit lamp examination showed marked corneal endothelial folds and fibrinous material filling the anterior chamber. Leakage from the surgical wounds was not observed. Because the hypotony and inflammation did not improve and the right fundus could not be observed, we performed pars plana vitrectomy on 2 November.

The fibrinous material in the anterior chamber and the anterior vitreous were removed. The optic disc appeared pale and swollen. A retinal detachment and a cherry red spot at the macula were not observed; however, the retina appeared pale with multiple blot haemorrhages. The arteries were severely narrowed and the veins were markedly engorged (Fig 1).

Fluorescein angiography (FA) demonstrated a delayed entry of fluorescein into the choroid and central retinal artery. The hypotony did not improve after the second surgery, and the pupil was finally occluded in the right eye. The right visual acuity decreased to no light perception.

Colour Doppler sonography, performed 4 months later, revealed that the blood flow velocity was slower in the right (15 cm/s) than in the left ophthalmic artery (25 cm/s). The calibre of the right internal carotid artery was not significantly narrowed, but mixed plaques were attached to the inner wall. Digital subtraction angiography (DSA) of the images obtained immediately after the subarachnoid haemorrhage and 3 weeks after the second surgery, showed good filling of the right ophthalmic artery, indicating that the blood flow into the right eye had been well maintained before the first surgery. From these findings, the patient was diagnosed with an acute ophthalmic artery occlusion following the first vitrectomy.

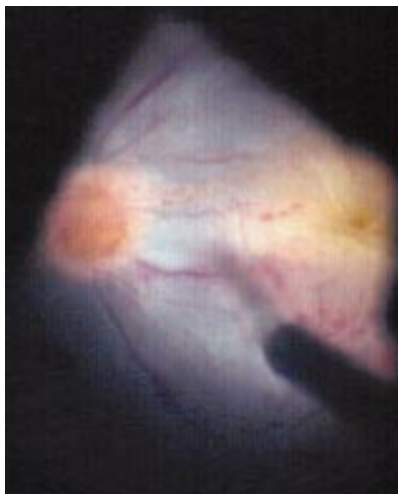


Figure 1 Fundus photograph of the right eye during the second surgery demonstrating optic disc swelling, whitening of the posterior pole retina, and retinal blot haemorrhage. Retinal arteries are narrowed and retinal veins are engorged.

Comment

There are several causes for the ophthalmic artery occlusion,¹⁻³ and atrial fibrillation and atrial myxoma were excluded in our case, because of normal electrocardiograms and chest x rays. The patient did not have any history of ocular trauma and did not show any symptoms suggesting orbital lesions.

Vasospasms following the subarachnoid haemorrhage can cause ophthalmic artery occlusion; however, such vasospasms usually normalise within 4 weeks after the subarachnoid haemorrhage.⁴ In our case, the occlusion occurred 3 months after the stroke and immediately after the pars plana vitrectomy, and the DSA findings showed good filling in the right ophthalmic artery, eliminating arteriosclerotic changes in the ophthalmic artery as the cause of the occlusion. Thus, it is most likely that the ophthalmic artery was occluded by an embolus from the atheromatous lesions in the internal carotid artery.

Visual prognosis in Terson's syndrome is usually good,⁵ if other retinal disorders are not present. However, patients with this disease usually suffer from other systemic diseases, and we believe ophthalmologists should be aware that an ophthalmic artery occlusion can be associated with vitrectomy in patients with Terson's syndrome.

W Saito, S Yamamoto, S Takeuchi

Department of Ophthalmology, Toho University
Sakura Hospital, Japan

Y Mitamura

Department of Ophthalmology, Sapporo Medical
University, Japan

Correspondence to: Shuichi Yamamoto, MD,
Department of Ophthalmology, Toho University
Sakura Hospital, 564-1 Shimoshizu, Sakura, Chiba
285-8741, Japan; shuyama@med.toho-u.ac.jp

Accepted for publication 5 April 2002

References

- 1 **Brown GC**, Magargal LE, Sergott R. Acute obstruction of the retinal and choroidal circulations. *Ophthalmology* 1986;**93**:1373-82.
- 2 **Rafuse PE**, Nicolle DA, Hutnik CML, et al. Left atrial myxoma causing ophthalmic artery occlusion. *Eye* 1997;**11**:25-9.
- 3 **Bullock JD**, Falter RT, Downing JE, et al. Ischemic ophthalmia secondary to an ophthalmic artery occlusion. *Am J Ophthalmol* 1972;**74**:486-93.
- 4 **Harders AG**, Gilsbach JM. Time course of blood velocity changes related to vasospasm in the circle of Willis measured by transcranial Doppler ultrasound. *J Neurosurg* 1987;**66**:718-28.
- 5 **Schults PN**, Sobol WM, Weingeist TA. Long-term visual outcome in Terson syndrome. *Ophthalmology* 1991;**98**:1814-19.

Acute bilateral blindness caused by accidental methanol intoxication during fire "eating"

Methanol intoxication can cause severe visual dysfunction and death. Indeed, small amounts of ingested methanol are sufficient to produce acute destruction of parts of the central nervous system leading to permanent neurological dysfunction and irreversible blindness.¹⁻³ More than half of the methanol related morbidity and mortality is classified as accidental and therefore preventable.¹ We present, to the best of our knowledge, the first case of a methanol intoxication caused by accidental ingestion of methanol during fire eating (US, fire spitting).

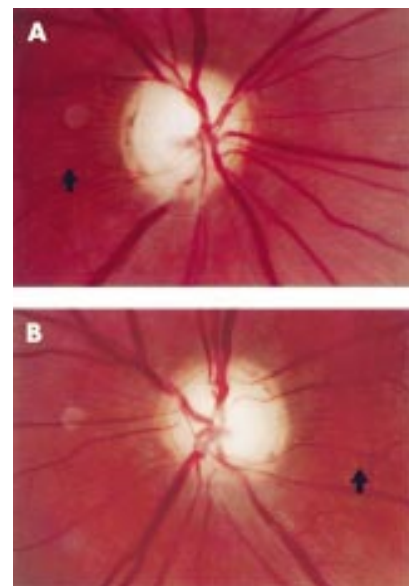


Figure 1 Right (A) and left (B) optic discs of the patient with pseudoglaucomatous optic neuropathy secondary to methanol intoxication (optic disc area both eyes: 2.6 mm²; neuroretinal rim area right eye: 1.1 mm²; left eye: 0.92 mm²). Note intensely pale appearance of the optic disc with alteration of neuroretinal rim configuration and (most likely) pre-existing peripapillary atrophy zone. Note also the "washboard-like" pattern of the internal limiting membrane (arrow) secondary to acute loss of retinal nerve fibres.

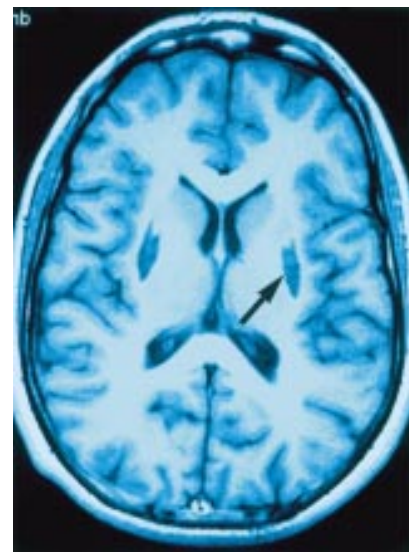


Figure 2 MRT imaging of the patient with methanol intoxication during fire eating (6 weeks after ingestion). Bilateral symmetric necrotic areas in the basal ganglia (putamen; arrow) in the T1 weighted image (hypointense lesions with marginal contrast enhancement) are typical of methanol intoxication.

Case report

A 19 year old German patient was admitted to a Spanish university hospital with acute methanol intoxication. The comatose patient had a metabolic acidosis with pH 7.16 and

was treated by intravenous ethyl alcohol and bicarbonate. Neurological examination 2 days later with the patient awake revealed extrapyramidal motor disturbances, and computer tomography (CT) scans correspondingly showed basal ganglia infarctions. Visual acuity at this time was light perception in both eyes. Optic discs were reported to be oedematous with dilated peripapillary vessels.

During summertime, the patient had earned his living by fire eating at different Spanish locations. According to the patient, a sudden episode of hiccupping during fire eating caused accidental ingestion of denatured alcohol containing methanol.

The patient was transferred to Germany thereafter and presented to our department 6 weeks after the acute intoxication. Visual acuity was light perception. The pupils were dilated and unreactive to light. The eyes were otherwise unremarkable, with the exception of pronounced pale, atrophic optic discs with "pseudoglaucomatous" thinning of the neuroretinal rim area (Fig 1A and B). Acute loss of nerve fibres presumably had induced a "washboard-like pattern" of internal limiting membrane. Nerve fibre layer measurement using GDx technology demonstrated abnormally low values. On magnetic resonance tomography (MRT) imaging, bilateral putamen necrosis typical of methanol intoxication was seen (Fig 2); otherwise the MRT examination was normal. Flash visual evoked potentials (VEPs) were nearly extinguished.

Comment

As a clear, colourless, volatile liquid with a weak odour, methanol is difficult to differentiate from other forms of alcohols such as ethanol.^{4,5} Methanol is rapidly absorbed not only after oral ingestion but by inhalation or after cutaneous exposure and becomes oxidised in the liver to formaldehyde and to formic acid, metabolites which are more toxic than methanol itself and which inhibit mitochondrial ATP production. Methanol poisoning can be life threatening and blinding. Early ocular symptoms and signs include photophobia, blurred vision, and painful eye movements as well as sluggish pupil reactions, reduced visual acuity, and optic disc oedema with tortuous retinal vessels. Histopathologically, circumscribed myelin damage behind the lamina cribrosa of the optic nerve has been reported.⁶ The electrophysiological changes following acute methanol ingestion suggest that methanol affects photoreceptors, Muller cells, and the retrolaminar portion of the optic nerve.⁷ Treatment is by drug elimination (for example, haemodialysis) and inhibition of metabolism of methanol to toxic formic acid by competitive inhibition of the enzyme alcohol dehydrogenase (ethyl alcohol or fomepizole).^{8,9}

Our patient demonstrates that accidental ingestion of even small amounts of denatured alcohol containing methanol can cause irreversible blindness with intracerebral lesions. For fire eating only denatured alcohol free of methanol should be used.

Acknowledgements

We thank Priv-Doz Dr W Mühlberg, Giftinformationszentrale, Medizinische Klinik II, Klinikum Nürnberg Nord, and Dr A Hahn, Bundesinstitut für gesundheitlichen Verbraucherschutz und Veterinärmedizin, Berlin.

C Cursiefen, A Bergua

Department of Ophthalmology, University of Erlangen-Nürnberg, Erlangen, Germany

Correspondence to: Dr Claus Cursiefen, Schepens Eye Research Institute, Department of Ophthalmology, Harvard Medical School, 20 Staniford Street, Boston, MA 02114-2500, USA; cursiefen@vision.eri.harvard.edu

Accepted for publication 5 April 2002

References

- 1 Liu JJ, Daya MR, Mann NC. Methanol-related deaths in Ontario. *J Toxicol Clin Toxicol* 1999;**37**:69-73.
- 2 Kuteifan K, Oesterlé, Tajahmady T, et al. Necrosis and haemorrhage of the putamen in methanol poisoning shown on MRI. *Neuroradiology* 1998;**40**:158-60.
- 3 Onder F, Ilker S, Kansu T, et al. Acute blindness and putaminal necrosis in methanol intoxication. *Int Ophthalmol* 1998;**22**:81-4.
- 4 Seme MT, Summerfelt P, Neitz J, et al. Differential recovery of retinal function after mitochondrial inhibition by methanol intoxication. *Invest Ophthalmol Vis Sci* 2001;**42**:834-41.
- 5 Eells J, Henry M, Lewandowski M, et al. Development and characterization of a rodent model of methanol-induced retinal and optic nerve toxicity. *Neurotoxicology* 2000;**21**:321-30.
- 6 Sharpe JA, Hostovsky M, Bilbao JM, et al. Methanol optic neuropathy: a histopathological study. *Neurology* 1982;**32**:1093-100.
- 7 McKellar MJ, Hidajat RR, Elder MJ. Acute ocular methanol toxicity: clinical and electrophysiological features. *Aust NZ J Ophthalmol* 1997;**25**:225-30.
- 8 Brent J, McMartin K, Phillips S, et al. Fomepizole for the treatment of methanol poisoning. *N Engl J Med* 2001;**344**:424-9.
- 9 Girault C, Tamion F, Moritz F, et al. Fomepizole (4-methylpyrazole) in fatal methanol poisoning with early CT scan cerebral lesions. *J Toxicol Clin Toxicol* 1999;**37**:777-80.

Central serous chorioretinopathy after inhaled steroid use for post-mycoplasmal bronchospasm

Central serous chorioretinopathy (CSR) is an uncommon cause of central visual loss, metamorphopsia, and dyschromatopsia, generally involving submacular and/or subretinal pigment epithelial (RPE) fluid blisters. While most cases of CSR are idiopathic, several associated risk factors have been implicated, such as so called type A personality, emotional stress, and male sex.¹ Systemic steroid use has long been known to be associated with CSR.² This case report demonstrates the development of CSR secondary to inhaled steroid use specifically for the management of post-mycoplasmal bronchospasm.

Case report

We evaluated a 40 year old white woman for complaints of metamorphopsia and decreased

visual acuity on the left side for approximately a 2 month period. She denied previous similar episodes in either eye. Four months earlier, treatment for bronchospasm following mycoplasma pneumonia had been initiated with fluticasone and chromolyn sodium oral inhalers. The only other medication she had been taking was synthetic thyroid hormone replacement for the management of primary hypothyroidism.

Examination revealed best corrected visual acuities of right eye 20/15 and left eye 20/20-2. She scored right eye 7/7 correctly and left eye 6/7 correctly using Hardy-Rand-Rittler colour plates. The patient reported some central distortion on Amsler grid testing on the left side. A single spot of RPE hypopigmentation was observed in the right macula, and a shallow blister of submacular fluid on the left side (Fig 1). No anterior or posterior segment inflammatory cells were seen in either eye, and the remainder of the external, slit lamp, and dilated funduscopic examinations were normal in both eyes.

Intravenous fluorescein angiography demonstrated several macular RPE "window" defects, more prominent on the left side than the right, and several foci of RPE leaks in the left macular region (Fig 2).

A diagnosis of CSR was made and the oral steroid inhaler was discontinued. Over the next several weeks, the patient's symptoms and objective clinical findings resolved, with the exception of some residual foci of RPE hypopigmentation in the left macula. At the 2 year follow up, the patient was free from recurrent symptoms and without new ophthalmoscopic findings. Acuity remained right eye 20/15 and left eye 20/20.

Comment

Systemic steroid use has been recognised in association with CSR since 1984.³ Inhaled steroids, administered orally or nasally, have been available commercially in the United States since the early 1980s. There are three published reports describing ophthalmic complications of inhaled steroid use, including ocular hypertension,⁴ CSR,⁵ and posterior subcapsular cataracts.⁶ To our knowledge, no case has been reported of an association between CSR and inhaled steroid use specifically for the management of post-mycoplasmal bronchospasm.

The apparently strong association between systemic steroid use and CSR, as well as a reported association between Cushing's syndrome and CSR,⁷ may indicate a cause and effect relation. It is likely that cortisol plays a part in the development of CSR. However, the hormonal, cellular, and biochemical nature of such a relation remains obscure at this time.

Most cases of CSR are self limited. A few individuals may require specific treatment

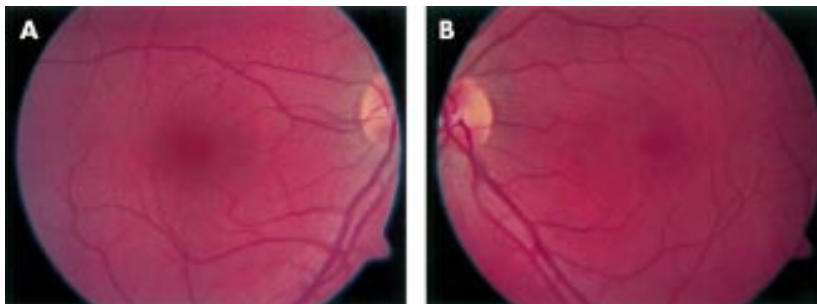


Figure 1 (A) Foci of retinal pigment epithelial hypopigmentation, right eye. (B) Shallow submacular fluid, left eye.

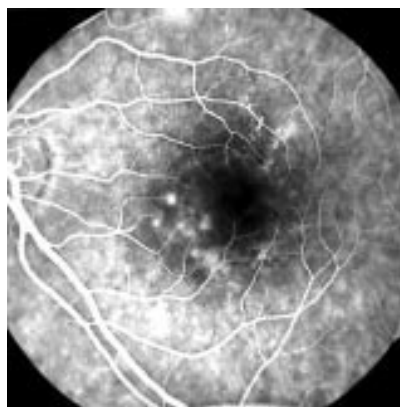


Figure 2 Late venous phase retinal fluorescein angiogram, left eye, demonstrating multiple hyperfluorescent foci of leakage at the level of the retinal pigment epithelium.

(for example, focal macular laser) for CSR. This is the second reported case that we are aware of where complete resolution of CSR associated symptoms following cessation of inhaled corticosteroid therapy was observed.³ While we believe that this medication cessation probably aided in the resolution of CSR in our patient, it is possible that the remission may have been spontaneous. Occasionally, other anti-inflammatory or immunomodulatory medications may be required in order to wean certain individuals off their systemic steroids.

We believe that patients being prescribed nasal and/or oral inhaled steroids ought to be warned about the possibility of CSR developing, with particular instructions to report any visual loss, metamorphopsia, or dyschromatopsia to their prescribing care givers.

B Fardin, D J Weissgold

Department of Ophthalmology, College of Medicine, University of Vermont, Burlington, Vermont, USA

Correspondence to: David J Weissgold, MD, Ophthalmology, UVM/FAHC, 1 S Prospect Street, Burlington, VT 05401, USA; david.weissgold@vtmednet.org

Accepted for publication 9 April 2002

References

- 1 **Gass JDM**. *Stereoscopic atlas of macular diseases*. 4th ed. St Louis: Mosby, 1997.
- 2 **Spraul CW**, Lang GE, Lang GK. Retinal pigment epithelial changes associated with systemic corticosteroid treatment: report of cases and review of the literature. *Ophthalmologica* 1998;**212**:142–8.
- 3 **Wakakura M**, Ishikawa S. Central serous chorioretinopathy complicating systemic corticosteroid treatment. *Br J Ophthalmol* 1984;**68**:329–31.
- 4 **Opatowsky I**, Feldman RM, Gross R, et al. Intraocular pressure elevation associated with inhalation and nasal corticosteroids. *Ophthalmology* 1995;**102**:177–9.
- 5 **Haimovici R**, Gragoudas ES, Duker JS, et al. Central serous chorioretinopathy associated with inhaled or intranasal corticosteroids. *Ophthalmology* 1997;**104**:1653–60.
- 6 **Fraunfelder FT**, Meyer SM. Posterior subcapsular cataracts associated with nasal or inhalation corticosteroids [letter]. *Am J Ophthalmol* 1990;**109**:489–90.
- 7 **Bouzas EA**, Scott MH, Mastorakos G, et al. Central serous chorioretinopathy in endogenous hypercortisolism. *Arch Ophthalmol* 1993;**111**:1229–33.

Concentration of intravitreally injected triamcinolone acetonide in aqueous humour

The unwanted proliferation of intraocular tissue such as vascular retinal cells in eyes with ischaemic retinopathies, subretinal neovascular tissue in eyes with exudative age related macular degeneration, and retinal pigment epithelium cells in the case of proliferative vitreoretinopathy, is one of the important problems still mostly unsolved in clinical ophthalmology. Since the early 1950s, corticosteroids have been used in ophthalmology to suppress intraocular inflammation by reducing inflammatory exudation and inhibiting proliferation of fibroblasts and formation of granulation tissue. They have been applied either topically as eye drops, locally by subconjunctival, parabolbar or retrobulbar injections, or systemically as oral medications or intravenous or intramuscular injections. Machermer *et al*, based on clinical observations and pathogenic considerations, suggested the intravitreal application of cortisone to locally suppress intraocular inflammation and proliferation of cells, especially in patients with proliferative vitreoretinopathy.¹ Since cortisone is washed out of the eye within approximately 24 hours after a single intravitreal injection,² Machermer *et al* suggested the use of the crystalline form of cortisone, which may provide intraocularly available cortisone for a longer period than the single injection of soluble cortisone. Clinical studies have correspondingly revealed that a single intraocular injection of triamcinolone acetonide may be a therapeutic option as adjunctive treatment of exudative age related macular degeneration, diabetic cystoid macular oedema, and proliferative diabetic retinopathy.^{3–6}

It is unknown, so far, how long after a single intravitreal injection clinically detectable concentrations of triamcinolone acetonide are available in the eye. Ophthalmoscopic findings of patients who received an intravitreal injection of triamcinolone acetonide suggest that triamcinolone acetonide crystals remain visible in the eye up to about 6 months after the injection.⁶ The purpose of the present study was, therefore, to assess the concentration of triamcinolone acetonide in aqueous humour samples obtained from patients who had previously received an intravitreal injection of triamcinolone acetonide.

Case report

The study included three female patients aged 74, 76, and 80 years. They had received an intravitreal injection of 25 mg of triamcinolone acetonide as an attempt to treat exudative age related macular degeneration with subfoveal occult neovascularisation. All patients were fully informed about the experimental character of the treatment and all patients signed an informed consent. The ethics committee of the university had approved the study following the tenets of the Declaration of Helsinki. A sample of aqueous humour was obtained from the anterior chamber through a paracentesis at the start of cataract surgery which had become necessary because of the cataractogenic effect of steroids ($n = 2$), or which was performed before a intravitreal re-injection of triamcinolone acetonide ($n = 1$).

The concentration of triamcinolone acetonide was 13 µg/l in the sample removed 3.5 months after the intraocular application of triamcinolone acetonide. The concentration of triamcinolone acetonide was 3 µg/l in the aqueous humour sample obtained from the

eye which had undergone the intravitreal triamcinolone injection 6 months before sampling. Triamcinolone acetonide was not detectable in the aqueous humour sample removed 12 months after the intraocular application of triamcinolone acetonide.

Comment

The results suggest that detectable concentrations triamcinolone acetonide can be found in the aqueous humour up to 6 months after its intravitreal instillation. Future studies may evaluate whether the concentrations of 13 µg/l or 3 µg/l are sufficient for an antiproliferative effect of triamcinolone acetonide in eyes with exudative age related macular degeneration or other proliferative intraocular diseases; which factors, besides the time interval after its injection, may be responsible for the varying concentrations of triamcinolone acetonide; and which is the therapeutic range of concentrations of intraocular triamcinolone acetonide for an antiproliferative or antiexudative effect.

Jost B Jonas

Department of Ophthalmology, Faculty for Clinical Medicine Mannheim, Ruprecht-Karls-University Heidelberg, Germany; Jost.Jonas@augen.ma.uni-heidelberg.de
Proprietary interest: none.

Accepted for publication 18 April 2002

References

- 1 **Machermer R**, Sugita G, Tano Y. Treatment of intraocular proliferations with intravitreal steroids. *Trans Am Ophthalmol Soc* 1979;**77**:171–80.
- 2 **Schindler RH**, Chandler DB, Thresher R, et al. The clearance of intravitreal triamcinolone acetonide. *Am J Ophthalmol* 1982;**93**:415–17.
- 3 **Machermer R**. Five cases in which a depot steroid (hydrocortisone acetate and methylprednisolone acetate) was injected into the eye. *Retina* 1996;**16**:166–7.
- 4 **Challa JK**, Gillies MC, Penfold PL, et al. Exudative macular degeneration and intravitreal triamcinolone: 18 month follow up. *Aust N Z J Ophthalmol* 1998;**26**:277–81.
- 5 **Danis RP**, Ciulla TA, Pratt LM, et al. Intravitreal triamcinolone acetonide in exudative age-related macular degeneration. *Retina* 2000;**20**:244–50.
- 6 **Jonas JB**, Hayler JK, Söfker A, et al. Intravitreal injection of crystalline cortisone as adjunctive treatment of proliferative diabetic retinopathy. *Am J Ophthalmol* 2001;**131**:468–71.

Two rare causes of posterior ischaemic optic neuropathy: eosinophilic fasciitis and Wegener's granulomatosis

Anterior ischaemic optic neuropathy (AION) and the need for its early diagnosis and treatment in temporal arteritis are well known especially because of the risk of bilateral blindness. Posterior ischaemic optic neuropathy (PION) is a rarer condition but has been described in systemic lupus erythematosus, polyarteritis nodosa, hypertension, diabetes, anterior carotid artery occlusion, blood loss, intraoperative hypotension, as well as temporal arteritis. We describe two cases of retrobulbar ischaemic optic neuropathy, one due to eosinophilic fasciitis and the other to Wegener's granulomatosis and discuss their presentation and management.

Case 1

An 87 year old woman, who was previously diagnosed with eosinophilic fasciitis, presented with acute visual loss of her right eye. Ten years earlier she had had a history of skin

tightness and thickening affecting her arms, legs, and trunk but sparing her face. She had pain and swelling of her hands, early morning stiffness, but no Raynaud's phenomenon. Blood tests at the time showed an erythrocyte sedimentation rate (ESR) of 21 mm in the first hour, haemoglobin 12.7 g/dl, white cell count $7.6 \times 10^9/l$, of which 19% were eosinophils (1–6%). Eosinophilic fasciitis was diagnosed on the basis of her clinical picture and blood eosinophilia. She was also anti-nuclear antibody positive; anti-double stranded DNA antibodies, anti-neutrophil cytoplasmic antibodies (ANCA), and cardiolipin antibodies were negative and protein S and C normal and she had been started on prednisolone and aspirin. She had also had several transient ischaemic attacks involving the right side of her body with paraesthesia of her face, hand, and right foot, which lasted 5 minutes at a time. She had a history of hypertension treated with amlodipine and carotid ultrasonography demonstrated less than 40% carotid stenosis.

On presentation she had already had two painless episodes of clouding of vision with flashing lights and a shadow which cleared after a couple of hours on each occasion. On the third occasion she suddenly developed clouding of vision in her right eye which did not recover.

On examination her visual acuity was 6/18 right, 6/9 left. She had a right afferent pupillary defect, but no retinal abnormalities apart from drusen at the macula reflecting age related change. Similar changes, albeit less marked, were also present at the left macula. The right optic disc was normal but became pale later 2 months after the initial episode. Her ESR was 63 mm in the first hour and her long term steroids were increased from 5 mg to 30 mg of prednisolone and she continued on aspirin. She had no further episodes of visual loss and there was some improvement in the visual field.

Case 2

A 56 year old woman who had Wegener's granulomatosis was referred to the eye department with sudden loss of vision in her right eye. Her medical history included rheumatoid arthritis, secondary Sjögren's syndrome, vitiligo, and pernicious anaemia treated with vitamin B12 injections. She took ibuprofen and azathioprine for arthritis.

She had chronic sinusitis which became more severe over 3 months and had nose bleeds, facial pain, anorexia, and lost 1 stone (6.3 kg) in weight over 2 months. Blood tests showed she had a negative serum ACE, a positive c-ANCA, and a diagnosis of Wegener's granulomatosis was made after a nasal biopsy (Fig 1). She was started on intravenous cyclophosphamide 750 mg and intravenous methylprednisolone 1 g, and maintained on 40 mg of oral prednisolone.

Following her second course of chemotherapy, while on holiday in Spain she noticed visual disturbances in her right eye and had a sudden loss of vision 2 days before her return. Visual acuity was hand movements in the right eye, 6/9 in the left eye. She had a right central scotoma to confrontation, a relative afferent pupil defect, and no proptosis. Intraocular pressures and funduscopy were normal with no optic disc swelling (Fig 2), ESR was 39. A computed tomography scan showed extensive inflammatory disease in the sinuses and anterior cranial fossa but no orbital masses or any other evidence of compression of the optic nerves or abnormality of the rest of the visual pathway. She had a third dose of intravenous

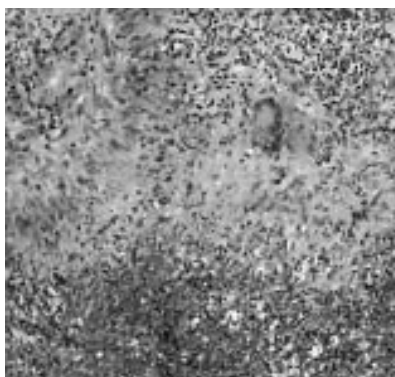


Figure 1 Nasal biopsy (case 2) showing foci of necrosis surrounded by epithelioid histiocytes and giant cells typical of Wegener's granulomatosis (haematoxylin and eosin staining).

cyclophosphamide 750 mg but unfortunately continued to lose vision rapidly. Two days later she had bare perception of light in both eyes and her pupils were unresponsive to light. She had a magnetic resonance imaging scan and the optic chiasm, intracranial, and orbital segments of the optic nerves appeared normal with the nerve sheaths a little prominent but no soft tissue mass in the orbits. Her clotting studies were normal and she was started on anticoagulants. She had four sessions of chemotherapy, intravenous cyclophosphamide 750 mg, and pulsed steroids as well as a 5 day course of intravenous immunoglobulin (found to be effective in refractory in Wegener's granulomatosis¹). Though her upper respiratory symptoms improved there was no change in her vision and she remained with no perception of light in the right eye and bare perception of light in the left eye. The optic discs went on to become atrophic and electrodiagnostics showed normal electroretinograms with low amplitude visual evoked responses though normal latency.

Comment

Both patients presented with posterior ischaemic optic neuropathy (PION) where there was visual loss, with signs of optic tract neuropathy but normal optic discs which later became atrophic. This condition was described by Hayreh,² who in one study of 170 patients with giant cell arteritis found PION in 7%.³ There are no disc signs initially as the part of the optic nerve affected is posterior to the retrolaminar region and the blood supply is from the peripheral centripetal vascular system rather than the posterior ciliary artery circulation affected in anterior ischaemic optic neuropathy.

Eosinophilic fasciitis is a rare connective tissue disorder first described by Shulman in 1974,⁴ presenting with painful swelling and brawny induration of the limbs and trunk, characteristic histology with sclerosis and lymphocytic inflammation affecting the deep fascia, subcutaneous tissue, and a peripheral eosinophilia (often more than 7% of the differential WCC). More than 200 cases have been described⁵ and there may be haematological associations such as aplastic anaemia, thrombocytopenia, leukaemia, and myelodysplasia⁶; other associated systemic conditions such as arthritis, thyroid disorders, inflammatory bowel disease, hepatitis, pericarditis, pulmonary and pleural⁷ involvement have been described. There is often a good response to

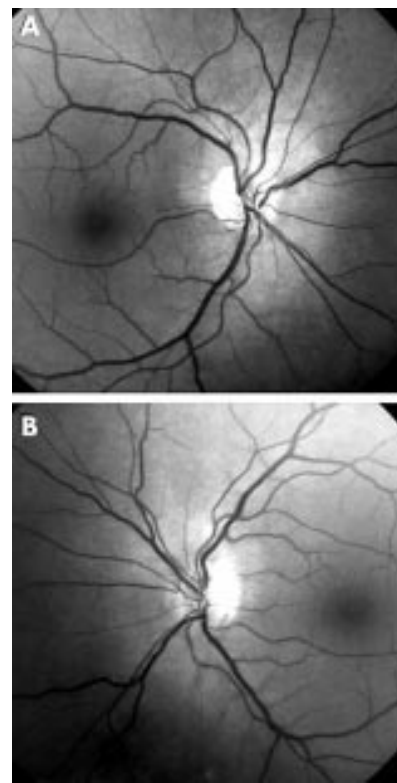


Figure 2 Fundus photographs of case 2 (A) right eye and (B) left eye showing normal optic discs.

corticosteroids with 70% expecting improvement and remission in 15%.

The second case of PION continued to lose vision although she was already on steroids and chemotherapy. Wegener's granulomatosis is a rare multisystem disorder with a necrotising vasculitis which affects the upper respiratory tract and lungs. It may cause a glomerulonephritis and has ocular involvement in 40% of cases; which may be varied including conjunctivitis, episcleritis, scleritis, corneal ulceration, retinal vasculitis, orbital and lacrimal masses.⁸ One series of five patients with Wegener's granulomatosis described vasculitis of the temporal artery and overlapping features of giant cell arteritis with headaches, jaw claudication, and sudden visual loss.⁹ Optic neuropathy is usually related to pressure from an orbital granuloma or sinus disease. In case 2 there was no evidence of this and we felt this was due to retrobulbar vasculitic pathology. This is extremely rare; only two other cases have been reported in the literature.¹⁰ Our patient had rapidly sequential bilateral retrobulbar ischaemic optic neuropathy while she was on chemotherapy and steroids which were started before she had any visual symptoms. In a patient with Wegener's granulomatosis even when there is no evidence of optic nerve or chiasmal compression visual disturbance may herald this rare but devastating manifestation and should be treated aggressively.

B Paul, A M McElvaney

Department of Ophthalmology, St George's Hospital, London, UK

S Agarwal, F E Bruckner

Department of Rheumatology

W Ayliffe

Croydon Eye Unit, Mayday Hospital, Croydon, UK

Correspondence to: Bobby Paul; bpj@aoi.co.uk

Accepted for publication 10 October 2001

Case 2 has been presented as a poster at the Royal Society of Medicine Ophthalmic Trainees Meeting 8 June 2000 as Bilateral sequential retrobulbar optic neuropathy—a devastating complication of Wegener's granulomatosis.

References

- 1 **Jayne RW**, Lockwood CM. Intravenous immunoglobulin as sole therapy for systemic vasculitis. *Br J Rheumatol* 1996;**35**:1150–3.
- 2 **Hayreh SS**. Posterior ischemic optic neuropathy. *Ophthalmologica (Basel)* 1981;**182**:29–41.
- 3 **Hayreh SS**, Podhajsky PA, Zimmerman B. Ocular manifestations of giant cell arteritis. *Am J Ophthalmol* 1998;**125**:509–20.
- 4 **Shulman LE**. Diffuse fasciitis with hypergammaglobulinaemia and eosinophilia: a new syndrome? *J Rheumatol* 1974;**1**(suppl) 46.
- 5 **Maddison PJ**. Eosinophilic fasciitis. *Br J Rheumatol* 1990;**29**:81–2.
- 6 **Brito-Babapulle F**. Patients with eosinophilic fasciitis should have a bone marrow examination to identify myelodysplasia. *Br J Dermatol* 1997;**137**:303–25.
- 7 **Killen JWW**, Switt GL, White RJ. Eosinophilic fasciitis with pulmonary and pleural involvement. *Postgrad Med J* 2000;**76**:36–7.
- 8 **Spalton DJ**, Graham EM, Page NG, et al. Ocular changes in limited forms of Wegener's granulomatosis. *Br J Ophthalmol* 1981;**65**:553–63.
- 9 **Nishino H**, DeRemee RA, Rubino FA, et al. Wegener's granulomatosis associated with vasculitis of the temporal artery: report of five cases. *Mayo Clin Proc* 1993;**68**:115–21.
- 10 **Belden CJ**, Rained LM, Mancuso AA. Bilateral isolated retrobulbar optic neuropathy in limited Wegener's granulomatosis. *J Clin Neuro-Ophthalmol* 1993;**13**:119–23.

MAILBOX

Quantifying corneal endothelial cell death

We read with interest the paper by Gain *et al.*¹ which assessed two distinct techniques to quantify corneal endothelial cell death in donor corneas. A significantly higher rate of cell death was observed with the TUNEL assay, which labels nuclei with fragmented DNA, compared to the trypan blue exclusion method, which detects cells with disrupted cell membranes. The authors conclude that TUNEL analysis is more accurate than trypan blue exclusion as a means of assessing the impact of different corneal storage methods on endothelial viability.

Our experience of using a number of cell death assays to investigate fibroblast apoptosis together with the findings of others^{2,3} supports the notion that trypan blue exclusion is not a good method for detecting apoptosis in vitro. However, we would like to propose that the sequential analysis of the same corneal tissue in this study might account for some of the disparity observed between the two methods. Following initial incubation in trypan blue, buttons were subjected to image analysis as well as cell density measurements after further incubation in 0.9% sodium chloride. After this the buttons were fixed overnight in 10% formaldehyde in preparation for TUNEL. It is possible that the higher rates of death observed by TUNEL reflect the known toxicity of trypan blue, or are a consequence of subsequent manipulation in image analysis and cell density measurement. The low rates of cell death observed by both techniques in non-stored corneas do not negate this possibility

since healthier corneas may be more resistant to the effects of trypan blue and subsequent analysis. Randomisation of the sequence of analysis between the techniques compared would not have been possible, but the authors could have divided the corneas before storage or used paired eyes as separate matched specimens.

The authors argue that the disparity between endothelial cell loss and observed cell death is greater for trypan blue exclusion because loss of membrane integrity occurs relatively late, giving a shorter observational window in which to detect dying cells than TUNEL analysis, which detects apoptosis earlier. But the relatively high percentage of apoptotic cells (12.7%) observed by TUNEL analysis may be an overestimate. Although the time span for apoptosis varies greatly depending on the cell type and nature of the apoptotic trigger, many estimates suggest that the processes is completed in less than 24 hours.⁴ If 12.7% of cells undergo apoptosis at any given time it can be predicted that complete endothelial cell death would occur within 8 days. The actual loss observed over the 22 day incubation period in this study was however only around 14%.

We agree with the authors regarding the need for accurate methods for determining endothelial cell death. No individual assay per se is ideal for both quantifying and determining the mode of cell death and combinations of assays should give a clearer picture of the impact of variations in corneal storage on endothelial viability.

J G Crowston, P R Healey, A Maloof, B Allan

Westmead Hospital, Sydney, Australia

Correspondence to: J G Crowston; jcrowston@lineone.net

References

- 1 **Gain P**, Thuret G, Chiquet C, et al. Value of two mortality assessments techniques for organ cultured corneal endothelium: trypan blue versus TUNEL technique. *Br J Ophthalmol* 2002;**86**:306–10.
- 2 **McCloskey TW**, Chavan S, Lakshmi Tamma, SM, et al. Comparison of seven quantitative assays to assess lymphocyte cell death during HIV infection: measurement of induced apoptosis in anti-Fas-treated Jurkat cells and spontaneous apoptosis in peripheral blood mononuclear cells from children infected with HIV. *AIDS Res Hum Retroviruses* 1998;**14**:1413–22.
- 3 **Crowston JG**, Akbar AN, Constable PH, et al. Antimetabolite-induced apoptosis in Tenon's capsule fibroblasts. *Invest Ophthalmol Vis Sci* 1998;**39**:449–54.
- 4 **Kravtsov VD**, Daniel TO, Koury MJ. Comparative analysis of different methodological approaches to the in vitro study of drug-induced apoptosis. *Am J Pathol* 1999;**155**:1327–39.

Dacryocystorhinostomy for partial nasolacrimal obstruction

We have read with avid interest the article on external dacryocystorhinostomy (DCR) for partial nasolacrimal obstruction (PNLO) in adults.¹ We would like to clarify a few pertinent aspects which are of relevance in understanding this rather complex issue.

Firstly, we are not in consonance with the authors' definition of PNLO, which they define as "a freely patent nasolacrimal system to irrigation with minimum or no reflux from the upper canaliculus or punctum." In our clinical experience and as quoted in the

literature, a patient is usually diagnosed as having PNLO if there is a relative resistance to passage of fluid on irrigation² along with some degree of reflux thorough the opposite punctum.³ So, the use of the term "freely patent" may not be appropriate to describe PNLO.

Secondly, although we agree that most patients with PNLO may eventually require a DCR the importance of giving a thorough trial to less invasive treatments such as forced syringing, stents, balloon dacryoplasty, and silicone intubation before undertaking a DCR in such cases has not been adequately emphasised. It is true that variable results have been reported with these techniques but there are studies which show success rates as high as 73.3% with antegrade balloon dilatation combined with silicone intubation even in cases of complete nasolacrimal obstruction over a 1 year follow up.⁴

We would like to share with the readers our own experience in handling such cases where we routinely use a procedure of dilatation of the nasolacrimal duct with lacrimal probes of progressively increasing diameters, taking care not to damage the puncta. During probing, we augment its effect by employing a technique which we call "reaming" of the nasolacrimal duct, which involves rotating the proximal end of the probe in circles of increasing diameter, which translates into a similar movement of its distal end. This is followed by silicone intubation. This is a safe and simple procedure which gives results comparable to balloon catheter dilatation and can be adopted by centres in the developing world that do not have access to expensive treatments and instrumentation.

M S Bajaj, N Pushker, S Ghose

RP Centre, All India Institute of Medical Sciences, New Delhi, India

Correspondence to: Dr Bajaj; msbajaj32@hotmail.com

Accepted for publication 9 June 2002

References

- 1 **Delaney YM**, Khooshabeh R. External dacryocystorhinostomy for the treatment of acquired partial obstruction in adults. *Br J Ophthalmol* 2002;**86**:533–5.
- 2 **Tucker SM**, Lindberg JV, Nguyen LL, et al. Measurement of the resistance to fluid flow within the lacrimal system. *Ophthalmology* 1995;**102**:1639–45.
- 3 **Perry JD**, Maus M, Nowinski, et al. Balloon catheter dilatation for treatment of adults with partial nasolacrimal duct obstruction: a preliminary report. *Am J Ophthalmol* 1995;**126**:811–16.
- 4 **Kuchar A**, Steinkogler FJ. Antegrade balloon dilatation of nasolacrimal duct obstruction in adults. *Br J Ophthalmol* 2001;**85**:200–4.

NOTICES

Sight Savers International Honoured by American Medical Association Award

Sight Savers International, the UK's leading charity tackling blindness in the developing world, is the 2002 recipient of the Nathan Davis International Award in Medicine and Public Health, awarded by the American Medical Association. This is the first time ever a non-US organisation has received this prestigious Award.

The annual Award, named after the founder of the American Medical Association, honours physicians and health sector organisations

that further health information and medical practice around the world.

The panel of judges made a unanimous decision to award the \$25 000 prize in recognition of Sight Savers' support for the provision of vital eye care services in some of the poorest communities around the world over the last 50 years.

Richard Porter, Executive Director of Sight Savers who received the award in Chicago commented: "We are delighted and honoured to receive the Dr Nathan Davis International Award. Our vision is of a world where no one is needlessly blind and where irreversibly blind people share the same opportunities as everyone. This award recognises the enormous difference which can be made to the lives of people in poor communities through some of the most simple and cost effective treatments available."

Sight Savers is dedicated to combatting avoidable blindness in developing countries. The charity works with partner organisations in poor and under served communities to develop and support healthcare programmes that prevent and cure blindness, and provide services to irreversibly blind people.

Patient care

The latest issue of *Community Eye Health* (No 41) discusses patient care with both ophthalmologists' and patients' views given. For further information please contact: Journal of Community Eye Health, International Centre for Eye Health, Institute of Ophthalmology, 11-43 Bath Street, London EC1V 9EL, UK (tel: +44 (0)20 7608 6910; fax: +44 (0)20 7250 3207; email: eyeresource@ucl.ac.uk; website: www.jceh.co.uk). Annual subscription (4 issues) UK£25/US\$40. Free to workers in developing countries.

International Centre for Eye Health

The International Centre for Eye Health has published a new edition of the *Standard List of Medicines, Equipment, Instruments and Optical Supplies* (2001) for eye care services in developing countries. It is compiled by the Task Force of the International Agency for the Prevention of Blindness. Further details: Sue Stevens, International Centre for Eye Health, 11-43 Bath Street, London EC1V 9EL, UK (tel: +44 (0)20 7608 6910; email: eyeresource@ucl.ac.uk).

Second Sight

Second Sight, a UK based charity whose aims are to eliminate the backlog of cataract blind in India by the year 2020 and to establish strong links between Indian and British ophthalmologists, is regularly sending volunteer surgeons to India. Details can be found at the charity website (www.secondsight.org.uk) or by contacting Dr Lucy Mathen (lucymathen@yahoo.com).

Specific Eye Conditions (SPECS)

Specific Eye Conditions (SPECS) is a not for profit organisation which acts as an umbrella organisation for support groups of any conditions or syndrome with an integral eye disorder. SPECS represents over fifty different organisations related to eye disorders ranging from conditions that are relatively common to very rare syndromes. We also include groups who offer support of a more general nature to visually impaired and blind people. Support groups meet regularly in the Boardroom at Moorfields Eye Hospital to offer support to each other, share experiences and explore new ways of working together. The web site www.eyecconditions.org.uk acts as a portal giving direct access to support groups own sites. The SPECS web page is a valuable resource for professionals and may also be of interest to people with a visual impairment or who are blind. For further details about SPECS contact: Kay Parkinson, SPECS Development Officer (tel: +44 (0)1803 524238; email: k@eyecconditions.org.uk; www.eyecconditions.org.uk).

The British Retinitis Pigmentosa Society

The British Retinitis Pigmentosa Society (BRPS) was formed in 1975 to bring together people with retinitis pigmentosa and their families. The principle aims of BRPS are to raise funds to support the programme of medical research into an eventual cure for this hereditary disease, and through the BRPS welfare service, help members and their families cope with the everyday concerns caused by retinitis pigmentosa. Part of the welfare service is the telephone helpline (+44 (0)1280 860 363), which is a useful resource for any queries or worries relating to the problems retinitis pigmentosa can bring. This service is especially valuable for those recently diagnosed with retinitis pigmentosa, and all calls are taken in the strictest confidence. Many people with retinitis pigmentosa have found the Society helpful, providing encouragement, and support through the Helpline, the welfare network and the BRPS branches throughout the UK. (tel: +44 (0)1280 821 334; email: lynda@brps.demon.co.uk; web site: www.brps.demon.co.uk)

Ophthalmic Anesthesia Society (OAS) 16th Scientific Meeting

The 16th Scientific Meeting of the OAS will be held on 4-6 October 2002 in The Westin, Michigan Avenue, 909 North Michigan Avenue, Chicago, USA (reservations +1 800 228 3000). Further details: OAS, 793-A Foothill Blvd, PMB 110, San Luis Obispo, CA 93405, USA (tel: +1 805 771 8300; web site: www.eyeanesthesia.org).

BEAVRS Meeting

The next BEAVRS meeting will be held in the Dalmahoy Hotel near Edinburgh on 31 October to 1 November 2002. Further details: Susan Campbell, Medical Secretary, Gartnavel General Hospital (email: susan.j.campbell.wg@northglasgow.scot.nhs.uk).

Cornea 2002—Celebrating 50 Years of Eyebanking

The Cornea 2002 meeting will be held in Le Meridien Hotel, London, Gatwick on 14-15 November 2002. Subjects to be covered will include eye banking, penetrating and lamellar keratoplasty, stem cell restoration, keratoprosthesis, advanced keratoplasty techniques, paediatric cornea, keratorefractive surgery, and intraocular refractive surgery. Spaces are limited and a beneficial package rate is available prior to 30 September 2002. Further details: CORNEA 2002 organiser at the Corneo Plastic Unit, The Queen Victoria Hospital, Holtye Road, East Grinstead, West Sussex, RH19 3DZ, UK (tel: 01342 410 210 ext 560; fax: 01342 317 181; email: Cornea2002@hotmail.com).

Introductory Course in Osteo-odonto-keratoprosthesis (OOKP)

The University of Brighton Postgraduate Medical School is holding an introductory course in osteo-odonto-keratoprosthesis (OOKP) on the 20-21 November 2002 in the New Seminar Room, Sussex House, Brighton & Sussex University Hospitals Trust in Brighton. The course will comprise of a variety of lectures with live surgery, two way audio and video links (Stage 1 and Stage 2 OOKP surgery), and examination of patients. Further details: Mrs Erica Strange, University of Brighton, Postgraduate Medical School, Falmer Campus, Brighton, East Sussex BN1 9PH, UK (tel: +44 (0)1273 644 005; fax: +44 (0)1273 644 002; email: e.strange@brighton.ac.uk).

23rd Annual Conference and Dinner Glaucoma Society (UK & EIRE)

The 23rd Annual Conference and Dinner of the Glaucoma Society will be held on Thursday 21 November 2002, 8.30am to 5.00pm at the Central Conference Centre, London. The Annual Dinner is from 6.30pm to 10.00pm at The Royal College of Surgeons, London. Conference charges: £60 members; £80 non-members. Price entitles delegates to refreshments, lunch, abstract book, programme, and annual dinner. (Maximum number of places 250—apply now to secure your place). Further details: Janet Flowers, Administrator, 29 Quarry Hill, Grays, Essex, RM17 5BT, UK (tel/fax: 01375 383172; email: glausoc@ukeire.freeserve.co.uk).



Dacryocystorhinostomy for partial nasolacrimal obstruction

M S Bajaj, N Pushker and S Ghose

Br J Ophthalmol 2002 86: 1068
doi: 10.1136/bjo.86.9.1068-a

Updated information and services can be found at:
<http://bjo.bmj.com/content/86/9/1068.2.full.html>

These include:

References

This article cites 4 articles, 2 of which can be accessed free at:
<http://bjo.bmj.com/content/86/9/1068.2.full.html#ref-list-1>

Email alerting service

Receive free email alerts when new articles cite this article. Sign up in the box at the top right corner of the online article.

Notes

To request permissions go to:
<http://group.bmj.com/group/rights-licensing/permissions>

To order reprints go to:
<http://journals.bmj.com/cgi/reprintform>

To subscribe to BMJ go to:
<http://group.bmj.com/subscribe/>