

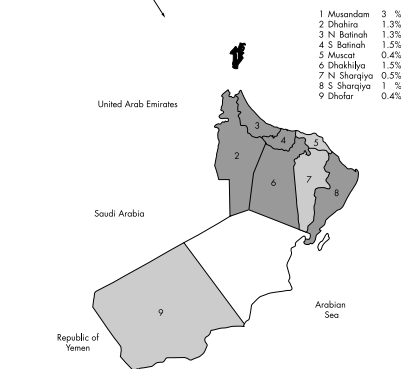
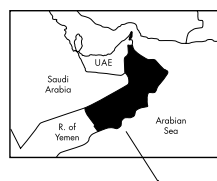BJO at a glance

Creig Hoyt, Editor

SHOULD WE CONTINUE USING SURGICAL FACEMASKS?

Eight years ago shoe coverings for the operating rooms at the University of California San Francisco, where I work, were removed from the operating rooms after a large study showed that wearing shoe covers during surgery had no effect on the postoperative infection rate. Many older surgeons at our hospital still find it difficult to enter the operating room without shoe covers despite the evidence of their ineffectiveness. Alwitary *et al* ask the question whether surgical facemasks are necessary during cataract surgery. In a relatively small investigation of 221 patients the authors studied bacterial growth on blood agar settle plates adjacent to the patient's head during cataract surgery. They documented that there were significantly fewer organisms cultured when the surgeon used a facemask. Since there were no cases of infectious complications they were unable to address the problem of whether or not this increase in organisms detected in cases where the surgeon did not wear a surgical facemask has any clinical significance. Nevertheless, the authors suggest that continued use of surgical facemasks is recommended in light of the clear difference in bacterial growth detected in the two study groups.

See p 975



See p 957

www.bjophthmol.com

SYSTEMIC ANTIMETABOLITE THERAPY IN HIGH RISK CORNEAL GRAFTING

Corneal grafting techniques continue to improve. The overall success rate of corneal grafting is high. Nevertheless, a small but significant percentage of patients undergoing corneal transplantation suffer serious rejection phenomena. Rumelt and coworkers address the question whether oral cyclosporin A is useful in the prevention and treatment of immune graft rejection in heavily vascularised repeated keratoplasties. In this study of 21 consecutive patients with 28 repeated corneal transplantations the use of systemic cyclosporin A appeared to have a limited beneficial effect in preventing immune graft rejection. The authors conclude that when immune graft rejections occur in these high failure risk grafts the prognosis is poor despite aggressive medical treatment. They also stress that causes other than immune graft rejection may be responsible for the poor visual outcome in some of these patients. Corneal grafting in high risk corneas remains a surgical and medical challenge. We need to identify the factors that increase the risk of failure and devise appropriate treatments to counteract them.

See p 988

BENEFITS OF SCREENING FOR RETINAL MICROVASCULAR CHANGES IN A HYPERTENSIVE POPULATION

Medical students everywhere are taught the importance of ophthalmoscopic examination of the retina in patients with hypertension. Retinal microvascular anomalies such as focal and generalised arteriolar narrowing, arteriovenous nicking, and retinopathy are known to be associated with clinically significant hypertension. Nevertheless, these changes are relatively common in an adult population. Wong and coworkers studied that clinical significance of retinal microvascular abnormalities in a large group of patients. They found in non-diabetic patients that an elevated concurrent blood pressure taken at the time of retinal photography was strongly associated with the presence of any retinal microvascular lesion. They also emphasised that generalised retinal arteriolar narrowing and perhaps arteriovenous nicking may be related to previous elevated blood pressure. In a separate study Wong evaluated 560 hypertensive, hyperlipidaemic middle aged men enrolled in the Lipid Research Clinics Coronary Primary Prevention Trial. In this study hypertensive retinopathy was a strong predictor of coronary heart disease. After adjusting for other risk factors the presence of either generalised or focal arteriolar narrowing predicted almost a tripling of the risk of coronary heart disease. There appear to be obvious benefits to the continued routine ophthalmoscopic examination for signs of hypertensive retinopathy in at-risk groups.

See pp 1002 and 1007

CATARACTS: STILL THE SAME OLD PROBLEM

One can argue that no surgical procedure in medicine is more effective in re-establishing near normal function than cataract surgery and intraocular lens implantation. Despite this fact cataract remains a major cause of blindness worldwide. Goh and coworkers report the findings of a national eye survey in Malaysia. There was no significant difference in the prevalence of poor vision and blindness among the four ethnic groups studied and urban versus rural residents. Regrettably, however, cataracts were the leading cause of blindness in this study (39%). Khandekar and coworkers report the findings of a similar study of blindness carried out in the Sultanate of Oman. In this study there was a significant difference in the prevalence of blindness between the northern and central regions of the country. However, the major finding was that the unoperated cataract was the leading cause of blindness in the Sultanate of Oman (30.5%). These two studies emphasise the need for continued commitment of ophthalmologists throughout the world to address the problem of the large number of patients with visually significant unoperated cataracts.

See pp 951 and 957



BJO at a glance

Creig Hoyt

Br J Ophthalmol 2002 86: 945
doi: 10.1136/bjo.86.9.945-a

Updated information and services can be found at:
<http://bjo.bmj.com/content/86/9/945.2.full.html>

	<i>These include:</i>
References	Article cited in: http://bjo.bmj.com/content/86/9/945.2.full.html#related-urls
Email alerting service	Receive free email alerts when new articles cite this article. Sign up in the box at the top right corner of the online article.

Notes

To request permissions go to:
<http://group.bmj.com/group/rights-licensing/permissions>

To order reprints go to:
<http://journals.bmj.com/cgi/reprintform>

To subscribe to BMJ go to:
<http://group.bmj.com/subscribe/>