

PostScript

LETTERS

If you have a burning desire to respond to a paper published in the *BJO*, why not make use of our "rapid response" option?

Log on to our website (www.bjophthol.com), find the paper that interests you, and send your response via email by clicking on the "eletters" option in the box at the top right hand corner.

Providing it isn't libellous or obscene, it will be posted within seven days. You can retrieve it by clicking on "read eletters" on our homepage.

The editors will decide as before whether to also publish it in a future paper issue.

Eyelid skin adenoid cystic carcinoma: a clinicopathological study of one case simulating sebaceous gland carcinoma

Adenoid cystic carcinoma is a rare subtype of sweat gland carcinoma.¹ In the eyelid, it can arise from the glands of Moll, the palpebral lobe of the lacrimal gland, the accessory lacrimal glands in conjunctiva, or from ectopic lacrimal gland tissue.¹ We present a rare case of adenoid cystic carcinoma arising from the skin of the eyelid with features simulating the more commonly seen sebaceous gland carcinoma.

Case report

A 57 year old man presented with a lesion in the right inferior lid. He reported a slow growth during the past 10 years. The examination revealed a firm tumour occupying the lateral two thirds of the right inferior lid. There was a loss of cilia but no ulceration of the skin or conjunctiva over the lesion (Fig 1). The remainder of the examination was normal. The clinical impression was sebaceous gland carcinoma and excision with clear margins was carried out.

Histopathologically, the lesion revealed solid nests of basaloid cells associated with numerous cystic spaces containing Alcian blue positive material and scant fibrous stroma. The neoplastic process seems to originate from an area of normal sweat glands of the lid skin. In some areas, the cells assumed a strand-like configuration forming glandular duct-like spaces (Fig 1). There was no continuity to the epidermis, hair sheaths, or conjunctiva, indicating origin of the tumour from skin sweat glands. The surgical margins were free of tumour. The final diagnosis was adenoid cystic carcinoma. After 18 months, no local recurrence or distant metastasis were noted.

Comment

The present case revealed clinical features commonly seen in association with eyelid sebaceous gland carcinoma. These included loss of cilia and a large slowly growing mass. It thus emphasises the need for including adenoid cystic carcinoma in the differential diagnosis of eyelid malignant tumours, albeit such tumours are rare.

In a review of the literature on eyelid tumours, at least three previous reports of

adenoid cystic carcinoma can be found²⁻³; however, in two such reports no definite conclusion about the origin of the tumour is offered.^{1,2} In the case reported by Mencia-Gutiérrez *et al*, the tumour appears to be primarily of the skin.³

Fewer than 50 cases of adenoid cystic carcinoma primarily of the skin have been reported.³ Its most common differential diagnosis is the adenoid basal cell carcinoma. While both lesions have an infiltrative growth pattern and share many histological features, like the tendency to invade perivascular and perineural spaces, some aspects can help to differentiate them. Adenoid cystic carcinoma presents lack of retraction artefact, absence of contiguity with the epidermis or hair sheaths, lack of peripheral palisading of the nuclei, and occasional presence of central apoptotic or even necrotic cells. In the rare instances when haematoxylin and eosin stained sections are not sufficient to differentiate the two lesions, adenoid cystic carcinoma pseudocysts stain positively to Alcian blue and periodic acid-Schiff (PAS). The tumour also shows positive immunostaining with EMA (epithelial membrane antigen), amylase, S100 protein, and carcinoembryonic antigen.^{1,4-6}

Adenoid cystic carcinoma of the eyelid skin is a tumour of middle aged adults, present for a long period before the patient seeks medical attention. Unlike most of the sweat gland carcinomas, it tends to recur locally and rarely spreads to lymph nodes or distant organs.⁴⁻⁶ Thus, local resection with verification of the margins is the recommended treatment and regional lymph nodes resection seems not to be necessary.⁴ When complete excision is not possible radiotherapy and chemotherapy have been employed as adjuvant or palliative treatment.⁷

E F Marback, A L Costa, L M B Nossa, R L Marback

Ophthalmology Clinic, Federal University of Bahia, Bahia, Brazil

E F Marback, N A Rao

Doheny Eye Institute, University of Southern California, Los Angeles, CA, USA

Correspondence to: Roberto L Marback, MD, Av Garibaldi 1987, 3 andar, Salvador, Bahia, Brazil, Cep 40210-070; robertomarback@uol.com.br

Accepted for publication 29 November 2001

References

- Font RL. Eyelid and lacrimal drainage system. In: Spencer WH, ed. *Ophthalmic pathology: an atlas and textbook*. 4th ed. Philadelphia: WB Saunders, 1996:2307-8.
- Kersten RC, Ewing-Chow D, Kulwin DR, *et al*. Accuracy of clinical diagnosis of cutaneous eyelid lesions. *Ophthalmology* 1997;104:479-84.
- Mencia-Gutiérrez E, Guttierrez-Diaz E, Santos-Briz A, *et al*. Primary cutaneous adenoid cystic carcinoma of the eyelid. *Am J Ophthalmol* 2001;131:281-3.
- Cooper HC. Carcinomas of sweat glands. *Pathol Annu* 1987;22:83-124.
- Murphy GF, Elder DE. *Non-melanocytic tumors of the skin. Atlas of tumor pathology*. 3rd series. Fascicle 1. Washington DC: Armed Forces Institute of Pathology, 1991:105.
- Wick MR, Swanson PE, Barnhill RL. Sweat gland tumors. In: Barnhill RL, ed. *Textbook of dermatopathology*. New York: McGraw-Hill, 1998:637.

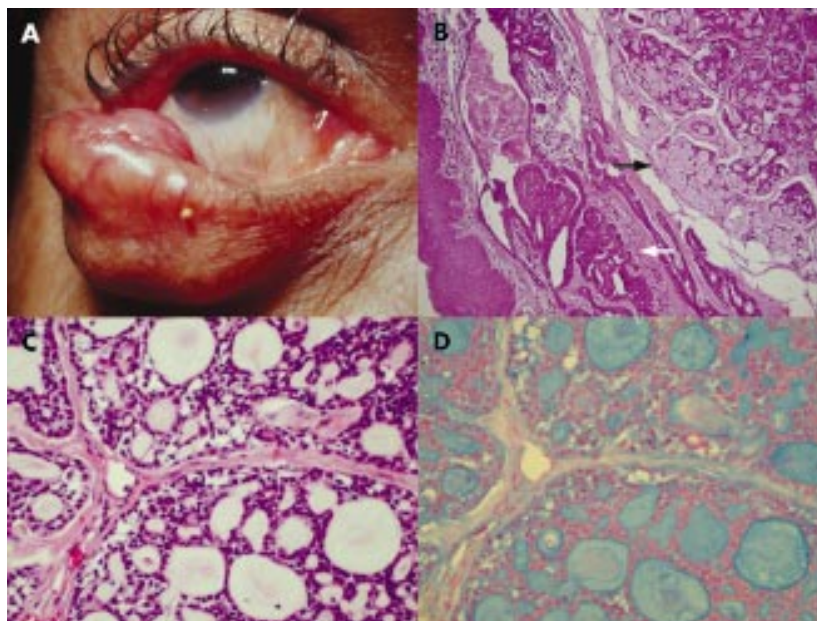


Figure 1 (A) Clinically, the lesion occupied the lateral two thirds of the inferior lid with loss of the cilia in the involved area. (B) Histologically the tumour (black arrow) seems to be continuous with normal sweat glands of the skin (white arrow) (haematoxylin and eosin, $\times 40$). (C) At higher magnification showing the characteristic cystic-like spaces (haematoxylin and eosin, $\times 200$). (D) Same area showing positive staining for Alcian blue (Alcian blue $\times 200$).

7 Kato N, Yasukawa K, Onozuka T. Primary cutaneous adenoid cystic carcinoma with lymph node metastasis. *Am J Dermatopathol* 1998;20:571-7.

Congenital trichomegaly (Oliver-McFarlane syndrome): a case report with 9 years' follow up

In 1965 Oliver and McFarlane¹ reported on the association of long eyelashes, pigmentary degeneration of the retina, and mental and growth retardation in an isolated case of a male child. The syndrome was called "congenital trichomegaly." Only six cases, four children and two adults, have been described since then.²⁻⁶ The present report describes the eighth case of Oliver-McFarlane syndrome and documents a 9 year follow up.

Case report

A 5½ year old boy presented with progressive visual deterioration in both eyes. Visual problems had become apparent from the second year of age. He was delivered at term without complications weighing 2220 g. Physical examination revealed a weight of 14 kg, a height of 102 cm, and a head circumference of 49 cm. Bone age studies (x ray of the hand) indicated a retardation in bone development with skeletal age of approximately 3 years. His genitals were small, his testes were palpable and descended. The scalp hair was sparse, very fine with a whitish aspect (Fig 1A). His eyelashes were very long and curled upwards

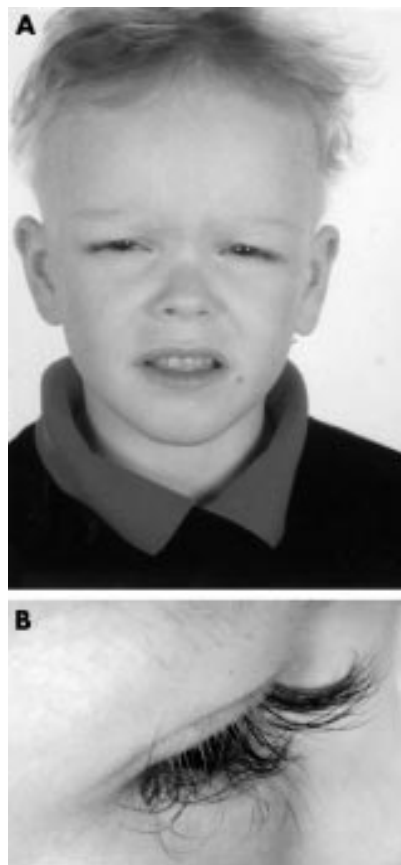


Figure 1 The patient at 5½ years of age. Note the fine, whitish, and sparse scalp hair (A). The eyelashes are long and curled upwards (trichomegaly) (B).

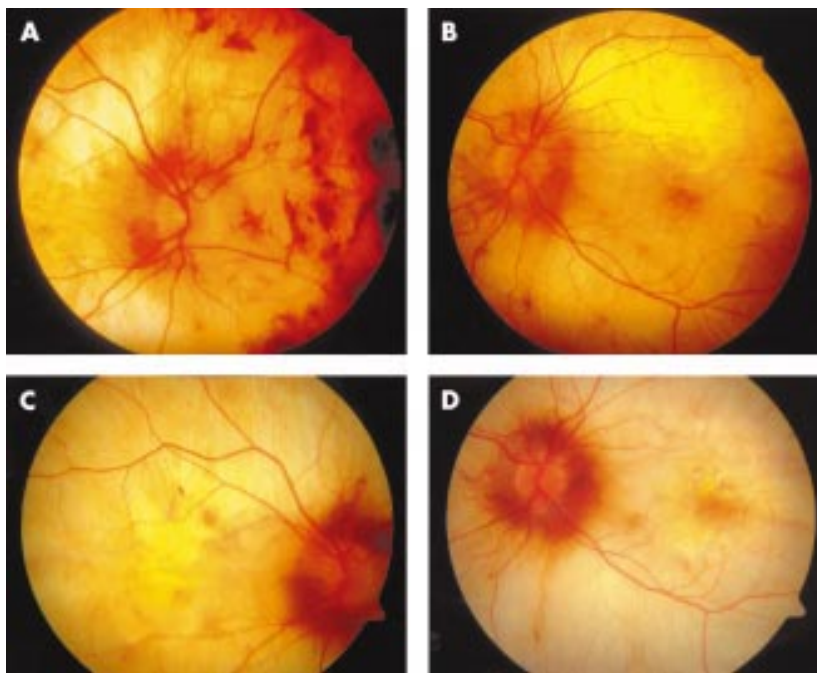


Figure 2 Chorioretinal degeneration with aggregation of the retinal pigment epithelium on both eyes at the age of 5½ years (A, B). Nine years later, a progression of the chorioretinal degeneration was observed (C, D).

(Fig 1B). A neurological examination showed discrete signs of ataxia, coordination was normal, myotonus was regular, and tendon reflexes were not present. IQ testing revealed an IQ of 97. Magnetic resonance imaging (MRI) of the brain disclosed no pathology.

A complete blood cell count and urinalysis including amino acids screening assay was normal. The urine sediments showed no signs of cytomegalic inclusion cysts. Serological tests for syphilis, hepatitis, German measles, mumps, herpes simplex, cytomegalovirus, mycoplasma, and toxoplasma were unremarkable.

Visual acuity was 20/400 in the right eye and 20/100 in the left at initial presentation. Cycloplegic retinoscopy revealed refractive errors of -7.0 in both eyes. Slit lamp examination was unremarkable, pupils were equal and reacted to direct and consensual stimulation. Intraocular pressures were normal. Fundus examination revealed a marked atrophy of the choriocapillaris. The fundus appeared pale due to depigmentation. There were plaques of pigment distributed in the mid-periphery. No aggregates of pigment were noted in the posterior pole and the macular area (Fig 2A, B).

Nine years later, at the age of 15, the boy was re-examined in our clinic. Best corrected visual acuity had decreased to hand movement at 30 cm in the right eye and 20/200 in the left. Objective refraction using an automated refractor revealed a refractive error of -15.25/-1.25/97° in the right eye and -14.00/-1.75/144° in the left. On fundus examination a progression of the bilateral chorioretinal degeneration was observed (Fig 2C, D). The discs were of normal colour and contour. Although the boy received testosterone therapy he did not develop secondary sexual characteristics according to his age. There was a marked retardation in body height. His gait was ataxic and coordination severely affected. Furthermore, the boy appeared to be mentally retarded. Cytogenetic analysis showed a karyotype without abnormalities.

Comment

Oliver-McFarlane syndrome is an extremely rare condition associated with chorioretinal degeneration, dwarfism with growth hormone deficiency, hair abnormalities, and cerebellar dysfunction.⁷ To our knowledge, this is the eighth case since the first report by Oliver and McFarlane in 1965.¹ The chorioretinal degeneration documented in our patient was similar to previous reports.¹⁻⁶ Neurological findings such as ataxia and coordination problems could be correlated with cerebellar abnormalities during the long term follow up of the patient initially described by Oliver and McFarlane.⁷ As ataxia progressed during follow up, cerebellar dysfunction as reported by Chang *et al*⁷ is very suggestive in our patient, too. However, as the parents refused further imaging of the brain, a definite cerebellar abnormality could not be shown. Peripheral neuropathy as present in our patient, was seen in three previous cases.^{1,2,6-8}

All reported cases appear to be sporadic. As only a very limited number of patients are documented, the genetics of this syndrome remain unclear. There is no known associated chromosomal defect or pattern of inheritance. Delleman and Van Walbeek⁴ suggested a partial trisomy 13. However, the karyotype of our patient showed no abnormalities.

C Haritoglou, G Rudolph, P Kalpadakis, K P Boergen

Department of Ophthalmology, Ludwig-Maximilians-University, Mathildenstrasse 8, 80336 Munich, Germany

Correspondence to: Christos Haritoglou, MD; Christos.Haritoglou@ak-i.med.uni-muenchen.de

Accepted for publication 29 June 2002

References

- 1 Oliver GL, McFarlane DC. Congenital trichomegaly with associated pigmentary degeneration of the retina, dwarfism, and mental retardation. *Arch Ophthalmol* 1965;74:169.

- 2 **Cant JS**. Ectodermal dysplasia. *J Pediatr Ophthalmol* 1967;**4**:13–17.
- 3 **Corby DG**, Lowe RS, Haskins RG, *et al*. Trichomegaly, pigmentary degeneration of the retina, and growth retardation. *Am J Dis Child* 1971;**121**:344–5.
- 4 **Delleman JW**, Van Walbeek K. The syndrome of trichomegaly, tapetoretinal degeneration and growth disturbances. *Ophthalmologica* 1975;**171**:313–15.
- 5 **Zaun H**, Stenger D, Zabransky S, *et al*. Das Syndrom der langen Wimpern ("Trichomegaliesyndrom" Oliver McFarlane). *Hautarzt* 1984;**35**:162–5.
- 6 **Patton MA**, Harding AE, Baraitser M. Congenital trichomegaly, pigmentary retinal degeneration, and short stature. *Am J Ophthalmol* 1986;**101**:490–1.
- 7 **Chang TS**, McFarlane DC, Oliver G, *et al*. Congenital trichomegaly, pigmentary degeneration of the retina and growth retardation (Oliver McFarlane syndrome): 28-year follow-up of the first reported case. *Can J Ophthalmol* 28:191–3.
- 8 **Sampson JR**, Tolmie JL, Cant JS. Oliver McFarlane syndrome: a 25-year follow-up. *Am J Med Genet* 1989;**34**:199–201.

Acute keratoconus with perforation in a patient with Down's syndrome

Down's syndrome has been reported to be frequently associated with keratoconus, a chronic non-inflammatory corneal disorder leading to scarring and progressive stromal thinning. An incidence of up to 15% in patients with Down's syndrome was reported in the literature.¹ Acute keratoconus or "corneal hydrops" is a frequent feature in these patients leading to a further decrease in visual acuity and a mostly central corneal opacification.² The spontaneous appearance of a fistula in the acute hydrops state in keratoconus has very rarely been observed. We describe both the clinical and histopathological findings in a patient with Down's syndrome with acute keratoconus who underwent penetrating keratoplasty following a spontaneous corneal perforation.

Case report

We report on a 59 year old female patient with Down's syndrome and late stage keratoconus who was referred to our clinic with a 1 day history of corneal hydrops on her left eye. On initial slit lamp examination a marked oedema of the central corneal stroma was apparent with vesicles and bullae in the corneal epithelium and stroma. The lens was cataractous. Visual acuity could not be assessed because of profound mental retardation. Diabetes mellitus had been diagnosed

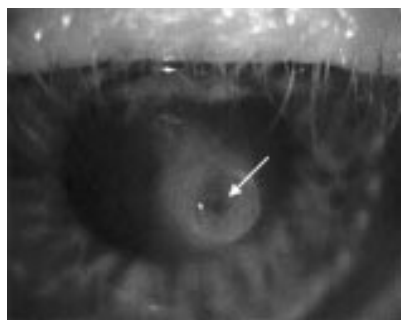


Figure 1 Slit lamp appearance of the cornea, showing an acute hydrops with epithelial defect, perforation with leakage (arrow). Shallow anterior chamber.

several years ago and was treated by oral anti-diabetics. Initial treatment consisted of anti-biotic ointment, cycloplegics, and pressure patching.

Three days later the patient returned with a shallow anterior chamber, an epithelial defect and a perforation with aqueous humour leakage in the centre of the corneal swelling. Fibrin was present in the anterior chamber (Fig 1).

Systemic antibiotic treatment was started following admission and a keratoplasty à chaud was planned for the next day. After another 24 hours of pressure patching the anterior chamber had reformed and the outer segment of the fistula was closed. The central part of the cornea had a "nipple-like" aspect. A triple procedure was successfully performed using a 8.25 mm diameter corneal transplant, which had been stored in 31°C organ culture medium. The graft was secured with 24 10-0 nylon interrupted sutures. An extracapsular cataract extraction was performed followed by implantation of an PMMA intraocular lens in the capsular bag. The postoperative period was uneventful. At the 6 month follow up the corneal graft was clear and the intraocular lens well placed. Light microscopy of the excised corneal button revealed features that are regularly found in advanced keratoconus: corneal thinning, "downgrowth" of epithelium in the corneal stroma, breaks and fragmentation of Bowman's membrane. The cross section displayed a complete fistula, covered by a fibrin-like plug on its outer opening. The surface of the hydrops displayed no corneal epithelium (Fig 2).

Comment

Corneal hydrops in pre-existing keratoconus is generally caused by the rupture of Descemet's membrane, followed by an influx of aqueous humour into the weakened corneal stroma that leads to a marked oedema and the formation of cystic spaces. If sufficiently severe, this process may under rare circumstances lead to a complete fistula with leakage of aqueous humour. Very few cases with a spontaneous corneal perforation in acute keratoconus have been reported in the literature.^{3–8} Three of the patients also suffered from Down's syndrome. Pierser described the history of a 17 year old boy, who was discovered to have a spontaneously sealed corneal perforation 6 weeks after the onset of acute keratoconus.² Perforation in a 20 year old female and an 18 year old male patient with corneal hydrops were reported by McElvanney.⁹ All three patients received a penetrating keratoplasty, with only one of the grafts remaining clear in the long term follow up. Penetrating keratoplasty was also clearly indicated in this reported case of perforation.

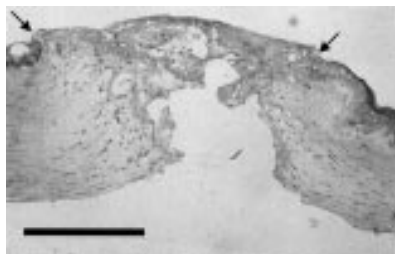


Figure 2 Cross section of the corneal button showing the area of the fistula. Discontinuity of the corneal epithelium (arrows) (azure-11-methylene blue basic fuchsin). Bar = 0.5 mm.

In general, corneal grafting will be considered in patients with Down's syndrome and acute keratoconus but, when compared to patients without mental retardation, a much higher complication rate owing to the lack of cooperation has to be taken into consideration.

To the best of our knowledge this is the first report to also present histopathological findings of a fistula following corneal hydrops in keratoconus. Habitual eye rubbing, which is frequently observed in patients with Down's syndrome and other forms of mental deficiency, has been postulated as an important factor not only for the development of keratoconus itself but also for the progression to the acute condition of the disease.² As diabetes mellitus is also known to have significant effects on the morphological, metabolic, and physiological aspects of the cornea,¹⁰ the coincidence in this particular case may have had an additional detrimental role in the development of this potentially disastrous complication.

J Stoiber

Department of Ophthalmology and Optometry, St Johanns-Spital, Landeskliniken Salzburg, Muellner Hauptstrasse 48, A 5020 Salzburg, Austria

W Muss

Department of Pathology

J Ruckhofer, G Grabner

Department of Ophthalmology and Optometry

Correspondence to: Dr Josef Stoiber; j.stoiber@lks.at

Accepted for publication 16 July 2002

References

- 1 **Rabinowitz YS**. Keratoconus. *Surv Ophthalmol* 1998;**42**:297–319.
- 2 **Pierser D**, Eustace P. Acute keratoconus in mongols. *Br J Ophthalmol* 1971;**55**:50–54.
- 3 **Ingraham HJ**, Donnenfeld ED, Perry HD. Keratoconus with spontaneous perforation of the cornea. *Arch Ophthalmol* 1991;**109**:1651–1652.
- 4 **Reis A**, Reinhard T, Sundmacher R. Spontane Fistulation bei akutem Keratokonus. *Spektrum Augenheilkd* 1998;**12**:197–198.
- 5 **Musco PS**, Aquavella JV. Corneal fistula. *Ophthalmic Surg* 1987;**18**:574–576.
- 6 **Lahoud S**, Brownstein S, LaFlamme MY, *et al*. Keratoconus with spontaneous perforation of the cornea. *Can J Ophthalmol* 1987;**22**:230–233.
- 7 **Grewal S**, Laibson PR, Cohen EJ, *et al*. Acute hydrops in the corneal ectasias: associated factors and outcomes. *Trans Am Ophthalmol Soc* 1999;**97**:187–203.
- 8 **Rubsamen PE**, McLeish WM. Keratoconus with acute hydrops and perforation. *Cornea* 1991;**10**:83–84.
- 9 **McElvanney AM**, Adhikary HP. Penetrating keratoplasty in the mentally retarded. *Eye* 1997;**11**:786–9.
- 10 **Sanchez-Thorin JC**. The cornea in diabetes mellitus. *Int Ophthalmol Clin* 1998;**38**:19–36.

Adult orbital xanthogranuloma with periosteal infiltration

A case of orbital xanthogranuloma is presented. The radiological and clinicopathological feature of diffuse periosteal infiltration, to the authors' knowledge, has never previously been reported.

Case report

A 64 year old woman was referred to the orbital clinic with a 2 year history of bilateral yellow cutaneous lesions on the upper and lower eyelids. She was otherwise well, under

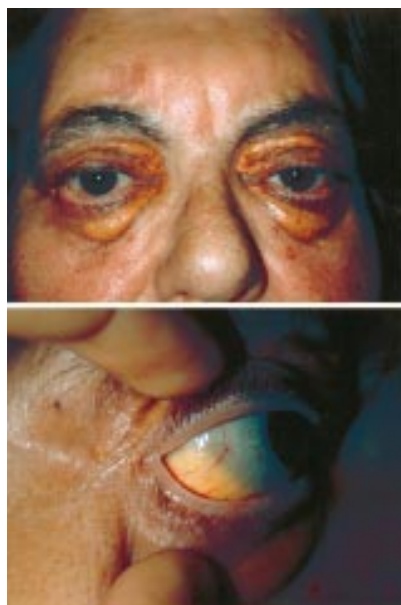

Figure 1 Bilateral upper and lower lid cutaneous lesions and yellow episcleral infiltrates.

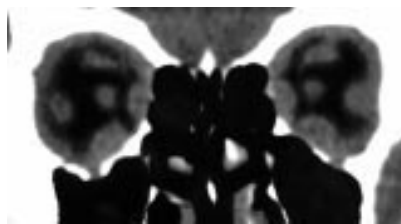

Figure 2 Coronal view of orbital CT scan demonstrating bilateral extraocular muscle enlargement and diffuse periosteal infiltration.

regular haematological review for a monoclonal gammopathy of uncertain significance. Examination revealed firm subcutaneous masses underlying the skin lesions, bilateral yellow episcleral infiltrates inferotemporally, and 2 mm bilateral proptosis (Hertel readings 24 mm each eye at 110 mm) (Fig 1). Eye movements were full, and the remaining ocular and systemic examinations were unremarkable. Investigations carried out by her haematologist included a bone scan, electrocardiogram, and liver and renal function tests, all of which were normal. Orbital computerised tomography (CT) demonstrated bilateral extraocular muscle enlargement and periosteal infiltration involving the entire orbit, from the orbital margin to the apices. (Fig 2) Biopsies of the skin, episcleral, and periosteal lesions all confirmed xanthogranuloma with S100 negative, CD68 positive foamy histiocytes, and Touton giant cells. The collagenous stroma showed no foci of necrosis and Langerhans cells were not seen. Electron microscopy was not performed.

The patient has been observed for 12 months, and remains asymptomatic, with no change in the clinical findings.

Comment

Adult xanthogranulomatous disease is defined histopathologically, by S100 negative foamy histiocytes and Touton giant cells. Categories, based on systemic and histopathological findings, include adult onset xan-

thogranuloma, adult onset asthma with periocular xanthogranuloma, necrobiotic xanthogranuloma (NBX), and Erdheim-Chester Disease (ECD).¹ They may also be classified as a form of non-Langerhans cell histiocytosis, involving soft tissues of the orbit rather than bone (bony involvement being a major feature of Langerhans cell histiocytosis).²

Miszkiel *et al*³ reported the radiological and clinicopathological features of orbital xanthogranuloma to include cutaneous periocular lesions and proptosis, largely due to an infiltrating soft tissue orbital mass. Local orbital involvement includes enlargement and infiltration of extraocular muscles, lacrimal gland, retrobulbar fat, and encasement of the optic nerve. Orbital involvement in ECD is rare, and usually bilateral.^{4,5} Local orbital bone destruction has been reported in juvenile xanthogranuloma.^{6,7}

To the authors' knowledge, the presence of diffuse periosteal infiltration, confirmed histologically to be xanthogranuloma in the above case, has never previously been reported.

There were no features of bony destruction, and the patient did not have any systemic involvement suggestive of ECD, confirmed by the normal investigations carried out by her haematologist. Necrosis of collagenous stroma, diagnostic of NBX, was also not seen histologically.

The prognostic importance of diffuse periosteal infiltration remains unknown, as our patient has no functional symptoms due to xanthogranuloma, or the monoclonal gammopathy, for which she remains under haematological review.

R Malhotra, R G B Porter, D Selva

Oculoplastic and Orbital Unit, Department of Ophthalmology, Royal Adelaide Hospital, North Terrace, Adelaide, SA 5000, Australia
Correspondence to: Dinesh Selva

Accepted for publication 25 July 2002

References

- 1 **Sivak-Calcott J.** Xanthogranulomatous disorders of the orbit. Review presentation at The Vancouver Orbital Symposium, Vancouver, Canada, 15–17 March 2002.
- 2 **Netland P,** Font RL, Jacobiec FA. Orbital histiocytic disorders. In: Albert DM, Jacobiec FA, eds. *Principles and practice of ophthalmology*. Philadelphia: WB Saunders, 1996. (CD Rom) Chapter 179.
- 3 **Miszkiel KA,** Sohaib SAA, Rose GE, *et al.* Radiological and clinicopathological features of orbital xanthogranuloma. *Br J Ophthalmol* 2000;**84**:251–8.
- 4 **Bancroft LW,** Berquist TH. Erdheim-Chester disease: radiographic findings in five patients. *Skeletal Radiol* 1998;**27**:127–32
- 5 **Shields JA,** Karcioglu ZA, Shields CA, *et al.* Orbital and eyelid involvement with Erdheim-Chester Disease. *Arch Ophthalmol* 1991;**109**:850–4.
- 6 **Sanders TE.** Infantile xanthogranuloma of the orbit. A report of three cases. *Am J Ophthalmol* 1966;**61**:1299–306.
- 7 **Gaynes PM,** Cohen GS. Juvenile xanthogranuloma of the orbit. *Am J Ophthalmol* 1967;**63**:755–7.

Tacrolimus

Tacrolimus (FK506) is a highly immunosuppressive agent, in particular tacrolimus inhibits the formation of cytotoxic lymphocytes which are mainly responsible for graft rejection. We report only the second case of bilateral optic neuropathy associated with tacrolimus.

Case report

A 38 year old man with cystic fibrosis underwent pancreatic transplantation in 1999. He had been taking 4 mg of tacrolimus twice daily since his transplantation, and had never previously taken cyclosporin because of renal impairment.

He had previously complained of gradual deterioration in vision of over 6 months duration, at which time he had been seen at another centre where visual acuity was noted to be 6/36 improving to 6/24 with pinhole bilaterally. Six months later during an admission for a chest infection, he had noted a further painless deterioration in both eyes over several days. There was no associated pain on eye movements, headache, diplopia, or any other neurological or ophthalmic complaint. He had never smoked and did not drink alcohol. In addition to tacrolimus he was taking amoxicillin 500 mg three times daily, vitamin A injections, prednisolone 10 mg daily, and ranitidine 150 mg twice daily. An ophthalmic referral was made.

On examination he was thin and pale, best corrected Snellen visual acuity were 3/60 right eye and 2/60 left eye, refraction was + 1.00 DS and + 0.75 DS respectively. Goldmann visual fields showed generalised depression of sensitivity, with no focal defects. Both pupils reacted sluggishly to light, there was no relative afferent pupillary defect. Motility, intraocular pressure, and anterior segment examination were normal.

Dilated fundal examination showed bilateral generalised optic disc pallor, cup:disc ratio of 0.3 bilaterally. Retinal vessels were mildly attenuated bilaterally. There were no retinal haemorrhages, or infiltrates, and there was no vitreous activity.

Laboratory studies showed mild normochromic normocytic anaemia with neutrophilia, Westergren sedimentation rate 42 mm in the first hour, normal coagulation studies, CRP 8, normal B₁₂ levels, negative VDRL, TPHA, and Bartonella serology. Tacrolimus blood levels were within the normal therapeutic range during the post-transplant follow up period. Magnetic resonance imaging showed no focal lesions, only mild cortical atrophy.

Electrodiagnostic studies reported very severe bilateral optic nerve/retinal ganglion cell dysfunction. The pattern visual evoked potential (VEP) was grossly delayed and of subnormal amplitude, flash VEP showed profound latency delay and amplitude reduction. Pattern electroretinogram (ERG) showed shortening of P50 with loss of N95 and some additional P50 amplitude involvement. Full field ERG was unremarkable.

Comment

Tacrolimus suppresses T cell activation and T helper cell dependent B cell proliferation, as well as the formation of lymphokines such as interleukin 2, 3, and α interferon and the expression of the interleukin 2 receptor. The effects are mediated at the molecular level by binding to a cytosolic protein (FKBP), which is also responsible for intracellular accumulation of the compound.

Although cortical blindness, associated with bilateral occipital white matter lesions, has been documented as a potential complication of tacrolimus therapy following bone marrow transplantation and liver transplantaton,^{1,2} there have been no reports to our knowledge of optic neuropathy secondary to tacrolimus in the United Kingdom.

Mechanisms of neurotoxicity are not clear, previously described theories include direct

neurotoxic effects, resulting in axonal swelling, increased water content, and oedema. Vascular mechanisms postulated include modification of prostacyclin-thromboxane interactions resulting in vasoconstriction and relative ischaemia.^{3,4}

Clinicians should be aware of the possible optic nerve toxicity of tacrolimus.

D B Lake, T R G Poole

Frimley Park Hospital, Portsmouth Road,
Camberley, Surrey GU16 7UJ, UK

Accepted for publication 6 March 2002

References

- 1 **Shutter LA**, Green JP, Newman NJ, *et al*. Cortical blindness and white matter lesions in a patient after receiving FK506 after liver transplantation. *Neurology* 1993;**43**:2417–18.
- 2 **Devine SM**, Newman NJ, Siegal JL, *et al*. Tacrolimus (FK506) induced cerebral blindness following bone marrow transplantation. *Bone Marrow Transplant* 1996;**18**:569–72.
- 3 **Brazis PW**, Spivey JR, Bolling JP, *et al*. A case of bilateral optic neuropathy in a patient on

tacrolimus (FK506) therapy after liver transplantation. *Am J Ophthalmol* 2000;**53**:6–8.

- 4 **Steg RE**, Kessinger A, Wszolek ZK. Cortical blindness and seizures in a patient receiving FK506 after bone marrow transplantation. *Bone Marrow Transplant* 1999;**23**:959–62.

Visual symptoms in patients on cyclophosphamide may herald sight threatening disease

Cytomegalovirus retinitis is a sight threatening, opportunistic infection of the neurosensory retina. Most cases occur in patients with AIDS,^{1,2} organ transplantation, or haematological malignancies.³ There are only a few isolated reports of cytomegalovirus retinitis complicating systemic immunosuppressive therapy in patients with collagen vascular diseases.^{4,6}

Case reports

We reviewed four patients on long term immunosuppression for collagen vascular disease who developed cytomegalovirus retinitis.

The retinitis was diagnosed on the basis of clinical presentation and laboratory testing including cytomegalovirus antibodies and/or viral culture and polymerase chain reaction for cytomegalovirus DNA of ocular fluid. CD4 and CD8 counts were obtained using FACS analysis of peripheral blood.

Two patients had systemic lupus erythematosus, one patient had Wegener's granulomatosis and the fourth patient had classic polyarteritis nodosa. Full patient details are given in Table 1. In summary, all patients were receiving combination immunosuppressive therapy. All patients were lymphopenic with three of four patients displaying a low CD4 cell count. Two patients presented with bilateral retinitis. Systemic immunosuppressive therapy was stopped or decreased in all patients and intravenous ganciclovir given. The retinitis healed eventually in all patients although one patient had two further recurrences on attempted cessation of ganciclovir therapy.

Comment

Cytomegalovirus is a herpesvirus, which generally causes a subclinical or mild clinical

Table 1 Patient characteristics

	Patient 1	Patient 2	Patient 3	Patient 4
Systemic disease				
Diagnosis	Polyarteritis nodosa	SLE	SLE	Wegener's granulomatosis
Age at diagnosis	43 years	38 years	28 years	71 years
Immunosuppressive therapy at presentation	Cyclophosphamide 100 mg/day Prednisolone 20 mg/day	Azathioprine 50 mg/day Prednisolone 10 mg/day	Azathioprine 150 mg/day Prednisolone 10 mg/day	Cyclophosphamide 50 mg/day Prednisolone 10 mg/day
Previous immunosuppression	IV steroids and IV cyclophosphamide	Oral cyclophosphamide	IV and oral cyclophosphamide	Oral cyclophosphamide
Duration of therapy	3 years	10 years	3 years	3 years
Ocular features				
Presenting complaints	Floaters	Decreased vision	Blurred vision	Blurred vision
Vision	6/12, 6/9	1/60, 6/9	6/18, 6/12	6/12-2, 6/9+2
Ophthalmic diagnosis	cytomegalovirus retinitis	cytomegalovirus retinitis	cytomegalovirus retinitis	cytomegalovirus retinitis
Delay between onset of symptoms and diagnosis	3–4 weeks	3–4 weeks	1.5–2 weeks	5–6 weeks
Other ophthalmic findings	Nil	Inferior retinal detachment	Epiretinal membrane	Nil
Laterality	Bilateral	Unilateral	Bilateral	Unilateral
Investigations				
CMV antibodies in blood	Positive IgM (rising titres)	Positive IgG and IgM (rising titres)	Positive IgG and IgM (rising titres)	Positive IgM
Cytomegalovirus culture	Positive from urine and blood	Negative	Negative	Negative
PCR for cytomegalovirus	Not done	Negative	Negative	Positive for CMV
WBC (NR 4–13)	3.9	17	7.6	3.1
Lymphocyte (NR 1.5–4)	0.2	0.5	0.72	0.3
CD4 cell count (NR 0.41–1.54)	Not done	0.12	0.26	0.02
CD8 cell count (NR 0.23–1.09)	Not done	0.28	0.25	0.21
Treatment				
Changes to immunosuppressive therapy	Cyclophosphamide reduced to 50 mg Prednisolone continued	Azathioprine stopped, Prednisolone reduced to 7.5 mg	Azathioprine stopped, Prednisolone continued	Cyclophosphamide stopped Prednisolone continued
Anticytomegalovirus therapy	IV ganciclovir	IV ganciclovir	IV ganciclovir	IV ganciclovir
Duration	6 weeks	3 weeks	5 weeks	4 weeks
Disease response	Quiescence	Quiescence	Quiescence	Quiescence
Recurrence	2 further recurrence	Nil	Nil	Nil
Prophylaxis	IV ganciclovir	Oral ganciclovir	Oral ganciclovir	Oral ganciclovir
Duration of prophylaxis	2.5 years	3 months	3.5 years	2 months
Outcome				
Visual acuity at last review	6/60, 6/36	1/60, 6/9	6/9, 6/9	6/12-2, 6/9+2
Other ocular complication/procedures	Successful bilateral retinal reattachment surgery	Successful right retinal reattachment surgery	Nil	Nil
Present status				
CD4 cell (NR 0.41–1.54)	0.55 (WBC 8.7, lymphocyte 4.2)	0.36	0.48	0.04
Immunosuppressive therapy	Nil	Prednisolone 7.5 mg/day	Prednisolone 7.5 mg/day, Azathioprine 100 mg/day	Prednisolone 10 mg/day
CMV prophylaxis	Nil	Nil	Nil	Oral ganciclovir

“flu-like” illness in healthy individuals. However in susceptible individuals—for example, those in immunocompromised states, many organs can be involved including the eyes, central nervous system, adrenals, gut, and lungs. Cytomegalovirus retinitis can occur as a complication of systemic immunosuppressive therapy including cyclophosphamide,^{3,6} azathioprine,^{4,6} and oral steroids, in isolation or in various combinations.

In our series, all patients were on cyclophosphamide. Patients 1 and 4 were taking cyclophosphamide at presentation. Patient 3 had received cyclophosphamide until 6 weeks before presentation, when his therapy was changed to azathioprine while patient 2 had received an 18 month course of cyclophosphamide in the past and a shorter 4 week course before development of CMV retinitis. Cyclophosphamide therapy suppresses both primary and established cellular and humoral immune responses.⁷ It can decrease the number of activated T lymphocytes, suppress CD4 and CD8 T cell functions, and decrease B lymphocyte counts and antibody production for several months. The incidence of CMV retinitis increases with CD4 cell count less than $0.05 \times 10^9/l$ and CD8 cell count less than $0.5 \times 10^9/l$.^{1,2} Following immunosuppression, CMV retinitis may also occur in the presence of normal CD4 cell count.⁶ In this single case report it was postulated that CMV retinitis occurred following the inhibition of T cell responses by azathioprine. In addition to the potential of immunosuppressive induced inhibition of T cell responses, all our patients were lymphopenic and three out of four presented with low CD4 and/or CD8 count.

Ganciclovir and foscarnet are the two most commonly used drugs for cytomegalovirus retinitis but both are virostatic and do not lead to complete eradication of the virus particles.⁸ Patients risk recurrence of cytomegalovirus retinitis after discontinuation of the antiviral therapy, especially if they require long term immunosuppression or have a slow immune recovery following the discontinuation of immunosuppressive therapy. One patient (patient 1), the only one to remain on immunosuppression in addition to steroids, had a recurrence of cytomegalovirus retinitis. On stopping the immunosuppressant, his WBC and CD4 cell count recovered and he did not have any further recurrence of cytomegalovirus retinitis, and maintenance of anti-CMV therapy was stopped successfully.

There are currently no established guidelines for the management of these patients. Studies of CMV retinitis in AIDS patients suggests that the maintenance therapy may be safely discontinued once the CD4 cell count is stable (above $0.1 \times 10^9/l$ for at least 3 months) and the retinitis is clinically quiescent.⁹ How applicable this guideline is for patients on immunosuppressive therapy is uncertain. In particular, two of our patients had CD4 cell counts above this level on presentation of CMV retinitis. Therefore any guideline would have to include a more quantitative assessment of cell function, so that prediction of safe withdrawal of maintenance therapy can be achieved.¹⁰

In summary, patients and their doctors need to be aware of this potentially sight threatening complication and are advised to seek expert help in the event of visual disturbance or atypical change in features of original ocular inflammation associated with their systemic disease.

A Agrawal

Department of Ophthalmology, St James University Hospital, Beckett Street, Leeds, UK

A D Dick

Department of Ophthalmology, University of Bristol, Bristol, UK

J A Olson

Department of Ophthalmology, Aberdeen Royal Infirmary, Aberdeen, UK

Correspondence to: John A Olson, Department of Ophthalmology, Aberdeen Royal Infirmary, Aberdeen AB25 2ZN, UK; J.Olson@arh.grampian.scot.nhs.uk

Accepted for publication 3 July 2002

References

- 1 Kupperman BD, Petty JG, Richman DD, *et al.* Correlation between CD4+ counts and prevalence of cytomegalovirus retinitis and human immunodeficiency virus-related non-infectious retinal vasculopathy in patients with acquired immunodeficiency syndrome. *Am J Ophthalmol* 1992;**16**:453–7.
- 2 Lowder CY, Butler CP, Dodds EM, *et al.* CD8+ lymphocyte and cytomegalovirus retinitis in patients with the acquired immunodeficiency syndrome. *Am J Ophthalmol* 195;**120**:283–90.
- 3 Erice A, Jordan MC, Chace BA, *et al.* Ganciclovir treatment of cytomegalovirus disease in transplant recipients and other immunocompromised hosts. *JAMA* 1987;**257**:3082–7.
- 4 Schlingemann RO, Wertheim-Van Dillen P, Kijlstra A, *et al.* Bilateral cytomegalovirus retinitis in a patient with systemic lupus erythematosus. *Br J Ophthalmol* 1996;**80**:169–70.
- 5 Tugal-Tutkun I, Kir N, Gul A, *et al.* Cytomegalovirus retinitis in a patient with Wegener's granulomatosis. *Ophthalmologica* 2000;**214**:149–52.
- 6 Morrison DA, Bibby K, Wiselka M, *et al.* Cytomegalovirus retinitis in the presence of normal helper T-cell count. *Eye* 1997;**11**:568–9.
- 7 Jabs DA, Rosenbaum JT, Foster CS, *et al.* Guidelines for the use of immunosuppressive drugs in patient with ocular inflammatory disorders: recommendations of an expert panel. *Am J Ophthalmol* 2000;**130**:492–513.
- 8 Burd EM, Pulido JS, Puro DG, *et al.* Maintenance of replicative intermediates in ganciclovir-treated human cytomegalovirus-infected retinal glia. *Arch Ophthalmol* 1996;**114**:856–61.
- 9 Vrabec TR, Baldassano VF, Whitcup SM. Discontinuation of maintenance therapy in patients with quiescent cytomegalovirus retinitis and elevated CD4+ counts. *Ophthalmology* 1998;**105**:1259–64.
- 10 Komanduri KV, Viswanathan MN, Wieder ED, *et al.* Restoration of cytomegalovirus-specific CD4+ T-lymphocyte responses after ganciclovir and highly active retroviral therapy in individuals infected with HIV-1. *Nat Med* 1998;**4**:953–6.

MAILBOX

Assessment of endothelium from donor corneas

We read with interest an article by Meier *et al.*¹ No doubt, this is an exciting issue on donor tissue harvesting and is more meaningful for the developing countries, where there is paucity of the donor material and, as a corollary to this, more people with corneal blindness. Further, because of more awareness towards cataract surgery as a result of the Vision 2020 programme, more patients are getting operated for cataract with a posterior chamber

intraocular lens insertion (PCIOL). This is more relevant because of the increase in lifespan, as a result of improved health care, worldwide.

However, we would like to comment on few additional aspects which would make the subject more clear. It is known that small incision cataract surgery influences less endothelial dysfunction than conventional extracapsular cataract extraction with PCIOL insertion.² Similarly, endothelial cell loss following cataract surgery is a gradual process and continues for 1–2 years.³ Therefore, it would have been better to understand, and analyse, the type of cataract surgery and the duration between cataract surgery and actual cornea retrieval. Though the better endothelial health in eyes with phacoemulsification was considered to be because of the shorter time taken with the procedure we feel, besides the time factor, the use of a high viscosity viscoelastic agent which is frequently used during phacoemulsification is responsible as it provides more endothelial protection and less chance of intraoperative corneal endothelial touch.⁴

The authors have further highlighted that prestorage endothelial evaluation was not done as it was extremely difficult in unstained corneas. But it might have been possible with 0.25% trypan blue staining, rather than alizarine red S, as this technique neither precludes clinical use nor its evaluation by other staining procedures.⁵

Finally, the authors have rightly emphasised three essential factors of endothelial evaluation: (i) endothelial cell density, (ii) percentage of hexagonality, (iii) coefficient of variation. Often, it is observed that endothelial status is commented only regarding cell count. This is more so for the developing countries where the endothelial specular microscope is not provided with the software by which the hexagonality and coefficient of variation can be calculated. Thus many good studies lose their authenticity owing to lack of this essential provision.⁶ We are grateful to the authors for throwing light on this aspect. On the basis of authors' comments and our own experience we suggest that while placing an order for specular microscope, it is mandatory to include this important software.

The authors are also commended by suggesting another source of donor tissue for penetrating keratoplasty.

A Panda, M S Pangtey, P Sony

AIIMS, New Delhi, India; anitap49@yahoo.com

References

- 1 Meier FM, Tschanz SA, Ganzfried R, *et al.* A comparative assessment of endothelium from pseudophakic and phakic donor corneas stored in organ culture. *Br J Ophthalmol* 2002;**86**:400–3.
- 2 Lavery KT, McDermott ML, Ernest PH, *et al.* Endothelial cell loss after 4 mm cataract surgery. *J Cataract Refract Surg* 1995;**21**:305–8.
- 3 Liesegang TJ, Bourne WM, Illstrup DM. Endothelial cell loss following cataract surgery. *Am J Ophthalmol* 1984;**97**:32–9.
- 4 Ravalico G, Tognetto D, Baccara F, *et al.* Corneal endothelial protection by different viscoelastics during phacoemulsification. *J Cataract Refract Surg* 1997;**23**:433–9.
- 5 Stocker FW, King EH, Lucas DO, *et al.* A comparison of two principles for evaluating corneal endothelial viability. *Arch Ophthalmol* 1959;**47**:772–82.
- 6 Panda A, Venkateshwarlu K, Angra SK, *et al.* Corneal changes in the corneal endothelial cell count as a function of age. *Ind J Ophthalmol* 1983;**33**:221–3.

Retinal vein occlusion and cardiovascular risk assessment

The article by Martin *et al*¹ on the cardiovascular risk assessment in a group of patients with compromised retinal circulation brings to light an important issue. For this group of patients and especially those with central retinal vein occlusion very little can be offered in the form of treatment. They are regularly followed up in the eye clinics for up to 2 years, with many of them worrying about secondary ophthalmic complications including that of neovascular glaucoma.

This article offers scope for evidence based practice in risk assessment and appropriate intervention in the form of primary preventive measures against coronary heart disease. The authors used a proprietary version of the Framingham algorithm for personal computers. Although this makes it simple for the ophthalmologist to feed in appropriate data to obtain the 10 year risk figure it may not be feasible in every ophthalmology unit that diagnoses and manages patients with retinal vein occlusion. A significant proportion of these patients are seen and managed in the district general hospitals. Access to a personal computer in the clinic may be difficult and this may discourage the risk assessment process.

The authors briefly mention in their introduction about the various tables that may help in calculating the risk. The Joint British Societies Coronary Risk Prediction Chart is available at the back of the *British National Formulary* (BNF). This provides the risk figure based on the various parameters like age, sex, smoking status, systolic blood pressure, presence or absence of diabetes, and total to HDL cholesterol ratio. This should serve the same purpose as that of the software mentioned in the article. The *BNF* should be more freely available and should encourage the practice of 10 year cardiovascular risk assessment much more widely for this group of patients.

The authors are to be congratulated for this excellent article that should change practice in many ophthalmology units.

S Dinakaran

A-Floor, Royal Hallamshire Hospital, Sheffield S10 2JF, UK; sdinakaran@yahoo.com

Reference

- 1 Martin SC, Butcher A, Martin N, *et al*. Cardiovascular risk assessment in patients with retinal vein occlusion. *Br J Ophthalmol* 2002;**86**:774–6.

A randomised controlled trial of written information

Newsham's effort to inform parents of children with amblyopia about occlusion therapy is laudable but incomplete.¹ Ethical considerations of informed consent require full disclosure of all aspect of the proposed treatment. The following points might be considered for inclusion.

(1) Occlusion therapy has never been scientifically validated with a randomised, controlled study.

(2) The dose/response relation has never been defined. Flynn *et al* stated that "Success was not related to the duration of occlusion therapy, type of occlusion used . . .".² The variety of treatment protocols accentuate another dilemma owing to our paucity of knowledge on the dose-effect relation—a situation one finds hard to imagine for any comparably established therapy outside ophthalmology.

In other words we have no understanding of the dose-effect relation of occlusion in amblyopia therapy."³

(3) The application of "greater levels of occlusion being prescribed for more severe amblyopia"⁴ is compromised by the observation that success was related to " . . . the depth of visual loss before treatment . . ."⁴

(4) The benefits of treatment are likely to deteriorate following cessation of patching.⁵

(5) Visual acuity improves as children become more mature, literate, and familiar with vision testing protocols.⁶ This is also true for amblyopic eyes. In amblyopic children between 3 and 7 years old, without treatment, visual acuity was shown to consistently improve in each older age group.⁷

(6) Both the occluded and the amblyopic eyes improve at the same rate during treatment.⁸

(7) Success in amblyopia treatment is usually defined as improvement by a minimum of three lines.⁹ Many of the successfully treated patients, by that criterion, will still not have normal vision at the end of presumably successful treatment. One quarter of treated patients with initial acuity better than 20/100 do not even achieve these limited goals.⁹ Therefore, the comments about achieving normal vision may raise expectations that will not be achieved.

(8) Occlusion therapy does have potential adverse effects beyond disruption of family and social life¹⁰ and interference with education.¹¹

(9) Despite decades of occlusion therapy the prevalence of amblyopia in the adult population is similar to that of the school age population.¹² Moreover, "the prevalence of unilateral amblyopia was not found to be statistically different by age group."¹³ This suggests that long term benefits of conventional therapy are not demonstrated in demographic studies.

Patients and their families should be provided with comprehensive information concerning proposed treatments. Physicians are obliged to make this information accurate and inclusive.

P Lempert

Ithaca, NY, USA; eyechartplus@aol.com

References

- 1 Newsham D. A randomised controlled trial of written information: the effect on parental non-concordance with occlusion therapy. *Br J Ophthalmol* 2002;**86**:787–91.
- 2 Flynn JT, Schiffman J, Feuer W, *et al*. The therapy of amblyopia: an analysis of the results of amblyopia therapy utilizing the pooled data of published studies. *Trans Am Ophthalmol Soc* 1998;**96**:431–50; discussion 450–3.
- 3 Simonsz HJ, Polling JR, Voorn R, *et al*. Electronic monitoring of treatment compliance in patching for amblyopia. *Strabismus* 1999;**7**:13–23.
- 4 Beardsell R, Clarke S, Hill M. Outcome of occlusion treatment for amblyopia. *J Pediatr Ophthalmol Strabismus* 1999;**36**:19–24.
- 5 Von Noorden GK, Attiah F. Alternating penalization in the prevention of amblyopia recurrence. *Am J Ophthalmol* 1986;**102**:473–5.
- 6 Robinson BE, Oladeji MM, Bobier WR. Visual acuity assessment in preschool children in Oxford County. ARVO 2000 Abst No 4955.
- 7 The Pediatric Eye Disease Investigator Group. The clinical profile of moderate amblyopia in children younger than 7 years. *Arch Ophthalmol* 2002;**120**:281–7 (Table 3 Baseline characteristics according to age at enrollment).
- 8 Dorey SE, Adams GG, Lee JP, *et al*. Intensive occlusion therapy for amblyopia. *Br J Ophthalmol* 2001;**85**:310–13.

- 9 The Pediatric Eye Disease Investigator Group. A randomized trial of atropine vs patching for treatment of moderate amblyopia in children. *Arch Ophthalmol* 2002;**120**:268–78.
- 10 Snowdon SL, Stewart-Brown SL. *Amblyopia and disability: a qualitative study*. Oxford: Health Services Research Unit University of Oxford.
- 11 Yang LL, Lambert SR. Reappraisal of occlusion therapy for severe structural abnormalities of the optic disc and macula. *J Pediatr Ophthalmol Strabismus* 1995;**32**:37–41.
- 12 Buch H, Vinding T, La Cour M, *et al*. The prevalence and causes of bilateral and unilateral blindness in an elderly urban Danish population. The Copenhagen City Eye Study. *Acta Ophthalmol Scand* 2001;**79**:441–9.
- 13 Brown SA, Weih LM, Fu CL, *et al*. Prevalence of amblyopia and associated refractive errors in an adult population in Victoria, Australia. *Ophthalmic Epidemiol* 2000;**7**:249–58.

NOTICES

Role of optometry in Vision 2000

The latest issue of *Community Eye Health* (No 43) discusses the mobilisation of optometry to deal with uncorrected refractive error, which is now a major cause of functional blindness. For further information please contact: Journal of Community Eye Health, International Centre for Eye Health, Institute of Ophthalmology, 11–43 Bath Street, London EC1V 9EL, UK (tel: +44 (0)20 7608 6910; fax: +44 (0)20 7250 3207; email: eyeresource@ucl.ac.uk; web site: www.jceh.co.uk). Annual subscription (4 issues) UK£25/US\$40. Free to workers in developing countries.

International Centre for Eye Health

The International Centre for Eye Health has published a new edition of the *Standard List of Medicines, Equipment, Instruments and Optical Supplies* (2001) for eye care services in developing countries. It is compiled by the Task Force of the International Agency for the Prevention of Blindness. Further details: Sue Stevens, International Centre for Eye Health, 11–43 Bath Street, London EC1V 9EL, UK (tel: +44 (0)20 7608 6910; email: eyeresource@ucl.ac.uk).

Second Sight

Second Sight, a UK based charity whose aims are to eliminate the backlog of cataract blind in India by the year 2020 and to establish strong links between Indian and British ophthalmologists, is regularly sending volunteer surgeons to India. Details can be found at the charity web site (www.secondsight.org.uk) or by contacting Dr Lucy Mathen (lucymathen@yahoo.com).

Specific Eye ConditionS (SPECES)

Specific Eye ConditionS (SPECES) is a not for profit organisation which acts as an umbrella organisation for support groups of any conditions or syndrome with an integral eye disorder. SPECES represents over fifty different organisations related to eye disorders ranging from conditions that are relatively common to very rare syndromes. We also include groups who offer support of a more general nature to visually impaired and blind people. Support groups meet regularly in the Boardroom at Moorfields Eye Hospital to offer support to

each other, share experiences and explore new ways of working together. The web site www.eyecconditions.org.uk acts as a portal giving direct access to support groups own sites. The SPECS web page is a valuable resource for professionals and may also be of interest to people with a visual impairment or who are blind. For further details about SPECS contact: Kay Parkinson, SPECS Development Officer (tel: +44 (0)1803 524238; email: k@eyecconditions.org.uk; web site: www.eyecconditions.org.uk).

The British Retinitis Pigmentosa Society

The British Retinitis Pigmentosa Society (BRPS) was formed in 1975 to bring together people with retinitis pigmentosa and their families. The principle aims of BRPS are to raise funds to support the programme of medical research into an eventual cure for this hereditary disease, and through the BRPS welfare service, help members and their families cope with the everyday concerns caused by retinitis pigmentosa. Part of the welfare service is the telephone helpline (+44 (0)1280 860 363), which is a useful resource for any queries or worries relating to the problems retinitis pigmentosa can bring. This service is especially valuable for those recently diagnosed with retinitis pigmentosa, and all calls are taken in the strictest confidence. Many people with retinitis pigmentosa have found the Society helpful, providing encouragement, and support through the Helpline, the welfare network and the BRPS branches throughout the UK. (tel: +44 (0)1280 821 334; email: lynda@brps.demon.co.uk; web site: www.brps.demon.co.uk)

World Conference on Tuberculosis

Stephen Lewis, UN special envoy for HIV/AIDS in Africa, closed the 33rd IUATLD World Conference on Lung Health in Montreal with a powerful call to increase advocacy for HIV and tuberculosis to resolve the health crisis in developing countries. We are at a crucial point in time, he said. Dr Richard Feachem, Executive Director of the Global Fund on Aids, Tuberculosis and Malaria (GFATM), will present his budget to the Fund's Board of Directors. Since its creation in 2001, the Fund has pledged of \$(US)2.1 billion but has only received \$(US)434 million so far. According to Stephen Lewis, Richard Feachem will be asking for \$(US)8.1 billion for the next year, of which \$(US)1.6 billion is devoted to TB—which doesn't take into account infrastructure costs. There is no precedence to match this pandemic, not even in the 14th century were deaths from communicable diseases so high. It is even worse than the two World Wars of the 20th century put together, he said. The situation is stunning, frightening and utterly unimaginable. On his visits to Africa, he has seen entire hospitals taken up by HIV patients, up to 60% of them also have active

tuberculosis. Although he widely commends the collaborative work of the tuberculosis community in its plans, strategies and treatments, the Stop TB Partnership targets will not be met if we do not take the HIV crisis on board. He emphasised that women, especially those in reproductive age groups, are badly hit by the epidemic. In his opinion, the HIV crisis in sub-Saharan Africa will influence the TB situation dramatically. This is further compounded by the famine that is impending from crop failure in six southern African countries, a threat to more than 14 million people already seriously weakened by the HIV-TB crisis. In these circumstances, there are no healthy people around to sustain productivity. You have to improve health conditions before you can expect to have economic development, he said. I am speaking to an enlightened audience, said Stephen Lewis. I beg of you, increase your advocacy to get the necessary resources. I would like to know, how come we can raise so much money so quickly for war and yet we have to grovel to raise money for health and fighting communicable diseases?

Retinal Detachment Course with international faculty and case presentations preceding Vitrektomie-Kurs—Wetlab

The Retinal Detachment Course with international faculty and case presentations and Vitrektomie-Kurs—Wetlab will be held 13 February 2003 (in English) and 14–15 February 2003 (in German) respectively, at Verwaltungsgebäude der KA Rudolfstiftung, 1030 Vienna, Boerhaavegasse 8a, Austria. Further details and registration: Firma Askin & Co, Albert-Schweritzer-Gasse 6, A-1140 Vienna, Austria (tel: +43 (1) 979 88 44; fax: +43 (1) 979 88 46).

Detachment Course with international faculty on: Retinal and Vitreous Surgery with Case Presentations preceding Retina Meeting

The detachment course with international faculty on: Retinal and Vitreous Surgery with Case Presentations and the Retina Meeting will be held 14–15 March 2003 and 16 March 2003 respectively, in Mexico City, Mexico. Further details: Scientific programme: Prof Ingrid Kreissig, University of Tuebingen, Schleichstr. 12, Breuningerbau, 72076 Tuebingen, Germany (tel: +49 7071 295209; email: ingrid.kreissig@med.uni-tuebingen.de). Local organisation: Prof. Quiroz-Mercado, Prof. Munoz, and Prof. Gonzalez "Hospital Luis Sanchez Bulnes", Asociacion para Evitar la Ceguera en Mexico Vicente Garcia Torres #46, Coyoacan, Mexico DF 04330 (fax: +5255 5659 5928; email: retinamex@yahoo.com).

16th Annual Meeting of German Ophthalmic Surgeons

The 16th Annual Meeting of German Ophthalmic Surgeons will be held 8–11 May 2003 in Nürnberg, Germany, Messezentrum. Organised by the Professional Association of German Ophthalmologists Ophthalmic Surgery Group the conference will cover cataract surgery, refractive surgery, glaucoma surgery, vitreoretinal surgery, corneal surgery, eye surgery in developing countries, and orbita, lacrimal and lid surgery. Further details: MCN Medizinische Congress organisation Nürnberg AG, Zerbabelshofstr 29, 90478 Nürnberg, Germany (tel: +49 911 3931621; fax: +49 911 3931620; email: doc@mcnag.info; web site: www.doc-nuernberg.de).

13th Meeting of the EASD Eye Complication Study Group

The 13th Meeting of the EASD Eye Complication Study Group will be held on the 23–25 May 2003, in Prague, Czech Republic. The scientific programme includes keynote lectures from Professor John H Fuller (UK) on The epidemiology of diabetic retinopathy; Dr P Martin van Hagen (The Netherlands) on Growth factors and diabetic retinopathy; Professor Terezie Pelikanova (Czech Republic) on Pathophysiology of diabetic microvascular complications; Dr Tomas Sosna (Czech Republic) on Risk and protective factors of diabetic retinopathy.

Three travel grants of €1000 each, sponsored by GlaxoSmithKline for young scientists (under 35 years at the time of the meeting). Applications should be made with the submission of abstracts. The deadline for abstracts is 14 February 2003.

Further details: Ortopedicke Centrum, s.r.o., Strekovské nabřeží 51, 400 03 Usti nad Labem, Czech Republic (tel: +420 47 521 6588; fax: +420 47 533 40 77; email: ortocentrum-ul@volny.cz; web site: www.ortopedicke-centrum.cz).

Detachment Course with international faculty on: Retinal and Vitreous Surgery with Case Presentations preceding the Annual Meeting of Iranian Society of Ophthalmology

The detachment course with international faculty on: Retinal and Vitreous Surgery with Case Presentations preceding Annual Meeting of Iranian Society of Ophthalmology will be held on 29–30 November 2003 and 1–4 December 2003 respectively, at the Razi Conference Center, Hemmat Hyw, Tehran, Iran. Further details: Scientific programme: Prof Ingrid Kreissig, University of Tuebingen, Schleichstr. 12, Breuningerbau, 72076 Tuebingen, Germany (tel: +49 7071 295209; email: ingrid.kreissig@med.uni-tuebingen.de). Local organisation: Dr Arman Masheyyekhi, Dr Siamak Moradian, Dept of Ophthalmology, Labbanfinejad Medical Center, Pasdaran Ave, Boostan 9, Tehran, 16666, Iran (fax: +98 21 254 9039; email: labbafi@hotmail.com).



Adult orbital xanthogranuloma with periosteal infiltration

R Malhotra, R G B Porter and D Selva

Br J Ophthalmol 2003 87: 120-121

doi: 10.1136/bjo.87.1.120-a

Updated information and services can be found at:

<http://bjo.bmj.com/content/87/1/120.2.full.html>

References

These include:

This article cites 5 articles, 2 of which can be accessed free at:

<http://bjo.bmj.com/content/87/1/120.2.full.html#ref-list-1>

Article cited in:

<http://bjo.bmj.com/content/87/1/120.2.full.html#related-urls>

Email alerting service

Receive free email alerts when new articles cite this article. Sign up in the box at the top right corner of the online article.

Notes

To request permissions go to:

<http://group.bmj.com/group/rights-licensing/permissions>

To order reprints go to:

<http://journals.bmj.com/cgi/reprintform>

To subscribe to BMJ go to:

<http://group.bmj.com/subscribe/>