

## WORLD VIEW

## Paediatric cataract blindness in the developing world: surgical techniques and intraocular lenses in the new millennium

M E Wilson, S K Pandey, J Thakur

*Br J Ophthalmol* 2003;**87**:14-19

Paediatric cataract blindness presents an enormous problem to developing countries in terms of human morbidity, economic loss, and social burden. Managing cataracts in children remains a challenge: treatment is often difficult, tedious, and requires a dedicated team effort. To assure the best long term outcome for cataract blind children, appropriate paediatric surgical techniques need to be defined and adopted by ophthalmic surgeons of developing countries. The high cost of operative equipment and the uneven world distribution of ophthalmologists, paediatricians, and anaesthetists create unique challenges. This review focuses on issues related to paediatric cataract management that are appropriate and suitable for ophthalmic surgeons in the developing world. Practical guidelines and recommendations have also been provided for ophthalmic surgeons and health planners dealing with childhood cataract management in the developing world.

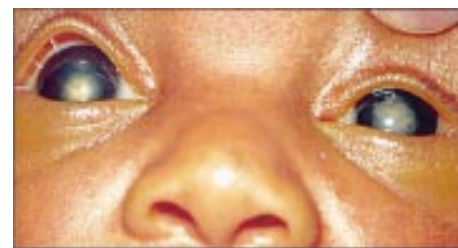Foster and Gilbert,<sup>14</sup> about 0.5 million children become blind each year (Fig 1). For those who survive childhood, the burden of disability in terms of "blind years" is huge. The child who goes blind today is likely to remain with us into 2050.<sup>7</sup>

Currently, approximately seven million adult cataract surgeries are performed annually in the world.<sup>15</sup> Precise data related to the total number of paediatric cataract surgeries performed annually are not available. However, paediatric cataract blindness presents an enormous problem to the developing world in terms of human morbidity, economic loss, and social burden (Table 2).<sup>16-20</sup> Restoring the sight of one child blind from cataracts may be equivalent to restoring the sight of 10 elderly adults.<sup>7</sup>

Irrespective of the cause, childhood blindness has far reaching effects on the child and family throughout life. It profoundly influences educational, employment, personal, and social prospects. The control of childhood blindness has been identified as a priority of the World Health Organization's (WHO) global initiative for the elimination of avoidable blindness by the year 2020.<sup>21</sup>

Series editors: W V Good and S Ruit

A child becomes bilaterally blind every minute, primarily within developing nations. Of the 1.5 million blind children in the world, 1.3 million live in Asia and Africa, and 75% of all causes are preventable or curable. The prevalence of blindness varies according to the socioeconomic development of the country and the mortality rate of those under 5 years of age. In developing countries the rate of blindness can be as high as 1.5 per 1000 population. Compared to industrialised countries, this figure is 10 times higher.<sup>1-9</sup> Table 1 summarises some of the studies regarding prevalence of childhood blindness in various developing countries.<sup>10-13</sup> As reported by



**Figure 1** Bilateral dense infantile cataract. Early surgery is needed to avoid nystagmus and a lifetime of poor visual acuity.

See end of article for authors' affiliations

M Edward Wilson, Jr, MD, Storm Eye Institute, Department of Ophthalmology, Medical University of South Carolina, 167 Ashley Avenue, PO Box 250676, Charleston, SC, 29425-5536 USA; wilsonme@musc.edu

Accepted for publication 31 July 2002

**Table 1** Prevalence of childhood blindness in developing countries

Study	Country	Prevalence per 1000 children (age range, years)
Cohen <i>et al</i> (1985) <sup>10</sup>	Bangladesh	1.09 (0-5, urban)
Cohen <i>et al</i> (1985) <sup>10</sup>	Bangladesh	0.64 (0-5, rural)
Brilliant <i>et al</i> (1985) <sup>11</sup>	Nepal	0.63 (0-14)
Chirambo <i>et al</i> (1986) <sup>12</sup>	Malawi	1.1 (0-5)
Faal <i>et al</i> (1989) <sup>13</sup>	Gambia	0.7 (0-19)

**Table 2** Cataract as a cause of childhood blindness

Study	Country	Percentage of blindness
Moriarty (1988) <sup>16</sup>	Jamaica	39%
Pottor (1991) <sup>17</sup>	Central African Republic	13.5%
Eckstein <i>et al</i> (1995) <sup>18</sup>	Sri Lanka	17%
Rahi <i>et al</i> (1995) <sup>19</sup>	India	12%
Waddell <i>et al</i> (1998) <sup>20</sup>	Uganda	30.7%

## CHILDHOOD CATARACT MANAGEMENT

Management of congenital and childhood cataracts remains a challenge. Increased intraoperative difficulties, propensity for increased postoperative inflammation, changing refractive state of the eye, more common postoperative complications and a tendency to develop amblyopia, all add to the difficulty in achieving a good visual outcome in the paediatric patient. Adaptation of techniques for cataract surgery specific to children is necessary owing to low scleral rigidity, increased elasticity of the anterior capsule, and high vitreous pressure. Also, microphthalmia and pupillary miosis often add to the surgical complexity. Finally, surgical timing and adequate visual rehabilitation are paramount, to avoid irreversible visual damage secondary to amblyopia.

Several articles and book chapters have been published regarding adult and paediatric cataract management in the industrialised world.<sup>22–32</sup> To the best of our knowledge, there are no publications that provide guidelines to readers regarding the management of paediatric cataracts in the developing world. In this article, we address some of the major issues related to the surgical treatment of childhood cataracts by surgeons of the developing world.

## PAEDIATRIC CATARACT SURGERY IN THE DEVELOPING WORLD

### General anaesthesia via endotracheal intubation or laryngeal mask airway (LMA)

A comprehensive summary of the techniques of general anaesthesia in ophthalmic care centres in the developing world is beyond the scope of this article. Cost and effectiveness are both very important when choosing anaesthetic agents in a developing world setting. We recommend that paediatric cataract surgery be performed under general anaesthesia with constant monitoring of the vital signs. Ophthalmic surgeons in Guatemala have utilised modern inhalation agents via LMA combined with peribulbar lignocaine (lidocaine) and Marcaine in children to facilitate anaesthesia maintenance on as little inhalation agent as possible.

### Ketamine anaesthesia

Because of limited resources and availability of anaesthetists in remote areas of the developing world, ketamine provides a safe and potent intravenously administered anaesthetic of short duration for paediatric populations. Ketamine combines analgesic and sleep producing effects without significant cardiovascular and respiratory depression.<sup>33</sup> The most common side effects are the so called “emergence phenomenon” which include disorientation, vivid dreams, and sensory or perceptual illusion.

Ophthalmic surgeons in Nepal have used ketamine in combination with peribulbar lignocaine when performing paediatric cataract surgery.<sup>34</sup> While an anaesthetist is not always available, the anaesthesia is always administered by a person trained in paediatric airway management and resuscitation. A pulse oximeter is used as part of the vital sign monitoring. This technique has the advantage of ketamine as the dissociative anaesthesia, and peribulbar lignocaine (combined with ocular massage) as the local anaesthetic agent to anaesthetise the ocular tissues and to counter the effect of increased intraocular pressure caused by the ketamine.

## SURGICAL METHODS FOR PAEDIATRIC CATARACT

The aim of paediatric cataract surgery is to provide and maintain a clear visual axis and a focused retinal image. This is accomplished by timely removal of the opacified crystalline lens and appropriate optical rehabilitation. Methods for paediatric cataract surgery used in the developing world setting are needling, needling and aspiration, or extracapsular cataract surgery with or without IOL implantation. The long

term visual outcome is often negatively affected by the development of amblyopia secondary to the cataract itself, or because of postoperative reopacification of the ocular media.<sup>23–24</sup>

Extracapsular cataract extraction (ECCE) techniques described in the literature for the paediatric cataract management include automated lensectomy with anterior vitrectomy (LAV); extracapsular cataract extraction with intraocular lens implantation ((ECCE + IOL) manual or automated with an intact posterior capsule), and ECCE, primary posterior capsulotomy, anterior vitrectomy with intraocular lens implantation ((ECCE + PPC + AV + IOL), manual or automated posterior capsulotomy with automated vitrectomy). Variations on the latter technique have been proposed in the hope of eliminating the vitrectomy, while still performing the posterior capsulotomy at the time of surgery. However, to the best of our knowledge, the available literature does not provide clearcut guidelines about when to use these various techniques. This is especially important in developing countries since microsurgical equipment is expensive and experience with paediatric ophthalmic surgery and anaesthesia are spread unevenly throughout many regions.

The results of using the various surgical techniques mentioned above have been reported in some of the studies concerning paediatric cataract management (Table 3).<sup>35–40</sup> Based on the published studies<sup>35–40</sup> and our experience so far,<sup>22–25</sup> we agree that extracapsular cataract surgery, primary posterior capsulotomy and anterior vitrectomy (ECCE, PPC, and AV) provide the best chance of a long term clear visual axis. When long term follow up is not likely and Nd:YAG laser treatment is not available, we recommend ECCE, PPC, and AV with IOL implantation for all children 8 years of age and younger. From age 8 until the end of growth, PPC is still recommended, although the AV is optional.

### Recommended surgical steps

Figure 2 illustrates our preferred surgical technique for management of the paediatric cataract in the developing world setting. In brief, under general anaesthesia, two limbal incisions are recommended utilising a 20 gauge microvitreoretinal (MVR) knife at the 10 o'clock and 2 o'clock positions; one for an irrigation cannula (connected to a balanced salt solution (BSS)) and the other one for an aspiration/cutting hand piece. Adrenaline (1:500 000) is usually added in the BSS to maintain the pupillary mydriasis.

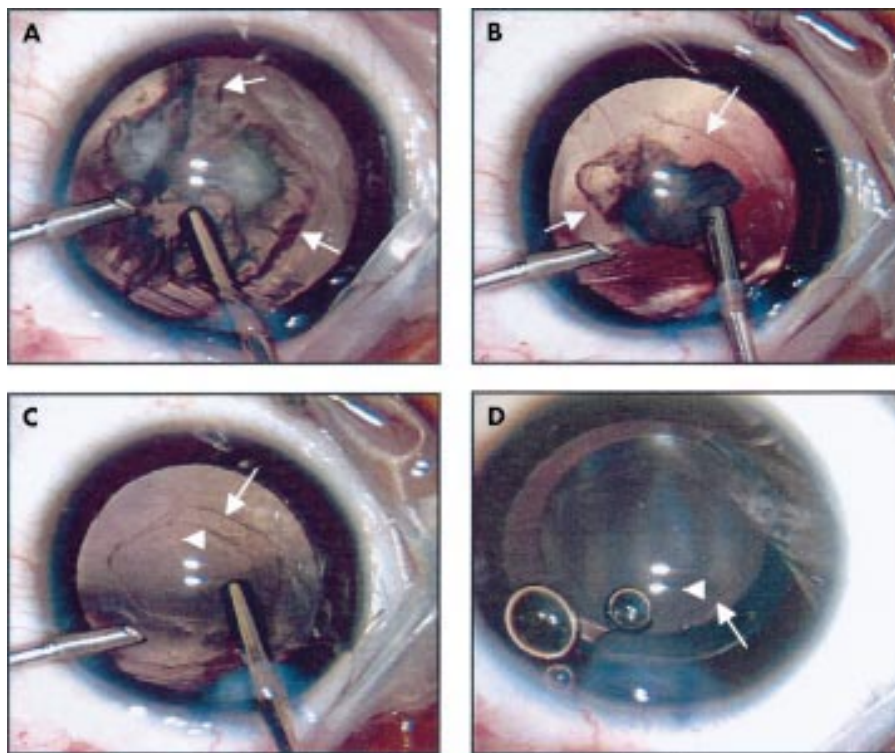
Several techniques have been described to open the anterior capsule. Interested readers are referred to the details about anterior capsule management discussed by one of the authors (MEW) elsewhere.<sup>26</sup> In brief, infants and young children have a very elastic anterior capsule, which easily extends toward the periphery. Manual continuous circular capsulorhexis (CCC) is challenging, and there is frequently a “runaway rhexis.” A practical alternative to manual CCC is to create a small central opening in the anterior capsule using a vitrector probe. This initial hole can be enlarged by “biting” into the anterior capsule with the vitrector until the desired 5 mm opening is achieved (Fig 2A). This technique is known as vitrectorhexis. We recommend using a Venturi pump vitrector set at a cutting rate of 150–300 cuts per minute and an aspiration maximum of 150–250. The lens cortex and nucleus are usually aspirated easily with either an irrigation-aspiration or vitrectomy hand piece (Fig 2, A and B). When using the vitrector, intermittent cutting bursts can facilitate aspiration of the more “gummy” cortex of young children. Complete removal of cortical material is desired. Even if a primary posterior capsulotomy is planned, removal of all cortical material will result in less inflammation and potentially less cortical reepithelialisation later.

Once the capsular bag is empty, a decision has to be made regarding management of the posterior capsule. Most authors

**Table 3** Selected studies of paediatric cataract surgery

Study	No of patients (no of eyes)	Age range (mean)	Mean follow up	BCVA		Type of surgery (no of eyes)	Posterior capsule opacity	% Other (complication)
				>6/18 (%)	>6/60 (%)			
Taylor (1981) <sup>35</sup>	29 (51)	0–18 months (16 weeks) 0–18 months (17.4 weeks)	18 months 18 months	NA	NA	Aspiration alone PC intact (28)	68.0%	Not mentioned
						Lensectomy (23)	0%	Not mentioned
Chrousos <i>et al</i> (1984) <sup>36</sup>	(392)	0–20 years	5.5 years	NA	NA	Aspiration alone (304)	62.1%	7.2% (glaucoma) 1.3% (RD)
						Roto extraction and primary capsulotomy -small (34)	11.7%	5.8% (glaucoma) 2.9% (RD)
						Ocutome aspiration-wide post capsulotomy (54)	0%	0% (glaucoma) 1.8% (RD)
Keech <i>et al</i> (1989) <sup>37</sup>	76 (125)	0–30 months (18 weeks)	44.8 months	NA	NA	Aspiration alone (20)	75.0%	20% (glaucoma) 5% (RD)
						Lensectomy (105)	11.0%	11.4% (glaucoma) 0.95% (RD)
Basti <i>et al</i> (1996) <sup>38</sup>	(192)	2–8 years	11.3 months	44.15%	63.64%	Lensectomy anterior vitrectomy (LAV) (23)	0%	0% RD 0% pupillary capture
						ECCE+IOL (87)	43.7%	1.14% (RD) 8.04% (pupillary capture) 13.8% (uveitis)
						ECCE+PPC+AV+IOL (82)	3.6%	0% (IOL dislocation) 1.22% (RD) 8.53% (pupillary capture) 15.9% (uveitis) 2.44% (IOL dislocation)
Eckstein <i>et al</i> (1999) <sup>39</sup>	56 (112)	3 months–10 years (53 months)	3 years	57.1%	94.6%	Lens aspiration with primary posterior capsulotomy (56)	66.1%	1.8% (glaucoma) 16% (amblyopia) 1.8% (pupil decentration)
						Lensectomy (vitreophage) (56)	1.8%	1.8% (glaucoma) 3.6% (RD) 16% (amblyopia) 3.6% (pupil decentration)
Yorston <i>et al</i> (2001) <sup>40</sup>	71 (118)	0–11 years (3.5 years)	3 months	44.0%	91.2%	Anterior capsulotomy and lens aspiration (56)	35.7%	1.7% (glaucoma) 30.5% (uveitis) 31.4% (amblyopia)
						Anterior capsulotomy + lens aspiration + primary posterior capsulectomy + anterior vitrectomy (62)	1.6%	

No = number; BCVA = best corrected visual acuity; NA = not available; PC = posterior capsule; RD = retinal detachment; ECCE+IOL = extracapsular cataract surgery + intraocular lens; ECCE+PPC+AV = extracapsular cataract surgery + primary posterior capsulotomy + anterior vitrectomy.



**Figure 2** Documentation of some of the surgical steps we recommend for paediatric cataract management in the developing world. (A) Vitrector hand piece and a blunt tip irrigation cannula have been inserted into the anterior chamber through MVR stab incisions. A 5 mm vitrectorhexis has been made (arrows) and the lens substance is being aspirated. (B) Lens cortex aspiration is completed before performing a posterior capsulectomy (arrows, anterior vitrectorhexis edge). (C) Posterior vitrectorhexis and an anterior vitrectomy can be performed after lens aspiration without removing the instruments from the eye (arrow, anterior vitrectorhexis edge; arrowhead, posterior vitrectorhexis edge). (D) Intraocular lens has been placed into the capsular bag (arrow, anterior vitrectorhexis edge; arrowhead, posterior vitrectorhexis edge).

agree that infants under 2 years of age should receive an elective posterior capsulectomy and anterior vitrectomy. Owing to poor compliance and the difficulty in following these paediatric patients in the developing world, we suggest a primary posterior capsulotomy followed by an anterior vitrectomy at least for children up to 8 years of age. Posterior capsulotomy can be carried out easily with the vitrector from an anterior incision or via the para plana.<sup>41 42</sup> The posterior capsulotomy should be 4–5 mm in diameter and approximately one third of the anterior vitreous should be removed to ensure a permanently clear visual axis (Fig 2C). Smaller posterior capsulectomies with shallow anterior vitrectomies tend to close down, especially in neonates. A posterior capsulectomy alone does not guarantee a permanently clear visual axis, because the vitreous face can serve as a scaffold on which the lens epithelium can grow. When this happens, opaque membranes form.

Intraocular lens optic capture, while helpful in implant centration (especially, when the IOL haptics are in the ciliary sulcus), does not assure a permanent clear visual axis in children less than 6–8 years of age. An anterior vitrectomy is recommended whether posterior IOL optic capture is utilised, or not.<sup>43 44</sup> While foldable IOLs can be inserted through either a corneal or a scleral tunnel (Fig 2D), the poly(methyl methacrylate) (PMMA) IOLs manufactured in the developing world should be inserted through a scleral tunnel which is securely sutured. A superior approach is favoured since the wound is protected beneath the brow.

## PAEDIATRIC CATARACT SURGERY IN THE DEVELOPING WORLD: SPECIAL ISSUES

### Use of IOLs for paediatric cataract surgery in the developing world

Aphakic glasses, contact lenses, and IOLs have been proposed as methods of visual rehabilitation after paediatric cataract surgery. Spectacles are heavy, ill fitting, and uncomfortable and have a magnification factor of 20–30%. Lenses scratch easily and frames easily break. It is difficult to replace spectacles once broken or damaged, owing to the expense and unavailability, particularly in the developing world. They are

unsuitable for monocular aphakia and restrict visual rehabilitation. Contact lenses are impractical for most patients in the developing world, because the majority live in rural areas where suboptimal living standards and scarcity of clean water makes personal and ocular hygiene difficult. Regular follow up visits to eye care clinics are problematic owing to cost and distance of travel. Contact lenses are expensive and easily lost. Moreover, personnel qualified to offer contact lens service are scarce.

Implantation of an IOL during cataract surgery in the developing world seems to be a practical option, while other methods of visual rehabilitation (aphakic glasses and contact lenses) are less suitable in these settings. An IOL can provide a full time correction with optics that closely simulate those of the crystalline lens. In the industrialised world, IOL implantation at the time of cataract surgery is rapidly becoming the most common means of optical correction for children beyond infancy.<sup>30</sup> In a recent study done in Africa, Yorston and coworkers<sup>40</sup> also recommend IOL implantation as the treatment of choice for most children with cataract in the developing world.

Efforts are in progress to manufacture PMMA IOLs inexpensively in the developing world.<sup>45</sup> The better visual acuity afforded by an IOL compared to correction with aphakic glasses has had a key role in stimulating market demand for cataract services from all economic strata. Vision with an IOL attracts adult cataract patients to accept surgery at an earlier stage, when they are still able to work and can pay for the surgery. Financial self sufficiency can be attained by the physician, as cataract surgery programmes are able to recover costs from user fees. The IOL producing facilities in Madurai, India (Aurolab of Aravind Eye Hospital) and in Nepal and Eritrea (Fred Hollows Foundation's facilities), are successful examples.

Foldable lenses allow a much smaller incision than PMMA IOLs, for children. Since children may traumatise their eyes after surgery, the size of the incision is of great importance. Smaller incisions are more practical in children (in the developing world) than adults since the lenses are soft and no hard nucleus is present. Small incisions incite less inflammation

**Table 4** Recommended surgical steps to improve the long term visual outcome of children with cataracts, in the developing world

Surgical step	Recommendation for patients aged 8 years or less	Recommendation for patients aged more than 8 years
Anterior capsule	Vitrectorhexis	Manual CCC or vitrectorhexis
Lens removal	Automated IA	Manual or automated IA
Posterior capsule	Vitrectorhexis	Manual PCCC or vitrectorhexis
Vitreous	Anterior vitrectomy	No vitrectomy or anterior vitrectomy
IOL implantation	PMMA IOL or acrylic IOL	PMMA IOL or acrylic IOL

IA = irrigation and aspiration; CCC = continuous curvilinear capsulorhexis; PCCC = posterior continuous curvilinear capsulorhexis; PMMA = poly(methyl methacrylate); IOL = intraocular lens.

and require less suture closure. The major disadvantage of foldable IOLs for children is cost. Aurolab has recently begun manufacturing a hydrophilic acrylic foldable IOL in its factory in India. These will be sold for approximately US\$35. Foldable lenses made from hydrophobic acrylic biomaterials (AcrySof, Alcon, Fort Worth, TX, USA) have become the most commonly implanted IOL for children in the United States, but are prohibitively expensive (more than \$100) for use in most of the developing world.

#### IOL power selection

Selecting the best IOL power to implant in a growing child presents unique challenges. A lack of instrumentation in the developing world operating room setting, such as the hand held keratometer and the A-scan ultrasound, creates difficulty in selecting the appropriate IOL power to use for paediatric cataract surgery. In order to minimise the need to exchange IOLs later in life when a large myopic shift occurs, it has been advised to undercorrect children with IOLs so that they can grow into emmetropia or mild myopia in adult life. We recommend measuring axial length and keratometry, and utilising modern theoretical IOL formulas. Dahan and coworkers<sup>46</sup> have advised utilising an IOL with a power that is 20% less than that predicted by these formulas when the child is less than age 2 years, and a 10% undercorrection from age 2–8 years. Alternatively, when keratometry is not available, axial length measurement can be done and 28, 27, 26, 24, and 22 dioptre IOLs can be implanted for axial lengths of 17, 18, 19, 20 and 21 mm, respectively. If emmetropia or mild myopia is selected as the target refraction in operating young children, high myopia will probably occur later.<sup>47</sup>

Residual hyperopia (that is, following IOL implantation) should be managed with spectacles if possible. In some developing world settings, obtaining and maintaining spectacles after surgery is not feasible. Less residual hyperopia is aimed for in these cases. When operating bilaterally, however, emmetropia need not always be the target refraction even when spectacles cannot be obtained. At the Storm Eye Institute<sup>48</sup> we have noted much better distance and near functional vision in children than would be predicted with poor spectacle compliance for residual hyperopia in the 1–3 dioptre range. Pseudoaccommodation in children with monofocal IOLs can be impressive even though the reasons for its existence have not been fully elucidated. For bilateral cataract surgery in the developing world, an IOL power should be selected for each eye that is likely to give a postoperative refraction of no more than 4 dioptries of myopia, after full eye growth. This strategy will require leaving a moderate amount of hyperopia in children less than age 3 years and a mild amount up to age 6 years. If glasses or refractive surgery are readily available to these children when they reach adulthood, this strategy could be altered. However, if these refractive aids are not available, it is preferable to choose moderate hyperopia now to avoid high myopia (which may affect work performance) later.

Every attempt should be made to obtain A-scan ultrasound capability in centres where paediatric cataract surgery is to be

performed. Microphthalmia produces much lower globe axial lengths than expected for age. Form vision deprivation from delays in removal of cataracts in children can result in much longer globe axial lengths than expected. While the same power for all IOL implantation may be preferred over aphakia for all, ultrasound technology is preferred and has little recurring cost once the equipment is purchased.

#### SIMULTANEOUS BILATERAL PAEDIATRIC CATARACT SURGERY OR IMMEDIATELY SEQUENTIAL CATARACT SURGERY

Some authors<sup>49–52</sup> have proposed simultaneous paediatric cataract surgery to manage the backlog of cataract blindness in the developing world. The fears of bilateral blinding endophthalmitis or bilateral postoperative wound rupture have made unilateral surgery the normal procedure in the industrialised world. Within the amblyopic years, surgery in the second eye is usually done within a few days or weeks of the initial surgery. In the developing world, this cautious approach may not be practical. To avoid the risks and costs of a second anaesthesia and to make maximal use of the vitrector tubing and cutter, bilateral simultaneous surgery on children should be given strong consideration.

#### PAEDIATRIC CATARACT SURGERY IN THE DEVELOPING WORLD

##### Guidelines and recommendation for health planners and surgeons

The acceptability, accessibility, and affordability of cataract surgical services must each be carefully addressed to improve efficiency. In some locations the facilities are in place but underutilised, because there is a lack of knowledge, monetary constraints, or a negative public perception of the surgery owing to poor results using inadequate or poorly timed treatment. Inadequate ophthalmic and anaesthesiology staff, the lack of ophthalmic surgical instruments, and poor equipment maintenance are also widespread in developing countries. Other problems include the logistic complexities of identifying the children who will benefit most for surgery and arranging reliable transportation to the treatment centre.

In conclusion, we recommend the following steps to improve the long term visual outcome of children with cataracts, regardless of the cause of those cataracts. These recommendations are in addition to the many ongoing efforts aimed at the eradication of childhood cataracts through such programmes as rubella vaccination and nutritional improvement. The steps should be funded by non-government organisations and regional eye centres through donations and cost recovery plans. Since the future of any society is its children, it is time to give childhood cataract treatment the attention that adult cataract treatment has received for many years. Figure 2 illustrates some of the steps of our recommended surgical techniques for paediatric cataract management in the developing world. Table 4 also summarises our surgical

recommendations. Our recommendations to facilitate the application of these surgical steps, are as follows:

(a) Improve the early identification and referral of children with cataract by educating and training paediatricians, rural health clinic personnel, and eye camp workers to screen for loss of the eye's red reflex and poor visual functioning in newborn, toddlers, and school aged children (Fig 1). An early surgical intervention and prompt optical rehabilitation is mandatory in order to prevent irreversible deprivational amblyopia.

(b) Designate regional centres for the treatment of paediatric cataracts. Equip these centres with vitrectomy machines, A-scan ultrasonography, and portable keratometry equipment for IOL power calculations, a supply of IOLs in a wide range of powers, and paediatric anaesthesia equipment needed for safe monitored anaesthesia of infants and children. Staff these centres with well trained paediatric ophthalmic surgeons and anaesthetists.

(c) Set up a twinning relation between each regional developing world paediatric cataract centre and an industrialised world centre that has experience in paediatric surgery. This will facilitate continuing medical education and internet consultation.

## ACKNOWLEDGEMENTS

The authors gratefully acknowledge the partial support of an unrestricted grant to the Storm Eye Institute from Research to Prevent Blindness, Inc, New York, USA; and the editorial assistance of Luanna R Bartholomew, PhD.

Supported in part by an unrestricted grant from Research to Prevent Blindness, Inc, New York, USA.

The authors have no financial or proprietary interest in any product mentioned in this paper.

## Authors' affiliations

**M E Wilson, S K Pandey, J Thakur**, Miles Center for Pediatric Ophthalmology, Storm Eye Institute, Medical University of South Carolina, Charleston, South Carolina, USA  
**J Thakur**, Tilganga Eye Center, Katmandu, Nepal

## REFERENCES

- Gilbert C, Foster A. Childhood blindness in the context of Vision 2020—the right to sight. *Bull World Health Organ* 2001;**79**:227–32.
- Hoyt CS, Good WV. The many challenges of childhood blindness. *Br J Ophthalmol* 2001;**85**:1145–6.
- Cunningham ET Jr, Lietman TM, Whitcher JP. Blindness: a global priority for the twenty-first century. *Bull World Health Organ* 2001;**79**:180.
- Steinkuller PG, Du L, Gilbert C, et al. Childhood blindness. *J AAPOS* 1999;**3**:26–32.
- Foster A. Cataract and “Vision 2020—the right to sight” initiative. *Br J Ophthalmol* 2001;**85**:635–7.
- O'Sullivan J, Gilbert C, Foster A. The causes of childhood blindness in South Africa. *S Afr Med J* 1997;**87**:1691–5.
- Foster A, Gilbert C, Rahi J. Epidemiology of cataract in childhood: a global perspective. *J Cataract Refract Surg* 1997;**23**:601–4.
- Rahi JS, Gilbert CE, Foster A, et al. Measuring the burden of childhood blindness. *Br J Ophthalmol* 1999;**83**:387–8.
- Foster A. Childhood blindness in India and Sri Lanka. *Indian J Ophthalmol* 1996;**44**:57–60.
- Cohen N, Rahaman H, Sprague J, et al. Prevalence and determinants of nutritional blindness in Bangladeshi children. *World Health Stat Q* 1985;**38**:3187–9.
- Brilliant LB, Pokhrel RP, Grosset NC, et al. Epidemiology of blindness in Nepal. *Bull World Health Organ* 1985;**63**:375–86.
- Chirambo MC, Tielsch JM, West KP, et al. Blindness and visual impairment in southern Malawi. *Bull World Health Organ* 1986;**64**:567–72.
- Faal H, Minassian D, Sowa S, et al. National survey of blindness and low vision in the Gambia. *Br J Ophthalmol* 1989;**73**:82–7.
- Foster A, Gilbert C. Epidemiology of childhood blindness. *Eye* 1992;**6**:173–6.
- Thylefors B. Cataract as a global health problem. *Ophthalmic Res* 1999;**31**:143–60.
- Moriarty BJ. Childhood blindness in Jamaica. *Br J Ophthalmol* 1988;**72**:65–7.
- Pottor AR. Cause of blindness and visual handicap in the Central African Republic. *Br J Ophthalmol* 1991;**75**:326–9.
- Eckstein MB, Foster A, Gilbert CE. Causes of childhood blindness in Sri Lanka: results from children attending six schools for the blind. *Br J Ophthalmol* 1995;**79**:633–6.
- Rahi JS, Sripathi S, Gilbert CE, et al. Childhood blindness in India: causes in 1318 blind school students in nine states. *Eye* 1995;**9**:545–50.
- Waddell KM. Childhood blindness and low vision in Uganda. *Eye* 1998;**12**:184–92.
- Thylefors B, Negrel AD, Pararajasegaram R, et al. Global data on blindness. *Bull World Health Organ* 1995;**73**:115–21.
- Wilson ME, Pandey SK, Werner L, et al. Pediatric cataract surgery: current techniques, complications and management. In: Agarwal S, Agarwal A, Sachdev MS, et al, eds. *Phacoemulsification, laser cataract surgery and foldable IOLs*. New Delhi: Jaypee Brothers, Medical Publishers, 2000:369–88.
- Pandey SK, Wilson ME, Trivedi RH, et al. Pediatric cataract surgery and intraocular lens implantation: current techniques, complications and management. *Int Ophthalmol Clin* 2001;**41**:175–96.
- Ram J, Pandey SK. Infantile cataract surgery: current techniques, complications and their management. In: Dutta LC, ed. *Modern ophthalmology*. New Delhi: Jaypee Brothers, 2000:378–84.
- Wilson ME. The challenge of pediatric cataract surgery. *J AAPOS* 2001;**5**:265–6.
- Wilson ME. Anterior capsule management for pediatric intraocular lens implantation. *J Pediatr Ophthalmol Strabismus* 1999;**36**:1–6.
- Apple DJ, Ram J, Foster A, et al. Elimination of cataract blindness: a global perspective entering the new millennium. *Surv Ophthalmol* 2000;**45**:S1–160.
- Good WV. Cataract surgery in young children. *Br J Ophthalmol* 2001;**85**:254–5.
- Jensen AA, Basti S, Greenwald MJ, et al. When may the posterior capsule be preserved in pediatric intraocular lens surgery? *Ophthalmology* 2002;**109**:324–8.
- Wilson ME. Intraocular lens implantation: has it become the standard of care for children? (Editorial). *Ophthalmology* 1996;**103**:1719–20.
- Wilson ME, Apple DJ, Bluestein EC, et al. Intraocular lenses for pediatric implantation: biomaterials, designs and sizing. *J Cataract Refract Surg* 1994;**20**:584–91.
- Wilson ME, Bluestein EC, Wang XH. Current trends in the use of intraocular lenses in children. *J Cataract Refract Surg* 1994;**20**:579–83.
- Green SM, Clark R, Hostetler MA, et al. Inadvertent ketamine overdose in children: clinical manifestations and outcome. *Ann Emerg Med* 1999;**34**:492–7.
- Sudan Pun M, Thakur J, Poudyal G, et al. Ketamine anaesthesia for paediatric ophthalmology surgery in the developing world. *Br J Ophthalmol* 2003;(in press)
- Taylor D. Choice of surgical technique in the management of congenital cataract. *Trans Ophthalmol Soc UK* 1981;**101**:114–7.
- Chrousos GA, Parks MM, O'Neill JF. Incidence of chronic glaucoma, retinal detachment and secondary membrane surgery in pediatric aphakic patients. *Ophthalmology* 1984;**91**:1238–41.
- Keech RV, Tongue AC, Scott WE. Complications after surgery for congenital and infantile cataracts. *Am J Ophthalmol* 1989;**108**:136–41.
- Basti S, Ravishanker V, Gupta S. Results of a prospective evaluation of three methods of management of pediatric cataracts. *Ophthalmology* 1996;**103**:713–20.
- Eckstein M, Vijayalakshmi P, Gilbert C, et al. Randomized clinical trial of lensectomy versus lens aspiration and primary capsulotomy for children with bilateral cataract in south India. *Br J Ophthalmol* 1999;**83**:524–9.
- Yarston D, Wood M, Foster A. Results of cataract surgery in young children in east Africa. *Br J Ophthalmol* 2001;**85**:267–71.
- Buckley EG, Klombers LA, Seaber JH, et al. Management of the posterior capsule during pediatric intraocular lens implantation. *Am J Ophthalmol* 1993;**115**:722–8.
- Alexandrakis G, Peterseim MM, Wilson ME. Clinical outcomes of pars plana capsulotomy with anterior vitrectomy. *J AAPOS* 2002;**6**:163–7.
- Koch DD, Kohnen T. Retrospective comparison of techniques to prevent secondary cataract formation following posterior chamber intraocular lens implantation in infants and children. *J Cataract Refract Surg* 1997;**23**(Suppl):657–63.
- Vasavada A, Trivedi R. Role of optic capture in congenital cataract and intraocular lens surgery in children. *J Cataract Refract Surg* 2000;**26**:824–31.
- Venkataswamy G. Intraocular lens implantation in India. *Ophthalmic Surg* 1990;**21**:866–7.
- Dahan E. Pediatric cataract surgery. In: Yanoff M, Ducker JS, eds. *Ophthalmology*. St Louis, Mosby-Yearbook, 1998:30.1–30.6
- Spieler A, Desantik H. Refractive status in children after long-term follow-up of cataract surgery with intraocular lens implantation. *J Pediatr Ophthalmol Strabismus* 1999;**36**:25–9.
- Hutchinson AK, Wilson ME, Saunders RA. Outcomes and ocular growth rates after intraocular lens implantation in the first 2 years-of-life. *J Cataract Refract Surg* 1998;**24**:846–52.
- Zwaan J. Simultaneous surgery for bilateral pediatric cataracts. *Ophthalmic Surg Lasers* 1996;**27**:15–20.
- Totan Y, Bayramlar H, Cekic O, et al. Bilateral cataract surgery in adult and pediatric patients in a single session. *J Cataract Refract Surg* 2000;**26**:1008–11.
- Guo S, Nelson LB, Calhoun J, et al. Simultaneous surgery for bilateral congenital cataracts. *J Pediatr Ophthalmol Strabismus* 1990;**27**:23–5; discussion 26–7.
- Smith GT, Liu CS. Is it time for a new attitude to “simultaneous” bilateral cataract surgery? *Br J Ophthalmol* 2001;**85**:1489–96.



## Paediatric cataract blindness in the developing world: surgical techniques and intraocular lenses in the new millennium

M E Wilson, S K Pandey and J Thakur

*Br J Ophthalmol* 2003 87: 14-19

doi: 10.1136/bjo.87.1.14

---

Updated information and services can be found at:

<http://bjo.bmj.com/content/87/1/14.full.html>

---

*These include:*

### References

This article cites 39 articles, 11 of which can be accessed free at:

<http://bjo.bmj.com/content/87/1/14.full.html#ref-list-1>

Article cited in:

<http://bjo.bmj.com/content/87/1/14.full.html#related-urls>

### Email alerting service

Receive free email alerts when new articles cite this article. Sign up in the box at the top right corner of the online article.

---

### Notes

---

To request permissions go to:

<http://group.bmj.com/group/rights-licensing/permissions>

To order reprints go to:

<http://journals.bmj.com/cgi/reprintform>

To subscribe to BMJ go to:

<http://group.bmj.com/subscribe/>