

CLINICAL SCIENCE

Polymerase chain reaction analysis of aqueous humour samples in necrotising retinitis

T H C Tran, F Rozenberg, N Cassoux, N A Rao, P LeHoang, B Bodaghi

Br J Ophthalmol 2003;**87**:79–83

See end of article for authors' affiliations

Correspondence to:
B Bodaghi, MD, PhD,
Department of
Ophthalmology,
Pitié-Salpêtrière Hospital,
47–83 Boulevard de
l'Hôpital, 75013 Paris,
France; bahram.bodaghi@
psl.ap-hop-paris.fr

Accepted for publication
16 July 2002

Aim: To evaluate the diagnostic value of polymerase chain reaction (PCR) performed on aqueous humour for the detection of viral DNA in patients with necrotising herpetic retinitis.

Methods: The clinical features and laboratory results of 22 patients (29 eyes) presenting with necrotising herpetic retinitis between March 1999 and June 2001 were reviewed retrospectively. Aqueous humour was obtained after anterior chamber paracentesis and PCR was performed in all cases.

Results: Viral DNA was detected in the aqueous humour of 19 patients (86.4%). Epstein-Barr virus (EBV) seroconversion was evidenced in one additional patient. In the acute retinal necrosis (ARN) group (n = 19), varicella zoster virus (VZV) DNA was identified in six patients, herpes simplex virus 1 (HSV-1) DNA in two patients, herpes simplex virus 2 (HSV-2) DNA in four patients, and cytomegalovirus (CMV) genome in four patients. In the progressive outer retinal necrosis (PORN) group (n = 3), VZV DNA was detected in all patients. No sample was positive for more than one virus.

Conclusions: PCR analysis of aqueous humour in patients with clinical features of necrotising viral retinitis can provide specific aetiological orientation and the method appears to be safe and highly sensitive.

Acute retinal necrosis syndrome is characterised by peripheral necrotising retinitis, retinal arteritis, and a prominent inflammatory reaction in the vitreous and anterior chamber of apparently immunocompetent patients.¹ Progressive outer retinal necrosis (PORN) syndrome has been described as a similar syndrome with minimal inflammation in immunocompromised patients.² The term necrotising herpetic retinitis refers to a spectrum of diseases induced by herpesviruses (herpes simplex virus (HSV-1 and HSV-2), varicella zoster virus (VZV), cytomegalovirus (CMV), or Epstein-Barr virus (EBV)) that encompasses both acute retinal necrosis (ARN) and PORN syndromes.³

The diagnosis of necrotising herpetic retinitis is usually based on clinical findings and confirmed by a good response to antiviral therapy. However, clinical findings are sometimes not clear enough to make a definite diagnosis, making the best and most specific therapeutic strategy uncertain. The wrong decision not only causes a delay of adapted treatment and a preventable loss of vision, but also exposes the patients to side effects of an unnecessary medication.

Polymerase chain reaction (PCR) is a sensitive and specific technique, which has been performed successfully to detect viral DNA in ocular samples from immunocompetent and immunocompromised patients presenting with viral retinitis.^{4–7} However, most studies have investigated the diagnostic value of PCR performed on vitreous fluid. Paracentesis to obtain aqueous humour is much easier, safer, and less invasive than taking vitreous specimens. We wished to analyse whether PCR would be sensitive enough to detect viral DNA in minimal volumes of aqueous humour, in order to reach a rapid diagnosis and apply prompt specific treatment.

PATIENTS AND METHODS

Twenty two patients (29 eyes) with a diagnosis of ARN or PORN syndrome were treated at the department of ophthalmology (Pitié-Salpêtrière Hospital, Paris, France) between March 1999 and June 2001. The clinical diagnosis of ARN syndrome was based on characteristic clinical criteria described by the executive committee of the American Uveitis

Society: focal, well demarcated areas of retinal necrosis located in the peripheral retina; rapid, circumferential progression of necrosis; evidence of retinal vasculitis and a prominent inflammatory reaction in the vitreous and anterior chamber.³ The PORN cases were characterised by rapidly progressive, multifocal, deep retinal opacifications involving both the peripheral retina and the posterior pole. All cases showed mild intraocular inflammation. The ocular findings were virtually identical to those reported by Forster *et al.*² Atypical retinal necrosis, which did not respond to antiviral therapy (intravenous foscarnet), with aqueous humour PCR positive for *Toxoplasma gondii* and negative for herpesviruses were excluded.

Anterior chamber tap was performed on the day of admission. Aqueous humour, 100–150 µl, was aspirated, using a 30 gauge needle passing through the limbus. Informed consent was obtained from all patients.

Aqueous samples from 22 eyes of 22 patients with ARN or PORN syndrome were analysed for the presence of herpesviruses by PCR.^{8–9} As controls, 10 aqueous samples from patients with clinical features of an active uveitis were analysed. This group included toxoplasma uveitis (n = 6), primary intraocular lymphoma (n = 2), syphilis retinitis (n = 1), and sarcoidosis (n = 1).

PCR

Aqueous humour, 10–20 µl, were used for each PCR reaction. DNA was either phenol chloroform extracted using classic procedures or simply treated by boiling and ethanol precipitating the samples. A single PCR for HSV-1, HSV-2, and EBV was performed as previously described.⁸ Amplified products were visualised on ethidium stained agarose gels, then characterised with reference to their specific migration pattern before and after digestion with restriction enzymes *SmaI* and *BamHI*. The sensitivity of this technique was evaluated at 5×10^3 genome equivalents (GEq)/ml for HSV-1, and 2×10^3 GEq/ml for HSV-2 by a European quality control HSV test panel. Specific CMV and VZV PCR assays were performed using slightly modified published procedures while preserving the described sensitivities.^{9–11} Using the same technique, 2–20 copies of EBV

Table 1 Summary of clinical features of 22 patients with viral retinitis who underwent anterior chamber tap for aqueous humour PCR analysis for the detection of herpesviruses

Patients No	Age (years)	Sex	Medical history	Type, eye	Initial visual acuity	Final visual acuity	Extent of the retinitis, clock hours
1	38	M	None	BARN	RE = 20/25, LE = 20/63	RE = 20/32, LE = 20/80	peripheral, 9
2	82	F	Thoracic varicella zoster dermatitis	BARN	RE = 20/200, LE = 20/100	RE = 20/200, LE = 20/100	RE = peripheral, 12; LE = peripheral, 9
3	51	M	None	ARN, LE	20/40	20/25	peripheral, 2
4	32	M	Neonatal herpes simplex infections. Vision loss of RE at birth. ARN of LE 9 years earlier with three recurrences	ARN, LE	20/25	20/20	peripheral, 4
5	29	F	None	ARN, RE	CF	CF	peripheral, 6
6	45	M	None	ARN, LE	CF	CF	peripheral, 10
7	70	F	Ipsilateral varicella zoster dermatitis along the distribution of V cranial nerve. Non-Hodgkin's lymphoma	ARN, LE	20/40	20/40	peripheral, 6
8	64	M	Chronic lymphocytic leukaemia	ARN, RE	HM	HM	peripheral, 3; and central
9	31	M	None	BARN	RE = 20/50, LE = 20/200		RE = peripheral, 12; LE = peripheral, 3
10	45	F	None	ARN, RE	20/50	20/200	peripheral, 10
11	11	M	Traumatic retinal detachment of the right eye	ARN, LE	CF	CF	peripheral, 12
12	63	F	Optic neuropathy of the left eye	BARN	RE = 20/20, LE = 20/100	RE = 20/25, LE = 20/50	RE = peripheral, 4; LE = peripheral, 12
13	33	F	Treated by azathioprine and prednisolone for kidney transplant	ARN, LE	CF	CF	peripheral; 6
14	67	F	Treated by cyclophosphamide and prednisolone for pulmonary fibrosis	ARN, RE	20/60	20/30	peripheral, 12
15	44	M	AIDS, CD4 = 170	ARN, LE	CF	CF	peripheral, 4; and central
16	67	M	Chronic lymphocytic leukaemia with cyclophosphamide. Thoracic varicella zoster dermatitis 6 years earlier	ARN, LE	20/30	20/200	peripheral; 6
17	13	F	None	mild ARN, RE	20/50	20/20	peripheral, 12
18	13	F	ARN of RE 7 years earlier with vision loss	ARN, LE	20/32	20/20	peripheral and central, 2
19	20	M	ARN of LE 8 years earlier with vision loss	ARN, RE	20/20	20/20	peripheral, 3
20	37	M	Thoracic varicella zoster dermatitis during childhood. HIV negative. Diminished in vitro lymphocyte proliferation test	bilateral PORN	RE = 20/32, LE = HM	RE = 20/20, LE = vision loss	RE = peripheral, 3; LE = peripheral and central
21	42	M	AIDS, CD4 = 4	bilateral PORN	RE = 20/125, LE = HM	RE = HM, LE = HM	RE and LE = peripheral and central
22	40	M	Thoracic varicella zoster dermatitis. AIDS, CD4 = 13.	bilateral PORN	RE = 20/100, LE = 20/40	RE = HM, LE = HM	RE = peripheral, 5; LE = central

ARN = acute retinal necrosis; BARN = bilateral acute retinal necrosis; PORN = progressive outer retinal necrosis; CF = counting fingers; HM = hand movement.

DNA could be detected, as previously described. The sensitivity of the published CMV and VZV PCR tests was evaluated by serial dilution of infected cell culture supernatants, and reached 10^{-6} for VZV and 10^{-5} for CMV. Amplification products were detected on agarose gels, and their specificity was confirmed by hybridisation with digoxigenin labelled specific oligonucleotide probes.

RESULTS

An ARN syndrome was confirmed in 19 patients (23 eyes) according to criteria of the American Uveitis Society (Table 1).¹ Mean age was 44.1 years. Ten patients were men and nine were women. One patient was HIV positive with a CD4+ count of 170 cells \times $10^6/l$ (Fig 1, top left). One patient had a history of non-Hodgkin's lymphoma and was in remission following chemotherapy. Two patients had chronic lymphocytic leukaemia. Two patients were treated with immunosuppressive drugs and corticosteroids for kidney transplant and pulmonary fibrosis. Three patients had a previous history of ARN syndrome and were referred either for involvement of the fellow eye or for relapse of retinitis in the same eye. A previous history of herpes zoster was noted in three patients and of neonatal herpes simplex infection in one patient. The interval between onset of disease and admission to the department of ophthalmology was between 1 day and 1 week in six patients, between 1 week and 1 month in eight patients and was more than 1 month in five patients. Four patients had received antiviral therapy before the anterior chamber tap.

PORN was diagnosed in three male patients (six eyes). Mean age was 39.6 years. Two patients were HIV positive and

one was HIV negative. The CD4+ counts ranged from 4–13 cells/ μ l in HIV positive patients. In this group of patients, aqueous humour samples were obtained within 1 week after onset of symptoms.

PCR for detection of viral DNA from aqueous samples was performed in all 22 patients (aqueous humour samples, n = 24) (Table 2). The reaction was positive in 19/22 patients (86.4%). Two patients (Nos 6 and 21) underwent two successive anterior chamber paracentesis in the same eye because of a negative result following the first procedure. PCR performed on the second sample, which was taken 1 week later, proved positive (while these patients were taking intravenous foscarnet). No complication from anterior chamber paracentesis was noted. In patient 17, PCR was negative but anti-EBV IgM were detected in the serum and IgG titres significantly increased in serum obtained 4 weeks later. In this patient, anti-EBNA IgG were absent, suggesting recent EBV infection. Aqueous specimens were negative in two patients (Nos 12 and 13) who had received 2 and 10 days, respectively, of intravenous aciclovir therapy before the anterior chamber tap.

In the ARN syndrome group (n = 19), PCR detected HSV-1 in two cases, HSV-2 in four cases, VZV in six cases, CMV in four cases, and no viral DNA was found in three cases. In the PRN syndrome group (n = 3), VZV was detected in all cases. No viral DNA was detected in any aqueous sample from the control group patients.

DISCUSSION

The viral cause of ARN syndrome has been determined by previous studies using a variety of diagnostic techniques: electron microscopy,¹² immunocytochemistry,¹³ viral culture from

Table 2 Results of PCR analysis performed on aqueous humour

Patients No	Anterior chamber tap following the onset of symptoms	Antiviral use before sampling	PCR HSV-1	PCR HSV-2	PCR VZV	PCR CMV	PCR EBV
1	6 weeks	None	+	-	-	-	-
2	6 months	None	+	-	-	-	-
3	3 days	None	-	+	-	-	-
4	2 days	None	-	+	-	-	-
5	2 weeks	None	-	+	-	-	-
6	6 weeks	IV foscarnet for 1 week	-	+	-	-	-
7	3 days	None	-	-	+	-	-
8	6 months	None	-	-	+	-	-
9	1 month	None	-	-	+	-	-
10	2 weeks	None	-	-	+	-	-
11	4 days	None	-	-	+	-	-
12	1 month	None	-	-	+	-	-
13	2 months	None	-	-	-	+	-
14	1 month	None	-	-	-	+	-
15	5 days	None	-	-	-	+	-
16	1 month	Valaciclovir for 3 weeks	-	-	-	+	-
17	1 month	None	-	-	-	-	...*
18	3 days	IV aciclovir for 2 days	-	-	-	-	-
19	10 days	IV aciclovir for 10 days	-	-	-	-	-
20	5 days	None	-	-	+	-	-
21	1 week	IV foscarnet for 1 week	-	-	+	-	-
22	1 week	None	-	-	+	-	-

CMV = cytomegalovirus; HSV = herpes simplex virus; VZV = varicella zoster virus; + = positive reaction; - = negative reaction; IV = intravenous.

*IgM positive in the sera.

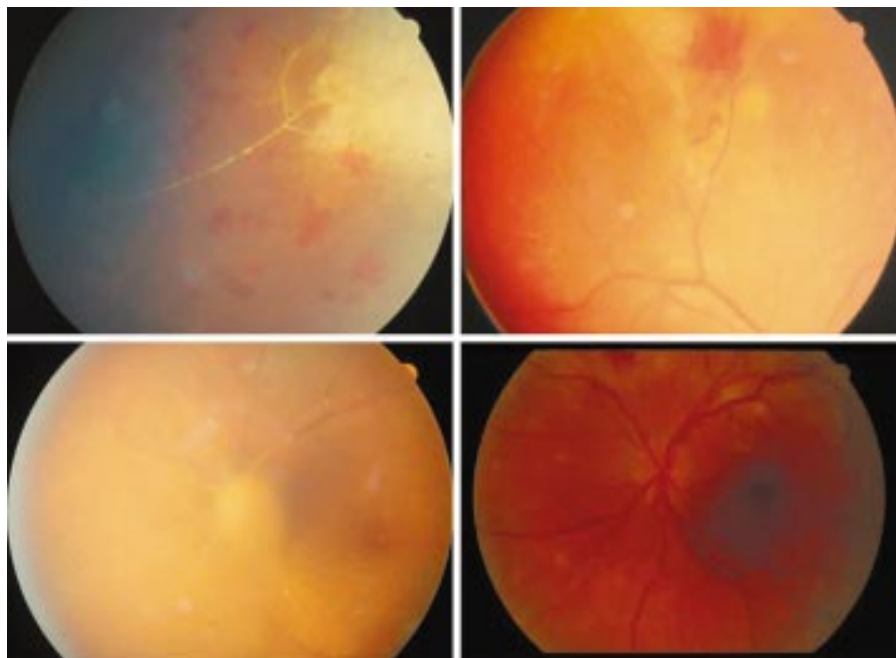


Figure 1 (Top left) Fundus photograph of patient 15. Vasculitis, retinal necrosis, and haemorrhages due to CMV in a HAART (highly active antiretroviral therapy), responder patient. (Top right) Peripheral retinal necrosis in patient 19. (Bottom left) Papillitis and diffuse arteritis due to HSV-1 in patient 1. (Bottom right) ARN syndrome with multiple necrotic satellite foci associated with haemorrhages.

intraocular specimens,^{13 14} serological analysis of serum and/or intraocular fluid,¹⁵⁻²¹ and, more recently, by PCR.^{6 20-25} These studies showed that most cases of ARN syndrome are caused by VZV, HSV-1, and HSV-2, and rarely by CMV. The PORN syndrome was first reported by Forster in 1990.² A member of the herpesvirus family was first suspected as a causative agent by electron microscopy.² Since then, VZV has been detected by PCR in most cases,^{26 27} although HSV-1 has recently been reported as a cause.²⁸

In a study by Ganatra *et al*⁶ who used PCR from vitreous and aqueous samples to detect viral DNA in 28 patients with ARN syndrome, VZV was detected in 13 cases (46%), HSV-1 in

seven cases (25%), HSV-2 in six cases (21.4%), and CMV in one case (3.6%). Mean age was 57.2 years in the VZV group, 44.2 in the HSV-1 group, 26.8 in the HSV-2 group. In Japan, Ichikawa *et al*²³ determined the viral cause of Kirisawa uveitis in a series of 44 patients (50 eyes) using IgG titres and/or PCR. They found that VZV was the pathogenic organism in 37 eyes (70%) of 31 patients and HSV in 13 eyes (30%) of 13 patients. Mean age was 47.9 years in the VZV group and 34.4 in the HSV group. HSV-2 seems also to have a high prevalence in ARN syndrome associated with HSV in Japan.²⁴

In our study of 19 patients with ARN, VZV was found in six cases (31.6%), HSV-1 in two cases (10.5%), HSV-2 in four cases

(21%), CMV in four cases (21%), and EBV was highly suspected in one case (5.2%). Mean age was 47.3 years in the VZV group, 46.2 in the HSV group, and 52.8 years in the CMV group. The high prevalence of HSV in the ARN syndrome was thus more like that reported by Ganatra *et al*, than that reported by Ichikawa *et al*. There were also more cases of CMV in this group. In addition, patients were older and all immunodeficient: three were treated with immunosuppressive drugs and one was HIV positive. However, our series requires more cases to determine a possible association between the patient's age and virus type.

Patient 17 was a 13 year old girl presenting with a mild form of ARN syndrome concomitant with EBV primary infection. Recently, one case of ARN has been reported in an HIV negative homosexual man with increased titres of anti-EBV-IgG, anti-EBV nuclear and early antigens who suffered from EBV infection and pericarditis 15 years earlier. In this case, however, PCR of intraocular fluid was not performed.²⁹ EBV should thus be considered as a potential cause of ARN syndrome and sought by serological and/or PCR analysis.

In our patients with PORN syndrome, VZV was detected in all cases. This result was similar to others studies.²²⁻²⁷

Patients 18 and 19 (Fig 1, top right) had received aciclovir therapy before anterior chamber tap, which may explain negative PCR results. Indeed, antiviral therapy may decrease viral replication below the threshold of PCR sensitivity.^{7,8} Although no viral DNA was detected, the final diagnosis of herpesvirus retinitis was most likely, since the disease resolved after foscarnet treatment with good final visual acuity. In contrast, for patients 6 and 21, PCR performed on the first aqueous sample was negative but became positive on a second sample obtained 1 week later, although these patients were both treated with intravenous foscarnet. These results suggest that antiviral therapy for a week does not prevent detection of viral DNA by PCR in aqueous humour. Previous studies showed that in spite of antiviral treatment, PCR from ocular specimens of AIDS patients with CMV retinitis were positive.^{5,7,21} Interestingly, similar findings were observed in cerebrospinal fluid of patients with herpes simplex encephalitis. In this group of patients, HSV-DNA was detected in half of cases during the second week of the disease.⁸

Previous studies that have analysed the viral cause of necrotising herpetic retinitis by PCR used only vitreous samples,^{30,31} aqueous, and/or vitreous samples.^{6,20-22,25} To our knowledge, this study is the largest monocentric case series of necrotising herpetic retinitis in Europe with a viral cause as determined by PCR of aqueous humour within a short (3 year) period.

Although the diagnosis of necrotising retinitis is based on clinical findings, the presentation is in some cases not clear enough and early viral DNA detection by PCR may be helpful in such cases. The results of this study are encouraging, since they indicate that amplification of DNA in aqueous humour is sensitive enough to become an appropriate method for detecting the causative agent of necrotising herpetic retinitis. Anterior chamber paracentesis is preferable to pars plana vitreous biopsy in many cases, since it is easier and more convenient to perform in an emergency. Side effects of anterior chamber taps are rare (hyphaema, cataract secondary to perforation of the lens capsule), and no complication was observed after paracentesis in this study or in previous reports.^{20,22,32-35} Advances in DNA extraction procedures and PCR techniques have contributed to reducing the time waiting for results, which can be available within 24-48 hours. The benefit of a reliable result leading to a rapid diagnosis and accurate treatment outweighs theoretical risks. However, aqueous samples may contain less viral DNA than vitreous for PCR amplification. An initial negative result should lead to repeated paracentesis, especially in patients who are on antiviral therapy for a presumptive diagnosis of viral retinitis.

Although clinical features observed in ARN patients may be highly suggestive of a herpesvirus aetiology, they do not allow

differentiating HSV from VZV caused cases. Ichikawa *et al*²³ reported 44 cases of Kirisawa-type uveitis (KU) and found that the VZV group included a significantly greater number of severe and serious cases than the HSV group. Only 32% of VZV-KU and 67% of HSV-KU eyes had a final visual acuity of greater than 0.5. This report suggests that VZV induced ARN syndrome may be more severe than HSV induced ARN syndrome and may require intensive antiviral therapy.

In summary, our results indicate that reliable identification of the pathogenic agent was possible by PCR analysis of aqueous samples in 86.4% of cases with necrotising retinitis. Moreover, early use of such highly sensitive and specific PCR based assays may not only contribute to the diagnosis, but also to the management of patients with necrotising herpetic retinitis.

Authors' affiliations

T H C Tran, N Cassoux, P LeHoang, B Bodaghi, Department of Ophthalmology, Pitié-Salpêtrière Hospital, Paris, France

F Rozenberg, Department of Virology, Saint Vincent de Paul Hospital, Paris, France

N A Rao, Doheny Eye Institute, University of Southern California, Los Angeles, USA

REFERENCES

- Holland GN. Standard diagnostic criteria for the acute retinal necrosis syndrome. *Am J Ophthalmol* 1994;**117**:663-7.
- Forster DJ, Dugel PU, Frangieh GT, *et al*. Rapidly progressive outer retinal necrosis in the acquired immunodeficiency syndrome. *Am J Ophthalmol* 1990;**110**:341-8.
- Guex-Crosier Y, Rochat C, Herbert CP. Necrotizing herpetic retinopathies. A spectrum of herpes virus-induced diseases determined by the immune state of the host. *Ocul Immunol Inflamm* 1997;**5**:259-65.
- Doornbal P, Seerp Baarsma G, Quint WG, *et al*. Diagnostic assays in cytomegalovirus retinitis: detection of herpesvirus by simultaneous application of the polymerase chain reaction and local antibody analysis on ocular fluid. *Br J Ophthalmol* 1996;**80**:235-40.
- Fox GM, Crouse CA, Chuang EL, *et al*. Detection of herpesvirus DNA in vitreous and aqueous specimens by the polymerase chain reaction. *Arch Ophthalmol* 1991;**109**:266-71.
- Ganatra JB, Chandler D, Santos C, *et al*. Viral causes of the acute retinal necrosis syndrome. *Am J Ophthalmol* 2000;**129**:166-72.
- McCann JD, Margolis TP, Wong MG, *et al*. A sensitive and specific polymerase chain reaction-based assay for the diagnosis of cytomegalovirus retinitis. *Am J Ophthalmol* 1995;**120**:219-26.
- Rozenberg F, Lebon P. Amplification and characterization of herpesvirus DNA in cerebrospinal fluid from patients with acute encephalitis. *J Clin Microbiol* 1991;**29**:2412-17.
- Puchhammer-Stockl E, Popow-Kraupp T, Heinz FX, *et al*. Detection of varicella-zoster virus DNA by polymerase chain reaction in the cerebrospinal fluid of patients suffering from neurological complications associated with chicken pox or herpes zoster. *J Clin Microbiol* 1991;**29**:1513-6.
- Gozlan J, Salord JM, Roulet E, *et al*. Rapid detection of cytomegalovirus DNA in cerebrospinal fluid of AIDS patients with neurologic disorders. *J Infect Dis* 1992;**166**:1416-21.
- Lionnet F, Pulik M, Genet P, *et al*. Myelitis due to varicella-zoster virus in two patients with AIDS: successful treatment with acyclovir. *Clin Infect Dis* 1996;**22**:138-40.
- Schwartz HN, Cashwell F, Hawkins HK, *et al*. Necrotizing retinopathy with herpes zoster ophthalmicus: a light and electron microscopic study. *Arch Pathol Lab Med* 1976;**100**:386-91.
- Culbertson WW, Blumenkranz MS, Pepose JS, *et al*. Varicella zoster virus is a cause of the acute retinal necrosis syndrome. *Ophthalmology* 1986;**93**:559-69.
- Duker JS, Nielsen JC, Eagle RC, *et al*. Rapidly progressive acute retinal necrosis secondary to herpes simplex virus, type 1. *Ophthalmology* 1990;**97**:1638-43.
- El Azazi M, Samuelsson A, Linde A, *et al*. Intrathecal antibody production against viruses of the herpesvirus family in acute retinal necrosis syndrome. *Am J Ophthalmol* 1991;**112**:76-82.
- Pepose JS, Flowers B, Stewart JA, *et al*. Herpesvirus antibody levels in the etiologic diagnosis of the acute retinal necrosis syndrome. *Am J Ophthalmol* 1992;**113**:248-56.
- Chung YM, Liu JH, Yeh TS. Acute retinal necrosis syndrome. *Chung Hua I Hsueh Tsa Chih (Taipei)* 1993;**51**:116-22.
- Rochat C, Herbert CP. Acute retinal necrosis syndrome. Lausanne cases, review of the literature and new physiopathogenetic hypothesis. *Klin Monatsbl Augenheilkd* 1994;**204**:440-9.
- De Boer JH, Luyendijk L, Rothova A, *et al*. Detection of intraocular antibody production to herpesviruses in acute retinal necrosis syndrome. *Am J Ophthalmol* 1994;**117**:201-10.
- De Boer JH, Verhagen C, Bruinenberg M, *et al*. Serologic and polymerase chain reaction analysis of intraocular fluids in the diagnosis of infectious uveitis. *Am J Ophthalmol* 1996;**121**:650-8.

- 21 **Abe T**, Tsuchida K, Tamai M. A comparative study of the polymerase chain reaction and local antibody production in acute retinal necrosis syndrome and cytomegalovirus retinitis. *Graefes Arch Clin Exp Ophthalmol* 1996;**234**:419–24.
- 22 **Garweg J**, Bohnke M. Varicella-zoster virus is strongly associated with atypical necrotizing herpetic retinopathies. *Clin Infect Dis* 1997;**24**:603–8.
- 23 **Ichikawa T**, Sakai J, Yamauchi Y, *et al*. A study of 44 patients with Kirisawa type uveitis. *Nippon Ganka Gakkai Zasshi* 1997;**101**:243–7.
- 24 **Itoh N**, Matsumura N, Ogi A, *et al*. High prevalence of herpes simplex virus type 2 in acute retinal necrosis syndrome associated with herpes simplex virus in Japan. *Am J Ophthalmol* 2000;**129**:404–5.
- 25 **Nishi M**, Hanashiro R, Mori S, *et al*. Polymerase chain reaction for the detection of the varicella-zoster genome in ocular samples from patients with acute retinal necrosis. *Am J Ophthalmol* 1992;**114**:603–9.
- 26 **Nogueira ML**, Siqueira RC, Freitas N, *et al*. Detection of herpesvirus DNA by the polymerase chain reaction (PCR) in vitreous samples from patients with necrotising retinitis. *J Clin Pathol* 2001;**54**:103–6.
- 27 **Pavesio CE**, Mitchell SM, Barton K, *et al*. Progressive outer retinal necrosis (PORN) in AIDS patients: a different appearance of varicella-zoster retinitis. *Eye* 1995;**9**:271–6.
- 28 **Kashiwase M**, Sata T, Yamauchi Y, *et al*. Progressive outer retinal necrosis caused by herpes simplex virus type 1 in a patient with acquired immunodeficiency syndrome. *Ophthalmology* 2000;**107**:790–4.
- 29 **Kramer S**, Brummer C, Zierhut M. Epstein-Barr virus associated acute retinal necrosis. *Br J Ophthalmol* 2001;**85**:114.
- 30 **Knox CM**, Chandler D, Short GA, *et al*. Polymerase chain reaction-based assays of vitreous samples for the diagnosis of viral retinitis. Use in diagnostic dilemmas. *Ophthalmology* 1998;**105**:37–44; discussion 44–5.
- 31 **Short GA**, Margolis TP, Kuppermann BD, *et al*. A polymerase chain reaction-based assay for diagnosing varicella-zoster virus retinitis in patients with acquired immunodeficiency syndrome. *Am J Ophthalmol* 1997;**123**:157–64.
- 32 **Verbraak FD**, Galema M, van den Horn GH, *et al*. Serological and polymerase chain reaction-based analysis of aqueous humour samples in patients with AIDS and necrotizing retinitis. *AIDS* 1996;**10**:1091–9.
- 33 **Baarsma GS**, Luyendijk L, Kijlstra A, *et al*. Analysis of local antibody production in the vitreous humor of patients with severe uveitis. *Am J Ophthalmol* 1991;**117**:201–10.
- 34 **Kijlstra A**. The value of laboratory testing in uveitis. *Eye* 1990;**4**:732–6.
- 35 **Luyendijk L**, vd Horn GJ, Visser OH, *et al*. Detection of locally produced antibodies to herpes viruses in the aqueous of patients with acquired immune deficiency syndrome (AIDS) or acute retinal necrosis syndrome (ARN). *Curr Eye Res* 1990;**9**:7–11.

Readers' favourite

Top 10

Click on the "Top 10" button on the homepage to see which are the best read articles each month

www.bjophthalmol.com



Polymerase chain reaction analysis of aqueous humour samples in necrotising retinitis

T H C Tran, F Rozenberg, N Cassoux, et al.

Br J Ophthalmol 2003 87: 79-83

doi: 10.1136/bjo.87.1.79

Updated information and services can be found at:

<http://bjo.bmj.com/content/87/1/79.full.html>

References

These include:

This article cites 31 articles, 8 of which can be accessed free at:

<http://bjo.bmj.com/content/87/1/79.full.html#ref-list-1>

Article cited in:

<http://bjo.bmj.com/content/87/1/79.full.html#related-urls>

Email alerting service

Receive free email alerts when new articles cite this article. Sign up in the box at the top right corner of the online article.

Topic Collections

Articles on similar topics can be found in the following collections

[Retina](#) (1217 articles)

Notes

To request permissions go to:

<http://group.bmj.com/group/rights-licensing/permissions>

To order reprints go to:

<http://journals.bmj.com/cgi/reprintform>

To subscribe to BMJ go to:

<http://group.bmj.com/subscribe/>