

PostScript

LETTERS

Unusual case of residual cortical lens matter in anterior chamber

Modern cataract surgery does not allow for any residual cortical matter in the anterior or posterior chamber, not even in the capsular bag. But for a beginner, a residual cortex in the eye is preferable to a ruptured posterior capsule and its associated complications. Therefore, the surgeon can stop and allow a minor complication (retained cortical material) to prevent posterior capsular rupture.

Case report

A 52 year old female patient was operated for posterior subcapsular cataract in her right eye. Her left eye had previously gone into phthisis bulbi 5 years earlier; she underwent a 360° buckling with vitreoretinal surgery in her left eye for traumatic total retinal detachment 6 years earlier.

The surgery was performed by a resident eye surgeon who was in the learning stage of phacoemulsification. During cortical aspiration, the matter at the 12 o'clock position was proving difficult to handle for the surgeon. The surgeon therefore thought, in the best interest of the patient, that the amount of sub-incisional cortical matter (approximately 2 clock hours, extending up to the capsulorhexis margin towards the centre) would absorb over time. He did not take the risk of further manipulations and getting a posterior capsular tear.

The surgeon increased the size of the corneal incision and implanted the all-PMMA (Single-piece, Biconvex, Mod C Step Vault, from AI Optics Ltd, India) intraocular lens. (The patient could not afford any other lens and the above lens is available free of cost for deserving patients in our centre.) The wound was closed with 10/0 monofilament Nylon sutures.

The first postoperative day did not reveal any unusual inflammation. The eye was quiet on third postoperative day (first follow up). At second follow up (10th postoperative day), the operated eye revealed a white, fluffy mass (Fig 1) in the anterior chamber. This cotton-wool ball-like mass was diagnosed to be retained sub-incisional cortical lens matter

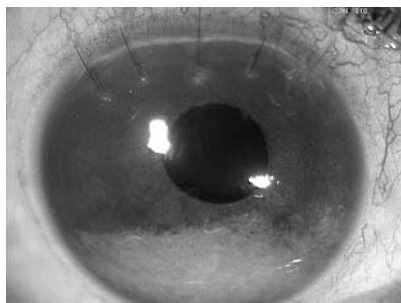


Figure 1 Retained cortical lens matter in the anterior chamber.

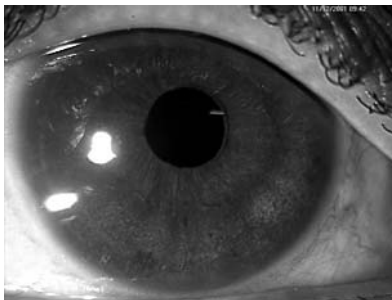


Figure 2 Eight week postoperative status of the same eye.

based on normal anterior segment and fundus findings. The IOP was 28 mm Hg in her right eye. Because of the raised IOP and the one eyed status of the patient, immediate removal of cortical lens matter was planned. The side port was used to aspirate cortical matter with topical 0.5% oxybuprocaine (proparacaine) eye drops, using a 23 gauge canula. Postoperatively there was normalisation (off oral medications) of raised IOP within 48 hours. All sutures were removed after 6 weeks (Fig 2). The final best corrected visual acuity was 6/6.

Comment

The case is reported to highlight the importance of complete removal of cortical matter. The reason for difficulty in aspirating sub-incisional cortex in our case was inferiorly decentralised capsulorhexis and corneal oedema at the incision site. Other reasons that can hamper the removal of such cortex could be positive vitreous pressure, long tunnel, fluid leakage due to divarication of incision lips, small capsulorhexis, probable miosis and corneal folds.¹ The raised IOP in our case could be due to obstruction of trabecular meshwork by lens debris and inflammatory components in the form of foamy macrophages and lens particles² and reduction of outflow facility of the anterior chamber angle. Lens debris was seen as a fluffy pseudohypopyon layer in the inferior anterior chamber; this can cause a mistaken diagnosis of postoperative endophthalmitis if associated with anterior uveitis.

The full visual recovery seen in our case could be attributed to immediate surgical intervention. The lens cortex retained in the eye after cataract extractions usually undergoes lyses by aqueous but may persist.³ The techniques that can be used to aspirate such sub-incisional cortex could be widening of the incision, mobilisation of the mass with IOL, verticalisation of irrigation/aspiration tip, using 180° bent canula by Binkhorst, bent and angled coaxial cannulas, and bimanual (one for irrigation and one for aspiration) technique.

G Prakash, A Kumar, A Purohit, A Kumar

Dr Rajendra Prasad Centre for Ophthalmic Sciences, All India Institute of Medical Sciences, Ansari Nagar, New Delhi - 110029, India

Correspondence to: Dr Gunjan Prakash, 8/12, Residential Hostel, AllMS, New Delhi - 110029, India, gunjan_prakash@rediffmail.com

Accepted for publication 6 February 2003

The authors do not have any proprietary or financial interest in any product. The did not receive any public or private support.

References

- 1 Buratto L, ed. *Phacoemulsification: principles and technique*. Thorofare, NJ: Slack Inc, 1998:178.
- 2 Epstein DL, Jedziniak JA, Grant WM. Obstruction of aqueous outflow by lens particles and by heavy-molecular-weight soluble lens proteins. *Invest Ophthalmol Vis Sci* 1978;17:272-7.
- 3 Jaffe NS, Jaffe MS, Jaffe GF. Retained lens matter. In: *Cataract surgery and its complications*. 6th ed. St Louis: Mosby, 1997:405.

Posterior segment complications of graft versus host disease after bone marrow transplantation

The efficacy of bone marrow transplantation (BMT) for the treatment of selected diseases of the haemopoietic system such as chronic myeloid leukaemia (CML) is well recognised. Graft versus host disease (GVHD) is however a common and potentially life threatening complication of this treatment, occurring in up to 75% of cases. It is thought to arise when immunocompetent donor T lymphocytes mount an immune response against host tissues. GVHD is characterised by a triad of enteritis, dermatitis, and hepatitis, but almost all organs may be targeted. Ocular involvement is frequently seen but is usually limited to the anterior segment. Posterior segment manifestations are rare.

This report describes two cases of GVHD with unusual posterior segment involvement that highlight the diversity of presentations in this condition.

Case 1

A 45 year old white male presented with progressive bilateral blurred vision and floaters 10 months post-BMT for CML. He had no history of ocular disease. His symptoms started 10 days after discontinuation of cyclosporin A as a routine protocol and were accompanied by alopecia, poliosis, vitiligo, and oral mucositis. A presumptive diagnosis of acute GVHD was made and cyclosporin restarted together with prednisolone. His other medications were azathioprine, aciclovir, fluconazole, and ranitidine.

Best corrected visual acuity was 6/9 bilaterally, with no afferent pupillary defect. There was no evidence of inflammation in anterior segments or vitreous and normal intraocular pressures. There was mild disc pallor with swelling and surrounding radial choroidal folds and several pale subretinal perifoveal lesions on the left. Systemic examination revealed widespread patchy alopecia with poliosis, vitiligo of the arms, and mild oral mucositis. Fluorescein angiography showed mild dilatation of the disc capillaries and extensive focal leakage from the retinal pigment epithelium, but no evidence of cystoid macular oedema. Ultra-

sonography showed a thickened posterior sclera. Optical coherence tomography (OCT) showed subretinal fluid bilaterally. Cerebral magnetic resonance imaging (MRI) and lumbar puncture revealed no abnormalities.

The clinical appearances were consistent with posterior scleritis together with a diffuse retinal pigment epitheliopathy. A reducing regimen of high dose steroids in combination with acetazolamide resulted in clinical improvement and visual stabilisation.

Case 2

A 31 year old white female underwent total body irradiation and BMT for $\alpha\beta$ -T cell splenic lymphoma. One month later she developed acute GVHD related erosive enteropathy resulting in life threatening exsanguination. Following successful resuscitation (which precipitated admission to intensive care for 6 weeks), she noted blurred left eye vision and described difficulty in dark adaptation and differentiating between shades of grey; there was right strabismic amblyopia. The patient's medication comprised aciclovir, cyclosporin, penicillin, propranolol, and lansoprazole.

Visual acuity was 6/18 and N14 with the right eye, and 6/12 and N5 with the left. Colour vision was normal and visual fields were full. There was no afferent pupillary defect. The anterior chambers and vitreous were quiet. The optic discs were normal. At both maculas (Fig 1), there were deep subretinal cream coloured spots and retinal thickening and OCT evidence of subretinal fluid without cystoid changes. Fluorescein angiography showed a few hyperfluorescent spots consistent with focal retinal pigment epithelium dysfunction. Electrodiagnostic tests identified diffuse rod dysfunction.

Since there was biochemical evidence of renal impairment, acetazolamide was considered to be contraindicated to treat the subretinal fluid. By 4 months, the best corrected visual acuities were 6/12–2 right; 6/6+2 left. Repeat electrophysiology was unchanged, however by ten months the full field electroretinograms had improved to normal limits.

Comment

GVHD is presumed to be caused by donor T lymphocytes recognising minor histocompatibility antigens on recipient tissues that are then subjected to CD8-T lymphocyte mediated attack. Commonly reported ocular manifestations include pseudomembranous conjunctivitis, keratoconjunctivitis sicca, corneal epitheliopathy, and cataract.¹ Posterior segment involvement is rare and includes cotton wool spots² as well as central serous chorioretinopathy.³

In both of our cases, there seems to be a striking temporal association between the onset of visual symptoms and an adverse event in the course of the disease. In case 1, in whom the cessation of cyclosporin resulted in acute GVHD, the ocular findings were consistent with scleritis, a feature only once previously reported.⁴ Postmortem studies have demonstrated choroidal infiltrates in GVHD patients containing histiocyte-like large eosinophils⁵ and clinically these may be represented by the pale perifoveal lesions observed in the left eye. Subsequently this patient was shown to be HLA-DR4 positive, a finding common in individuals with Harada's disease and frequently associated with chronic GVHD.⁶

By contrast, the ocular findings in the second case were not a result of acute but a consequence of previous life threatening GVHD during which exsanguination occurred. While interruption of blood flow

to the optic nerve or visual cortex can account for visual loss following extreme haemorrhage, retinal ischaemia has also been documented.⁵ The rod photoreceptor system appears most vulnerable,⁷ a feature consis-

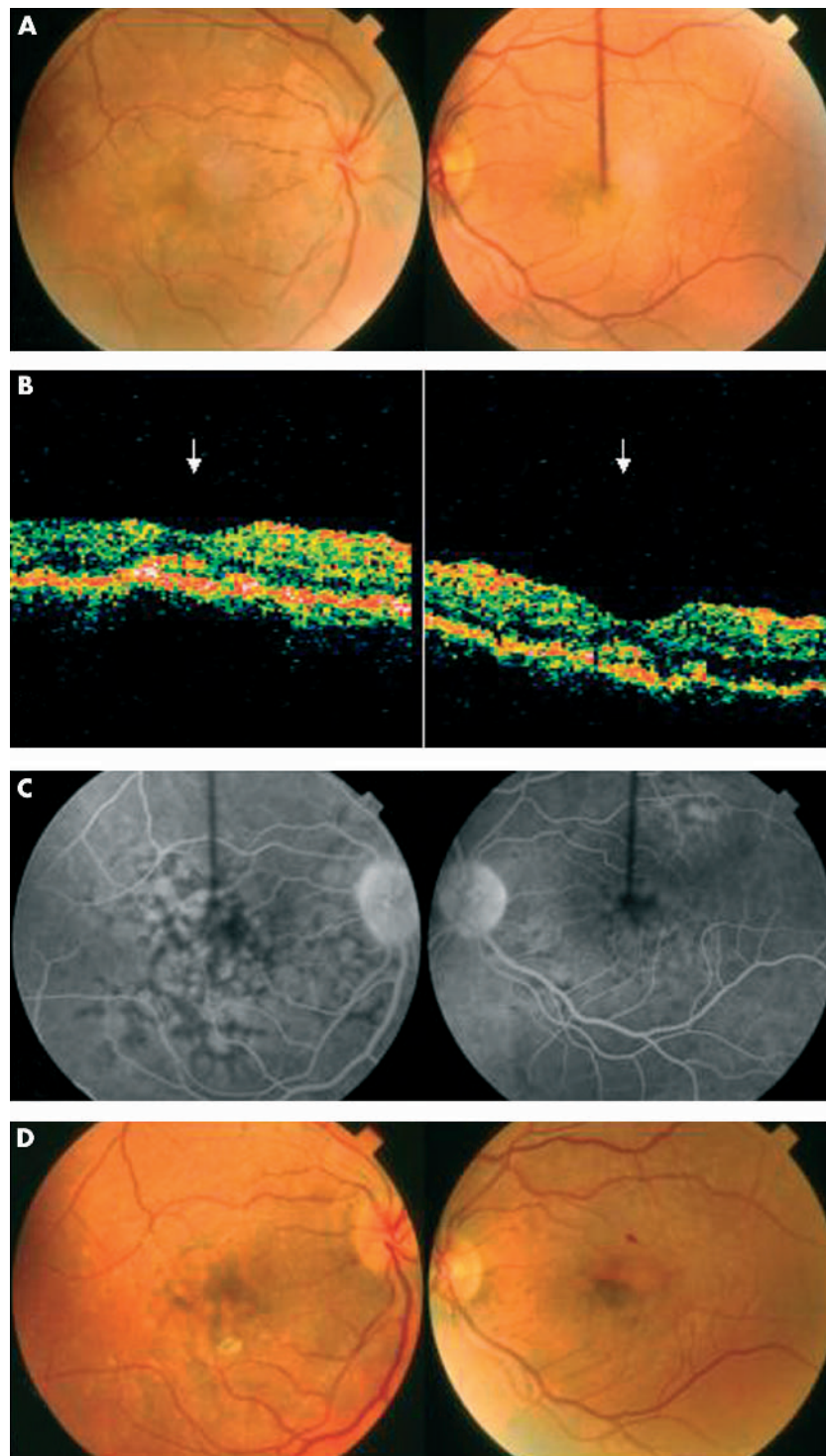


Figure 1 Images of case 2 (in each case right eye on the right). (A) Colour fundal photographs at presentation, showing deep subretinal cream coloured spots and overlying retinal thickening. (B) Optical coherence tomography of each macula (foveae arrowed) at presentation showing evidence of subretinal fluid without cystoid changes. (C) Fluorescein angiography (later arteriovenous phase) at presentation showing a few hyperfluorescent spots consistent with focal RPE dysfunction. (D) Colour fundal photographs 4 months later showing irregular pigmentation at the level of the retinal pigment epithelium.

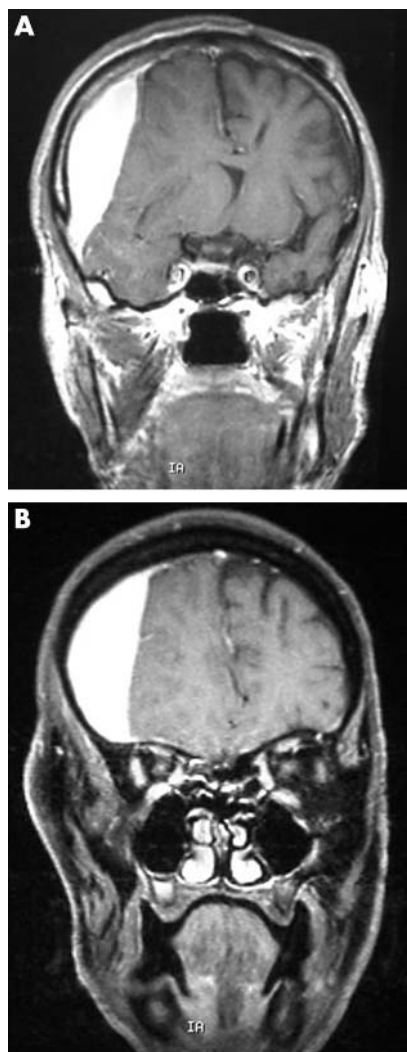


Figure 2 Magnetic resonance imaging (T1 weighted coronal) of (A) right subdural haematoma with significant right to left midline shift but without direct compression of the prechiasmatic optic nerves and (B) without compression of the intraorbital optic nerves.

ventriculoperitoneal shunt placed in January 2001. Eleven months following placement of the shunt, the patient presented with ataxia and headaches but no visual complaints. A computed tomograph (CT) scan showed a right subdural haematoma measuring 2.8 cm on coronal section, and 150 ml of blood were drained via a burr hole.

One month following the drainage procedure, the patient presented to the hospital with a complaint of sudden, painless loss of vision in his left eye occurring 24 hours earlier. The patient had a left afferent pupillary defect with best corrected vision of 20/30 in his right eye and hand movements in his left eye. Extraocular movements were full, and the patient had normal colour vision in his right eye. Slit lamp examination showed only trace nuclear sclerosis cataracts bilaterally. Fundus examination was also normal, with no evidence of optic disc oedema or pallor in either eye (Figs 1A, B).

Automated perimetry revealed a constricted field in the right eye and severe, global depression in the left eye (Fig 1C).

Magnetic resonance imaging (MRI) of the brain showed that the right subdural haematoma was still present but was decreased in size to 2.1 cm on coronal section (Fig 2A) compared to the study performed 1 month earlier. No intraorbital abnormalities were present, and the optic nerves and chiasm appeared free of direct compression by the haematoma. The blood did not appear to surround the optic nerves (Fig 2B). The patient's haematocrit and blood pressure remained within normal limits during the initial presentation and subsequent treatment. The patient underwent craniotomy with further drainage of the subdural haematoma. After 6 months, the patient's vision in the left eye improved to 20/200. Follow up perimetry showed less constriction on the right and improved performance on the left (Fig 1D). Funduscopy examination revealed mild optic nerve pallor in the left eye and a normal appearing right optic nerve.

Comment

This case represents a rare example of anterior pathway vision loss due to subdural haematoma. Most cases of vision loss with subdural haematoma affect the posterior visual pathway, with mechanisms including occipital infarct and compression of the posterior cerebral artery during trans-tentorial herniation.^{1,2} Posterior lesions may present with anterior signs—for example, optic atrophy was seen in three patients with occipital infarcts, two of whom initially presented with severe disc oedema.¹ Necropsy studies have shown that trans-tentorial herniation can result in damage at the level of the optic tract, chiasm, or optic nerves.²

The anterior visual pathway can be compromised directly by gyrus herniation into the suprasellar cistern, a mechanism associated with meningiomas.³ Prechiasmatic vision loss due to intracranial optic nerve infarction has also been reported in the setting of subdural haematoma; in this case the mechanism was presumably due to direct compression of the nerve against basal skull structures, although this specific radiographic finding was not described.⁴

The precise mechanism of anterior pathway vision loss due to subdural haematoma in our patient, as well as in the few previous reports, remains poorly understood.^{1,4} MRI showed no signs of blood in the orbits, direct compression of the optic nerves or chiasm, or gyrus herniation into the suprasellar cistern. The occipital lobes also appeared normal. Right to left midline shift due to the right sided haematoma was present, probably leading to vascular compromise or nerve compression that could not be visualised on MRI. Visual improvement following chiasmatic decompression of mass lesions has been reported, and this mechanism may explain our patient's improved visual acuity and peripheral fields following the drainage of the haematoma.⁵ Surprisingly, the subdural haematoma in our patient was smaller at the time of onset of visual symptoms than it had been 1 month earlier.

Subdural haematomas can affect vision through compression or vascular compromise at many points along the visual pathway. This case illustrates that optic neuropathy can occur late in the setting of a subdural haematoma, after the volume of the haematoma has begun to decrease. Because of the many ways in which patients with subdural haematomas can lose vision, they require

close follow up, and a sudden change in vision necessitates immediate radiological testing, ophthalmological examination and, possibly, urgent surgical intervention and drainage.

D A Hollander, J M Stewart

Department of Ophthalmology, University of California, San Francisco, CA, USA

Correspondence to: Jay M. Stewart, MD, University of California, San Francisco, Department of Ophthalmology, 10 Koret Way, Suite K-301, San Francisco, CA 94143, USA; ne62@yahoo.com

Accepted for publication 28 February 2003

References

- 1 Keane JR. Blindness following tentorial herniation. *Ann Neurol* 1980;**8**:186–90.
- 2 Lindenberg R, Walsh FB. Vascular compressions involving intracranial visual pathways. *Trans Am Acad Ophthalmol Otolaryngol* 1964;**68**:677–94.
- 3 Klingele TG, Gado MH, Burde RM, et al. Compression of the anterior visual system by the gyrus rectus: case report. *J Neurosurg* 1981;**55**:272–5.
- 4 Skarf B, Davis RL, Birsner HA, et al. Intracranial optic nerve infarction from subdural hematoma: clinical and neuropathological findings. *Arch Neurol* 1984;**41**:58–60.
- 5 Cohen AR, Cooper PR, Kupersmith MJ, et al. Visual recovery after transsphenoidal removal of pituitary adenomas. *Neurosurg* 1985;**17**:446–52.

Surodex in paediatric cataract surgery

Paediatric cataract surgery is associated with a high incidence of postoperative inflammation.^{1–3} Intensive topical steroid therapy is still relied upon as the conventional mode of prevention and treatment.^{1–4} Frequently, adjuvant systemic^{2–5} and/or periocular steroids^{3–5} may be required for further control, particularly if the child has a history of, or is at risk of, uveitis (for example, microphthalmos).^{5–9} Non-compliance and missed application of steroid drops into the eye impedes control of the postoperative uveitis.

The Oculex Drug Delivery System (DDS; Oculex Pharmaceuticals, Inc, Sunnyvale, CA, USA) is a biodegradable device that allows sustained drug release after insertion into the anterior chamber (AC). Surodex is a DDS with 60 µg of dexamethasone incorporated into the polymer matrix (poly(lactic-glycolic)-acid, PLGA) with sustained and controlled release of dexamethasone over 7 days, achieving higher intraocular drug levels than with conventional dexamethasone eye drops.¹⁰ Randomised controlled trials found Surodex to be as effective as 0.1% dexamethasone eye drops in the control of post-cataract surgery inflammation.^{10–12} Surodex is approved for use in cataract surgery in Singapore.

We reviewed retrospectively all paediatric patients who underwent cataract surgery with the insertion of one pellet of Surodex into the AC at the conclusion of surgery. Eighteen eyes of 13 patients (nine males and four females) were diagnosed with cataracts at a mean age of 57.4 months (range 1 day to 136 months). The mean age at surgery was 66.5 months (range 1 week to 139 months) and follow up period ranged from 6–18 months (mean 7.8 months). Factors predisposing to cataracts included hereditary cataracts (two), microphthalmos (three),

Table 1 Pseudophakic and aphakic groups

	Pseudophakic group	Aphakic group
No of eyes	11 (61.1%)	7 (38.9%)
Mean age at surgery	84.8 months	14.3 months
No of eyes with posterior capsular opening and anterior vitrectomy	7 (63.6%)	7 (100%)
No of eyes with intact posterior capsule	4 (36.4%)	0
Complications		
Intraoperative complications	0	0
Postoperative complications	4 (36.4%)	1 (14.3%)
1 Malposition of PCIOL	1	0
2 Vitreous strand in anterior chamber with peaked pupil	1	0
3 Posterior synechiae	1	0
4 Fibrinous inflammation	0	1
5 Raised intraocular pressure	1	0

severe atopic dermatitis (one) and traumatic cataract (one). The types of cataract included total/mature (seven), nuclear (two), lamellar (three), subcapsular (two), posterior lenticonus (two), and posterior polar (two).

All eyes underwent lens aspiration through can opener anterior capsulotomy or continuous curvilinear capsulorhexis (CCC) under general anaesthesia. Fourteen eyes had either posterior capsulotomy (with the vitrectomy cutter) or a posterior CCC (surgeon's preference). Anterior vitrectomy was done in 13 eyes. Eleven eyes (61.1%) were implanted with a foldable intraocular lens (IOL) (Acrysof lens MA60BM, 10 and MA30BM, 1) (pseudophakic group) (Table 1). This group was older (mean 84.81 months) than the aphakic group (mean age 14.31 months). Only seven eyes (63.6%) of the pseudophakic group underwent posterior CCC/capsulotomy and anterior vitrectomy, compared to all eyes in the aphakic group. Complications were encountered in four eyes in the pseudophakic group (36.4%)—malposition of IOL, vitreous strand in AC, posterior synechiae and raised IOP.

Four eyes (two in the pseudophakic and two in the aphakic group) did not receive additional postoperative topical steroids (prednisolone acetate 1%). This decision was made for patients 4 and 12 as there was minimal manipulation and iris trauma intraoperatively. These children were older (ages 131 and 115 months at surgery), allowing for easier follow up examination. Patient 13 had developmental delay and was difficult to manage. All four eyes were assessed to be quiet by slit lamp examination 2–4 weeks postoperatively. Additional steroids were not indicated and there was no glaucoma or endophthalmitis.

One eye (patient 17) required adjuvant periocular dexamethasone (1 mg) for fibrinous inflammation in the first week. The left eye of patient 6, which had been quiescent and without treatment for 2 months, developed raised IOP (30 mm Hg) at 3 months after surgery. This was controlled with topical betaxolol. There was no glaucomatous cupping and visual fields could not be performed in view of the age of the child.

Patient 13 had severe atopic dermatitis requiring systemic prednisolone. When visually significant cataract developed in the left eye, preoperative prednisolone was increased prophylactically and a pellet of Surodex was inserted at the end of surgery. As there was minimal inflammation, the systemic steroid was tapered over 2 weeks

and the steroid eye drops were stopped after 3 weeks. This eye achieved a final visual acuity of 20/20.

Comment

Fibrinous anterior uveitis is common after paediatric cataract surgery, occurring in varying severities in up to 100% of cases.^{2,3}

In our series, only two eyes (11.1%) developed inflammation that required additional steroid therapy. The remaining 16 eyes achieved good control of inflammation, particularly the four eyes that received Surodex without postoperative topical steroids. None experienced rebound uveitis after 1 week, when the pellet had ceased its release of dexamethasone. This suggests that in selected eyes, a Surodex pellet alone may be adequate to control postoperative inflammation. A randomised controlled trial comparing Surodex versus conventional steroid eye drop therapy will be needed to determine the ultimate efficacy of Surodex in paediatric eyes.

The efficacy of eye drops is dependent on compliance and timely application for drug penetration and absorption. In infants and young children, the systemic absorption of the steroid may have potentially serious complications such as hyperglycaemia and immunosuppression. Surodex significantly reduces the total dose delivered, as the 60 µg of dexamethasone in one pellet is approximately equivalent to that in just one drop of 0.1% dexamethasone.¹⁰ A system such as the DDS allows for direct application of the drug to the target site, potentially eliminating the problems of compliance.

The single complication encountered, which may be related to Surodex insertion, is the late onset of raised IOP (patient 6) despite the lack of marked postoperative inflammation. The fellow eye had also undergone cataract surgery with insertion of Surodex without complications. Steroid responsive glaucoma is an unlikely cause as the drug has been shown to persist only for 7 days in rabbits, although this has not been demonstrated in human eyes.¹³ Gonioscopy may reveal focal peripheral anterior synechiae (PAS) at the site of residual pellet, but it is unlikely that this minor degree of synechiae may cause angle closure glaucoma, although the pellet may persist for weeks in the angles.¹⁰ Unfortunately, gonioscopy was not performed in this eye. Glaucoma after paediatric cataract surgery is, however, a complication that increases in frequency with longer durations of follow up (3–22%).^{1,5,14}

We acknowledge that there are several limitations to these findings. Firstly, being a retrospective review, the efficacy of Surodex in preventing posterior capsular opacification, an indicator of postoperative inflammation, could not be assessed. We are also unable to establish if Surodex alone is sufficient for postoperative control of inflammation, this would require a prospective randomised clinical controlled trial. The efficacy of control of postoperative inflammation and safety are incomplete without the assessment of flare and endothelial cell counts but these are difficult in children, although endothelial cell count studies in adult eyes have shown no significant change.^{10,12} Finally, gonioscopy to visualise the angles to look for PAS was also not done.

Surodex has previously been shown to be safe and effective in uncomplicated cataract surgery in adults. This retrospective review provides preliminary data to suggest that Surodex may be an effective and safe adjunctive anti-inflammatory agent that in some paediatric eyes may eliminate the need for other steroid administration. Further studies will be required to determine the ultimate safety of Surodex in paediatric eyes.

S-Y Lee, S-P Chee, V Balakrishnan, S Farzavandi, D T H Tan
Singapore National Eye Centre

S-P Chee, V Balakrishnan, D T H Tan
Singapore Eye Research Institute

S-P Chee, D T H Tan
Department of Ophthalmology, National University of Singapore

Correspondence to: Soon-Phaik Chee, Singapore National Eye Centre, 11 Third Hospital Avenue, Singapore 168751; chee_soon_phaik@snecc.com.sg

Accepted for publication 3 March 2003

The authors have no proprietary or financial interest in Oculex Pharmaceuticals, Inc, Sunnyvale, CA, or in the product Surodex.

Financial support: Nil.

Presentation: Poster presentation at the XXIXth International Congress of Ophthalmology, Sydney, Australia. 21–25 April 2002.

References

- Zwann J, Mullaney PB, Awad A, et al. Pediatric intraocular lens implantation. Surgical results and complications in more than 300 patients. *Ophthalmology* 1998;**105**:112–19.
- Sharma N, Pushker N, Dada T, et al. Complications of pediatric cataract surgery and intraocular lens implantation. *J Cataract Refract Surg* 1999;**25**:1585–8.
- Malukiewicz-Wisniewska G, Kaluzny J, Lesiewska-Junk H, et al. Intraocular lens implantation in children and youth. *J Pediatr Ophthalmol Strabismus* 1999;**36**:129–33.
- Apple DJ, et al. Pediatric cataract. *Surv Ophthalmol* 2000;**45**(Suppl):S150–68.
- Cavallaro BE, Madigan WP, O'Hara MA, et al. Posterior chamber intraocular lens use in children. *J Pediatr Ophthalmol Strabismus* 1998;**35**:254–63.
- Yu YS, Lee JH, Chang BL. Surgical management of congenital cataract associated with severe microphthalmos. *J Cataract Refract Surg* 2000;**26**:1219–24.
- BenAzra D, Cohen E. Cataract surgery in children with chronic uveitis. *Ophthalmology* 2000;**107**:1255–60.
- Lundvall A, Zetterstrom C. Cataract extraction and intraocular lens implantation in children with uveitis. *Br J Ophthalmol* 2000;**84**:791–3.

- 9 Paikos P, Fotopoulou M, Papatthanassiou M, et al. Cataract surgery in children with uveitis. *J Pediatr Ophthalmol Strabismus* 2001;**38**:16–20.
- 10 Tan DTH, Chee SP, Lim L, et al. Randomized clinical trial of a new dexamethasone delivery system (Surodex) for treatment of post-cataract surgery inflammation. *Ophthalmology* 1999;**106**:223–31.
- 11 Chang DF, Garcia IH, Hunkeler JD, et al. Phase II results of an intraocular steroid delivery system for cataract surgery. *Ophthalmol* 1999;**106**:1172–7.
- 12 Tan DTH, Chee SP, Lim L, et al. Randomized clinical trial of Surodex steroid drug delivery system for cataract surgery. Anterior versus posterior placement of two Surodex in the eye. *Ophthalmology* 2001;**108**:2172–81.
- 13 Kochinke F, Vajda JJ, Wang VG. Novel bioabsorbable drug delivery system (bDDS) for the treatment of post-surgical inflammation. *Invest Ophthalmol Vis Sci* 1994;**35**(Suppl):4474.
- 14 Keech RV, Cibis Tongue A, Scott WE. Complications after surgery for congenital and infantile cataracts. *Am J Ophthalmol* 1989;**108**:136–41.

Pars plana ciliary epithelial proliferation in 13q deletion syndrome

The 13q deletion syndrome is an uncommon chromosomal disorder affecting the long arm of chromosome 13 which is deleted to a variable degree.¹ This syndrome is phenotypically characterised by mental retardation, structural malformations, facial dysmorphism, and a predisposition to develop retinoblastoma.¹ This intraocular tumour is diagnosed in approximately 80% of cases with this syndrome.² Moreover, the incidence of bilateral retinoblastoma is much higher in individuals with this syndrome.^{3,4} The retinoblastoma susceptibility gene (RB-1), which encodes for the nuclear phosphoprotein of 105 kDa, is located in band 13q14.⁵ The involvement of the q14 band on the long arm of chromosome 13 places patients with this syndrome at significant risk for developing retinoblastoma.⁶ In addition, children with 13q deletion syndrome also show optic nerve hypoplasia and retinal dysplasia.⁷ In this case, we report additional findings of pars plana ciliaris epithelial proliferation in 13q deletion syndrome.

Case report

A 5 month old Hispanic female infant with a karyotype 46,XX, del (13) (q14.1q21.3) was referred to us for the evaluation of retinoblastoma. She had dysmorphic features, such as craniosynostosis. There was no family history of ocular or systemic disease. While under anaesthesia, the patient's right eye was examined, revealing a mass that occupied a large area of the inferior nasal portion of the retina, and extending into the vitreous cavity (Fig 1). It obscured the optic nerve head and was associated with retinal detachment. There were also fine vitreous seedings. Ultrasonography disclosed a retinal tumour with intralaminar calcific foci. The preoperative diagnosis was retinoblastoma with vitreous seedings, and she underwent enucleation of the globe. The left eye was unremarkable.

Macroscopic examination revealed a greyish-white tumour arising from the retina that exhibited calcific foci and was extended into the vitreous cavity. Histological examination of the tumour indicated a well differentiated retinoblastoma that displayed both Flexner-Wintersteiner and Homer-Wright rosettes

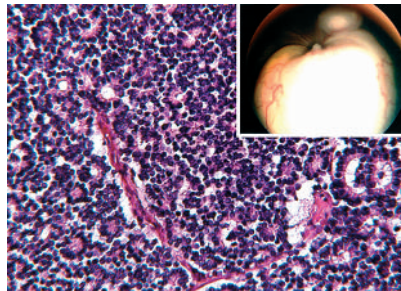


Figure 1 The retinoblastoma shows numerous Flexner-Wintersteiner and Homer Wright rosettes (haematoxylin and eosin; original magnification $\times 200$). Inset; note a large endophytic retinoblastoma arising from the inferior retina and obscuring the optic disc.

(Fig 1). There was no tumour invasion of the uvea or the post laminar optic nerve. In addition, the globe showed multilayered plaquoid non-pigmented ciliary epithelial proliferation at the pars plana ciliaris (Fig 2) and optic nerve hypoplasia. The epithelial proliferation revealed benign histological features, unlike the malignant neoplastic proliferation of the retina. At the pars plana ciliaris, the pigment epithelium showed focal proliferation.

Comment

The extent of the deletions affecting the long arm of chromosome 13 may result in various developmental anomalies that constitute 13q syndrome.^{8,9} Proliferation of the pars plana ciliaris non-pigmented ciliary epithelium, as noted in the present case, and its association with retinoblastoma suggests that the RB-1 gene, or a gene close to the RB-1 locus may have a role in the proliferation of the other neuroepithelial structures of the eye, including the pars plana ciliary epithelium.

In embryological terms, the non-pigmented ciliary epithelium is derived from the inner layer of the optic cup which also gives rise to the neural retina.⁹ Proliferation of the pars plana ciliary epithelium in an eye that harbours retinoblastoma suggests that the RB-1 gene may play a part in

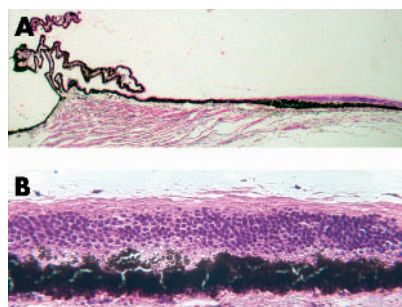


Figure 2 (A) Low magnification of ciliary body and pars plana ciliaris reveals plaquoid, thickening of non-pigmented ciliary epithelium and double layered pigment epithelium (haematoxylin and eosin; original magnification $\times 50$). (B) High magnification of the pars plana ciliaris shows multilayered proliferation of non-pigmented epithelium (haematoxylin and eosin; original magnification $\times 400$).

such epithelial proliferation. However, this epithelial proliferation has not been previously reported in eyes with retinoblastoma. Although the cause of proliferation of the ciliary epithelium is not clear, this case suggests that the non-pigmented ciliary epithelial proliferation at the pars plana ciliaris in an eye that harbours retinoblastoma may be related to 13q deletion syndrome. Such findings may be unique to this syndrome, but previous reports about it have not mentioned them. The lack of previously reported cases with findings of pars plana epithelial proliferation suggests that this syndrome may have variable phenotypic expression.

Acknowledgements

This work was supported in part by NEI core grant Ey03040 and by an unrestricted grant from Research to Prevent Blindness Inc, New York, USA. The clinical illustration is provided by Dr Linn A Murphree.

Y Usui

Department of Ophthalmology, Tokyo Medical University, Tokyo, Japan

Y Usui, N A Rao

The A Ray Irvine Ocular Pathology Laboratory, the Doheny Eye Institute, and the Department of Ophthalmology, Keck School of Medicine of the University of Southern California, Los Angeles, CA, USA

Correspondence to: Yoshihiko Usui, MD, Department of Ophthalmology, Tokyo Medical University, 6-7-1 Nishi-shinjuku, Shinjuku-ku, Tokyo 160-0023, Japan; usuyoshi@aol.com

Accepted for publication 3 March 2003

References

- 1 Seidman DJ, Shields JA, Augsburger JJ, et al. Early diagnosis of retinoblastoma based on dysmorphic features and karyotype analysis. *Ophthalmology* 1987;**94**:663–6.
- 2 Ganesh A, Kenue RK, Mitra S. Retinoblastoma and the 13q deletion syndrome. *J Pediatr Ophthalmol Strabismus* 2001;**38**:247–50.
- 3 Bunin GR, Emanuel BS, Meadows AT, et al. Frequency of 13q abnormalities among 203 patients with retinoblastoma. *J Natl Cancer Inst* 1989;**81**:370–4.
- 4 Donaldson SS, Smith LM. Retinoblastoma: biology, presentation, and current management. *Oncology (Huntingt)* 1989;**3**:45–52.
- 5 Friend SH, Bernards R, Rogelj S, et al. A human DNA segment with properties of the gene that predisposes to retinoblastoma and osteosarcoma. *Nature* 1986;**323**:643–6.
- 6 Kennerknecht I, Barbi G, Greher J. Diagnosis of retinoblastoma in a presymptomatic stage after detection of interstitial chromosomal deletion 13q. *Ophthalmic Genet* 1994;**15**:19–24.
- 7 Weichselbaum RR, Zakov ZN, Albert DM, et al. New findings in the chromosome 13 long-arm deletion syndrome and retinoblastoma. *Ophthalmology* 1979;**86**:1191–201.
- 8 Brown S, Russo J, Chitayat D, et al. The 13q syndrome: the molecular definition of a critical deletion region in band 13q32. *Am J Hum Genet* 1995;**57**:859–66.
- 9 Beebe DC. Development of the ciliary body: a brief review. *Trans Ophthalmol Soc UK* 1986;**105**:123–30.

Phacoemulsification of posterior polar cataracts—a surgical challenge

Posterior polar cataracts are relatively uncommon yet they pose a significant chal-

lence to the cataract surgeon. Cataract surgery in these cases is frequently accompanied by a high incidence of posterior capsule rupture (PCR).

Morphology

Posterior polar cataracts are associated with remnants of the hyaloid system or the tunica vasculosa lentis.¹ These cataracts may also occur without any relation to hyaloid remnants and appear as circular or rosette shaped opacities; they are hereditary and usually transmitted as a dominant trait. The gene for this has been mapped to chromosome 16q22.²

Classification³

See Table 1 and Figure 1.

Methods

The incidence of posterior polar cataracts in our centre is approximately 5 per 1000. We conducted a retrospective review from 1994 to 1999 and identified 31 patients (36 eyes) who had surgery for posterior polar cataracts.

Results

Four eyes had PCR (11.1%) and the other 32 had uncomplicated surgery; 34 eyes achieved a best corrected visual acuity of 6/12 or better (94.4%).

Comment

Our series showed a PCR rate of 11.1% in contrast with the 26% incidence reported by Osher *et al*⁴ and 36% by Vasavada and Singh.⁵ No hydrodissection was attempted and only careful controlled hydrodelineation was performed. This was done using small aliquots of

balance salt solution (BSS) to loosen the nucleus while simultaneously watching the capsular bag to ensure that the fluid wave passed gently. In some cases, no hydroprocedures were necessary as there was slow separation of the nucleus by the BSS flowing from the phaco tip.

Vasavada and Singh described the use of step by step chop in situ and lateral separation to minimise stress on the capsule-zonule complex.^{6,7} We preferred the use of the “lambda” technique which involved sculpting in the shape of the Greek letter (λ), followed by cracking along both “arms” and removal of the central piece first. The advantage of this is its gentleness in not stretching the capsule while removing the quadrants, especially the first one. We emphasise that this is our preferred technique and other techniques would be equally effective in skilled hands.

We also used low vacuum, low aspiration, and low inflow parameters to ensure a more stable anterior chamber; bottle height was at 50 cm, vacuum at 100 mm Hg, and aspiration flow rate at 20 ml per minute. Optimum power setting was achieved when minimal movement of the nucleus occurred while sculpting.

The epinucleus and cortex were removed using manual dry aspiration with Simcoe cannula. This method is gentler as we believe that the aspiration pressure is more controllable with our “million dollar” hands. There is also no “after aspiration” effect which in the automated unit can continue for several milliseconds even after the foot has been taken off the pedal. The disadvantage of manual aspiration is the increased surgical time.

The status of the posterior capsule (PC) dictated the action of the surgeon. If the PC was absent or torn but with no vitreous loss, a dispersive viscoelastic was injected over the defect to tamponade and push the vitreous face backwards. A dispersive rather than a cohesive viscoelastic is preferable as it is more adapted to maintaining a space and stabilising the anterior vitreous face. If there was PCR with vitreous loss, a two port anterior vitrectomy was performed. Intraocular lens implantation in these cases would depend on the extent of the PCR and the integrity of the remaining PC.

Surgical management of posterior polar cataracts poses a special challenge to the cataract surgeon. It is important that the surgeon and the patient understand the technical difficulties associated and are aware of potential complications. It may be prudent to address these cases at the end of an operating list or to shorten the list in anticipation of prolonged surgical time. The surgeon should use a technique that he or she is most familiar and comfortable with. With emphasis on gentleness, together with patience and a well practised technique, the incidence of PCR can be minimised in phacoemulsification for posterior polar cataracts.

M W Lee, Y C Lee

Lee Eye Centre, 44–46 Persiaran Greenhill, Ipoh, Perak, 30450, Malaysia

Correspondence to: Dr Mun W Lee, Lee Eye Centre, 56 Heyscroft Road, Withington, Manchester M20 4XF, UK; bigmun@doctors.org.uk

Accepted for publication 3 March 2003

References

- 1 Luntz MH. Clinical types of cataracts. *Duane's Ophthalmology* 1996;CD ROM.
- 2 Maumenee III. Classification of hereditary cataracts in children by linkage analysis. *Ophthalmology* 1979;86:1554–8.
- 3 Anon. Consultation section: Cataract surgical problem. *J Cataract Refract Surg* 1997;23:819–24.
- 4 Osher RH, Yu BC, Koch DD. Posterior polar cataracts: a predisposition to intraoperative posterior capsular rupture. *J Cataract Refract Surg* 1990;16:157–62.
- 5 Vasavada A, Singh R. Phacoemulsification in eyes with posterior polar cataract. *J Cataract Refract Surg* 1999;25:238–45.
- 6 Vasavada A, Singh R. Step-by-step chop in-situ and separation of very dense cataracts. *J Cataract Refract Surg* 1998;24:156–9.
- 7 Vasavada A, Singh R. Surgical techniques for difficult cataracts. *Curr Opin Ophthalmol* 1999;10:46–52.

Table 1 Classification of posterior polar cataracts

Type 1	Opacity associated with posterior subcapsular cataract.
Type 2	Opacity with ringed appearance like an onion.
Type 3	Opacity with dense white spots at the edge often associated with thin or absent posterior capsule.
Type 4	Combination of the above 3 types with nuclear sclerosis.

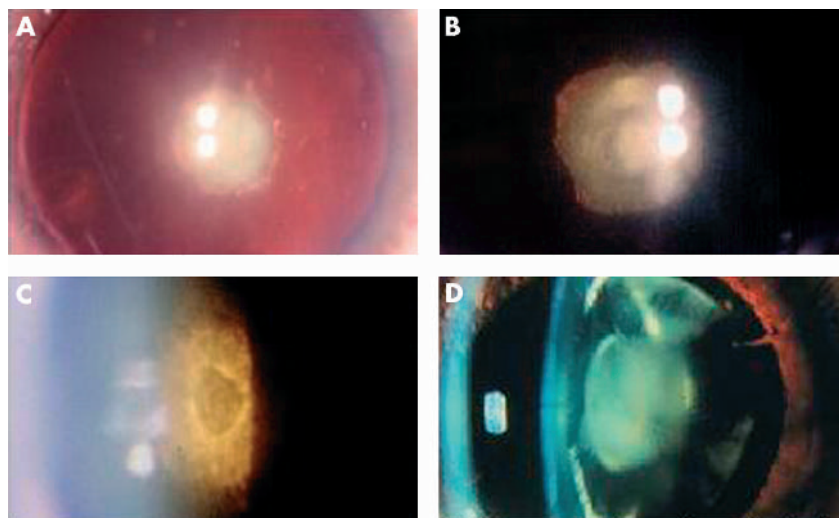


Figure 1 (A) One spot polar cataract. (B) Onion polar cataract. (C) Polar cataract with hole in posterior capsule. (D) Polar cataract with nuclear sclerosis.

Molluscum contagiosum in an immune reconstituted AIDS patient

In spite of lower viral loads and increasing T cell counts, AIDS patients receiving highly active antiretroviral therapy (HAART) are not always successful in mounting an immune response to some opportunistic pathogens. In fact, CMV retinitis, which was known to occur in HIV patients with CD4 counts below $50 \times 10^6/l$, has been described in immune reconstituted patients with CD4 counts above $200 \times 10^6/l$.¹ It is therefore important to make observations about the clinical spectrum of infectious disease in immune reconstituted AIDS patients. Here we report an isolated

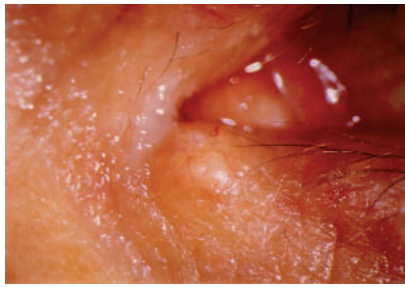


Figure 1 Note solitary umbilicated lesion involving lower eyelid margin.

lesion of molluscum contagiosum in an immune reconstituted AIDS patient.

Case report

A 46 year old Hispanic female presented with a history of burning, tearing, and itching of her left eye for 1 month. Three years earlier she had been diagnosed with AIDS during a hospital admission for *Pneumocystis carinii* pneumonia (PCP). At that time her CD4 count had been $27 \times 10^6/l$ and her viral load 905 000. After 3 months of HAART with combivir, norvir, and fortovase her viral load dropped to 15 000 and her CD4 count rose to $184 \times 10^6/l$. Her viral load became undetectable 6 months after initiation of therapy and has remained so for 2½ years. Her recent CD4 count was $435 \times 10^6/l$.

Best corrected visual acuity was 20/25 in each eye. A 2 mm smooth, dome-shaped, translucent papule with central umbilication was present inferior to the medial aspect of the left lower lid margin (Fig 1). The lesion was excised and histopathology revealed invasive acanthosis with lobules of epithelial hyperplasia invaginating into the dermis. Intranuclear and intracytoplasmic inclusion bodies typical of molluscum contagiosum were noted (Fig 2). The lesion did not recur after biopsy.

Comment

Immunocompetent patients with molluscum contagiosum involving the eyelid typically suffer from an isolated lesion that is self limited. Larger, more numerous and widespread molluscum contagiosum lesions have been documented in patients with AIDS, individuals immunosuppressed from using prednisone and methotrexate, or patients with lymphoreticular malignant neoplasms

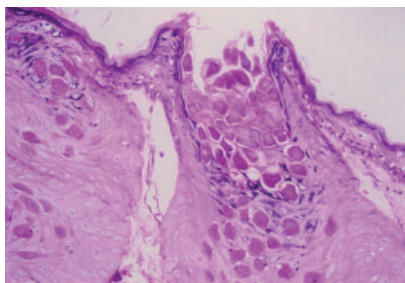


Figure 2 Histologically, the molluscum contagiosum shows intracellular eosinophilic inclusion bodies (haematoxylin and eosin $\times 120$).

or sarcoidosis.²⁻⁵ In HIV infected individuals the disease runs a more protracted course with persistent lesions and there appears to be an inverse relation of the CD4 count and the number of molluscum contagiosum lesions.⁶

The present case shows that the patient's reconstituted immune system from HAART can limit molluscum contagiosum infection to a single lesion at the eyelid, clinically and histologically identical to molluscum contagiosum lesions found in immunocompetent hosts. Such limited expression of molluscum contagiosum could be from a competent T cell response as noted in individuals with normal immune function or those with reconstituted immune response from HAART.^{3,7} Thus, clinically the presence of a solitary molluscum contagiosum lesion in an HIV infected individual suggests appropriate response to HAART.

T Albini

Department of Ophthalmology, Los Angeles County Hospital, USA

N Rao

Department of Pathology A, Ray Irvine Pathology Laboratory, Doheny Eye Institute, USA

Correspondence to: N Rao, Doheny Eye Institute, DVRC #211, 1450 San Pablo Street, Los Angeles, CA 90033, USA; nrao@usc.edu

Accepted for publication 16 March 2003

References

- 1 Johnson SC, Benson CA, Johnson DW, *et al*. Recurrences of cytomegalovirus retinitis in a human immunodeficiency virus infected patient, despite potent antiretroviral therapy and apparent immune reconstitution. *Clin Infect Dis* 2001;**32**:815.
- 2 Dugal P, Rao N. Ocular infections in the acquired immunodeficiency syndrome. *Int Ophthalmol Clin* 1993;**33**:103-27.
- 3 Smith KJ, Skelton H, Yeager J. Molluscum contagiosum: ultrastructural evidence for its presence in skin adjacent to clinical lesions in patients infected with human immunodeficiency virus type 1. *Arch Dermatol* 1992;**128**:223.
- 4 Lombardo, PC. Molluscum contagiosum and the acquired immunodeficiency syndrome. *Arch Dermatol* 1985;**121**:834.
- 5 Cattelan AM, Sasset L, Corti L, *et al*. A complete remission of recalcitrant molluscum contagiosum in an AIDS patient following highly active retroviral therapy. *J Infect* 1999;**38**:58.
- 6 Schwartz JJ, Myskowski PL. Molluscum contagiosum in patients with human immunodeficiency virus infection: a review of twenty-seven patients. *J Am Acad Dermatol* 1992;**27**:583.
- 7 Charteris DG, Bonshek RE, Tullo AB. Ophthalmic molluscum contagiosum: clinical and immunopathological features. *Br J Ophthalmol* 1995;**79**:476.

Malignant melanoma of the conjunctiva metastasising to the parotid gland

Conjunctival melanoma is rare, accounting for just 2% of ocular malignancies.¹ We present an unusual case of conjunctival melanoma with subsequent metastasis to the parotid gland. A diagnosis was made after fine needle aspiration cytology of the parotid gland was performed in light of the previous history.

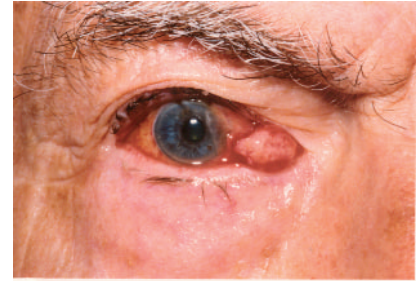


Figure 1 Pedunculated lesion arising from the nasal limbal conjunctiva, right eye.

Case report

A 79 year old white man presented to the eye clinic in September 1999. He had been noted 3 years previously to have a small inclusion cyst of the bulbar conjunctiva in his right eye, which he complained had increased in size and was becoming red and sore. Examination showed an inflamed pedunculated lesion 1 cm in diameter arising from the nasal limbal conjunctiva (Fig 1). The lesion was granulomatous and amelanotic. There was adjacent corneal opacity. Ocular examination was otherwise unremarkable.

The appearance of the lesion was felt to be unusual with a presumptive diagnosis of conjunctival malignancy. Excision biopsy with conjunctival autografting was performed.

Histology revealed a primary nodular malignant melanoma, at least 7 mm thick, composed of epithelioid sparsely pigmented melanocytes positive for S100 and vimentin immunostains. Excision was deemed incomplete.

The patient was referred for adjuvant treatment with cryotherapy. To date, there has been no sign of local recurrence.

In June 2001, the patient was referred by his general practitioner to the oral surgery service at the same hospital with a 6 month history of pain on the right side of his neck. He had also noticed some right facial swelling. Clinical examination disclosed a diffuse, firm mass over the lower pole of his right parotid gland, measuring 4 cm in diameter. There were no overlying skin changes.

Magnetic resonance imaging (MRI) of the head and neck showed a well defined lesion within the right parotid gland involving the deep lobe and the deeper portion of the

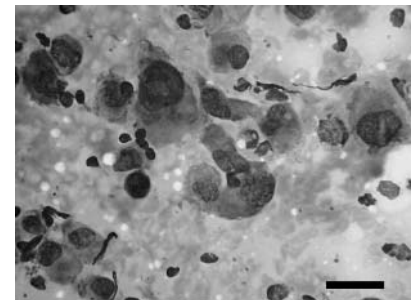


Figure 2 FNA cytology of the parotid swelling. Highly pleomorphic malignant epithelioid melanocytes with scattered lymphocytes in the background. Scale bar = 25 mm.

superficial lobe. A few small lymph nodes were visible at several sites bilaterally but none appeared enlarged. Computed tomography (CT) of the chest, abdomen and pelvis revealed single nodules measuring 3–5 mm at both lung bases, which may represent lung metastases.

An orthopantomogram was normal, and fine needle aspiration (FNA) cytology was performed. This showed scattered lymphocytes and highly pleomorphic non-lymphoid malignant cells, some containing flecks of pigment (Fig 2). While these appearances alone would not allow definitive diagnosis of melanoma, in the clinical context they were sufficient to conclude that the parotid swelling was likely to be metastatic melanoma. This was confirmed on subsequent parotid excision biopsy, which revealed extensive involvement of the parotid nodes and parotid parenchyma, extending into the external jugular vein.

Comment

Malignant melanoma is a relatively rare tumour in the parotid gland, with most tumours representing metastasis from cutaneous head and neck primaries.² Very occasionally, as in this case, the primary tumour is non-cutaneous in origin.

Conjunctival melanoma metastasising to the parotid has been noted in previous series,³ but remains rare. This case is unusual with respect to the initial size and appearance of the tumour, the previous history of a conjunctival cyst, and that definitive diagnosis of a metastatic lesion from a conjunctival primary was made by FNA. This method has been helpful in the diagnosis of other types of tumour in the parotid,⁴ and indeed in parotid melanomas of different origin.⁵ In this case, the patient's previous ophthalmic history had been unknown to the maxillofacial surgeon managing the case, and the diagnosis only became clear during reporting of the cytology, when the FNA findings could be compared with previous histology. This illustrates the importance of exhaustive history taking and the value of a cohesive local histopathology service.

F Cuthbertson

Department of Ophthalmology, St James's University Hospital, Beckett Street, Leeds LS9 7TF, UK

J Luck, S Rose

Royal United Hospital, Combe Park, Bath BA1 3NG, UK

Correspondence to: Dr Fiona Cuthbertson, Department of Ophthalmology, St James's University Hospital, Beckett Street, Leeds LS9 7TF, UK; fcuthbertson@hotmail.com

Accepted for publication 26 March 2003

References

- 1 McCartney AC. Pathology of ocular melanomas. *Br Med Bull* 1995;51:678–93.
- 2 Prayson RA, Sebek BA. Parotid gland malignant melanomas. *Arch Pathol Lab Med* 2000;124:1780–4.
- 3 Esmali B, Wang X, Youssef A, et al. Patterns of regional and distant metastasis in patients with conjunctival melanoma. *Ophthalmology* 2001;108:2101–5.
- 4 Nasufi JF, Yu GH, Gupta PK. Fine needle aspiration of cystic parotid gland lesions: an institutional review of 46 cases with histologic correlation. *Cancer* 2000;90:111–16.

- 5 Chieng DC, Cangiarella JF, Waisman J, et al. Fine needle aspiration cytology of desmoplastic malignant melanoma metastatic to the parotid gland: case report and review of the literature. *Diagn Cytopathol* 2000;22:97–100.

Bilateral *Aspergillus* endophthalmitis in a patient with chronic lymphocytic leukaemia

Aspergillus species are ubiquitous saprophytic moulds, commonly growing in soil, stored hay, and decaying vegetation. Even though exposure to *Aspergillus* is universal, infection in humans is uncommon.¹ *Aspergillus* infection of ophthalmic interest usually causes keratitis or orbital cellulitis; *Aspergillus* endophthalmitis is a relatively rare condition that has a devastating course, with blindness as its usual outcome.² The clinical diagnosis is difficult and the treatment is disappointing. In most cases, ocular involvement results from spread of aspergillosis infection from other organs and typically occurs in injecting drug users and in patients with immune deficiency of various causes. The leucopenia appears to be a predisposing condition for the occurrence of aspergillosis.³

We report an unusual case of bilateral endogenous *Aspergillus* endophthalmitis in a patient with chronic lymphocytic leukaemia in the absence of any detectable focus of aspergillosis infection elsewhere in the body and that showed a good response to specific systemic therapy.

Case report

A 51 year old white man with a previous diagnosis of chronic lymphocytic leukaemia and use of an immunosuppressive agent was referred to ophthalmological examination because of a red eye, pain, and blurred vision

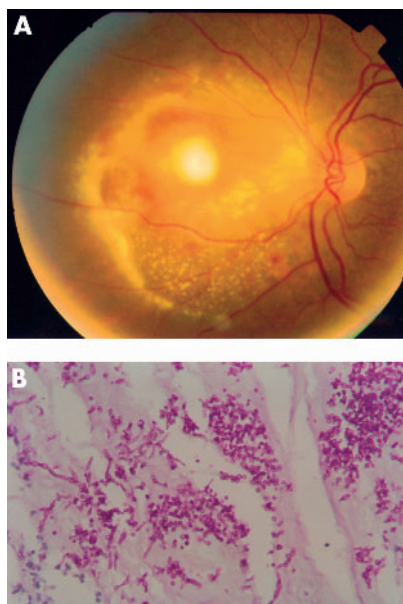


Figure 1 (A) Fundus photography showing a yellowish subretinal lesion surrounded by fluid and haemorrhages, nasal to the disc, in the left eye. (B) PAS stain showing the presence of *Aspergillus* in the cornea of the eviscerated right eye.

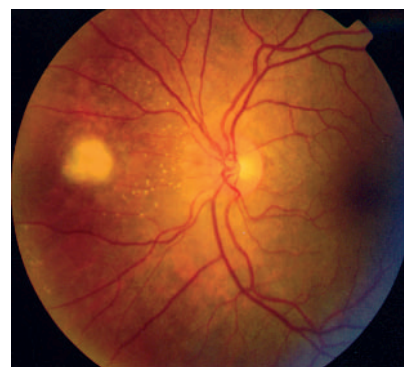


Figure 2 Lesion nasal to the disc after treatment.

in his right eye. The clinical picture worsened and diagnosis of endophthalmitis was made. Intravitreal amphotericin B injection was performed and did not control the case. Culture of vitreous fluid was positive for *Candida*. This eye was eviscerated because of increasing pain, progressive infection, and poor response to treatment. Posterior histopathological study was conclusive for *Aspergillus* endophthalmitis in the right eye (Fig 1B and 2). At the same time, fundus examination of the left eye showed two subretinal exudative lesions located at nasal and inferior retina with retinal oedema associated with superficial haemorrhages (Fig 1A). The vitreous was clean and the central macula remained intact. Visual acuity was 6/6 in this eye.

Vitreous biopsy or culture may yield negative results in some cases of early intraocular *Aspergillus* endophthalmitis.³ We did not take a vitreous biopsy of the left eye, since we already had the diagnosis in the right eye and the visual acuity was 6/6. This eye was treated with intravenous amphotericin B and oral itraconazole with a good result. The patient remained stable with resolution of the lesions and no focus of systemic aspergillosis was found.

Comment

Fungal endophthalmitis is uncommon. In most of the cases *Candida* is the causal organism.^{4,5} Few cases of *Aspergillus* endophthalmitis in a patient with chronic lymphocytic leukaemia have been described,⁴ and according to the literature endogenous *Aspergillus* endophthalmitis represents a manifestation of disseminated aspergillosis, usually a fatal infection.^{6,7} This case is unusual because it is bilateral and no focus of systemic aspergillosis was found.

The cases of intraocular inflammation secondary to *Aspergillus* are more common in the central macula and have a poor prognosis.¹ In our case the localisation of the chorioretinitis in the left eye was out of the posterior area and the patient's visual acuity remained 6/6.

The major antifungal agent used in aspergillosis is amphotericin B. Without host immune competence, treatment is rarely effective. Penetration of intravenous amphotericin B into the vitreous cavity of the normal or inflamed eye is poor.^{8,9} The azole compounds have been used to reduce the significant toxicity and enhance the efficacy

of intravenous amphotericin B; oral fluconazole is the drug of choice because it has excellent penetration in central nerve system and vitreous.¹ Itraconazole may be used. Intravitreal amphotericin B and vitrectomy have given the best results in the treatment of these cases.² Our patient received intravenous amphotericin B and oral itraconazole and this therapy was sufficient to control the infection.

This case shows that *Aspergillus* endophthalmitis should be considered in all patients with immune deficiency even in the absence of systemic aspergillosis. Treatment with intravenous amphotericin B may be able to control these cases and should be attempted more often.

D de O Machado, R Gonçalves, E M Fernandes, W R Campos, F Oréfica

Department of Ophthalmology, Federal University of Minas Gerais, Brazil

A L L Curi

Department of Ophthalmology, Federal Fluminense University Niterói, Brazil

Correspondence to: André L L Curi, R Francisco Dutra 163/701, Icaraí, Niterói, RJ, Brazil Cep 24220150; curiall@yahoo.com

Accepted for publication 30 March 2003

References

- 1 Weishaar PD, Flynn HW Jr, Murray TG, *et al*. Endogenous aspergillus endophthalmitis: clinical features and treatment outcomes. *Ophthalmology* 1998;**105**:57–65.
- 2 Sihota R, Agorwal HC, Grover AK, *et al*. Aspergillus endophthalmitis. *Br J Ophthalmol* 1987;**71**:611–13.
- 3 Rao NA, Hidayat AA. Endogenous mycotic endophthalmitis: variation in clinical and histopathologic changes in candidiasis compared with aspergillosis. *Am J Ophthalmol* 2001;**132**:244–51.
- 4 Kalina PH, Campbell J. Aspergillus terreus endophthalmitis in a patient with chronic lymphocytic leukemia. *Arch Ophthalmol* 1991;**109**:102–3.
- 5 Hara KS, Reju JH, Lie TS, *et al*. Disseminated aspergillus terreus infection in immunocompromised hosts. *Mayo Clin Proc* 1989;**64**:770–5.
- 6 Graham DA, Kinyoun JL, George DP. Endogenous aspergillus endophthalmitis after lung transplantation. *Am J Ophthalmol* 1995;**119**:107–9.
- 7 Hunt KE, Glasgow BJ. Aspergillus endophthalmitis: an unrecognized endemic disease in orthotopic liver transplantation. *Ophthalmology* 1996;**103**:757–67.
- 8 Green WR, Bennett JE, Goos RD. Ocular penetration of amphotericin B. *Arch Ophthalmol* 1965;**73**:769–75.
- 9 Fisher JF, Taylor AT, Clark J, *et al*. Penetration of amphotericin B into the human eye. *J Infect Dis* 1983;**147**:164.

Late bleb needling

Surgical manipulation of the trabeculectomy bleb has become a recognised postoperative procedure to increase the success of glaucoma surgery. The first needling revision of a glaucoma drainage bleb was described in 1941¹ and there are several reports of the successful restoration of failing blebs within the first 3 years following trabeculectomy.^{2–6}

We report the results of five cases of late bleb needling with 5-fluorouracil (5-FU) where trabeculectomy had been performed between 8 and 30 years earlier.

Table 1 Demographic details of patients

Case no		Drainage procedure	Delay to needling (years)	No of needlings	No of 5-FU injections
1	72	M Bilateral Scheie's	31	2	4
2	88	F Left ECCE+trabeculectomy	10	4	5
3	80	F Right trabeculectomy	12	1	4
4	35	M Right trabeculectomy	8	1	2
5	71	M Bilateral trabeculectomy	13	1	2

ECCE = extracapsular cataract surgery.

Table 2 Results of pre-bleb and post-bleb needling with a 12 month follow up period

Case no	Age (years)	Sex	IOP (mm Hg)		No of medications	
			Pre	Post	Pre	
1	72	M	19	9	3+ acetazolamide	0
2	88	F	25	14	3	1
3	80	F	20	17	3	1
4	35	M	58	12	2+ acetazolamide	0
5	71	M	25	16	2	0

Case reports

The demographic details of all cases are summarised in Table 1.

Glaucoma surgery had taken place between 8 and 31 years before bleb needling and in no case had antimitotics been used at the original surgery. Before bleb needling the average intraocular pressure (IOP) among the patients was 29.4 mm Hg (range 19–58). Each patient showed glaucomatous deterioration despite being on maximum tolerated medical therapy, taking on average three ocular hypotensive agents, and in two cases oral acetazolamide. In all cases an open sclerotomy was confirmed by gonioscopy.

All procedures were performed in the outpatient clinic, by either a consultant or associate specialist, using a slit lamp. The eye was anaesthetised with amethocaine eye drops 1%, and phenylephrine eye drops 2.5% were used for vasoconstriction. After several drops of chloramphenicol the conjunctiva was entered several millimetres from the flap site with a 27 gauge needle mounted on an insulin syringe. In one case aqueous flow was established after perforating scar tissue around an encysted bleb, whereas in the others it was necessary to dissect beneath the scleral flap and enter the anterior chamber. After creating a bleb and confirming a reduction in IOP by applanation tonometry, 5 mg 5-FU (25 mg/ml) were injected into the subconjunctival space around the bleb. After needling, all hypotensive therapies were stopped and replaced by intensive topical steroids and chloramphenicol. The steroid was titrated, and repeat injections of 5-FU with or without needling were given, according to the IOP and appearance of the bleb.

After 12 months' follow up from the last needling (Table 2), average IOP was reduced to 14 mm Hg (range 9–17). There was no change in the patients' visual acuity. Two cases developed a mild corneal epitheliopathy that healed within 8 weeks. There were no other complications from the needling procedure.

Comment

Although trabeculectomy is the preferred glaucoma drainage procedure, only 67% of patients may achieve an adequate target pressure after 1 year.⁵

In recent years glaucoma surgery has developed with the use of antimitotics and intense postoperative surveillance with bleb manipulation. Reports show that bleb needling used in combination with subconjunctival 5-FU injections can rectify a failing bleb in the early postoperative phase but there are few reports confirming its effect in the late postoperative period.^{2–3} Some studies have indicated that the success of bleb needling is unrelated to the time lapsed from the original surgery^{2–3} though in these studies the maximum interim period was less than 4.5 years.

The patients presented in this study had had their original glaucoma surgery at least 8 years previously and bleb needling was carried out before listing the patient for a repeat trabeculectomy with mitomycin C. The only adverse effect noted was a temporary corneal epitheliopathy, probably related to toxicity of the 5-FU. Other reported adverse events after bleb needling include hyphaema, bleb leak, shallow anterior chamber, choroidals effusion and endophthalmitis, but there are no reports of long term hypotony as has been described following mitomycin C trabeculectomy.

These case reports indicate that bleb needling may be successful in achieving a long lasting IOP reduction even several years after the original surgery. The procedure does not require dextrous skills beyond that of a trained general ophthalmologist. It appears at least as safe as trabeculectomy and avoids a formal operation. If it does fail the surgical field is still intact for a "redo" trabeculectomy.

C T Ung, H Von Lany, K G Claridge

Taunton and Somerset NHS Trust, Musgrove Park, Taunton TA1 5DA, UK

Correspondence to: Ms Katherine Claridge, Taunton and Somerset NHS Trust, Musgrove Park, Taunton TA1 5DA, UK; kate.claridge@tst.nhs.uk

Accepted for publication 31 March 2003

References

- 1 Ferrer H. Conjunctival dialysis in the treatment of glaucoma recurrent after sclerotomy. *Am J Ophthalmol* 1941;**24**:788–90.
- 2 Ewing RH, Stamper RL. Needling revision with and without 5-fluorouracil for the treatment of failed filtering blebs. *Am J Ophthalmol* 1990;**110**:254–9.
- 3 Shin DH, Juzycz MS, Khatana AK, et al. Needling revision of failed filtering blebs with adjunctive 5-fluorouracil. *Ophthalmic Surg* 1993;**24**:242–8.
- 4 Gillies WE, Brooks AMV. Restoring the function of the failed bleb. *Aus and NZ J Ophthalmol* 1991;**19**:49–51.
- 5 Edmunds B, Thompson JR, Salmon JF. The National Survey of Trabeculectomy. II. Variations in operative technique and outcome. *Eye* 2001;**15**:441–8.
- 6 Mardelli PG, Lederer CM Jr, Murray PL, et al. Slitlamp needle revision of failed filtering blebs using mitomycin C. *Ophthalmology* 1996;**103**:1946–9.
- 3 Tsirbas A, Wormald PJ. Endonasal dacryocystorhinostomy with mucosal flaps. *Am J Ophthalmol* 2003;**135**:76–83.
- 4 Moore WM, Bentley CR, Olver JM. Functional and anatomic results after two types of endoscopic endonasal dacryocystorhinostomy: surgical and holmium laser. *Ophthalmology* 2002;**109**:1575–82.
- 5 Minasian M, Olver JM. The value of nasal endoscopy after dacryocystorhinostomy. *Orbit* 1999;**18**:167–76.

MAILBOX

The success rates for endonasal dacryocystorhinostomy

Tsirbas and Wormald are to be congratulated on their landmark paper in lacrimal surgery describing endonasal dacryocystorhinostomy (DCR) with mucosal flaps,¹ which is also known as powered endonasal DCR.^{2,3} Their results are seemingly impressive, with anatomical success rate of 95% and functional success rate of 89%, closely approaching those of external (transcutaneous) DCR. I have three comments that I hope will help readers who are less familiar with endonasal lacrimal surgery, put this paper into perspective.

Firstly, the mucosal flaps have a greater role preoperatively than postoperatively. The large nasal mucosal flap reflected medially over the middle turbinate protects that structure preoperatively from inadvertent damage during mechanical/powering instrumentation. After the bony opening has been made (osteotomy) this flap is trimmed in the described C shape, which prevents it from flapping over the common canalicular opening and occluding it; it has only a negligible postoperative role covering raw bony edges in part. The creation of a useful lacrimal sac mucosal flap is entirely dependent on the size of the sac, being large when there is a mucocele and small when the sac is small and shrunken. In external DCR the fashioned mucosal flaps are well apposed and sutured, and are assumed to have a major role in reducing scarring from secondary intention healing. In comparison, the mucosal “flaps” described in this paper probably have only a minor role in the postoperative period.

Secondly, the disadvantage of this technique is undoubtedly the reported 46% rate of concomitant septoplasty, in order to create an adequate nasal space for safe instrumentation. Concomitant septoplasty is only occasionally needed in endoscopic endonasal surgical dacryocystorhinostomy (EES-DCR), probably in less than 5% of cases operated, yet the results of that faster and less invasive surgery are approximately 85%. Septoplasty is

hardly ever required in external DCR, usually only in occasional trauma cases where the nasal space is exceedingly narrow. The authors have recognised that maintaining an unimpeded common canalicular opening free from fine bone fragments, mucosal tags, or flaps enables free tear drainage into the nose and is a key factor for a high success rates in DCR surgery. In order to achieve this they consistently make a very large rhinostomy (20 mm×15 mm) by removing both the thin lacrimal and the thicker maxilla bone. The drawback of doing this endonasally is that there are risks of mucosal damage and subsequent synechiae from the bone punches (rongeurs) used to remove maxilla bone anterior to the sac, and the diamond burr used to remove the thick maxilla bone superior. Hence, there is the need for the high septoplasty rate to create an adequately large size nasal space.

Thirdly, their follow up times are inconsistent and need to be standardised in order for readers to understand the results and compare them with those of other endonasal DCR techniques. The success rates for mechanical endonasal DCR reported by Tsirbas and Wormald¹ appear to be very good (95% anatomical and 89% functional success), but their follow up period varied from only 2 months to 28 months (mean 9.7). Some of the patients who had only a short follow up time may subsequently fail. A paper published in the *American Journal of Ophthalmology* by the same authors using the same technique,³ where they had a minimal follow up of 9 months, had a lower anatomical success rate (91%).

It is important to define success and what this really means, and for lacrimal surgeons to agree consistent outcome criteria. Perhaps lacrimal surgeons should agree the following criteria for DCR surgical success, irrespective of whether it is by an external or endonasal route?

- Assess the outcome a minimum of 6 months after surgery, being at least 3 months after removal of tubes. Or is 1 year after surgery better?
- Assess subjective success based on the patient's symptoms.
- Assess objective success (anatomical success) based on (i) patency on syringing and (ii) presence of a functioning rhinostomy. The latter is evaluated using the functional endoscopic dye test, which is positive when 2% fluorescein instilled in the conjunctival fornix is seen emerging from the rhinostomy a few seconds later.^{4,5}

Despite these minor quibbles, the authors are to be congratulated on advancing endonasal lacrimal surgery.

J M Olver

Western Eye Hospital, Marylebone Road, London NW1 5YE, UK; janeolver@aol.com

Accepted for publication 11 February 2003

References

- 1 Tsirbas A, Wormald PJ. Mechanical endonasal dacryocystorhinostomy with mucosal flaps. *Br J Ophthalmol* 2003;**87**:43–7.
- 2 Wormald PJ. Powered endonasal dacryocystorhinostomy. *Laryngoscope* 2002;**112**:69–72.

Trypan blue stains the epiretinal membrane but not the internal limiting membrane

We read with great interest the paper by Li et al about staining of the internal limiting membrane (ILM) and epiretinal membrane (ERM) with trypan blue (TB).¹ We would like to comment on one aspect of this paper, when the authors claimed that a good staining of both the ILM and the ERM was achieved with TB. We disagree that ILM is stained by TB, and propose that TB only stains the ERM, not the ILM.

The authors affirm “ILM staining” with TB as they observed histologically the presence of ILM in four eyes with macular holes at stage III and IV. In one of those eyes, immunohistochemistry was performed, and an epiretinal membrane was observed. In the other three cases, immunohistochemistry examination was not performed because of insufficient tissue. Most of the stage III and IV macular holes are known to be associated with an epiretinal membrane,² and probably an ERM would be seen in addition to the ILM in those three cases if immunohistochemistry for glial elements were performed. Therefore, we believe that TB stained the ERM associated with the macular holes, but not the ILM. In their study, staining with TB of seven patients with idiopathic epiretinal membrane was successfully performed. ERM of proliferative vitreoretinopathy is also reported to be well stained by TB.³ We speculate that TB has binding affinity to some of the glial cell elements of the highly cellular ERMs, either those associated with macular holes or not.

Indocyanine green (ICG) is another new dye for intraocular staining that has gained wide acceptance among retina surgeons in the past few years.⁴ In contrast with the cellular affinity of TB, ICG stains the acellular ILM, because of the fast binding of ICG to collagen proteins of the ILM. ERM tends to be stained negatively by ICG, well because the hydrophilic ICG does not penetrate cell membranes easily.⁵

TB staining seems to be a good alternative to ICG staining in the surgical management of macular diseases. Further studies are warranted on the intraocular kinetics of that dye.

E B Rodrigues, C H Meyer, J C Schmidt, P Kroll
Department of Ophthalmology, Philipps-University Marburg, Germany

Correspondence to: E B Rodrigues, MD; Department of Ophthalmology, Philipps-University Marburg, Germany; edubrodrigues@yahoo.com.br

Accepted for publication 4 April 2003

References

- 1 Li K, Wong D, Hiscott P, et al. Trypan blue staining of internal limiting membrane and

epiretinal membrane during vitrectomy: visual results and histopathological findings. *Br J Ophthalmol* 2003;**87**:216-19.

- 2 **Torambe P**, Augustin AJ. Macular holes. Review of the current status of knowledge of pathogenesis and treatment methods. *Ophthalmology* 2002;**99**:601-8.
- 3 **Feron EJ**, Veckeneer M, Parys-Van Ginderdeuren R, *et al*. Trypan blue staining of epiretinal membranes in proliferative vitreoretinopathy. *Arch Ophthalmol* 2002;**120**:141-4.
- 4 **Schmidt JC**, Meyer CH, Rodrigues EB, *et al*. Staining of internal limiting membrane in vitreomacular surgery: a simplified technique. *Retina* 2003 (in press).
- 5 **Forster RE**, Petersen MR, Da Mata AP, *et al*. Negative indocyanine green staining of epiretinal membranes. *Retina* 2002;**22**:106-7.

Thermochemotherapy in hereditary retinoblastoma

Schueler and associates describe their experience with thermochemotherapy (TCT) in bilateral retinoblastoma.¹ The reported results of transpupillary thermotherapy used in combination with chemotherapy are encouraging, with 86-96% tumour control.^{2,3} In the current series, however, local recurrence occurred in 38%.

The dosage of carboplatin used in the current series was 10 mg/kg body weight, which is lower than the standard dosage of 18.6 mg/kg body weight.⁴ Lower dose of carboplatin, the key drug in the chemotherapy regimen for retinoblastoma, could have influenced the higher recurrence rate.

The authors mention that they treated submacular tumours with TCT. However, in our experience, tumours located in the macular area are better treated initially with chemotherapy for 3-6 cycles in order to achieve maximum possible reduction in tumour size before considering thermotherapy. Chemotherapy reduced macular tumours tend to shrink away from the fovea towards one of the major arcades or the optic nerve, thus exposing the foveal region. Residual tumours beyond 3-6 cycles of chemotherapy could be treated with thermotherapy. A smaller scar thus produced may optimise residual central vision.

The high mean total duration of thermotherapy in the current series is probably because of a smaller spot size of 0.4 mm. The diode laser (Iris Medical Inc, Mountain View, CA, USA) with an operating microscope adapter allows for a spot size of 0.8, 1.2, and 2.0 mm.³ The relatively newer large spot indirect ophthalmoscope delivery system provides a 1.2 mm spot size.³ A larger spot size will indeed reduce the duration of thermotherapy and allow for a more uniform coverage. Corneal, iris, and lens complications are minimised with better convergent beam optical systems currently available.

We believe that with higher dose of carboplatin, staggered thermotherapy for submacular tumours, use of better optical systems for delivery and a larger spot size for thermotherapy, and judicious selection of cases, the tumour regression and vision salvage with TCT could be further optimised.

R Murthy, S G Honavar, M Naik, V A P Reddy
Ocular Oncology Service, LV Prasad Eye Institute, Hyderabad, India

Correspondence to: Santosh G Honavar, MD, Ocular Oncology Service, LV Prasad Eye Institute, LV Prasad

Marg, Banjara Hills, Hyderabad 500 034, India; honavar@lvpapeye.stph.net

Accepted for publication 21 April 2003

References

- 1 **Schueler AO**, Jurklics C, Heimann H, *et al*. Thermochemotherapy in hereditary retinoblastoma. *Br J Ophthalmol* 2003;**87**:90-5.
- 2 **Lumbraso L**, Doz F, Urbeita M, *et al*. Chemotherapeutic management of retinoblastoma. *Ophthalmology* 2002;**109**:1130-6.
- 3 **Shields CL**, Santos CM, Diniz W, *et al*. Thermotherapy for retinoblastoma. *Arch Ophthalmol* 1999;**117**:885-93.
- 4 **Shields CL**, Honavar SG, Shields JA, *et al*. Factors predictive of recurrence of retinal tumors, vitreous seeds, and subretinal seeds following chemoreduction for retinoblastoma. *Arch Ophthalmol* 2002;**120**:460-4.

Causes of severe visual impairment and blindness in children in Ethiopia

We read with great interest the article by Kello *et al*.¹ The authors have to be congratulated for the hard hitting and well written article. A current concern for people involved in paediatric eye care is the emergence of what is probably the third epidemic of retinopathy of prematurity (ROP) in developing countries.^{2,3} It is therefore significant that no case of ROP was found in the population screened in this study. Several factors could account for this.

- The very low or nil prevalence of ROP in countries such as Ethiopia, where the study was carried out, is most probably because of lack of intensive care facilities for premature infants and their low survival rates.
- The variation in the incidence of ROP between ethnic groups could also account for this, with the available evidence suggesting that African-American infants are less prone to severe outcome ROP than white infants.^{4,5}
- However, it is also important to note that the article mentions that children with mental retardation were not examined owing to the admission criteria of the blind schools that preclude their admission. This too could have accounted for the gross underestimation of the prevalence of ROP as suggested by Jacobson *et al*.⁶ In addition, these children with mental handicap could be suffering from cerebral palsy and would have been at high risk for ROP because of the higher incidence of retinal vascular anomalies associated with both cerebral ischaemia and prematurity.⁷
- A large number of infants had phthisis bulbi (51 cases). In children with bilateral phthisis bulbi, there is a possibility that an unknown proportion developed the condition secondary to end stage ROP.

In conclusion, if improvement in perinatal care occurs in Ethiopia, the overall numbers of children with ROP would increase as is seen in other developing countries like India with infant mortality rates (IMRs) between 10-60 per 1000 live births.³ Lack of ophthalmologists experienced in the management of ROP could be effectively circumvented by introduction of digital retina camera technol-

ogy to improve access to subspecialty care⁸ for cases requiring treatment. As a lower cost option, screening infants under 1200 g alone might be more cost effective⁹ and could be the first step, with modification of the screening guidelines made later, consequent to research undertaken within the country itself.

V Vedantham, P K Ratnagiri

Aravind Eye Hospital and Postgraduate Institute of Ophthalmology, Madurai, Tamil Nadu 625 020, India

Correspondence to: V Vedantham, Department of Retina-Vitreous, Aravind Eye Hospital and Postgraduate Institute of Ophthalmology, 1 Anna Nagar, Madurai, Tamil Nadu 625 020, India; drvvasumathy@yahoo.com

Accepted for publication 5 May 2003

References

- 1 **Kello AB**, Gilbert C. Causes of severe visual impairment and blindness in children in schools for the blind in Ethiopia. *Br J Ophthalmol* 2003;**87**:526-30.
- 2 **Wheatley CM**, Dickinson JL, Mackey DA, *et al*. Retinopathy of prematurity: recent advances in our understanding. *Arch Dis Child Fetal Neonatal Ed* 2002;**87**:F78-82.
- 3 **Gilbert C**, Rahi J, Eckstein M, *et al*. Retinopathy of prematurity in middle-income countries. *Lancet* 1997;**350**:12-14.
- 4 **Schaffer DB**, Palmer EA, Plotsky DF, *et al*. Prognostic factors in the natural course of retinopathy of prematurity. *Ophthalmology* 1993;**100**:230-7.
- 5 **Saunders RA**, Donahue ML, Christmann LM, *et al*. Racial variation in retinopathy of prematurity. *Arch Ophthalmol* 1997;**115**:604-8.
- 6 **Jacobson I**, Fennell E, Broberger U, *et al*. Children with blindness due to retinopathy of prematurity: a population-based study. Perinatal data, neurological and ophthalmological outcome. *Dev Med Child Neurol* 1998;**40**:155-9.
- 7 **Pennefather PM**, Tin W. Ocular abnormalities associated with cerebral palsy after preterm birth. *Eye* 2000;**14**:78-81.
- 8 **Schwartz DS**, Harrison SA, Ferrone PJ, *et al*. Telemedical evaluation and management of retinopathy of prematurity using a fiberoptic digital fundus camera. *Ophthalmology* 2000;**107**:25-8.
- 9 **Lee SK**, Normand C, McMillan D, *et al*. Evidence for changing guidelines for routine screening for retinopathy of prematurity. *Arch Pediatr Adolesc Med* 2001;**155**:387-95.

CORRECTIONS

An error occurred in the author listings for two letters in the September issue. In the letter by Lee *et al* (*Br J Ophthalmol* 2003;**87**:1184-5) the order should be D K Lee, E B Suhler, W Augustin, R R Buggage.

In the letter by Buggage *et al* (*Br J Ophthalmol* 2003;**87**:1190-1) the order should be R R Buggage, D G Callanan, D F Shen, C-C Chen. The journal apologises for the error.

In the article by Williamson *et al* in the September issue (*Br J Ophthalmol* 2003;**87**:1126-9), the author list contained an error. The correct spelling is N Strouthidis. The journal apologises for the error.

In the article by Courtright *et al* in the September issue (*Br J Ophthalmol* 2003;**87**:1079-82), the author list contained an error. The correct spelling is A Hoehmann. The journal apologises for the error.

NOTICES

Elimination of avoidable blindness

The latest issue of *Community Eye Health* (No 46) discusses the resolution of the World Health assembly on the elimination of avoidable blindness. For further information please contact: Journal of Community Eye Health, International Resource Centre, International Centre for Eye Health, Department of Infectious and Tropical Diseases, London School of Hygiene and Tropical Medicine, Keppel Street, London WC1E 7HT, UK (tel: +44 (0)20 7612 7964; email: Anita.Shah@lshtm.ac.uk; website: www.jceh.co.uk). Annual subscription (4 issues) UK £28/US\$45. Free to developing country applicants.

Second sight

Second Sight, a UK based charity whose aims are to eliminate the backlog of cataract blind in India by the year 2020 and to establish strong links between Indian and British ophthalmologists, is regularly sending volunteer surgeons to India. Details can be found at the charity's website (www.secondsight.org.uk) or by contacting Dr Lucy Mathen (lucymathen@yahoo.com).

Specific Eye ConditionS (SPECS)

Specific Eye ConditionS (SPECS) is a not for profit organisation which acts as an umbrella organisation for support groups of any conditions or syndrome with an integral eye disorder. SPECS represents over 50 different organisations related to eye disorders ranging from conditions that are relatively common to very rare syndromes. The website acts as a portal giving direct access to support groups' own websites. The SPECS web page is a valuable resource for professionals and may also be of interest to people with a visual impairment or who are blind. For further details about SPECS, contact: Kay Parkinson, SPECS Development Officer (tel: +44 (0)1803 524238; email: k@eyeconditions.org.uk; website: www.eyecconditions.org.uk).

The British Retinitis Pigmentosa Society

The British Retinitis Pigmentosa Society (BRPS) was formed in 1975 to bring together people with retinitis pigmentosa and their families. The principle aims of BRPS are to raise funds to support the programme of medical research into an eventual cure for this hereditary disease, and through the BRPS welfare service, help members and their families cope with the everyday concerns caused by retinitis pigmentosa. Part of the welfare service is the telephone help line (+44 (0)1280 860 363) for any queries relating to retinitis pigmentosa, especially for those recently diagnosed with retinitis pigmentosa (tel: +44 (0)1280 821 334; email: lynda@brps.demon.co.uk; website: www.brps.demon.co.uk).

Surgical Eye Expeditions International

Volunteer ophthalmologists in active surgical practice are needed to participate in short term, sight restoring eye surgery clinics around the world. Contact: Harry S Brown, Surgical Eye Expeditions International, 27 East De La Guerra, C-2, Santa Barbara, CA

93101-9858, USA (tel: +805 963 3303; fax: +805 965 3564; email: hsbrown.md@cox.net or seeintl@seeintl.org; website: www.seeintl.org).

Rise in organ transplant numbers

According to UK Transplant, the UK has seen the highest number of organ transplants in six years. Last year (1 April 2002 to 31 March 2003), 2777 patients had their lives saved or dramatically improved through the generosity of 1064 donors. This equated to a 6% increase compared to the previous 12 months (1 April 2001 to 31 March 2002). Furthermore, during 2002-3, the highest number of people benefited from a cornea transplant for five years (1997-98) and 240 more people had their sight restored than the previous year. For further information see UK Transplant's website (www.uktransplant.org.uk).

Elimination of avoidable blindness

The 56th World Health Assembly (WHA) considered the report on the elimination of avoidable blindness (doc A56/26) and urged Member States to: (1) Commit themselves to supporting the Global Initiative for the Elimination of Avoidable Blindness by setting up a national Vision 2020 plan by 2005; (2) Establish a national coordinating committee for Vision 2020, or a national blindness prevention committee to help implement the plan; (3) Implement the plan by 2007; (4) Include effective monitoring and evaluation of the plan with the aim of showing a reduction in the magnitude of avoidable blindness by 2010; (5) To support the mobilisation of resources for eliminating avoidable blindness. The WHA also urged the Director-General to maintain and strengthen WHO's collaboration with Member States and the partners of the Global Initiative for the Elimination of Avoidable Blindness as well as aid in the coordination and support of national capability.

Glaucoma Society 24th Annual Meeting and Dinner

The Glaucoma Society 24th Annual Meeting and Dinner will take place on 20 November 2003, from 8:30 am to 5:00 pm at The Royal College of Physicians, London, UK. Further details: Ms Janet Flowers (email: glausoc@ukeire.freereserve.co.uk).

Detachment course with international faculty on: retinal and vitreous surgery with case presentations preceding the annual meeting of Iranian Society of Ophthalmology

The detachment course with international faculty on: Retinal and Vitreous Surgery with Case Presentations preceding the Annual Meeting of Iranian Society of Ophthalmology will be held on 29-30 November 2003 and 1-4 December 2003 respectively, at the Razi Conference Center, Hemmat Hyw, Tehran, Iran. Further details: Scientific programme: Prof Ingrid Kreissig, University of Tuebingen, Schleichstr. 12, Breuningerbau, 72076 Tuebingen, Germany (tel: +49 7071 295209; email: ingrid.kreissig@med.uni-tuebingen.de). Local organisation: Dr Arman Mashekyehi, Dr Siamak Moradian, Dept of Ophthalmology, Labbanfinejad Medical Center, Pasdaran

Ave, Boostan 9, Tehran, 16666, Iran (fax: +98 21 254 9039; email: labbafi@hotmail.com).

5th International Symposium on Ocular Pharmacology and Therapeutics (ISOPT)

The 5th International Symposium on Ocular Pharmacology and Therapeutics (ISOPT) will take place 11-14 March 2004, in Monte Carlo, Monaco. Please visit our website for details of the scientific programme, registration, and accommodation. To receive a copy of the Call for Abstracts and registration brochure, please submit your full mailing details to <http://www.kenes.com/isopt/interest.htm>. Further details: ISOPT Secretariat (website: www.kenes.com/isopt).

XVth Meeting of the International Neuro-Ophthalmology Society

The XVth Meeting of the International Neuro-Ophthalmology Society will take place 18-22 July 2004, in Geneva, Switzerland. Further details: Prof. A Safran, University Hospital Geneva, c/o SYMPORG SA, Geneva (fax: +4122 839 8484; email: info@symporg.ch; website: www.symporg.ch).

4th International Congress on Autoimmunity

The 4th International Congress on Autoimmunity will take place 3-7 November 2004 in Budapest, Hungary. The deadline for the receipt of abstracts is 20 June 2004. Further details: Kenes International Global Congress Organisers and Association Management Services, 17 Rue du Cendrier, PO Box 1726, CH-1211 Geneva 1, Switzerland (tel: +41 22 908 0488; fax: +41 22 732 2850; email: autoim04@kenes.com; website: www.kenes.com/autoim2004).

Wake up call as dream time deadline looms

Scientists have less than a month left to apply for a new Dream Time award from NESTA, the organisation that invests in UK creativity and innovation. Dream Time supports exceptional achievers (with at least 10 years experience in their field) who want time to experiment or follow a passion, but who intend to continue with their career and put what they have discovered to good use. Up to 12 exceptional individuals from the fields of science, technology and the arts will each receive up to £40,000 to pursue their goals and push at the boundaries of knowledge and practice. NESTA is looking for people who can demonstrate evidence of exceptional achievement. This would include a significant body of work collated over at least a decade in their field, the ability to work in new ways and a commitment to the proposed area of exploration. Dream Time is a development of NESTA's existing Fellowship Programme, which has helped talented and creative individuals to innovate and explore new ideas emerging through periods of personal development. As with all its awards, NESTA is looking for people who demonstrate excellence, promise, creativity, innovation and commitment. Funding can be used on a full- or part-time basis, in tandem with professional careers or temporarily away from the constraints of employment. Offered awards can be for any period of time up to

one year. Dream Time Fellows will be asked to provide 10% in kind support for their plan and will be required to plan ways of disseminating their findings with their professional community. To apply, visit NESTA's website: www.nesta.org.uk/dreamtime.

14th Meeting of the EASD Eye Complication study group

The 14th Meeting of the EASD Eye Complication (EASDEC) study group will take place on the 21–23 May 2004. There will be key lecture notes on the following topics:

Peter Gaede (Denmark)—Results of the Steno 2 study, Hans Peter Hammes (Germany)—Animal models of diabetic retinopathy, Massimo Porta (Italy)—Screening with the London protocols: 12 years after, and Anselm Kampik (Germany)—Surgical options in diabetic retinopathy. There will also be case presentations and oral and poster presentations. The EASDEC board comprises F Bandello (President), PJ Guillausseau (Vice President), C-D Agardh (Past President), P Massin (Secretary), M Porta (Treasurer). The Scientific and Organizing Committee includes: F Bandello, PJ Guillausseau, P

Massin, C-D Agardh, M Porta, A Kampik, M Ulbig, and G Lang. There are three travel grants available, at 1000 Euro each, for young scientists (less than 35 years at the time of the meeting). Application for the grant should be made together with the submission of the abstract. For further information, contact: Department of Ophthalmology, Ingrid Mannl, Ludwig-Maximilians-University, Mathildenstr. 8, 80336 Munich, Germany (tel: +49-89-5160-3800; fax: +49 89 5160 4778; e-mail: easdec@ak-i.med.uni-muenchen.de). The deadline for abstracts is 2 March 2004.



Want full text but don't have
a subscription?

Pay per view

For just \$8 you can purchase the full text of individual articles using our secure online ordering service. You will have access to the full text of the relevant article for 48 hours during which time you may download and print the pdf file for personal use.

www.bjophthalmol.com



Trypan blue stains the epiretinal membrane but not the internal limiting membrane

E B Rodrigues, C H Meyer, J C Schmidt, et al.

Br J Ophthalmol 2003 87: 1431-1432

doi: 10.1136/bjo.87.11.1431-a

Updated information and services can be found at:

<http://bjo.bmj.com/content/87/11/1431.2.full.html>

References

These include:

This article cites 4 articles, 1 of which can be accessed free at:

<http://bjo.bmj.com/content/87/11/1431.2.full.html#ref-list-1>

Article cited in:

<http://bjo.bmj.com/content/87/11/1431.2.full.html#related-urls>

Email alerting service

Receive free email alerts when new articles cite this article. Sign up in the box at the top right corner of the online article.

Notes

To request permissions go to:

<http://group.bmj.com/group/rights-licensing/permissions>

To order reprints go to:

<http://journals.bmj.com/cgi/reprintform>

To subscribe to BMJ go to:

<http://group.bmj.com/subscribe/>