

BJO at a glance

Creig Hoyt, Editor

THE BURDEN OF CATARACT IN TIBET

That cataract remains a significant cause of blindness in much of the underdeveloped part of the world is well known. Dunzhu and coworkers, in a study of blindness in Tibet, emphasise the high prevalence of age related cataract blindness among Tibetans. This may perhaps be the result of high altitude ultraviolet light exposure. As elsewhere in the world women have an excess burden of blindness compared to men in Tibet.

See p1443

PROPHYLAXIS FOR OPHTHALMIA NEONATORUM

Isenberg and coworkers pioneered the widespread use of 2.5% povidone-iodine ophthalmic solution in an effort to prevent ophthalmia neonatorum. In a 1995 study they demonstrated that povidone-iodine was more effective than erythromycin or silver nitrate for prophylaxis of ophthalmia neonatorum in a large study in Kenya. Moreover, it was less toxic. They now present the results of a study comparing two drops with one drop of 2.5% povidone-iodine in another study conducted in Kenya. This study would suggest that there is no advantage to administering twice a day therapy as opposed to once a day therapy. The most common infectious

cause of ophthalmia neonatorum in these patients appears to be *Chlamydia trachomatis*. Isenberg's study supports the original notion of Crede in 1881 that a single drop of an effective medication given at birth is the best way to prevent the development of neonatorum.

See p 1449

OUTCOMES OF SCLERAL FIXATED POSTERIOR INTRAOCULAR LENSES

In the presence of a posterior capsule tear during cataract extraction the intraocular lens can be placed in the sulcus if the capsular rim is available or in the bag if the tear is small. When the posterior capsule tear is large or the capsular rim is unstable scleral fixated intraocular lenses or anterior chamber intraocular lenses can be implanted. There is no consensus currently as to the optimal method for intraocular lens implantation without capsular support. Lee and coworkers assessed and compared the results of primary and secondary implantation of scleral fixated posterior chamber intraocular lenses in series of 55 patients. In this study secondary implantation after cataract extraction seemed to have a lower early complication rate than primary implantation, although the final visual acuity and late complication rates did not seem to be significantly different.

See p 1459

DETECTING INTERNAL CAROTID ARTERY DISEASE

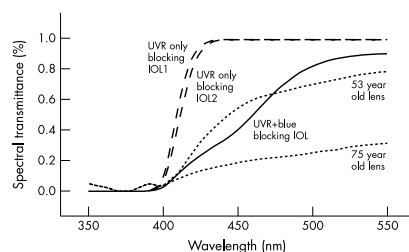
Stenosis of the internal artery has been associated with a number of ocular disorders especially the ocular ischaemic syndrome, glaucoma, and vascular occlusions. Barkana and coworkers investigated the use of pulsatile ocular blood flow to detect internal carotid artery disease. By repeatedly measuring the intraocular pressure with a pneumatic applanation tonometer during the cardiac pulse cycle and base-on intraocular pressure variation with time the authors are able to calculate the pulsatile ocular blood flow. In this study a low or unrecordable pulsatile ocular blood flow was associated with severe stenosis of the internal carotid artery. Although the pulsatile ocular blood flow is not a direct reflection of ipsilateral internal carotid artery blood flow, this technique may be a reasonably inexpensive screening device for the presence of clinically significant internal carotid artery stenosis.

See p 1478

INTRAOCULAR LENSES AND THE TRANSMISSION OF BLUE LIGHT

Older and even some more modern intraocular lenses transmit potentially hazardous ultraviolet radiation to the retina. Moreover, intraocular lenses transmit more blue and green light to the retina for scotopic vision than the human crystalline lens. This light is also potentially hazardous. Ultraviolet blue type phototoxicity increases with decreasing wavelength. Therefore, ultraviolet blue absorbing intraocular lenses should provide better retinal protection but worse scotopic sensitivity than ultraviolet only absorbing intraocular lenses. Mainster and Sparrow review the action spectrum of retinal phototoxicity potentially involved in human retinal ageing and the amount of shorter wavelength blue light required for older adults to perform essential activities in dimly lit environments. They then suggest the design possibilities for intraocular lens filtration of blue light.

See p 1523



See p 1523



BJO at a glance

Creig Hoyt

Br J Ophthalmol 2003 87: 1437

doi: 10.1136/bjo.87.12.1437-b

Updated information and services can be found at:

<http://bjo.bmj.com/content/87/12/1437.3.full.html>

These include:

**Email alerting
service**

Receive free email alerts when new articles cite this article. Sign up in the box at the top right corner of the online article.

Notes

To request permissions go to:

<http://group.bmj.com/group/rights-licensing/permissions>

To order reprints go to:

<http://journals.bmj.com/cgi/reprintform>

To subscribe to BMJ go to:

<http://group.bmj.com/subscribe/>