

CLINICAL SCIENCE

Blood flow per unit retinal nerve fibre tissue volume is lower in the human inferior retina

A Harris, Y Ishii, H S Chung, C P Jonescu-Cuypers, L J McCranor, L Kagemann, H J Garzozzi

Br J Ophthalmol 2003;**87**:184–188

Aim: To determine if perfusion per unit tissue volume of retinal nerve fibre layer and optic nerve head in the inferior sector is lower than in the superior sector.

Methods: Heidelberg retinal tomogram (HRT) for topographic measurement of optic nerve head and retinal nerve fibre layer and Heidelberg retinal flowmeter (HRF) for retinal blood flow were performed on 19 normal healthy subjects. Measurements from the superior and inferior sectors were compared. The perfusion/nerve fibre ratio (PNR); the blood flow per unit retinal nerve fibre tissue volume, was calculated in each sector with a formula; HRF flow measurements divided by HRT measurements.

Results: Retinal nerve fibre layer thickness in the inferior retina was significantly higher than in the superior retina ($p < 0.05$). There were, however, no differences in retinal blood flow between the superior and inferior retinal sectors. The PNR in the inferior sector were significantly lower than in the superior sector ($p = 0.047$ for HRF mean flow/rim volume and $p = 0.0282$ for HRF 75th percentile flow/rim volume).

Conclusions: The inferior sector of retinal nerve fibre layer and optic nerve head may have lower blood flow per unit nerve tissue volume compared to the superior sector. This result suggests that the inferior sector is more vulnerable to elevated intraocular pressure (IOP) and ischaemic insults in glaucomatous optic neuropathy.

See end of article for authors' affiliations

Correspondence to:
Alon Harris, PhD,
702 Rotary Circle, Rm
137, Indianapolis, IN
46202, USA;
alharris@indiana.edu

Accepted for publication
15 July 2002

Glaucomatous visual field defects are more commonly found in the superior visual field than in the inferior field.¹ Glaucomatous pathological findings such as notching of the rim,² disc haemorrhage,³ and peripapillary choroidal atrophy⁴ are more commonly found in the inferior hemisphere than in the superior hemisphere. One histopathological study⁵ reported that ganglion cell loss is more severe in the inferior hemiretina than the superior hemiretina. These findings suggest that retinal ganglion cells and their axons in the inferior retina are more vulnerable to glaucomatous damage than those in the superior retina. One group suggests that comparative differences in vascular reactivity to blood gas perturbations between the superior and inferior retina may explain this finding.⁶

It is well known that the nerve fibre layer is thicker in the inferior retina than in the superior retina.⁷ Therefore the metabolic demand may be higher in the inferior retina. Consequently, the inferior retina would need a greater blood supply than the superior retina to compensate for the difference in volume of retinal ganglion cells and their axons. We performed this study to determine if the blood flow per unit retinal nerve fibre tissue volume and optic nerve head in the inferior sector is lower than in the superior sector.

METHODS

Subjects

Nineteen young healthy subjects (mean age 29 (SD 5) years, range 20–38; 10 females and nine males) participated in the study. All subjects had normal eye examinations and were free from any history or evidence of ocular disease. Each individual had a corrected visual acuity of 20/25 or better and a refractive error not exceeding 5.00 dioptre sphere and/or 2.00 dioptre cylinder. Subjects with opaque optical media (for example, moderate to severe cataract) were excluded.

Intraocular pressure (IOP) was measured using a Goldmann applanation tonometer to confirm that the measurements were < 21 mm Hg. All potential subjects underwent an

achromatic visual field test with a Humphrey visual field analyser (using a central 24-2 or 30-2 SITA standard program) to confirm normal visual fields. Visual field reliability criteria included subjects with fewer than 25% fixation losses, and fewer than 25% false positive and false negative responses. Subjects did not have any family history of glaucoma, and were not receiving any ocular or systemic medications. Subjects with diabetes mellitus or cardiovascular disorders, such as systemic hypertension or arrhythmias were excluded. None of the subjects were pregnant or anticipating pregnancy at the time of the study. Before participating, subjects signed an informed consent statement outlining all procedures that had been reviewed and approved by an institutional review board. All experimental procedures conformed to the tenets of the Declaration of Helsinki.

Experimental design

A cross sectional study design was followed. One eye from each subject was randomly selected for the study using a randomisation table. Retinal nerve fibre layer thickness was measured using confocal scanning laser retina tomography (Heidelberg Retina Tomogram: HRT, Heidelberg Engineering, Heidelberg, Germany). Confocal scanning laser Doppler flowmetry (Heidelberg Retinal Flowmeter: HRF, Heidelberg Engineering, Heidelberg, Germany) was used to assess haemodynamics in the peripapillary retinal capillary bed.

Confocal scanning laser retinal tomography

Topographic measurements of optic nerve head and retinal nerve fibre layer were obtained with the HRT. HRT measurements are highly reproducible.⁸ In brief, HRT scans the optic disc and the surrounding peripapillary retina through an undilated pupil with a diode laser. Each image consists of 256×256 pixels; each pixel represents the retinal height at that location relative to the focal plane of the eye. The light reflected from each single point is registered, digitised, and

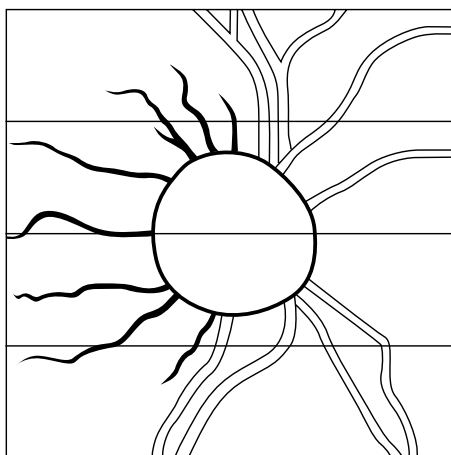


Figure 1 Transparent overlay copy with drawn reference points such as disc margin and major retinal vessels. Each rectangle is matched for one screen image of HRF.

then stored in a computer. To obtain three dimensional information, the retina and/or optic nerve head is examined layer by layer using 32 optical section images parallel to the retinal surface at different focal planes. These sections are then stored in the computer and constructed into a three dimensional image.

Three images were obtained on one undilated eye of each subject. The mean topographic values of the three consecutive images were analysed by the HRT software, version 2.01. The average standard deviation (of each pixel is three height values) was less than 22 μm .⁹ The contour line for the optic disc was outlined manually by a single experienced ophthalmologist (CJ). According to software version 2.01, the reference plane for the delineation of the optic cup from the neuroretinal rim was the level 50 μm beneath the contour line in the temporal segment, 4–10 degrees below the horizontal axis of the optic disc.

HRT assessment of disc area, cup/disc ratio, rim area, rim volume, cup shape measure, mean retinal nerve fibre layer thickness (MRNFLT), and retinal nerve fibre layer cross sectional area (RNFLCA) was evaluated. HRT parameters were described in detail previously.¹⁰

Confocal scanning laser Doppler flowmetry

The HRF utilises a low intensity infrared laser beam that scans the fundus through the undilated pupil. Moving red blood cells strike the beam causing some portion of the reflected light to be Doppler shifted. Shifts within the reflected light are analysed to determine the velocities present within the scanned tissue. The amplitude of Doppler shifts allows determination of the volume of moving blood. Velocity and volume information are combined in order to compute total blood flow. Subjects fixated on a static target 3 metres away, and 15 degree field HRF images were taken. To include the superior and the inferior peripapillary retina area, four contiguous HRF images were taken. A transparent overlay with drawn reference points such as disc margin and major retinal vessels was applied to the monitor to correctly align each HRF image field (Fig 1). Images were focused on the superficial retina, and the four images of each subject had the same focus setting and similar brightness.

Image analysis

The images obtained by the HRT and HRF were divided into four sectors (Fig 2). The superior and inferior sectors were defined at 120 degrees. The nasal and temporal sectors were defined at 70 and 50 degrees, respectively. To determine the retinal area in each sector of HRF analysis, an elliptical line

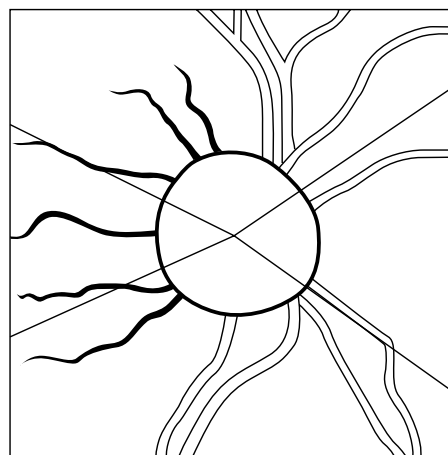


Figure 2 The image obtained by the HRT and HRF divided into the four sectors. Superior and inferior sectors are defined at 120 degrees. Nasal and temporal sectors are defined at 70 and 50 degrees.

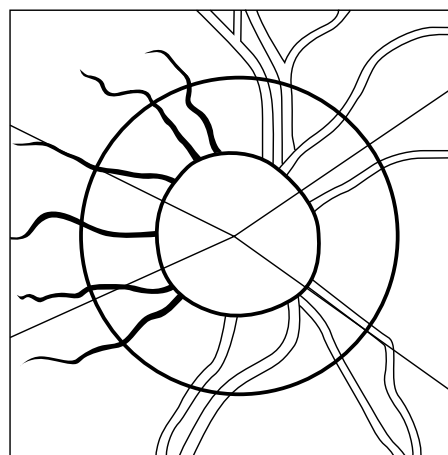


Figure 3 The ellipse line placed at 1.75 disc diameter. The area of HRF between the disc margin and the elliptical line is analysed.

was placed at 1.75 disc diameter. The area of HRF between the disc margin (transferred from the HRT contour line) and the elliptical line was analysed (Fig 3). The blood flow histograms of HRF images were generated from pixel by pixel analysis¹¹ of qualified retinal areas. Pixels were excluded from the cup and rim, major blood vessels, artefact lines from movement saccades, and areas with unacceptable levels of brightness (brightness (DC) value <70 or >200). The flow in pixels at the mean, the 50th, and 75th percentile in each category were used for analysis.

The perfusion/nerve fibre ratio (PNR)

To evaluate perfusion state per unit retinal nerve fibre layer tissue volume, we created a ratio; the perfusion/nerve fibre ratio (PNR); the blood flow per unit retinal nerve fibre tissue volume. The PNR was calculated by the following formula:

$$\text{PNR} = \text{HRF flow measurements} \div \text{HRT measurements}$$

HRF flow measurements: HRF mean flow, HRF 50th percentile flow, and HRF 75th percentile flow.

HRT measurements: MRNFLT, RNFLCA, rim area, and rim volume.

Statistical analysis

A two tailed, paired *t* test was applied to compare measurements from each technique. This study was designed to have

Table 1 Eleven shape parameters automatically extracted from the optic nerve head (ONH) topography image of the superior and inferior retinal sectors

| HRT parameters | Superior | | Inferior | | p Value |
|-------------------------------|----------|-------|----------|-------|----------|
| | Mean | SD | Mean | SD | |
| Disc area (mm ²) | 0.675 | 0.164 | 0.679 | 0.164 | 0.3217 |
| Cup area (mm ²) | 0.183 | 0.146 | 0.138 | 0.124 | 0.0008** |
| Cup/disc ratio | 0.246 | 0.166 | 0.187 | 0.141 | 0.0022** |
| Rim area (mm ²) | 0.493 | 0.114 | 0.541 | 0.134 | 0.0003** |
| Cup volume (mm ³) | 0.049 | 0.055 | 0.031 | 0.039 | 0.0017** |
| Rim volume (mm ³) | 0.12 | 0.052 | 0.148 | 0.067 | 0.0018** |
| Mean cup depth | 0.214 | 0.095 | 0.176 | 0.075 | 0.0027** |
| Maximum cup depth | 0.567 | 0.194 | 0.503 | 0.177 | 0.0014** |
| Cup shape | -0.032 | 0.207 | -0.185 | 0.129 | 0.0071** |
| RNFL (mm) | 0.255 | 0.056 | 0.279 | 0.059 | 0.0344* |
| RNFL CRA (mm ²) | 0.427 | 0.116 | 0.467 | 0.128 | 0.0227* |

RNFL = retinal nerve fibre layer thickness; RNFL CRA = retinal nerve fibre layer, cross sectional area; *p<0.05; **p<0.01.

Table 2 Blood flow of the superior and inferior retinal sectors (mean (SD))

| HRF parameter | Superior | Inferior | p Value |
|--------------------------|--------------|--------------|---------|
| Mean flow | 188.2 (32.0) | 193.5 (33.8) | 0.5328 |
| Flow at 50th percentiles | 149.5 (27.9) | 156.6 (33.0) | 0.4402 |
| Flow at 75th percentiles | 281.9 (43.3) | 287.2 (50.7) | 0.642 |

All data presented as arbitrary units.

Table 3 The perfusion/nerve fibre ratio (PNR) of the superior and inferior retinal sectors

| Ratio | Superior | | Inferior | | p Value |
|-------------------------------------|----------|--------|----------|--------|---------|
| HRF mean flow/RNFL | 792.5 | 310.9 | 721.7 | 196.9 | 0.2543 |
| HRF mean flow/RNFL CRA | 483.3 | 201.0 | 438.8 | 125.7 | 0.2341 |
| HRF mean flow/rim area | 401.7 | 121.2 | 375.1 | 105.9 | 0.26 |
| HRF mean flow/rim volume | 1946.4 | 1176.9 | 1532.8 | 708.4 | 0.047* |
| HRF 50th percentile flow/RNFL | 628.4 | 249.6 | 581.4 | 165.8 | 0.3779 |
| HRF 50th percentile flow/RNFL CRA | 383.1 | 163.9 | 352.2 | 101.5 | 0.4012 |
| HRF 50th percentile flow/rim area | 317.7 | 95.1 | 301.97 | 87.7 | 0.4727 |
| HRF 50th percentile flow/rim volume | 1540.1 | 936.6 | 1232.5 | 582.0 | 0.0625 |
| HRF 75th percentile flow/RNFL | 1185.1 | 448.3 | 1072.2 | 297.0 | 0.179 |
| HRF 75th percentile flow/RNFL CRA | 722.0 | 286.3 | 650.9 | 180.6 | 0.218 |
| HRF 75th percentile flow/rim area | 601.4 | 174.2 | 556.7 | 155.2 | 0.1635 |
| HRF 75th percentile flow/rim volume | 2916.4 | 1753.9 | 2279.4 | 1060.7 | 0.0282* |

*p<0.05.

at least 90% power of detecting a 15% difference of HRT and HRF respectively. Data were presented as the mean (SD). Statistical significance was determined with a p value less than 0.05.

RESULTS

HRT measurements of optic nerve head and retinal nerve fibre layer (Table 1)

There was no statistically significant difference in disc area between the superior and inferior sectors. Measurements of cup area, cup/disc ratio, cup volume, mean cup depth, and maximum cup depth in the superior sector were significantly higher than in the inferior sector. Measurements of rim area, rim volume, and cup shape in the superior sector were statistically significantly lower than in the inferior sector. The inferior sector of the optic nerve head has less cupping and more neuroretinal rim than the superior sector of the optic nerve head.

Retina nerve fibre layer measurements (MRNFL and RNFLCA) in the inferior retina were significantly higher than in the superior retina.

HRF measurements of retinal capillary blood flow in the nerve fibre layer (Table 2)

There were no statistically significant differences in retinal blood flow, the flow within pixels at 50th and 75th percentiles, or the mean flow between the superior and inferior retinal sectors.

The perfusion/nerve fibre ratio (PNR) (Table 3)

The PNR was calculated for the superior and inferior sectors. Two (HRF mean flow/rim volume and HRF 75th percentile flow/rim volume) in the inferior sector were significantly lower than in the superior sector (p=0.047 and 0.0282, respectively).

DISCUSSION

The relation between capillary blood flow of the retina measured by confocal scanning laser Doppler flowmetry (HRF) and morphological characteristics of the optic nerve disc including nerve fibre layer thickness measured by confocal scanning laser Doppler tomography (HRT) were evaluated in this experiment. We found statistically significant differences of the PNR between the superior and inferior sectors.

There is evidence that ischaemia in peripheral nerves clearly leads to neuropathy.¹² This observation may be an important risk factor for the development of the excavation of the optic nerve head in patients with glaucoma.

The ophthalmoscopic appearance of the optic nerve head is generally that of a vertical oval, although there is considerable variation in size and shape. As previously noted, the neural rim of the normal optic nerve head is typically broadest in the inferior quadrant, followed by the superior and then the nasal rims, with the temporal rim being the thinnest.^{7 12-14} In contrast with the normal optic nerve head, the inferior temporal rim in the glaucomatous eye is usually thinner than the superior temporal area.¹⁵ Thus, the greatest difference in retinal nerve fibre layer height between healthy individuals and those with glaucoma is found in the inferior sector.¹⁶

Numerous studies describe the characteristics of visual field defects found in patients with glaucoma. Early visual field loss in glaucoma commonly occurs within this arcuate area, especially in the superior hemifield.¹ This correlates with selective loss of neural rim tissue occurring primarily in the inferotemporal region of the optic nerve head.^{1 17-19} The different manifestations of glaucomatous visual field defects between superior and inferior fields are supported by the morphological differences in the optic nerve head and peripapillary retina.

Wollstein *et al* reported that the best hallmark to detect the glaucoma is examining the relation between disc size, rim area, and cup/disc ratio. Their data suggest that the cup/disc ratio of the temporal inferior plus nasal inferior has the highest specificity to detect glaucoma.²⁰ Jonas *et al* reported that the inferior neuroretinal rim has the highest correlation with the progression of the glaucoma.²¹ Disc haemorrhage³ and peripapillary choroidal atrophy⁴ are also more commonly found in the inferior hemisphere than in the superior hemisphere. Notching of the rim also often begins in the inferotemporal quadrant.^{1 2} These findings suggest that vascular pathological episodes are more common in the inferior area and may explain the differences between superior and inferior visual field defect in glaucoma patients. More direct evidence was provided by one experimental histopathological study of monkeys.²² In glaucomatous eyes, the inferior retina had significantly more large cell loss than the corresponding areas of the superior retina.

In addition, we confirmed differences in the morphological characteristics of the optic nerve head between the superior and inferior sectors in normal subjects using HRT. Measurements of cup area, cup/disc area ratio, cup volume, mean cup depth, and maximum cup depth in the superior sector were significantly higher than in the inferior sector. Measurements of cup shape in the superior sector were significantly lower than in the inferior sector. These findings indicate that the inferior retina has more retinal nerve fibres than the superior retina, consequently resulting in differences between the superior and inferior sector of the optic nerve head.

Considering all this evidence, it is likely that the inferior retinal nerve fibres are more susceptible to glaucomatous damage than superior retinal nerve fibres. Nevertheless, there is a lack of explanation for this difference between the superior and inferior sectors in glaucomatous optic neuropathy. Mechanical damage to retinal nerve fibres by increased IOP cannot explain these pathological characteristics. If IOP is the primary factor, superior and inferior nerve fibres should demonstrate equal loss. Henceforth, the inferior nerve fibre would remain healthier than the superior since the inferior sector has a thicker retinal nerve fibre.¹²⁻¹⁴ This would result in visual field defects being more common in the inferior field. This study suggests that although the inferior rim is bulky, it is more easily altered in shape and loss of optic nerve fibre, probably caused by factors other than IOP.

To test this vascular hypothesis for the superior versus inferior difference in glaucoma, Chung *et al* evaluated the haemodynamic response to blood gas perturbations in the superior

and inferior retina in healthy subjects using the HRF. They reported that the inferior retina can only respond to isocapnic hyperoxia (100% O₂ breathing), which reduces the mean blood flow and is related with endothelin-1, while the superior retina can only respond to isoxic hypercapnia (Pco₂ increased 15% above baseline), which increases mean flow.⁶ Therefore, the vessels of these two sectors respond oppositely. The high sensitivity of the inferior retina to O₂, which is a vasoconstrictor, might be one of the possible pathophysiological factors for the superior versus inferior difference in glaucoma. Chung *et al* also applied the same study on glaucoma patients who have vertical asymmetric visual field defect. In that study, the hemiretina with the visual field defect showed significant blood flow decrease during hyperoxia. In contrast, the opposing side hemiretina with the normal field did not show blood flow change during hyperoxia.²³

A plethora of blood flow measurement techniques have been introduced during the past two decades. A single technique can measure a specific anatomic location, and not the entire ocular vasculature such as the retinal, choroidal, retrolubar vessels, and so on. Therefore, choosing the appropriate technique in the study of blood flow is very important to produce suitable outcomes for the particular purpose. In this study we are specifically interested in the nerve fibre layer and its blood flow. Superficial retinal capillaries are located in the retinal nerve fibre layer. Therefore, blood flow in these capillaries may be closely related to the physiological status of retinal nerve fibre layer and neighbouring retinal ganglion cells. To measure the haemodynamic status of superficial retinal capillaries, HRF is probably the most suitable technique because of its unique features. The HRF measures flow from a volume of tissue within a focal plane thickness of 400 µm. Retinal capillaries are mostly located in the superficial retina, more specifically, the retinal nerve fibre layer. Hence, the HRF measurements are mostly from the superficial retinal capillaries, and considered to be the total retinal capillary flow measurement.

We compared the blood flow between the superior and inferior retina. When we compared the total blood flow there was no statistically significant difference in the retinal blood flow between the two sectors. However, by using the PNR, new perfusion state indicator, we are able to detect the fact that the inferior sector of retinal nerve fibre layer and optic nerve head may have lower blood flow per unit retinal nerve fibre tissue volume compared to the superior sector.

Glaucoma changes the shape of the optic nerve head and it linearly correlates with change in the number of optic nerve fibres,²⁴ with the rim volume representing the number of retinal nerve fibres.²⁵ The rim volume has the highest association with retinal nerve fibre layer height, which seems more representative of the total nerve fibre population entering the optic nerve head than the surface area of the disc occupied by nerve tissue.^{26 27} The PNR showed that blood flow per unit retinal nerve fibre volume was lower in the inferior area than the superior area, even though the metabolic demand may be higher in the inferior retina than in the superior retina. Consequently, the inferior retina requires an enhanced blood supply compared to the superior retina to compensate for the difference in the number of retinal ganglion cells and their axons. Our results suggest that capillary density in the normal inferior portion of the "optic nerve to be" is reduced at baseline, before any disease process.

In conclusion, although the inferior sector has a thicker nerve fibre layer in a healthy retina, it may be more vulnerable to glaucomatous damage because of its lower blood flow per retinal nerve fibre.

ACKNOWLEDGEMENT

Supported by an unrestricted grant from Research to Prevent Blindness.

.....

Authors' affiliations

A Harris, Y Ishii, H S Chung, C P Jonescu-Cuypers, L J McCranor, L Kagemann, Department of Ophthalmology, Indiana University School of Medicine, Indianapolis, IN, USA
H J Garzozzi, Haemek Medical Center, Afula, Israel and Bruce Rappaport Faculty of Medicine, Technion, Israel

REFERENCES

- Hart WM**, Becker B. The onset and evolution of glaucomatous visual field defects. *Ophthalmology* 1982;**89**:268-79.
- Hitchings RA**, Spaeth GL. The optic disc in glaucoma. I: Classification. *Br J Ophthalmol* 1976;**60**:778-5.
- Airaksinen PJ**, Mustonen E, Alanko HI. Optic disc hemorrhages. Analysis of stereophotographs and clinical data of 112 patients. *Arch Ophthalmol* 1981;**99**:1795-801.
- Jonas JB**, Nguyen XN, Gusek G C, et al. Peripapillary chorioretinal atrophy in normal and glaucomatous eyes. I. Morphometric data. *Invest Ophthalmol Vis Sci* 1989;**30**:908-18.
- Glovinsky Y**, Quigley HA, Dunkelberger GR. Retinal ganglion cell loss is size dependant in experimental glaucoma. *Invest Ophthalmol Vis Sci* 1991;**32**:484-91.
- Chung HS**, Harris A, Halter PJ, et al. Regional differences in retinal vascular reactivity. *Invest Ophthalmol Vis Sci* 1999;**40**:2448-53.
- Jonas JB**, Gusek GC, Naumann GOH. Optic disc, cup and neuroretinal rim size, configuration and correlations in normal eyes. *Invest Ophthalmol Vis Sci* 1992;**33**:474-5.
- Janknecht P**, Funk J. Optic nerve head analyzer and Heidelberg retinal tomography; accuracy and reproducibility of topographic measurements in a model eye and in volunteers. *Br J Ophthalmol* 1994;**78**:760-8.
- Tai CS**, Zangwill L, Gonzales G, et al. Ethnic differences in optic nerve head topography. *J Glaucoma* 1995;**4**:248-57.
- Mickelberg FS**, Parfitt CM, Swindale NV, et al. Ability of the Heidelberg retina tomograph to detect early glaucomatous visual field loss. *J Glaucoma* 1995;**4**:242-7.
- Harris A**, Chung HS, Ciulla TA, et al. Progress in measurement of ocular blood flow and relevance to our understanding of glaucoma and age-related macular degeneration. *Prog Retin Eye Res* 1999;**18**:669-87.
- Schratzberger P**, Schratzberger G, Silver M, et al. Favorable effect of VEGF gene transfer on ischemic peripheral neuropathy. *Nat Med* 2000;**6**:405-13.
- Jonas JB**, Nguyen NX, Naumann GOH. The retinal nerve fiber layer in normal eyes. *Ophthalmology* 1989;**96**:627-32.
- Dichtl A**, Jonas JB, Naumann GOH. Retinal nerve fiber thickness in human eyes. *Graefes Arch Clin Exp Ophthalmol* 1999;**237**:474-9.
- Jonas JB**, Dichtl A. Evaluation of the retinal nerve fiber layer. *Surv Ophthalmol* 1996;**40**:369-78.
- Lester M**, Courtright P, Mickelberg FS. Retinal nerve fiber layer height in high-tension glaucoma and healthy eyes. *J Glaucoma* 1998;**7**:1-7.
- Harrington DO**. The Bjerrum scotoma. *Am J Ophthalmol* 1965;**59**:646-56.
- Gramer E**, Gerlach R, Kriegelstein GK, et al. Topography of early glaucomatous visual field defects in computerized perimetry. *Klin Monatsbl Augenheilkd* 1982;**180**:515-23.
- Shields MB**. Visual function in glaucoma. In: *Textbook in glaucoma*. 3rd ed. Baltimore, MD: Williams and Wilkins, 1998:180-6.
- Wollstein G**, Garway-Heath DF, Hitchings RA. Identification of early glaucoma cases with the scanning laser ophthalmoscope. *Ophthalmology* 1998;**105**:1557-63.
- Jonas JB**, Gusek GC, Naumann GOH. Optic disc morphometric data to visual field indices. *Graefes Arch Clin Exp Ophthalmol* 1988;**226**:531-8.
- Glovinsky Y**, Quigley HA, Dunkelberger GR. Retinal ganglion cell loss is size dependant in experimental glaucoma. *Invest Ophthalmol Vis Sci* 1991;**32**:484-91.
- Chung HS**, Harris A, Hirst AD, et al. Microcirculations of diseased and healthy retinal areas responded differently to blood gas perturbation in glaucoma patients. [ARVO abstract]. *Invest Ophthalmol Vis Sci* 1999;**40**:S678. [Abstract no 3575.]
- Varma R**, Quigley HA, Pease ME. Changes in optic disc characteristics and the number of nerve fibers in experimental glaucoma. *Am J Ophthalmol* 1992;**114**:554-9.
- Yucel YH**, Gupta N, Kalichman MW, et al. Relationship of optic disc topography to optic nerve fiber number in glaucoma. *Arch Ophthalmol* 1998;**116**:493-7.
- Eid TM**, Spaeth GL, Katz LJ, et al. Quantitative estimation of retinal nerve fiber layer height in glaucoma and the relationship with optic nerve head topography and visual field. *J Glaucoma* 1997;**6**:221-30.
- Walker D**, Carrington A, Cannan SA, et al. Structural abnormalities do not explain the early functional abnormalities in the peripheral nerves of the streptozotocin diabetic rat. *J Anat* 1999;**195**:419-27.

Video Reports (www.bjophthalmol.com)

- Capsule staining and mature cataracts: a comparison of indocyanine green and trypan blue dyes. *DF Chang*
- Pearls for implanting the Staar toric IOL. *DF Chang*
- An intraocular steroid delivery system for cataract surgery. *DF Chang*
- Evaluation of leucocyte dynamics in mouse retinal circulation with scanning laser ophthalmoscopy. *H Xu, A Manivannan, G Daniels, J Liversidge, P F Sharp, J V Forrester, I J Crane*
- *Dipetalonema reconditum* in the human eye. *T Huynh, J Thean, R Maini*
- Surgical revision of leaking filtering blebs with an autologous conjunctival graft. *K Taherian, A Azuara-Blanco*
- Thixotropy: a novel explanation for the cause of lagophthalmos after peripheral facial nerve palsy. *M Aramideh, J H T M Koelman, P P Devriese, F VanderWerf, J D Speelman*



Blood flow per unit retinal nerve fibre tissue volume is lower in the human inferior retina

A Harris, Y Ishii, H S Chung, et al.

Br J Ophthalmol 2003 87: 184-188

doi: 10.1136/bjo.87.2.184

Updated information and services can be found at:

<http://bjo.bmj.com/content/87/2/184.full.html>

These include:

References

This article cites 23 articles, 7 of which can be accessed free at:

<http://bjo.bmj.com/content/87/2/184.full.html#ref-list-1>

Article cited in:

<http://bjo.bmj.com/content/87/2/184.full.html#related-urls>

Email alerting service

Receive free email alerts when new articles cite this article. Sign up in the box at the top right corner of the online article.

Topic Collections

Articles on similar topics can be found in the following collections

[Angle](#) (791 articles)
[Glaucoma](#) (779 articles)
[Intraocular pressure](#) (789 articles)
[Neurology](#) (1042 articles)
[Optic nerve](#) (558 articles)

Notes

To request permissions go to:

<http://group.bmj.com/group/rights-licensing/permissions>

To order reprints go to:

<http://journals.bmj.com/cgi/reprintform>

To subscribe to BMJ go to:

<http://group.bmj.com/subscribe/>