

CLINICAL SCIENCE

The familial contribution to non-syndromic ocular coloboma in south India

S J Hornby, L Dandona, R B Jones, H Stewart, C E Gilbert

See end of article for authors' affiliations

Br J Ophthalmol 2003;87:336-340

Correspondence to:
Miss Stella Hornby,
Department of
Epidemiology and
International Eye Health,
Institute of Ophthalmology,
11-43 Bath Street, London
EC1V 9EL, UK;
stella.hornby@virgin.net

Accepted for publication
3 July 20002

Aims: To identify the proportion of familial cases of isolated ocular colobomatous malformations in a case series from south India.

Methods: Children with ocular coloboma without systemic features were recruited from multiple sources in Andhra Pradesh, India. Their families were traced, pedigrees drawn, and family members examined.

Results: 56 probands, 25 females (44.6%) and 31 males (57.4%) with a colobomatous malformation were identified. In 12 cases (21.4%) another family member was affected. The risk to siblings was 3.8%. The parents were consanguineous in 25 cases (44.6%).

Conclusions: 21.4% of cases of isolated ocular coloboma in this highly consanguineous population of south India were familial, with both autosomal dominant and autosomal recessive mechanisms likely in different families.

Congenital malformations of the globe appear to occur more frequently in certain countries, particularly India and Sri Lanka, accounting for approximately 25% of cases of severe visual impairment and blindness (VA < 6/60) in studies from India.¹⁻⁵

Coloboma is defined as a congenital defect in uveal tissue in a site consistent with abnormal closure of the embryonic fissure. Microphthalmos with cyst is a distinct phenotypic form of coloboma.^{6,7} Microphthalmos with cyst in one eye may be associated with a coloboma in the fellow eye, and both phenotypes may be seen in different individuals of the same family.⁸⁻¹¹ Clinical anophthalmos, where there is no evidence of ocular tissue present in the orbit, is clinically distinct from coloboma but may represent the severe end of the coloboma spectrum as clinical anophthalmos and coloboma may occasionally both be present in the same individual or in different individuals within the same family.¹² Ocular features

commonly associated with coloboma are microcornea, microphthalmos, cataract, and retinal detachment.^{10,13,14}

Ocular coloboma can be associated with other systemic abnormalities in a multitude of syndromes—for example, CHARGE syndrome, or can be an isolated abnormality.^{12,15}

Coloboma can be caused by genetic, environmental (teratogens),¹⁶ or unknown factors. The genetic causes can be chromosomal or monogenic. Coloboma associated with chromosomal abnormalities is usually associated with systemic abnormalities—for example, mental retardation.¹⁷ The ocular phenotype does not correlate with the aetiology.

Autosomal dominant (AD) inheritance is the most common mechanism reported in the literature although most cases are sporadic.^{12,18-21} Autosomal recessive (AR) inheritance has been proposed although in many studies the parents were not examined, which is necessary to confidently exclude dominant inheritance.²² Consanguineous pedigrees have been

Table 1 Details of families with more than one affected individual

No	Sex	Phenotype of proband	Other affected family member	Phenotype of other affected	Likely mechanism of inheritance
1	M	Coloboma and microcornea	Sister, mother and 5 of mothers siblings	All had coloboma. Some also had microcornea and cataract	Autosomal dominant*
2	M	Bilateral iris and retinal colobomata and microcornea	Father	Unilateral disc coloboma	Autosomal dominant
3	M	Colobomatous microphthalmos/coloboma with microcornea	Mother	Unilateral retinal coloboma	Autosomal dominant
4	F	Bilateral colobomatous microphthalmos	Paternal uncle	Not examined	Recessive*
5	M	Coloboma and microcornea	Sister	Coloboma and microcornea	Recessive
6	F	Coloboma R Severe microphthalmos L	Sister	R colobomatous microphthalmos L severe microphthalmos	Recessive
7	M	Bilateral colobomatous microphthalmos	Sister (deceased)	Died at 2 days of age so not examined	Recessive
8	M	Bilateral colobomata or retina and left disc	Father	Isolated retinal coloboma in right eye and left microcornea and dense cataract	Dominant*
9	M	Bilateral coloboma with microphthalmos	Brother	Bilateral coloboma with microphthalmos	Recessive
10	F	Bilateral colobomata and microcornea	Father, brother (deceased)	Isolated retinal coloboma in right eye, left microcornea and dense cataract	Recessive*
11	M	Bilateral coloboma and microphthalmos and minor lens opacities	Mother Maternal uncle	Mother had unilateral coloboma of the iris, microcornea and mature cataract Uncle not examined but blind and appearance said to resemble proband	Recessive*
12	M	Bilateral colobomata of iris and retina	Mother	Unilateral coloboma of retina and disc	Dominant*

*Consanguineous parents.

described which support autosomal recessive inheritance for both colobomatous microphthalmos²³ and microphthalmos with cyst.²⁴ An unusual molecular mechanism, such as trinucleotide expansion, has been suggested for one pedigree with isolated coloboma.²⁵

To date there have been few studies of coloboma in families, and none from India. A population based study in Scotland using segregation analysis found a sibling recurrence risk of 8.1% and 13.3%. However, both parents were not examined in all cases in this study and both syndromic and non-syndromic cases were included.²⁶ The aim of the present study was to identify the familial contribution to the aetiology of isolated

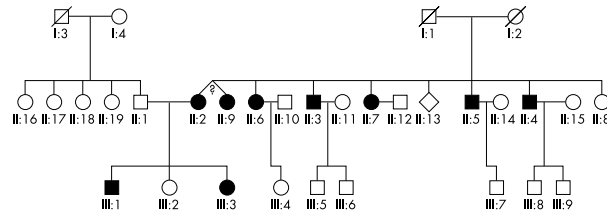
ocular coloboma in a case series from a south Indian population where consanguinity is common (18% in the urban population of Hyderabad) and has been practised for generations.²⁷

PATIENTS AND METHODS

Children with coloboma or microphthalmos with cyst in either eye were recruited from special schools for the blind, schools with integrated education for the visually impaired, eye hospital records and a community based rehabilitation programme in Andhra Pradesh, India. This study is part of a

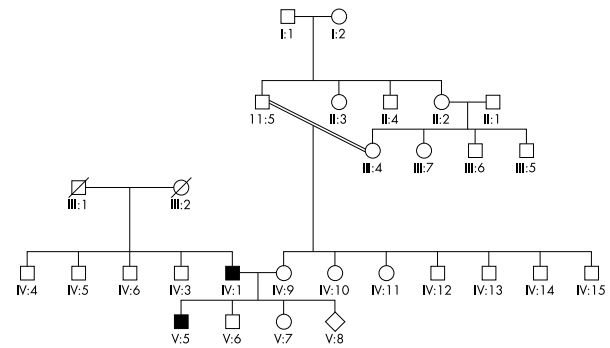
A

Pedigree 1



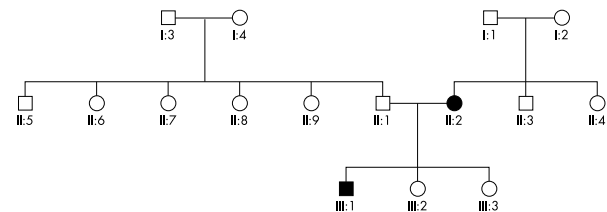
B

Pedigree 2



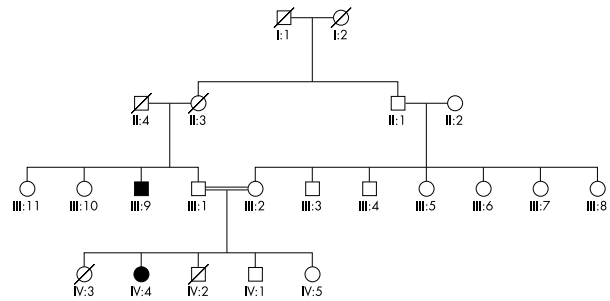
C

Pedigree 3



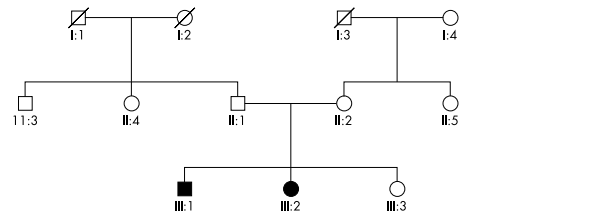
D

Pedigree 4



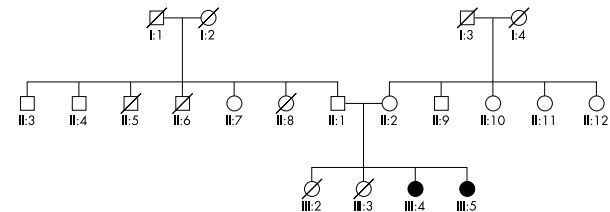
E

Pedigree 5



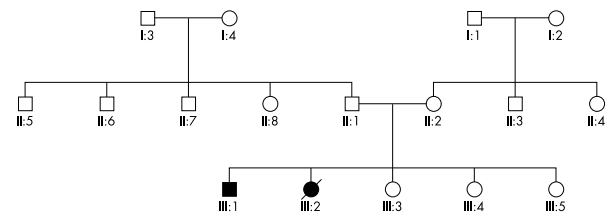
F

Pedigree 6



G

Pedigree 7



H

Pedigree 8

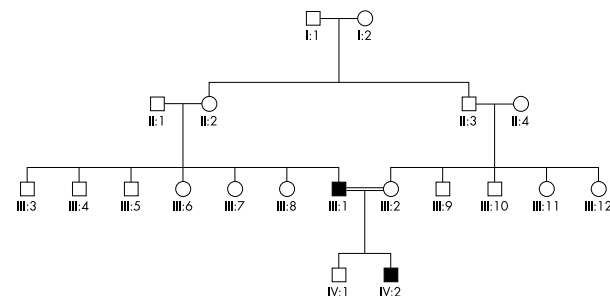


Figure 1 Family pedigrees 1–8.

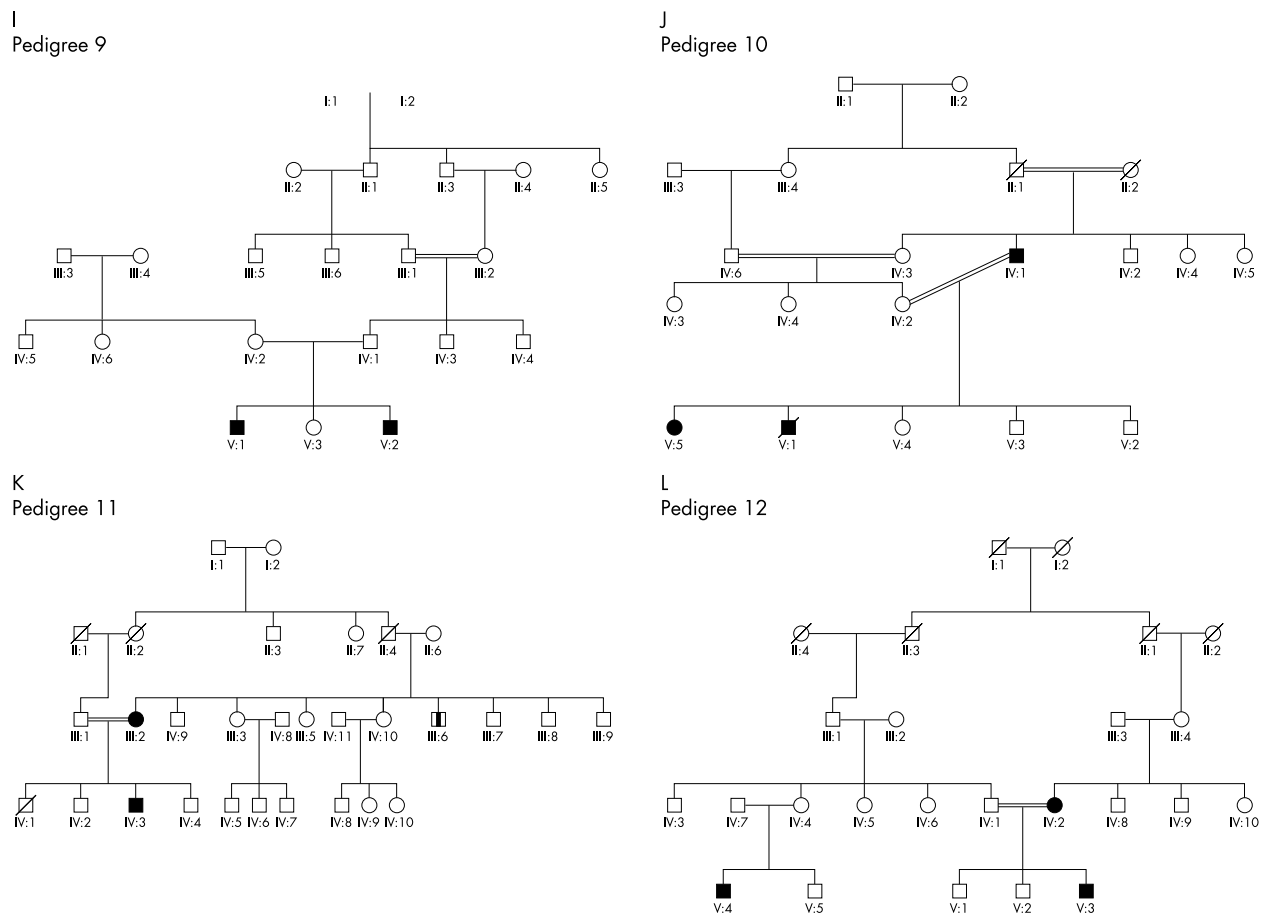


Figure 1 Family pedigrees 9–12.

larger study of congenital eye anomalies, which was carried out between January 1998 and February 1999.^{14 28–30} The ethics committee of the LV Prasad Eye Institute, Hyderabad, approved the study.

Inclusion criteria for this study were that the child should have a colobomatous malformation in either eye without associated systemic features, and that both parents were also examined. Children with non-syndromic ocular anomalies were selected in order to exclude dysmorphic children who were likely to have chromosomal abnormalities or phenocopies due to a teratogen.

Every child was examined by the same ophthalmologist (SJH). The anterior segment was examined using a portable slit lamp. Dilated fundal examination was performed by direct and indirect ophthalmoscopy. Each child was examined for systemic abnormalities by the ophthalmologist and the majority were traced and examined on a separate occasion by a paediatrician (RBJ).

The field workers recruited to the study had previous experience in health related field work, were fluent in English and the local languages. The same female field investigator carried out the interviews using a structured questionnaire. Questions were asked about consanguinity between the parents and grandparents of the affected child. All pregnancies, including miscarriages and stillbirths, were recorded. As many family members as possible were examined. Pedigrees were constructed by the ophthalmologist with the field worker acting as an interpreter. Data were entered into a database in EPI-INFO.³¹

RESULTS

Fifty six probands fulfilled the criteria for the study. Forty (71.4%) were examined by RBJ. They were recruited from a

series of 109 probands with coloboma recruited to a larger study, of whom nine were excluded because they had systemic abnormalities and/or one parent was not available for examination in the remainder.

Of 56 probands, 25 were female (44.6%) and 31 were male (55.4%). The age range was from 2.8 years to 16.3 years, with a mean of 9.9 years. Forty nine (87.5%) were Hindu, four (7.1%) were Muslim, and three (5.4%) were Christian. They were recruited from schools for the blind (n=15, 26.8%), hospital records (n=24, 42.9%), and a community based rehabilitation programme (n=15, 26.8%), integrated education (n=1, 1.8%), and a school for the mentally handicapped (n=1, 1.8%). (The child identified in the school for the mentally retarded was found to have visual handicap as an isolated problem and had been inappropriately placed.)

Forty probands (71.4%) had bilateral colobomatous malformations; two (3.5%) had anophthalmos; six (10.7%) were unilaterally affected with a normal fellow eye; two (3.5%) had phthisical fellow eyes; and six (10.7%) had non-cystic severe microphthalmos.

In 12 cases (21%) another family member was affected on examination (n=10) and an additional two families had a positive family history but the individuals were not examined. Eight families had two siblings affected. In seven families one parent was affected (four mothers, three fathers). In three families aunts or uncles of the proband were affected. In one family a first cousin of the proband was affected. The clinical findings are shown in Table 1 and the pedigrees are shown in Figure 1.

Consanguinity

The parents were consanguineous in 25 cases (44.6%); four uncle-niece, 13 first cousin, three second cousin marriages,

and five distantly related. (A second cousin is in the same generation as the person speaking but the linking senior relatives are two generations above them.)

The maternal grandparents were related in 12 families (21.4%) (five uncle-niece, six first cousin, and one distantly related). The paternal grandparents were related in seven families (12.5%) (six first cousin, one distantly related). Eight (14.3%) families had more than one generation of consanguinity.

Sibling risk

The sibling risk is defined as the number of siblings with an eye anomaly excluding the index case divided by the total number of siblings, again excluding the index case. Data from the mother's interview gave a sibling risk of 3.8% (95% CI 1.4 to 8.1). For consanguineous parents the sibling risk was 1.4% (95% CI 0.1 to 8.4) and for non-consanguineous parents the sibling risk was 6.0% (95% CI 2.2 to 14.1).

DISCUSSION

The present study is the first large family study of coloboma where both parents were examined in all cases and the first from India. Twelve of 56 cases of non-syndromic ocular coloboma in this sample were familial (21%), which compares with 10% in a Chinese study.³² There are no comparable Western studies but the familial contribution to isolated ocular coloboma has been estimated to be 1% or less (D Taylor, personal communication). Family studies of coloboma are hampered by under-reporting of affected relatives because of frequent asymptomatic disease. Family aggregation patterns may also be distorted by reduced reproductive fitness among affected individuals, which has been reported in collie dogs.³³

A higher proportion of familial cases in India than elsewhere may be related to the prevailing high levels of consanguinity in the population increasing the frequency of recessive disease and modifying the genetic background. However, even in India the majority of cases are sporadic. Possible causes for sporadic cases include unrecognised recessive disease, new mutations, phenocopies (environmental factors), extramarital conceptions, chromosomal aberrations, or complex genetic mechanisms such as polygenic inheritance or gene-environment interactions.³⁴

Familial coloboma can be unilateral and although such asymmetry between eyes is uncommon in inherited eye disease in general it is commonly reported in both human and animal studies of coloboma. The reasons for this are unclear.

Both AD and AR patterns of inheritance were observed in different families (see Table 1) confirming genetic heterogeneity. Dominant pedigrees for coloboma have been reported previously in humans^{12 19 35-37} and cattle.³⁷ AD colobomatous microphthalmia has been mapped to chromosome 15q12-q15.³⁸ Mutations in the PAX2 gene have been identified in dominant renal coloboma syndrome but not in isolated ocular coloboma.^{39 40} In order to identify dominant inheritance with incomplete penetrance, obligate carriers (an individual with an affected parent and affected child) must be identified. There were no obligate carriers identified in the present study.

Recessive inheritance for coloboma is likely in many families in this study and may be more common than dominant inheritance in this inbred population.²² The parents of children with coloboma were significantly more closely related than the general population, which suggests that recessive factors may be important. However, high background rates of consanguinity make interpretation of individual pedigrees difficult as highly inbred pedigrees may show the phenomenon of "pseudodominance" of recessive conditions. Multiple generations of consanguinity would be expected to increase the frequency of complex genetic disorders such as double recessives, gene-environment interactions, or multifactorial conditions. Recessive CHX10 mutations have been identified

in two consanguineous pedigrees with non-syndromic microphthalmia.⁴¹ A gene for microphthalmos without coloboma has been mapped to chromosome 14q32.⁴² In the Australian shepherd dog microphthalmos with coloboma behaves as an incompletely penetrant recessive trait.⁴³

No families with X linked inheritance were seen in the study although coloboma has been reported in several rare X linked syndromes⁴⁴ and in non-syndromic X linked coloboma, and microphthalmos.⁴⁵

Genetic counselling is difficult in coloboma. Karyotyping and examination by a paediatrician or clinical geneticist should be performed to identify associated syndromes. Parents should be examined for minor forms of coloboma. In south India there is a low risk to siblings (3.8%) but this would be higher in a family with dominant coloboma. Surprisingly, the sibling risk was lower for consanguineous parents than for non-consanguineous but the confidence intervals overlapped. The conclusions of the present study (including the recurrence risk) may not be applicable to other populations because of the high background rate of consanguinity as well as under-ascertainment and recruitment bias in favour of more severely affected cases in the present study. However, this study confirms the relative rarity of familial coloboma.

ACKNOWLEDGEMENTS

This study was supported by grants from Christoffel Blinden Mission, the British Council for the Prevention of Blindness, Dark and Light, and the Tjissen Foundation. Mrs SM Farhath carried out the interviews. Mr M Ferozuddin and Mr B Raju traced the families. Mr S Adolph carried out refraction and low vision assessments.

.....

Authors' affiliations

S J Hornby, C E Gilbert, Department of Epidemiology and International Eye Health, Institute of Ophthalmology, London, UK
L Dandona, International Centre for the Advancement of Rural Eye Care, LV Prasad Eye Institute, LV Prasad Marg, Banjara Hills, Hyderabad 500034, India
R B Jones, Department of Paediatrics, Moorfields Eye Hospital, City Road, London, UK
H Stewart, Department of Medical Genetics, Churchill Hospital, Oxford

REFERENCES

- 1 **Fujiki K**, Nakajima A, Yasuda N, *et al*. Genetic analysis of microphthalmos. *Ophthalmic Paediatr Genet* 1992;1:139-49.
- 2 **Czeizel A**, Torzs E, Lujza G, *et al*. An aetiological study on 6 to 14 year-old children with severe visual handicap in Hungary. *Acta Paediatr Hung* 1991;31:365-77.
- 3 **Dandona L**, Williams JD, Williams BC, *et al*. Population-based assessment of childhood blindness in southern India. *Arch Ophthalmol* 1998;116:545-6.
- 4 **Rahi JS**, Sripathi S, Gilbert CE, *et al*. Childhood blindness in India: causes in 1318 blind school students in nine states. *Eye* 1995;9:545-50.
- 5 **Hornby SJ**, Gilbert CE, Rahi J, *et al*. Regional variation in blindness in children due to microphthalmos, anophthalmos and coloboma. *Ophthalmic Epidemiol* 2000;7:127-38.
- 6 **Duke-Elder S**. Congenital deformities of the eye. In: *System of ophthalmology*. London: Henry Kimpton, 1964:415-29.
- 7 **Foxman S**, Cameron JD. The clinical implications of bilateral microphthalmos with cyst. *Am J Ophthalmol* 1984;97:632-8.
- 8 **Warburg M**. Diagnostic precision in microphthalmos and coloboma of heterogeneous origin. *Birth Defects* 1982;18:31-50.
- 9 **Leatherbarrow B**, Kwartz J, Noble JL. Microphthalmos with cyst in monozygous twins. *J Pediatr Ophthalmol Strabismus* 1990;27:294-8.
- 10 **Warburg M**. Classification of microphthalmos and coloboma. *J Med Genet* 1993;30:664-9.
- 11 **Waring GO**, Roth AM, Rodrigues MM. Clinicopathologic correlation of microphthalmos with cyst. *Am J Ophthalmol* 1976;82:714-21.
- 12 **Pagon RA**. Ocular coloboma. *Surv Ophthalmol* 1981;25:223-36.
- 13 **Daufenbach DR**, Ruttum MS, Pulido JS, *et al*. Chorioretinal colobomas in a pediatric population. *Ophthalmology* 1998;105:1455-8.
- 14 **Hornby SJ**, Adolph S, Gilbert CE, *et al*. Prognosis for vision in children with coloboma: clinical features and a new phenotypic classification system. *Ophthalmology* 2000;107:511-20.
- 15 **Weiss AH**, Kousseff BG, Ross EA, *et al*. Complex microphthalmos. *Arch Ophthalmol* 1989;107:1619-24.
- 16 **Pons JC**, Imbert MC, Elefant E, *et al*. Development after exposure to mifepristone in early pregnancy. *Lancet* 1991;338:763

- 17 **Warburg M**, Friedrich U. Coloboma and microphthalmos in chromosomal aberrations. Chromosomal aberrations and neural crest cell developmental field. *Ophthalmic Paediatr Genet* 1987;**8**:105-18.
- 18 **Bateman JB**. Microphthalmos. *Int Ophthalmol Clin* 1984;**24**:87-107.
- 19 **Konstas AG**, Bufidis T, Kardasopoulos A. Simple iris coloboma in a Greek family. *Acta Ophthalmol Scand* 1996;**74**:89-92.
- 20 **Savell J**, Cook JR. Optic nerve colobomas of autosomal-dominant heredity. *Arch Ophthalmol* 1976;**94**:395-400.
- 21 **Pallotta R**, Fusilli P, Sabatino G, et al. Confirmation of the colobomatous macrophthalmia with microcornea syndrome: report of another family. *Am J Med Genet* 1998;**76**:252-4.
- 22 **Pagon RA**, Kalina RE, Lechner DJ. Possible autosomal-recessive ocular coloboma. *Am J Med Genet* 1981;**9**:189-93.
- 23 **Zlotogora J**, Legum C, Raz J, et al. Autosomal recessive colobomatous microphthalmia. *Am J Med Genet* 1994;**49**:261-2.
- 24 **Porges Y**, Gershoni BR, Leibur R, et al. Hereditary microphthalmia with colobomatous cyst. *Am J Ophthalmol* 1992;**114**:30-4.
- 25 **Barros NP**, Medina C, Mendoza R, et al. Unexpected familial recurrence of iris coloboma. A delayed mutation mechanism? *Clin Genet* 1995;**48**:160-1.
- 26 **Morrison DA**, Fitzpatrick DR, Hanson I, et al. National study of microphthalmia, anophthalmia, and coloboma (MAC) in Scotland: investigation of genetic aetiology. *J Med Genet* 2002;**39**:16-22.
- 27 **Srinivas MN**, Dube L, Panini MN, et al. *Caste: its twentieth century avatar*. 2nd ed. New Delhi: Penguin Books India, 1996.
- 28 **Hornby SJ**, Adolph S, Gothwal VK, et al. Requirements for optical services in children with coloboma, microphthalmos and microcornea in Southern India. *Eye* 2000;**14**:219-24.
- 29 **Hornby SJ**, Adolph S, Gothwal VK, et al. Evaluation of children in six blind schools of Andhra Pradesh, India. *Indian J Ophthalmol* 2000;**48**:195-200.
- 30 **Hornby SJ**, Gilbert CE, Dandona LFA, et al. Anophthalmos in children from India: clinical findings, pedigrees and consanguinity. *Dev Med Child Neurol* 2001;**43**:392-5.
- 31 **Dean AG**, Dean JA, Coulombier D, et al. Epi Info, Version 6: a word processing, database, and statistics program for epidemiology on microcomputers. (6.04). Atlanta GA: Centers for Disease Control and Prevention, 1994.
- 32 **Lu BX**. [An analysis of 193 cases of congenital intraocular colobomas.] *Chung Hua Yen Ko Tsa Chih* 1989;**25**:357-9.
- 33 **Wallin-Hakanson B**, Wallin-Hankanson N, Hedhammar A. Collie eye anomaly in the rough collie in Sweden: genetic transmission and influence on offspring vitality. *J Small Anim Pract* 2000;**41**:254-8.
- 34 **Hornby SJ**, Ward SJ, Gilbert CE, et al. Environmental risk factors in the aetiology of congenital malformations of the eye in children in South India. *Arch Trop Paediatr* 2002;**22**:67-77.
- 35 **Yamashita T**, Kawano K, Ohba N. Autosomal dominantly inherited optic nerve coloboma. *Ophthalmic Paediatr Genet* 1988;**9**:17-24.
- 36 **Savell J**, Cook JR. Optic nerve colobomas of autosomal-dominant heredity. *Arch Ophthalmol* 1976;**94**:395-400.
- 37 **Francois J**. Colobomatous malformations of the ocular globe. *Int Ophthalmol Clin* 1968;**8**:797-816.
- 38 **Morle L**, Bozon M, Zech JC, et al. A locus for autosomal dominant colobomatous microphthalmia maps to chromosome 15q12-q15. *Am J Med Genet* 2000;**67**:1592-7.
- 39 **Sanyanusin P**, McNoe LA, Sullivan MJ, et al. Mutation of PAX2 in two siblings with renal-coloboma syndrome. *Hum Mol Genet* 1995;**4**:2183-4.
- 40 **Cunliffe HE**, McNoe LA, Ward TA, et al. The prevalence of PAX2 mutations in patients with isolated colobomas or colobomas associated with urogenital anomalies. *Med Genet* 1998;**35**:806-12.
- 41 **Ferda Percin E**, Ploder LA, Yu JJ, et al. Human microphthalmia associated with mutations in the retinal homeobox gene CHX10. *Nat Genet* 2000;**25**:397-401.
- 42 **Bessant DA**, Khaliq S, Hameed A, et al. A locus for autosomal recessive congenital microphthalmia maps to chromosome 14q32. *Am J Hum Genet* 1998;**62**:1113-16.
- 43 **Gelatt KN**, Powell NG, Huston K. Inheritance of microphthalmia with coloboma in the Australian shepherd dog. *Am J Vet Res* 1981;**42**:1686-90.
- 44 **Goldberg MF**, McKusick VA. X-linked colobomatous microphthalmos and other congenital anomalies. A disorder resembling Lenz's dysmorphogenetic syndrome. *Am J Ophthalmol* 1971;**71**:1128-33.
- 45 **Lehman DM**, Sponsel WE, Stratton RF, et al. Genetic mapping of a novel X-linked recessive colobomatous microphthalmia. *Am J Med Genet* 2001;**101**:114-19.

Want full access but don't
have a subscription?

Pay per access

For just US\$25 you can have instant access to the whole website for 30 days. During this time you will be able to access the full text for all issues (including supplements) available. You will also be able to download and print any relevant pdf files for personal use, and take advantage of all the special features *British Journal of Ophthalmology* online has to offer.

www.bjophthalmol.com



The familial contribution to non-syndromic ocular coloboma in south India

S J Hornby, L Dandona, R B Jones, et al.

Br J Ophthalmol 2003 87: 336-340

doi: 10.1136/bjo.87.3.336

Updated information and services can be found at:

<http://bjo.bmj.com/content/87/3/336.full.html>

References

These include:

This article cites 42 articles, 8 of which can be accessed free at:

<http://bjo.bmj.com/content/87/3/336.full.html#ref-list-1>

Article cited in:

<http://bjo.bmj.com/content/87/3/336.full.html#related-urls>

Email alerting service

Receive free email alerts when new articles cite this article. Sign up in the box at the top right corner of the online article.

Topic Collections

Articles on similar topics can be found in the following collections

[Eye \(globe\)](#) (543 articles)

[Public health](#) (379 articles)

Notes

To request permissions go to:

<http://group.bmj.com/group/rights-licensing/permissions>

To order reprints go to:

<http://journals.bmj.com/cgi/reprintform>

To subscribe to BMJ go to:

<http://group.bmj.com/subscribe/>