

SCIENTIFIC CORRESPONDENCE

Confocal microscopy of *Aspergillus fumigatus* keratitis

A M Avunduk, R W Beuerman, E D Varnell, H E Kaufman

Br J Ophthalmol 2003;**87**:409–410

Aim: To use a confocal microscope to characterise the treated and untreated courses of fungal keratitis.

Methods: In the first experiment, *Aspergillus fumigatus* stromal keratitis was produced in both eyes of seven New Zealand white rabbits. In the second experiment, keratitis was induced in right eyes of 20 rabbits. Group 1 rabbits were treated with topical fluconazole, group 2 rabbits received oral fluconazole, and group 3 rabbits were used as controls. The rabbits were examined with a slit lamp and confocal microscope 2, 6, 10, 14, and 20 days after inoculation. The corneal cultures were taken on days 2, 14, and 20 and biopsies were taken on days 2 and 22.

Results: On days 14 and 22 confocal microscopy was more sensitive than culture technique in both treated and untreated animals, since not all cases of fungal keratitis can be cultured.

Conclusion: This study indicates that confocal microscopy is a rapid and sensitive diagnostic tool for both the early diagnosis and non-invasive follow up of fungal keratitis

Confocal microscopy is a relatively new, non-invasive technique for imaging the cornea in normal and diseased states.¹ The imaging of *Aspergillus* keratitis in a rabbit eye and *Aspergillus* and *Fusarium* keratitis in human eyes by confocal microscopy has been reported previously.^{2–4} In this study, we followed treated and untreated *Aspergillus fumigatus* keratitis in a rabbit model by serial confocal microscopy, fungal culture, and histopathological examination of diagnostic corneal biopsies to establish the reliability and value of this technique in follow up of treatment.

MATERIALS AND METHODS

Twenty male New Zealand albino rabbits, weighing approximately 2.5 kg, were used. All animal studies were approved by the LSU Health Sciences Center institutional animal care and use committee. All experiments adhered to the Association for Research in Vision and Ophthalmology resolution on the use of animals in research.

Aspergillus fumigatus was isolated from a patient and counted with a haemocytometer and adjusted to a concentration of 4.2×10^7 cells/ml.

An aliquot of 25 μ l of *Aspergillus fumigatus* spores, the equivalent of 1×10^6 spores, was injected into the central corneal stroma of rabbits. In the first experiment, we induced *Aspergillus fumigatus* keratitis in both eyes of seven rabbits. The corneal culture samples for Sabouraud's agar and biopsy samples were taken 2 days after inoculation. The animals were examined with a confocal microscopy 2, 6, 10, 14, and 22 days after inoculation.

In the second experiment, *Aspergillus fumigatus* keratitis was induced in the right eye of 20 rabbits. Forty eight hours after inoculation, the rabbits were randomised into three groups. In group 1, a commercially available intravenous fluconazole preparation was used (Diflucan for injection (2 mg/ml in 0.9% NaCl; pH = 6.2; 304 mOsm/l), Pfizer Inc, New York, NY, USA)

for topical treatment. A 20 μ l drop of fluconazole was administered every hour for 8 hours a day. Group 2 animals were treated with oral fluconazole (37.5 mg/kg) twice daily. For this purpose, appropriate doses of Diflucan oral tablets (Pfizer Inc, New York, NY, USA) were dissolved in 0.9% NaCl and administered by gavage. Group 3 (control) animals were not treated. The animals were examined with a confocal microscopy 2, 6, 10, 14, and 22 days after inoculation. On days 2, 14, and 22, corneal cultures were obtained on days 2 and 22, a diagnostic biopsy was performed.

A Kimura spatula was used for culture on Sabouraud's dextrose agar containing 50 μ g/g gentamicin sulphate and the plates were incubated for 1 week at 21°C. The Sabouraud's agar plates were kept at room temperature for 1 week and were examined daily.

After the corneal scraping was taken, a 1 \times 1 mm sample of deep corneal tissue was removed from the infiltration site and stained either with calcofluor or periodic acid Schiff (PAS).

The eyes were examined with a tandem scanning confocal microscope (Advanced Scanning, New Orleans, LA, USA) with a 20 \times water immersion objective. We examined the eyes by confocal microscope before culture and biopsy collection.

The Wilcoxon rank sum test was utilised for analysing the difference between slit lamp scores. However, statistical differences between the positive culture results, positive biopsy results, and confocal diagnosis rates at different stages were analysed by χ^2 test.

RESULTS

In the first experiment, on day 2, each of the 14 cultures of scrapings from infected corneas plated on Sabouraud's dextrose agar grew *Aspergillus fumigatus*. All of the corneal biopsy specimens stained with calcofluor showed multiple septated hyphae with branching at a 45° angle on day 2.

By day 2, confocal microscopy of infiltrates revealed interlocking white lines, ~6 μ m in width and 200–400 μ m in length in the superficial stroma (Fig 1). The white lines were located parallel to the corneal surface with branching at a 45° angle. Confocal microscopy of the colony growth on the culture plates revealed similar filaments in terms of thickness and branching pattern. By days 6–10, deep stromal invasion of the cornea by fungal hyphae and endothelial cell destruction were prominent features. By day 16–22, break up of fungal elements was evident along with blood vessel invasion and highly reflective scar tissue formation.

In the second experiment, all cultures taken 2 days after inoculation grew *Aspergillus fumigatus*. However, on day 14, two of six topically treated eyes and two of seven orally treated eyes grew *Aspergillus fumigatus* in Sabouraud's medium, while four of seven scrapings grew *Aspergillus fumigatus* from untreated control eyes. The statistical difference was found to be significant ($p = 0.002$ and $p = 0.003$ χ^2 test). The same trend was also observed on day 22 cultures. On day 22, positive growth in the control group (3/7) was also statistically significantly more than both topically treated (1/6) and orally treated groups (1/7) ($p = 0.008$ and $p = 0.009$, χ^2 test).

By day 6, hyphal fragments were beginning to break up into small pieces in treated eyes. On day 14, we observed hyphal

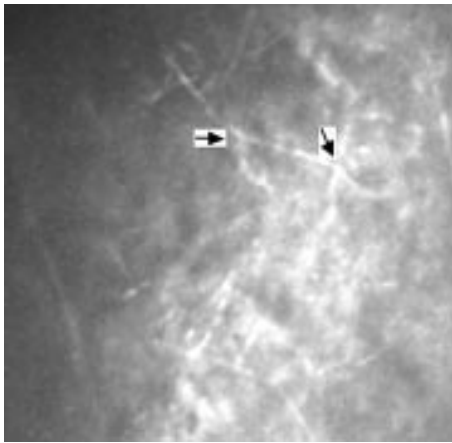


Figure 1 Confocal microscopy, 2 days after *Aspergillus fumigatus* inoculation. Note hyphae (arrows), in disrupted superficial corneal stroma is parallel to corneal surface with branching at a 45° angle.




Figure 2 Confocal microscopy, 20 days after *Aspergillus fumigatus* inoculation of oral fluconazole treated rabbit cornea, shows small hyphal fragments (arrow).

fragments (broken in treated corneas and full size in untreated ones) in each cornea by confocal examination. However, only eight of 20 scrapings grew *Aspergillus fumigatus* on Sabouraud's agar culture at this stage. The positive diagnostic value of confocal microscopy compared with Sabouraud's culture was significant ($p=0.007$, χ^2 test) at this stage. On day 22, observed some small hyphal fragments in three of six topically and four of seven orally treated rabbits (Fig 2). *Aspergillus fumigatus* hyphal fragments were visualised in all corneas from group 3 on day 22. The diagnostic value of confocal microscopy over Sabouraud's agar culture was significant also at this stage ($p=0.005$ χ^2 test).

The characteristics of fungus in calcofluor and PAS stained corneal biopsies showed parallel findings with confocal examinations on day 22.

DISCUSSION

In studies of human keratitis, about one third of all corneal ulcers are culture negative.^{5,6} About one fourth of fungal cultures become positive only after 2 weeks.⁷ This delay in diagnosis and treatment can result in the loss of vision.^{8,9} A perforated cornea from secondary fungal keratitis complicating acanthamoeba keratitis also was reported. In this case, although the cornea perforated and hyphae were plentiful, culture was not obtained pre-keratoplasty.¹⁰ Thus, rapid and reliable diagnostic techniques may salvage useful vision in many eyes with fungal keratitis.⁸

We were able to detect fungal hyphae in all rabbit eyes 2 days after fungal inoculation by confocal microscopy, as soon as slit lamp evidence of stromal infiltration became apparent. Confocal microscopy has previously been reported to be a useful adjunct in the diagnosis of *Aspergillus* and *Fusarium* keratitis (case reports).^{3,4} Although in our model Sabouraud's agar culture and corneal biopsy techniques showed similar sensitivity (100%) in the early stage, confocal microscopy appears to have a definite advantage in the later stages of infection, since not all cases of fungal keratitis could be cultured.

PCR (polymerase chain reaction) has been used for the diagnosis of fungal keratitis, but it generally takes longer, may be more difficult to set up, and is more difficult to use with consistent results.¹¹ Other reports have used a variety of staining techniques on corneal smears¹²⁻¹⁴; however, the results are somewhat confusing. One report suggested that a potassium hydroxide (KOH) wet mount preparation was superior to the other techniques,¹² other investigators^{13,14} found calcofluor staining to be equal or superior to KOH. The overall sensitivity of smear staining procedures in these reports ranged between 71-93% in culture positive cases.¹³

One advantage of confocal microscopy over the PCR and fungal smears is that confocal microscopy is helpful not only in diagnosis but in the follow up and treatment monitoring of fungal keratitis.^{3,4}

This study provides strong evidence that confocal microscopy is a fast, safe, and sensitive diagnostic tool in the diagnosis, follow up, and treatment monitoring of fungal keratitis.

Authors' affiliations

A M Avunduk, Karadeniz Technical University Medical School, Trabzon, Turkey

R W Beuerman, E D Varnell, H E Kaufman, Louisiana State University Eye Center, New Orleans, LA, USA

Correspondence to: Avni Murat Avunduk, Karadeniz Technical University Medical School, Trabzon, Turkey; avunduk@ttnet.net.tr

Accepted for publication 9 November 2002

REFERENCES

- 1 **Cavanagh HD**, Petroll WM, Alizadeh AH. Clinical and diagnostic use of in vivo confocal microscopy in patients with corneal disease. *Ophthalmology* 1993;**100**:1444-54.
- 2 **Chew SJ**, Beuerman RW, Assouline M, et al. Early diagnosis of infectious keratitis with in vivo real time confocal microscopy. *CLAO J* 1992;**18**:197-201.
- 3 **Winchester K**, Mathers WD, Sutphin JE. Diagnosis of *Aspergillus* keratitis in vivo with confocal microscopy. *Cornea* 1997;**16**:27-31.
- 4 **Florakis GJ**, Moazami G, Schubert H, et al. Scanning slit confocal microscopy of fungal keratitis. *Arch Ophthalmol* 1997;**115**:1461-63
- 5 **Liesegang TJ**, Forster RK. Spectrum of microbial keratitis in South Florida. *Am J Ophthalmol* 1980;**90**:38-47.
- 6 **McDonnell PJ**, Nobe J, Gauderman WJ, et al. Community care of corneal ulcers. *Am J Ophthalmol* 1992;**114**:531-8.
- 7 **O'Day DM**, Akrabawi PL, Head WS, et al. Laboratory isolation techniques in human and experimental fungal infections. *Am J Ophthalmol* 1979;**87**:688-93.
- 8 **Polack FM**, Kaufman HE, Newmark E. Keratomycosis. Medical and surgical treatment. *Arch Ophthalmol* 1971;**85**:410-6.
- 9 **Jones DB**, Wilson L, Sexton RR, et al. Early diagnosis of mycotic keratitis. *Trans Ophthalmol Soc UK* 1970;**89**:805-13.
- 10 **Froumis NA**, Mondino BJ, Glasgow BJ. Acanthamoeba keratitis associated with fungal keratitis. *Am J Ophthalmol* 2001;**131**:508-9.
- 11 **Alexandrakis G**, Jalali S, Gloor P. Diagnosis of *Fusarium* keratitis in an animal model using the polymerase chain reaction. *Br J Ophthalmol* 1998;**82**:306-11.
- 12 **Vajpayee RB**, Angra SK, Sandramouli S, et al. Laboratory diagnosis of keratomycosis: comparative evaluation of direct microscopy and culture results. *Ann Ophthalmol* 1993;**25**:68-71.
- 13 **Sharma S**, Silverberg M, Mehta P, et al. Early diagnosis of mycotic keratitis: predictive value of potassium hydroxide preparation. *Indian J Ophthalmol* 1998;**46**:31-5.
- 14 **Chander J**, Chakrabarti A, Sharma A, et al. Evaluation of calcofluor staining in the diagnosis of fungal corneal ulcer. *Mycoses* 1993;**36**:243-5.



Confocal microscopy of *Aspergillus fumigatus* keratitis

A M Avunduk, R W Beuerman, E D Varnell, et al.

Br J Ophthalmol 2003 87: 409-410

doi: 10.1136/bjo.87.4.409

Updated information and services can be found at:

<http://bjo.bmj.com/content/87/4/409.full.html>

References

These include:

This article cites 14 articles, 3 of which can be accessed free at:

<http://bjo.bmj.com/content/87/4/409.full.html#ref-list-1>

Article cited in:

<http://bjo.bmj.com/content/87/4/409.full.html#related-urls>

Email alerting service

Receive free email alerts when new articles cite this article. Sign up in the box at the top right corner of the online article.

Topic Collections

Articles on similar topics can be found in the following collections

[Cornea](#) (383 articles)

[Ocular surface](#) (455 articles)

[Eye \(globe\)](#) (543 articles)

Notes

To request permissions go to:

<http://group.bmj.com/group/rights-licensing/permissions>

To order reprints go to:

<http://journals.bmj.com/cgi/reprintform>

To subscribe to BMJ go to:

<http://group.bmj.com/subscribe/>