

BJO at a glance

Creig Hoyt, Editor

THE PERSISTENT PROBLEM OF VITAMIN A DEFICIENCY AND ITS COMPLICATIONS

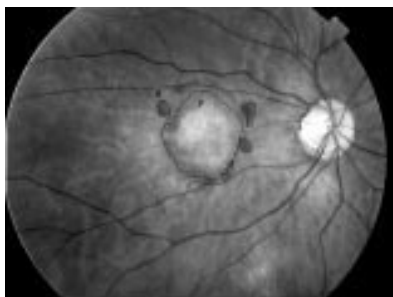
In many parts of the developing world vitamin A deficiency and measles remain a major problem in relation to childhood visual impairment. In a study from Ethiopia Kello and Gilbert found that 68% of children in three blind schools had avoidable causes of visual loss. Vitamin A deficiency and/or measles contributed to the majority of the preventable causes.

The need for prevention of the disorders is highlighted by the study of Vajpayee and coworkers who analysed the results of keratoplasty in 29 children with keratomalacia. 41% of these cases were related to measles and nearly 40% to vitamin A deficiency. In 15 eyes an emergency tectonic keratoplasty was performed. Only five grafts remained clear at a mean follow up of 7.3 months. Seven eyes underwent optical penetrating keratoplasty, of which only four grafts remained clear at a mean follow up of 6.4 months. None of these patients achieved acuity of better than 6/60.

See p 526 and p 538

PREVENTING FALLS IN THE ELDERLY WITH CATARACT SURGERY

Falls are the most frequent cause of injury related to morbidity and mortality among the elderly. Falls occur as the result of multiple factors including decreasing muscle strength and balance,



See p 609

common joint disorders, and visual problems. Brannan and coworkers report a study of 97 patients who underwent cataract surgery; 84 patients completed the study and 31 had reported falls before cataract surgery. This group showed a statistically significant reduction in the number of falls in the postoperative period. This study suggests that cataract surgery may be an effective intervention to reduce the risk of falls in elderly patients with cataract visually related impairment.

See p 560

WHAT ARE THE RISK FACTORS FOR CHOROIDAL NEOVASCULARISATION IN PATHOLOGICAL MYOPIA?

High myopia remains a major cause of legally defined blindness in many developed countries. Ohno-Matsui *et al* report a study of 218 consecutive patients with myopic fundus changes. Thirty three eyes developed myopic choroidal neovascularisation. The incidence was higher among fellow eyes of patients with pre-existing choroidal neovascularisation. Choroidal neovascularisation developed in 3.7% of patients with diffuse chorioretinal atrophy, 20% with patch atrophy, and in nearly 30% with lacquer cracks. Patchy atrophy and lacquer cracks appear to be important predisposing findings in highly myopic eyes that later develop choroidal neovascularisation.

See p 570

AMBIENT LIGHT AT NIGHT: A RISK FOR MYOPIA?

Both genetic and environmental factors are implicated in the aetiology of myopia. The precise interplay of genetic and environmental factors has yet to be determined. Recently, Quinn and coworkers suggested that there was association between nighttime light exposure during the first 2 years of childhood and subsequent myopic development.¹

Guggenheim and coworkers report a study of 122 university students. In this study myopia occurred with approximately equal frequency in those who slept with and without lighting exposure at night as children. In contrast with largely genetic factors parental myopia and race were both significantly associated with myopia development. This study confirms previous studies that reported a higher prevalence of myopia among Asians than Europeans and the influence of parental myopia in determining the refractive error of their children.

See p 580

VISUAL FUNCTION IN AGE RELATED MACULAR DEGENERATION

Age related maculopathy represents a spectrum of gradual degenerative changes in the human macula. In late stages of macular degeneration central visual loss occurs and is related to both non-neovascular and neovascular changes. Hogg and coworkers studied both eyes of 58 subjects with a confirmed clinical diagnosis of age related macular degeneration. They noted the size, location, and composition of the macular lesion. In this study the composition of the macular lesions strongly influenced visual function with atrophy and fibrosis accounting for most of the variation. Fibrosis within the fovea significantly influenced all clinical measures of vision but atrophy, exudates, and the presence of blood were also variables that explained the variation in clinical measures of vision in these patients.

See p 609

Reference

- 1 Quinn GE, Shin CH, Maguire MG, *et al*. Myopia and ambient lighting at night. *Nature* 1999;399:113.



BJO at a glance

Creig Hoyt

Br J Ophthalmol 2003 87: 521
doi: 10.1136/bjo.87.5.521-a

Updated information and services can be found at:
<http://bjo.bmj.com/content/87/5/521.2.full.html>

References

These include:

This article cites 1 articles
<http://bjo.bmj.com/content/87/5/521.2.full.html#ref-list-1>

Article cited in:
<http://bjo.bmj.com/content/87/5/521.2.full.html#related-urls>

Email alerting service

Receive free email alerts when new articles cite this article. Sign up in the box at the top right corner of the online article.

Notes

To request permissions go to:
<http://group.bmj.com/group/rights-licensing/permissions>

To order reprints go to:
<http://journals.bmj.com/cgi/reprintform>

To subscribe to BMJ go to:
<http://group.bmj.com/subscribe/>