

## SCIENTIFIC CORRESPONDENCE

## LASIK after retinal detachment surgery

R Sinha, T Dada, L Verma, D B Chaudhury, R Tandon, R B Vajpayee

*Br J Ophthalmol* 2003;**87**:551–553

**Aim:** To assess the efficacy and safety of laser in situ keratomileusis (LASIK) for correction of myopic refractive errors in eyes which have previously undergone retinal detachment surgery.

**Methods:** In a prospective, non-comparative case series, 10 eyes of nine patients who had a myopic refractive error and had previously undergone retinal detachment surgery underwent LASIK surgery according to the standard surgical protocol. The surgery could be completed in eight eyes and in two eyes it was aborted intraoperatively. The parameters evaluated included the uncorrected visual acuity, best corrected visual acuity, refraction, detailed fundus evaluation with indirect ophthalmoscope, slit lamp biomicroscopy, and corneal pachymetry. Any intraoperative or postoperative complications were recorded. Follow up visits were scheduled at day 1, 1 week, 1 month, 3 months, and 6 months after LASIK.

**Results:** Eight eyes underwent successful LASIK surgery. The mean spherical equivalent before surgery was  $-5.436$  (SD 1.6) dioptres (D), which was reduced to  $+0.42$  (0.65) D,  $-0.07$  (1.32) D,  $-0.06$  (1.39) D, and  $-0.06$  (0.65) at 1 week, 1 month, 3 months, and 6 months respectively after LASIK. The uncorrected visual acuity improved in all the eyes and the best corrected visual acuity improved or remained same in all the eyes. There was no retinal complication after LASIK.

**Conclusion:** LASIK may be used to correct refractive errors in eyes that have undergone retinal detachment surgery. However, scarred conjunctiva in such cases may prevent generation of optimal suction for the microkeratome.

Myopic refractive errors are common in eyes that develop a retinal detachment.<sup>1,2</sup> In addition, myopic changes may also be induced by retinal detachment surgery because of the changes in axial length, anterior chamber depth, or position of the crystalline lens.<sup>3,4</sup> Thus, many patients demand a refractive correction after undergoing retinal detachment surgery.

LASIK (laser in situ keratomileusis) has gained wide acceptance as the procedure of choice for the correction of a wide variety of refractive errors. It has also been found useful in treating refractive errors in eyes that have undergone previous ocular surgery.<sup>5-7</sup> However, the efficacy of LASIK has not been evaluated for correction of refractive errors after retinal detachment surgery. We therefore undertook the present study to evaluate the safety and efficacy of LASIK in eyes that have undergone a retinal detachment surgery.

## METHODS

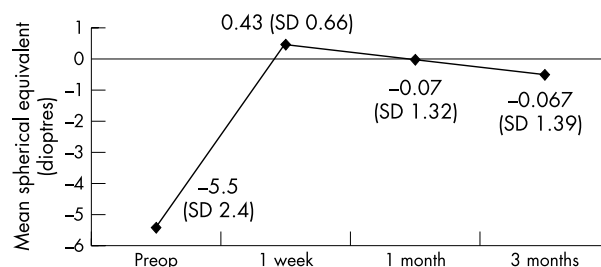
For the present prospective study, 10 eyes of nine patients with a myopic refractive error were enrolled from the retina service of a tertiary care eye hospital. All these patients had undergone a conventional retinal detachment surgery for primary rhegmatogenous retinal detachment with application of

a scleral buckle and encirclage, at least 6 months before inclusion in the study.

A complete ocular and medical history was obtained in all patients. Patients who were not willing to wear spectacles or contact lenses were included in the present study. Written consent was obtained after detailed instruction and discussion with the patient. Preoperative evaluation included the measurement of the uncorrected visual acuity (UCVA) and best corrected visual acuity (BCVA), cycloplegic refraction, slit lamp biomicroscopy, indirect ophthalmoscopy, ultrasonic pachymetry, applanation tonometry, and videokeratography. The mean preoperative Sim K on Orbscan topography system (Bausch and Lomb, Salt Lake City, UT, USA) was 43.02 (SD 2.22). Intraoperative evaluation included measurement of the flap thickness using the Corneo Gage plus (Sonogage Inc, Cleveland, OH, USA) ultrasonic pachymeter. The central corneal thickness was measured just before initiating the surgery and then after lifting the stromal flap, before laser ablation.

Surgery was performed under topical anaesthesia (0.5% oxybuprocaine (proparacaine)). The hansatome microkeratome (Chiron Vision, Claremont, CA, USA) was used to create a superiorly hinged flap. The hansatome head cutting a 180  $\mu$ m flap and an 8.5 mm suction ring was used in all the cases. The intraocular pressure generated after activation of the suction was measured with the Barraquer tonometer. The flap was cut only if on applanation of the cornea, the central mire was equal to or within the circular mark etched on the tonometer (indicating a pressure of equal to or more than 65 mm Hg). Standard surgical technique was used and the Chiron Technolas 217 excimer laser (Chiron Vision, Claremont, CA, USA) was used for laser ablation. The optic zone diameter was 5.5 mm in all the cases and a minimal residual stromal thickness of 250  $\mu$ m was left after laser ablation in all the eyes. The target refraction was emmetropia in all the operated eyes. In two eyes with extensive conjunctival scarring adequate suction could not be obtained and the IOP generated was less than 65 mm Hg. Surgery was not performed in these two eyes.

All patients received ciprofloxacin (0.3% four times daily) and fluorometholone (0.1% four times daily) eye drops for 2 weeks and tear supplements for 4 weeks in the postoperative period. Routine postoperative examinations were scheduled at day 1, 1 week, 1 month, 3 months, and 6 months after the surgery. The UCVA, BCVA, refraction, corneal topography, and

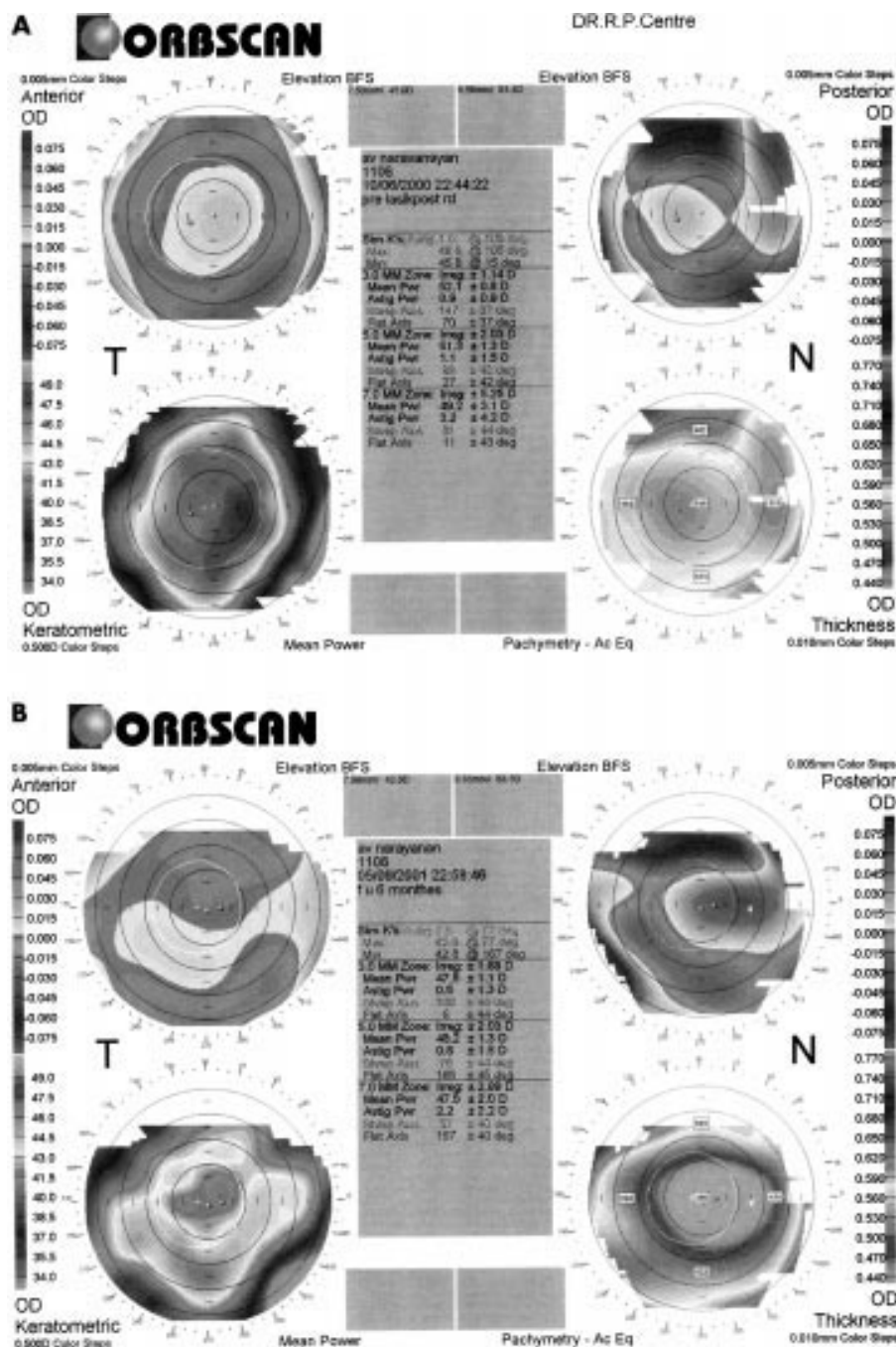


**Figure 1** Mean spherical equivalent (mean spherical deviation from emmetropia) shown before and after surgery.

**Table 1** Details of the patients who underwent LASIK after RD surgery

No	Age/sex	Eye	RD surg*	UCVA† (pre)	BCVA‡ (pre)	Preop ref error	UCVA (6 metres)	BCVA (6 metres)	Ref error (6 metres)
1	59/M	R	9 months	3/60	6/9	-6.00/-0.75 Cyl x 25°	6/12	6/9	Plano
2	35/M	R	9 months	1/60	6/12	-6.00/-0.75 Cyl x 15°	6/18	6/12	-0.75 D sp
3	52/M	L	8 months	6/24	6/9	-1.00/-3.00 Cyl x 85°	6/9	6/9	-0.75 cyl x90°
4	25/M	R	7.5 months	3/60	6/18	-4.25/-1.25 Cyl x 45°	6/12	6/12	+0.75 D sp
5	20/M	R	15 months	2/60	6/18	-5.50/-3.50 Cyl x 50°	6/18	6/18	+1.00 D sp
6	20/M	R	9 months	3/60	6/18	-6.00/-0.75 Cyl x 95°	6/18	6/18	-0.5 D sp
7	25/M	R	8 months	3/60	6/12	-5.00/-2.00 Cyl x 80°	6/18	6/12	-0.75 D sp
8	25/M	L	13 months	6/60	6/9	-3.00/-1.50 Cyl x 60°	6/9	6/9	Plano

\*LASIK performed after RD surgery in months.  
 †UCVA = uncorrected visual acuity ‡BCVA = best corrected visual acuity  
 Nos 7 and 8 are the right and left eyes of the same patient.



**Figure 2** (A) Pre-LASIK topography map. (B) Post-LASIK topography map.

pachymetry were performed at the 1 week, 1 month, 3 month, and 6 month follow up and any postoperative complication was noted.

## RESULTS

Ten eyes of nine patients were enrolled for the present study, out of which eight eyes of seven patients subsequently underwent LASIK surgery for refractive correction after retinal detachment surgery. All patients were male. The right eye was operated in five patients, the left eye in one patient, while one patient had bilateral surgery. The mean age at the time of surgery was 33.29 years (range 21–58 years). The mean time interval from retinal detachment surgery was 10.63 months (range 7–15 months). The indication for retinal detachment surgery was rhegmatogenous retinal detachment associated with myopia in all the patients. All patients were myopic before surgery with a mean spherical equivalent of  $-5.536$  (SD 2.413) D on cycloplegic correction (range  $-3$  to  $-11$  D). Postoperatively, the mean spherical equivalent was  $+0.43$  (0.66) D at 1 week,  $-0.07$  (1.32) D at 1 month,  $-0.067$  (1.39) D at 3 months, and  $-0.06$  (0.65) D at 6 months (Fig 1). Four eyes (50%) were within plus or minus 0.5 D of emmetropia at 6 months, while all eight eyes (100%) were within plus or minus 1 D of emmetropia at 6 months after the surgery. The mean refractive cylinder before surgery was  $-2.14$  (1.44) D (range  $-0.75$  D to  $-3.5$  D). A residual refractive cylinder of  $-0.5$  D was present in only one of the eight eyes, 6 months after LASIK.

Five out of eight eyes (62.5%) had BCVA of 6/12 or better before surgery, while six eyes (75%) had a BCVA of better than 6/12 after surgery. The preoperative UCVA ranged from 6/24 to 1/60. At final examination at 6 months, four eyes (50%) had a UCVA of equal to or better than 6/12, while all eight eyes (100%) had a UCVA better than or equal to 6/18. There was no decrease in the UCVA or BCVA in any of the eyes in the follow up period (Table 1).

The mean thickness of the flap made by the hanskome was  $132.1$  (30.26)  $\mu\text{m}$  (range 110–170  $\mu\text{m}$ ). The mean thickness of ablation was  $117.7$  (30.48)  $\mu\text{m}$  (72.00–135.0  $\mu\text{m}$ ). Mean preoperative pachymetry was  $527.1$  (20.24)  $\mu\text{m}$ . Mean postoperative pachymetry at the 1 week, 1 month, 3 month, and 6 month follow up was  $386.4$  (33.27)  $\mu\text{m}$ ,  $402$  (63.60)  $\mu\text{m}$ ,  $425$  (65.63)  $\mu\text{m}$ , and  $430$  (64.42)  $\mu\text{m}$  respectively. There were no other postoperative complications (Fig 2). All patients were satisfied with the final visual outcome.

No retinal pathology predisposing to retinal detachment was detected on indirect ophthalmoscopy done preoperatively. On indirect ophthalmoscopy done at 3 months and 6 months after the surgery, none of the eyes was found to have any new retinal lesion and in all the eyes the retina was flat.

## DISCUSSION

LASIK is being successfully used for the correction of myopic refractive errors all over the world. The therapeutic value of LASIK has also been realised for the correction of refractive errors after previous surgical procedures such as penetrating keratoplasty, radial keratotomy, and cataract surgery.<sup>2–7</sup> However, there are several studies which have reported the occurrence of retinal detachment following LASIK surgery, especially in myopic eyes.<sup>8–9</sup>

There is only one study<sup>10</sup> in the literature, which has mentioned the use of LASIK for management of refractive errors in eyes following retinal detachment surgery. All eyes operated had an improvement in the uncorrected visual acuity and there was no decrease in the best corrected visual acuity in any of the cases. All eyes achieved a refractive error of

within 1 D of emmetropia and an uncorrected visual acuity of better than 20/60. Although there was no retinal complication in the postoperative period, a longer follow up is required with regular screening of the retinal periphery. The only problem we found in doing LASIK after retinal detachment surgery was that these patients have extensive conjunctival scarring, which hampers the function of the suction ring of the microkeratome. Owing to the presence of scar tissue, a good hold on the ocular surface is not obtained and thus suction may be inadequate to initiate the procedure. This can lead to a decrease in the level of intraocular pressure obtained before performing the microkeratome cut which eventually affects the thickness of the flap. Thus, one might see thin flaps in such cases and the suction may be too inadequate even to initiate the surgery, as in two of our cases where an adequate IOP could not be generated to proceed with the microkeratome cut. In such cases a good option can be photorefractive keratectomy or laser epithelial keratomileusis (LASEK).

In conclusion, LASIK may be considered for treating refractive errors post-retinal detachment surgery. In addition, this procedure is especially useful for correction of anisometropia induced by scleral buckling surgery. But there may be difficulties in performing the procedure owing to conjunctival scarring and thereby poor suction generation. However, in those cases where it is possible to develop adequate suction one can perform the procedure with reasonable safety and efficacy. Further studies with a larger sample size and longer follow up will be helpful to either validate or refute the results of this study.

Declaration: The authors do not have any proprietary interest in the article.

## Authors' affiliations

**R Sinha, T Dada, L Verma, D B Chaudhury, R Tandon, R B Vajpayee**, Rajendra Prasad Centre for Ophthalmic Sciences, All India Institute of Medical Sciences, New Delhi 110029, India

Correspondence to: Rasik B Vajpayee, Rajendra Prasad Centre for Ophthalmic Sciences, All India Institute of Medical Sciences, Ansari Nagar, New Delhi 110029, India; [rasikvajpayee@rediffmail.com](mailto:rasikvajpayee@rediffmail.com)

Accepted for publication 20 September 2002

## REFERENCES

- Schepens CL, Marden D. Data on the natural history of retinal detachment. Further characterization of certain unilateral non-traumatic cases. *Am J Ophthalmol* 1966;**61**:213–26.
- Yannuzzi LA, Sorenson JA, Sobel RS, et al. Risk factors for idiopathic rhegmatogenous retinal detachment. *Am J Epidemiol* 1993;**137**:749–57.
- Larsen JS, Syrdalen P. Ultrasonographic study on changes in axial eye dimensions after encircling procedure in retinal detachment surgery. *Acta Ophthalmol* 1979;**57**:337–43.
- Smiddy WE, Loupe DN, Michels RG, et al. Refractive changes after scleral buckling surgery. *Arch Ophthalmol* 1989;**107**:1469–71.
- Spadea L, Mosca L, Balestrazzi E. Effectiveness of LASIK to correct refractive error after penetrating keratoplasty. *Ophthalmic Surg Lasers* 2000;**31**:111–20.
- Lipshitz I, Man O, Shemesh G, et al. Laser in situ keratomileusis to correct hyperopic shift after radial keratotomy. *J Cataract Refract Surg* 2001;**27**:273–6.
- Ayala MJ, Perez-Santonja JJ, Artola A, et al. Laser in situ keratomileusis to correct residual myopia after cataract surgery. *J Refract Surg* 2001;**17**:12–16.
- Ruiz-Moreno JM, Perez-Santonja JJ, Alio JL. Retinal detachment in myopic eyes after laser in situ keratomileusis. *Am J Ophthalmol* 1999;**128**:588–94.
- Arevalo JF, Azar-arevalo O. Retinal detachment in myopic eyes after laser in situ keratomileusis [letter]. *Am J Ophthalmol* 2000;**128**:825.
- Georgiev N, Sheludchenko VM, Kurenkov VV. Possibilities and results of photorefractive operations for myopia after retinal detachment surgery. *Vestn Ophthalmol* 2001;**117**:20–2.



## LASIK after retinal detachment surgery

R Sinha, T Dada, L Verma, et al.

*Br J Ophthalmol* 2003 87: 551-553

doi: 10.1136/bjo.87.5.551

---

Updated information and services can be found at:

<http://bjo.bmj.com/content/87/5/551.full.html>

---

*These include:*

### References

This article cites 10 articles, 2 of which can be accessed free at:

<http://bjo.bmj.com/content/87/5/551.full.html#ref-list-1>

### Email alerting service

Receive free email alerts when new articles cite this article. Sign up in the box at the top right corner of the online article.

---

### Topic Collections

Articles on similar topics can be found in the following collections

[Ophthalmologic surgical procedures](#) (971 articles)

[Optic nerve](#) (558 articles)

[Optics and refraction](#) (385 articles)

[Retina](#) (1217 articles)

---

### Notes

---

To request permissions go to:

<http://group.bmj.com/group/rights-licensing/permissions>

To order reprints go to:

<http://journals.bmj.com/cgi/reprintform>

To subscribe to BMJ go to:

<http://group.bmj.com/subscribe/>