

BJO at a glance

Creig Hoyt, Editor

CENTRAL SEROUS CHORIORETINOPATHY: MORE THAN MEETS THE EYE

Central serous chorioretinopathy (CSC) is characterised by a focal serous detachment of the neurosensory retina. Leakage of fluorescein dye from the retinal pigment epithelium and subretinal dye pooling can be demonstrated on fluorescein angiography. Fluorescein angiography has not been successful in imaging the choroidal vessels. Kitaya and coworkers report the findings of 36 consecutive patients with acute central serous chorioretinopathy using indocyanine green angiography. Additionally, in 11 of these patients laser Doppler flowmetry estimated the foveal choroidal blood flow. In this study, decreased choroidal blood flow in CSC was demonstrated for the first time. Decreased foveal choroidal blood flow was also demonstrated. These findings suggest that CSC is not merely a disorder of retinal pigment epithelium but also involves choroidal vascular abnormalities including hyperpermeability in decreased foveal choroidal blood flow. Why these abnormalities of choroidal blood flow take place is uncertain.

Spahn and coworkers evaluated the psychosomatic symptoms and social support of 24 consecutive patients with CSC. In this study CSC was primarily an ailment of middle aged socially well integrated men. However, this study also suggested that elevated psychic stress

was associated with CSC. This lends further support to the thesis that CSC may represent a disorder involving elevated levels of endogenous stress hormones.

See p 704 and 709

THE USEFULNESS OF COLOUR TESTING IN DIABETES MELLITUS

Studies of the Farnsworth Munsell 100 Hue test in diabetics have shown an increased error score. Some studies reported generalised loss of hue discrimination while others have demonstrated a red-green axis loss. Other studies have shown a loss of colour discrimination on a tritanopic axis in patients with diabetes. Davies and coworkers used a colour matching technique to test whether the foveal tritanopic zone is increased in size in diabetic subjects. In their study, the majority of diabetic subjects showed a foveal tritanopia zone no larger than normal. However, in a small group of subjects the size of the zone was significantly increased. This suggests that the short wave length sensitive (S) cone pathway may be damaged sufficiently to lead to dichromatic colour vision in the fovea in some diabetics. The question arises whether diabetics should be screened using colour vision tests in order to detect early retinal damage.

Ong and coworkers studied a group of diabetic patients with automated tritan contrast threshold (TCT) testing as a screening device. In this study tritan colour deficiency was observed in patients with sight threatening diabetic retinopathy even in the presence of normal best corrected visual acuity. These results suggest that automated TCT assessment may be effective and a clinically valuable technique for detecting sight threatening diabetic retinopathy, especially diabetic maculopathy, before visual loss can be detected.

See p 742 and p 747

SMOKING ADVERSELY EFFECTS THE TREATMENT OF THYROID OPHTHALMOPATHY

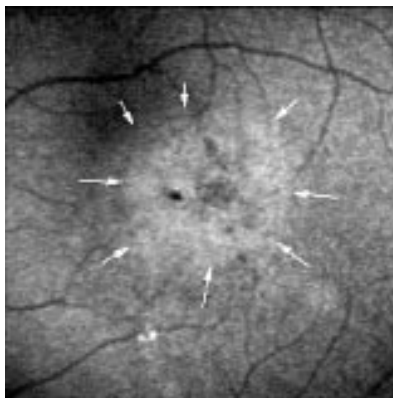
Thyroid associated ophthalmopathy occurs more frequently and tends to be more severe in smokers than non-smokers. Being a current smoker correlates with the severity of thyroid associated ophthalmopathy. Studies have suggested that smoking increases the risk of ophthalmopathy progression after radioiodine therapy and decreases the efficacy of orbital irradiation and or glucocorticoid therapy. Eckstein and coworkers studied 41 smokers and 19 non-smokers with thyroid associated ophthalmopathy. The authors evaluated whether or not smoking influences the course of thyroid associated ophthalmopathy during treatment and whether it adversely affects therapy. The extent of smoking was estimated from the concentration of haemoglobin adduct *N*-2-hydroxyethylvaline. The authors found that smoking influences the course of thyroid associated ophthalmopathy and does so in a dose dependent manner. This was true for clinical activity signs of thyroid associated ophthalmopathy as well as ocular motility restrictions. Smokers should be strongly urged to discontinue smoking during treatment for thyroid associated ophthalmopathy.

See p 773

LOCAL BLOOD FLOW ABNORMALITIES IN NORMAL TENSION GLAUCOMA

Glaucoma is defined as a progressive optic neuropathy characterised by optic nerve head excavation and glaucomatous visual field loss usually associated with intraocular pressure. However a subset of patients with glaucomatous optic neuropathy never appear to develop abnormal intraocular pressure. This subset has been referred to as normal tension glaucoma. It has been suggested that a vascular failure leading to perfusion defects of the optic nerve head, retina, choroid, or retrobulbar vessels may contribute to the nerve fibre loss in normal tension glaucoma. Plange and coworkers report the results of colour Doppler imaging and fluorescein studies of the optic disc in 29 patients with normal tension glaucoma. In this study patients with normal tension glaucoma had reduced blood flow velocities and higher resistive indices in most retrobulbar. Optic nerve head fluorescein defects were considerably larger compared to normal controls. The filling defects were correlated with end diastolic velocities and resistive indices of the posterior ciliary arteries and with blood flow velocities of the central retinal artery. This suggests that capillary loss of the optic nerve head may be related to higher downstream resistance and reduced blood flow velocities of the retrobulbar vessels in patients with normal tension glaucoma.

See p 731



See p 709

www.bjophthalmol.com



BJO at a glance

Creig Hoyt

Br J Ophthalmol 2003 87: 663
doi: 10.1136/bjo.87.6.663-a

Updated information and services can be found at:
<http://bjo.bmj.com/content/87/6/663.2.full.html>

These include:

Email alerting service

Receive free email alerts when new articles cite this article. Sign up in the box at the top right corner of the online article.

Notes

To request permissions go to:
<http://group.bmj.com/group/rights-licensing/permissions>

To order reprints go to:
<http://journals.bmj.com/cgi/reprintform>

To subscribe to BMJ go to:
<http://group.bmj.com/subscribe/>