

## EXTENDED REPORT

# A 10 year retrospective survey of cataract surgery and endophthalmitis in a single eye unit: injectable lenses lower the incidence of endophthalmitis

E Mayer, D Cadman, P Ewings, J M Twomey, R H Gray, K G Claridge, K N Hakin, A K Bates

See end of article for authors' affiliations

*Br J Ophthalmol* 2003;**87**:867–869

Correspondence to:  
A K Bates, Department of Ophthalmology, Taunton and Somerset Hospital, Musgrove Park, Taunton TA1 5DA, UK;  
KeithBates@theorchardhouse.demon.co.uk

Accepted for publication  
16 November 2002

**Aim:** To study the incidence of endophthalmitis following cataract surgery over a 10 year period, and to examine ways in which this may be related to changes in surgical technique.

**Methods:** All cases of endophthalmitis occurring over a 10 year period within a single ophthalmic unit in the United Kingdom were reviewed, and possible risk factors identified.

**Results:** During the study period, as the technique of extracapsular cataract surgery was replaced by phacoemulsification, there was a commensurate reduction in the incidence of endophthalmitis. Injectable IOLs were associated with the lowest risk of postoperative endophthalmitis (0.028%).

**Conclusions:** Injectable intraocular lenses do not make contact with the ocular surface and this may result in the observed lower rate of endophthalmitis. This, and the ease with which they can be inserted through small incisions, support their use as the first line method of lens insertion.

Cataract surgery is one of the most commonly performed and successful surgical procedures in the world. Over the past 10 years in the United Kingdom, there has been a progressive change from extracapsular extraction (ECCE) to phacoemulsification (phaco). Concurrent with this change has been the development of foldable and injectable intraocular lenses (IOLs), obviating the need for incision enlargement.

Complications after cataract surgery occur with similar frequency for both phaco and ECCE.<sup>1</sup> Endophthalmitis can be one of the most devastating of these, since it can lead to complete blindness in the affected eye; unchecked it can even give rise to cavernous sinus thrombosis and death. Fortunately it is rare, with a reported frequency in the UK National Cataract Surgery Survey of between 0.1 and 0.2%,<sup>2</sup> a figure comparable with other reports.<sup>3–4</sup>

Most cases of postoperative endophthalmitis occur acutely, with a speed and severity that reflect bacterial load and virulence. Virulent organisms present early, usually with hypopyon and severe inflammation.<sup>5</sup> Less virulent organisms cause milder and later onset disease, which may respond to topical steroids, and are difficult to distinguish from persistent postoperative inflammation.<sup>6</sup>

The ocular surface flora is capable of causing endophthalmitis<sup>7–9</sup> and is the likely source of infection in most cases.<sup>10–11</sup> Bacteria can enter the eye at the time of uncomplicated surgery,<sup>11–12</sup> and they can be cultured from the anterior chamber in higher numbers after ECCE than after phaco.<sup>13</sup> An IOL can collect bacteria from the ocular surface during insertion, and form a focus for postoperative infection as with other prosthetic devices.<sup>14</sup>

We have found no studies specifically investigating the potential link between method of IOL implantation and risk of endophthalmitis. We have therefore studied the postoperative endophthalmitis rate in our unit during the 10 year period, which included the transition from ECCE to phaco. We recognise that such a study might lack sufficient statistical power, though given growing concerns regarding a possible disparity in the endophthalmitis rate associated with injectable versus foldable intraocular lens styles it was felt that such a study might yield useful information to justify a larger, prospective, multicentre trial.

## METHOD

We conducted a retrospective study of all cataract surgery in a single UK eye department (Department of Ophthalmology, Taunton and Somerset Hospital), over a 10 year period between June 1991 and June 2001. For the purposes of this study, endophthalmitis was defined as excessive postoperative intraocular inflammation after cataract surgery or secondary intraocular lens insertion, irrespective of microbial culture results or steroid responsiveness. Surgical and diagnostic data were obtained from the hospital admission and operating theatre computer databases that have remained largely unchanged throughout the study period. Additional checks were then made by reviewing theatre and ward diaries.

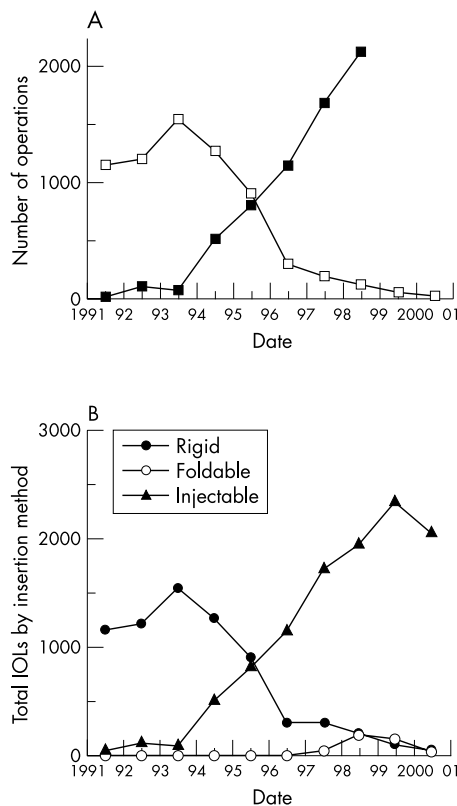
For each case of endophthalmitis the surgical details were recorded, including choice of IOL and introduction technique, and any operative complications. No preoperative or perioperative antibiotics were used routinely during the study period, and postoperative subconjunctival injections of antibiotic and steroid depended on the operating surgeon. Preoperative application of iodine to lid skin and irrigation of the conjunctival sac was routine in all cases, except where iodine allergy was documented, when chlorhexidine was used instead.

Our management of acute postoperative endophthalmitis did not change significantly over the 10 years. This involved an anterior chamber (AC) aspirate, and vitrectomy or vitreous aspirate, combined with intravitreal antibiotics (the standard doses being vancomycin 2 mg and amikacin 0.4 mg). High dose ciprofloxacin was often used intravenously or orally.

The incidence of endophthalmitis is presented with 95% confidence intervals (CI); groups are compared using  $\chi^2$  tests and Mann-Whitney tests and Spearman correlations as appropriate, using InStat 2.01. Graphs were plotted using Cricketgraph.

## RESULTS

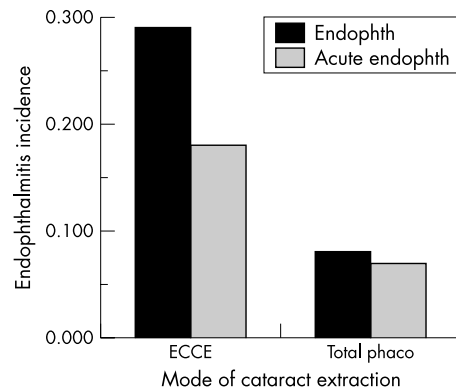
Over the 10 years, a total of 18 191 cataract operations were performed. During this time, ECCE was almost totally replaced by phaco (Fig 1A), and the number of ECCE cases (6823) was lower than phaco (11368). The phaco group included 141 rigid (PMMA) IOLs, 10815 injectable lenses



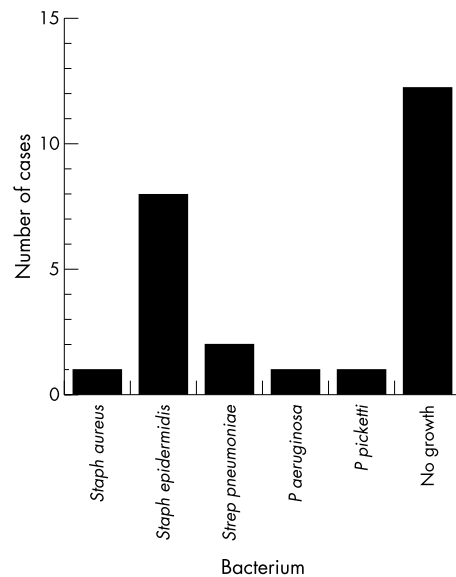
**Figure 1** Cataract surgery over a 10 year period, divided into 12 monthly intervals, and subdivided according to (A) the method of cataract extraction. (open symbol = ECCE and closed symbol = phacoemulsification). (B) the method of IOL implantation

(mostly C11UB Bausch and Lomb silicone plate lenses) and 412 manually folded lenses (Fig 1B). Towards the end of the study period, other injectable lenses were added, predominantly Allergan AR40 and SI40.

A total of 30 cases of endophthalmitis were recorded over the 10 years, giving an overall incidence of endophthalmitis of 0.16% (95% CI 0.11 to 0.24). The age range was 43–89 years, 73% of patients were female, and 50% of cases were in right eyes. The total of 30 can be broken down into groups according to the mode of cataract extraction and clinical presentation, as illustrated in Table 1 and Figure 2. Twenty one cases occurred after ECCE, eight after phaco, and one after secondary IOL insertion.  $\chi^2$  testing confirmed that there was a higher risk of endophthalmitis for ECCE than phaco (0.31% compared with 0.07%,  $p < 0.001$ , relative risk (RR) = 4.37, 95% CI = 1.94 to 9.87). Within the group of eight phaco cases, five had received manually folded IOLs, and three had received injectable IOLs. The rate of endophthalmitis for folded lenses (1.21%; 95% CI 0.40 to 2.81), was higher than for injectable lenses (0.028%; 95% CI 0.006 to 0.081). This difference was statistically significant ( $p < 0.001$ , RR = 43.8, 95% CI 10.5 to 18.2).



**Figure 2** The overall incidence of endophthalmitis over 10 years, subdivided according to method of cataract extraction and steroid responsiveness.



**Figure 3** The results of microbiological culture for the 26 cases of acute endophthalmitis. The organism is as named, and “no growth” refers to those cases where an attempt was made to obtain a microbiological diagnosis but no organism was grown.

Twenty four (80%) endophthalmitis cases followed routine cataract surgery, five (17%) followed an anterior vitrectomy before lens insertion, and one followed secondary IOL insertion. A total of 243 anterior vitrectomies were performed over the 10 years, and this gives an overall risk of endophthalmitis following anterior vitrectomy and IOL insertion of 2.06% (95% CI 0.7 to 4.7). For two of the three eyes that received injectable IOLs and went on to develop endophthalmitis, other potential risk factors were present: a leaking corneal section in one, and vitreous loss requiring an anterior vitrectomy in the other.

**Table 1** The incidence of endophthalmitis according to the type of cataract surgery

Cataract surgery (n = 18191)	Number of endophthalmitis cases (incidence)	Number of acute endophthalmitis cases (incidence)
ECCE (6823)	21 (0.31%)	13 (0.19%)
All phaco (11368)	8 (0.07%)	8 (0.07%)
Phaco and folded lens (412)	5 (1.21%)	4 (0.97%)
Phaco and injected lens (10815)	3 (0.028%)	3 (0.028%)

Twenty six cases (87%) underwent sampling of intraocular fluids, and an organism was cultured from the AC tap or vitreous biopsy in 14 (52%) (see Fig 3).

The presenting visual acuity (VA) varied from Snellen 6/12 to perception of light (PL). Final VA ranged from 6/5 to NPL, and was not significantly related to VA at presentation (Spearman  $r = 0.286$ , 95% CI  $-0.101$  to  $0.598$ ,  $p = 0.132$ ). As expected, acute cases achieved worse final visual acuity (median VA = 6/24) than those presenting after 2 weeks (median VA 6/9), and this difference was highly significant (Mann-Whitney U statistic  $p = 0.0003$ ). Overall, endophthalmitis patients had a 67% chance of seeing 6/24 or better after treatment to the affected eye, and patients who presented with PL visual acuity had a similar (64%) chance of achieving this level of vision. Three cases failed to improve beyond PL. Two of these presented with PL vision and developed retinal detachments (incidence of 6.7%), and one case underwent evisceration after failing to respond to repeated intravitreal antibiotics, IOL removal, and vitrectomy.

## DISCUSSION

Throughout the latter part of the study period there was a surgical preference for injectable IOLs because of perceived advantages with respect to wound size, optic diameter, and reduced risk of endophthalmitis. The study period was therefore chosen to reflect the transition from ECCE to phaco, and the introduction of injectable lenses. It is hypothesised that the lower incidence of endophthalmitis with injectable lenses reported in this study is due to the fact that the lenses do not make contact with the ocular surface.

Various factors may influence the risk of postoperative endophthalmitis. Prolonged surgery (over 1 hour), vitreous loss, and inadequate lid/conjunctival preparation may increase the risk.<sup>6 10 15</sup> Preoperative and postoperative antibiotics may have a protective role but their efficacy has not been conclusively demonstrated.<sup>16</sup> Peroperative subconjunctival antibiotics may only reach subtherapeutic levels in the anterior chamber,<sup>4</sup> and good clinical evidence to support their widespread use is lacking. Heparin has been used to coat the surfaces of IOLs, reducing bacterial adherence and potentially the incidence of endophthalmitis.<sup>17</sup> Heparin in the infusion fluid does not reduce bacterial contamination of the anterior chamber,<sup>18</sup> but may reduce the incidence of endophthalmitis by coating bacteria, intraocular surfaces and the IOL itself.<sup>19</sup> However, this may be less important with injected lenses that do not make contact with the ocular surface.

Topical povidone-iodine has been proved to reduce ocular surface flora, and lowers significantly the incidence of culture positive endophthalmitis without any adverse reactions.<sup>10</sup> In a recent review of endophthalmitis prophylaxis,<sup>20</sup> it was the only measure to receive a category B recommendation (moderately important to clinical outcome). All other measures reviewed were graded category C (possibly relevant but not definitely related to clinical outcome). Povidone-iodine appears to act by reducing the risk of bacterial adherence to an IOL during its passage into the eye.<sup>14</sup> Since injectable lenses do not make contact with the ocular surface they would not be contaminated in this way. In previous studies comparing ECCE and phaco, endophthalmitis rates have not differed greatly,<sup>1 21</sup> perhaps because phaco was performed with insertion of rigid IOLs.

Our study undoubtedly has limitations with respect to sample size, its retrospective nature, and potential differences between the practices of different surgeons. However, we hope that our findings may encourage others to look at this issue and report on it, and perhaps even lead on to a prospective multicentre study to test our hypothesis that injectable lenses are associated with a lower risk of endophthalmitis.

In conclusion, the incidence of endophthalmitis after phacoemulsification with injectable IOLs in our unit over 10 years has been significantly lower than published rates. This is most probably due to the fact that injectable IOLs do not touch the ocular surface, thereby lowering the risk of microbial contamination. The absence of low grade endophthalmitis in the injected lens group further supports this view. We feel that injection of intraocular lenses (by reducing the incidence of endophthalmitis) is the optimal mode of lens insertion following phacoemulsification.

## ACKNOWLEDGEMENTS

We would like to thank Mr Christopher Hutchins of the Clinical Information Department at Taunton and Somerset Hospital for his help with data retrieval. We would also like to thank Mrs Keron Butland and Mrs Carol Young for help with the retrieval of notes.

## Authors' affiliations

**E Mayer, D Cadman, J M Twomey, R H Gray, K G Claridge, K N Hakin, A K Bates**, Department of Ophthalmology, Taunton and Somerset Hospital, Musgrove Park, Taunton, TA1 5DA, UK  
**P Ewings**, Research and Development Unit

## REFERENCES

- 1 **Schein OD**, Steinberg EP, Javitt JC, *et al*. Variation in cataract surgery practice and clinical outcomes. *Ophthalmology* 1994;**101**:1142-52.
- 2 **Desai P**, Minassian DC, Reidy A. The National Cataract Survey 1997/1998: a report of the results of clinical outcomes. *Br J Ophthalmol* 1999;**83**:1336-40.
- 3 **Powe NR**, Schein OD, Geiser SC, *et al*. Synthesis of the literature on visual acuity and complications following cataract extraction with intraocular lens implantation. *Arch Ophthalmol* 1994;**112**:239-52.
- 4 **Aaberg TM**, Flynn HW, Schiffman J, *et al*. Nosocomial acute onset postoperative endophthalmitis survey. *Ophthalmol* 1998;**105**:1004-10.
- 5 **Johnson MW**, Doff BH, Kelsey SF, *et al*. The Endophthalmitis Vitrectomy Study Group. Relationship between clinical presentation and microbiologic spectrum. *Ophthalmology* 1997;**104**:261-72.
- 6 **Kresloff MS**, Castellarin AA, Zarbin MA. Endophthalmitis. *Surv Ophthalmol* 1998;**43**:193-224.
- 7 **Dunnington JH**, Locatcher-Khorazo D. Value of cultures before operation for cataract. *Arch Ophthalmol* 1945;**34**:215-9.
- 8 **Locatcher-Khorazo D**, Gutierrez E. Bacteriophage typing of *Staphylococcus aureus*. A study of normal, infected eyes and environment. *Arch Ophthalmol* 1960;**63**:774-87.
- 9 **Fahmy JA**, Moller S, Bentzon MW. Bacterial flora in relation to cataract extraction. II. Preoperative flora. *Acta Ophthalmol* 1975;**53**:476-94.
- 10 **Speaker MG**, Menikoff JA. Prophylaxis of endophthalmitis with topical povidone iodine. *Ophthalmology* 1991;**98**:1769-75.
- 11 **Sherwood DR**, Rich WJ, Jacob JS, *et al*. Bacterial contamination of intraocular and extra ocular fluids during extracapsular cataract extraction. *Eye* 1989;**3**:308-12.
- 12 **Beigi B**, Westlake W, Mangelschots E, *et al*. Peroperative microbial contamination of anterior chamber aspirates during extracapsular cataract extraction and phacoemulsification. *Br J Ophthalmol* 1997;**81**:953-5.
- 13 **Egger SF**, Huber-Spitz V, Skorpiak C, *et al*. Different techniques of extracapsular cataract extraction, bacterial contamination during surgery. *Graefes Arch Clin Exp Ophthalmol* 1994;**32**:308-11.
- 14 **Assia EI**, Jubran RZ, Solberg Y *et al*. The role of intraocular lenses in anterior chamber contamination during cataract surgery. *Graefes Arch Clin Exp Ophthalmol* 1998;**36**:721-4.
- 15 **Speaker MG**, Mich FA, Shah MK, *et al*. Role of external bacterial flora in the pathogenesis of acute postoperative endophthalmitis. *Ophthalmology* 1991;**98**:639-49.
- 16 **Starr MB**. Prophylactic antibiotics for ophthalmic surgery. *Surv Ophthalmol* 1983;**27**:353-73.
- 17 **Amon M**, Menapace R. Long-term results and biocompatibility of heparin-surface-modified intraocular lenses. *J Cataract Refract Surg* 1993;**19**:258-62.
- 18 **Manners TD**, Turner DP, Galloway PH *et al*. Heparinised intraocular infusion and bacterial contamination in cataract surgery. *Br J Ophthalmol* 1997;**81**:949-52.
- 19 **Montan PG**, Koranyi G, Setterquist HE, *et al*. Endophthalmitis after cataract surgery: Risk factors relating to technique and events of the operation and patient history. A retrospective case-control study. *Ophthalmology* 1998;**105**:2171-7.
- 20 **Ciulla TA**, Starr MB, Masket S. Bacterial endophthalmitis prophylaxis for cataract surgery. An evidence based update. *Ophthalmology* 2002;**109**:13-26.
- 21 **Williams DL**, Gills JP. Infectious endophthalmitis after sutureless cataract surgery. *Arch Ophthalmol* 1992;**110**:913.



## A 10 year retrospective survey of cataract surgery and endophthalmitis in a single eye unit: injectable lenses lower the incidence of endophthalmitis

E Mayer, D Cadman, P Ewings, et al.

*Br J Ophthalmol* 2003 87: 867-869

doi: 10.1136/bjo.87.7.867

---

Updated information and services can be found at:

<http://bjo.bmj.com/content/87/7/867.full.html>

---

### References

*These include:*

This article cites 21 articles, 6 of which can be accessed free at:

<http://bjo.bmj.com/content/87/7/867.full.html#ref-list-1>

Article cited in:

<http://bjo.bmj.com/content/87/7/867.full.html#related-urls>

### Email alerting service

Receive free email alerts when new articles cite this article. Sign up in the box at the top right corner of the online article.

---

### Topic Collections

Articles on similar topics can be found in the following collections

[Choroid](#) (435 articles)

[Eye \(globe\)](#) (543 articles)

[Lens and zonules](#) (642 articles)

[Ophthalmologic surgical procedures](#) (971 articles)

---

### Notes

---

To request permissions go to:

<http://group.bmj.com/group/rights-licensing/permissions>

To order reprints go to:

<http://journals.bmj.com/cgi/reprintform>

To subscribe to BMJ go to:

<http://group.bmj.com/subscribe/>