

PostScript

LETTERS

Charles Bonnet syndrome precipitated by brimonidine tartrate eye drops

Brimonidine tartrate (BT) (Alphagan) is an α -2 adrenergic agonist marketed for treatment of primary open angle glaucoma (POAG) which may have neuroprotective effects.¹ One report of acute delusional psychosis with auditory hallucinations in a 68 year old man treated for POAG has been published,² and use of BT eye drops in an infant resulted in coma and other serious systemic abnormalities.³ Here we report four elderly patients with bilateral visual loss who developed formed visual hallucinations (Charles Bonnet syndrome; CBS) shortly after beginning the use of BT eye drops. The hallucinations ceased after discontinuation of BT drops in three cases, and after decreasing the dose in one case, within a time frame of days to 4 months.

Case reports

Table 1 summarises visual function and the characteristics of the visual hallucinations in all four patients.

Comment

The Charles Bonnet syndrome is characterised by persistent or repetitive formed visual hallucinations in elderly individuals in the setting of significant bilateral prechiasmal visual impairment.⁴ The visual hallucinations in CBS are not routinely accompanied by other psychiatric symptoms and the affected individuals retain full or partial insight into the unreality of the visions.

Brimonidine tartrate is a lipid soluble α -2 adrenergic agonist that has a systemic half life of about 3 hours. It is excreted mainly by the kidneys with 87% of an oral dose eliminated after 120 hours.⁵ Auditory hallucinations, depression, confusion, and anxiety have been reported with BT use in an elderly adult² and coma, hypotension, bradycardia, hypotonia, and hypothermia was caused by BT eye drops given to an infant for treatment of

glaucoma.³ Clearly, BT has the capability of causing central nervous system side effects.

Oral clonidine, another α -2 adrenergic agonist, is known to cause visual hallucinations. Brown and coworkers⁶ described the case of a 31 year old woman treated with clonidine for poorly controlled hypertension who developed visions of "hands reaching for her from a closet or an old woman following her" in the presence of an otherwise clear sensorium. Also, clonidine use has caused delusional psychoses and auditory hallucinations in other patients.^{7,8}

All of our patients were at risk for the CBS based on age and visual impairment but none had had visual hallucinations before using BT. The onset of CBS ranged from 5 days to 2.5 months from starting BT. The visual hallucinations ceased in three of our patients within days of discontinuing BT (cases 1 and 3) or decreasing the dose (case 4), consistent with the washout period of the drug. In case 2, the hallucinations lasted on and off for about 4 months. Therefore the persistence of the hallucinations cannot be explained directly by persistent drug toxicity in this person. However, it is still possible that BT triggered the start of CBS in this individual. The natural history of duration of CBS is 47.4 months on average, with a range of 1-240 months.⁴ It should be noted that patient 2 also was taking a wide variety of drugs at the time BT was prescribed but their role, if any, in causing the visual hallucinations to persist is uncertain. For example, one study found no statistical difference in the number of drugs taken by patients seen in a geriatric psychiatry clinic who suffered from visual hallucinations when compared with a control group of elderly patients without hallucinations (4.4 (SD 3.1) drugs in the group with hallucinations).⁹

In summary, elderly people with bilateral visual impairment should be warned of the possibility of visual hallucinations resulting from BT use.

Acknowledgement

This work was supported in part by a gift from Laverne Kolbe Burke.

Conflict of interest: None of the authors has a conflict of interest involving any aspect of this publication.

R L Tomsak

Departments of Neurology and Ophthalmology, Division of Clinical Neuro-ophthalmology, University Hospitals of Cleveland, LKSD 3200, 1100 Euclid Avenue, Cleveland, OH 44106, USA

C R Zaret

Departments of Ophthalmology and Neurology, The Feinberg School of Medicine, Northwestern University, Chicago, IL, USA

D Weidental

Department of Ophthalmology, Case Western Reserve University School of Medicine, Cleveland, OH, USA

Correspondence to: Dr Robert L Tomsak, Departments of Neurology and Ophthalmology, Division of Clinical Neuro-ophthalmology, University Hospitals of Cleveland, LKSD 3200, 1100 Euclid Ave., Cleveland, OH 44106, USA; Robert.Tomsak@uhhs.com

Accepted for publication 9 November 2002

References

- Gao H, Qiao X, Cantor LB, *et al.* Up-regulation of brain-derived neurotrophic factor expression by brimonidine in rat retinal ganglion cells. *Arch Ophthalmol* 2002;120:797-803.
- Kim DD. A case of suspected Alphagan-induced psychosis. *Arch Ophthalmol* 2000;118:1132-3.
- Berlin RJ, Lee UT, Samples JR, *et al.* Ophthalmic drops causing coma in an infant. *J Pediatr* 2001;138:441-3.
- Teunisse RJ, Zitman FG, Raes DCM. Clinical evaluation of 14 patients with the Charles Bonnet syndrome (isolated visual hallucinations). *Comp Psychiatry* 1994;35:70-5.
- Brimonidine (Management/Treatment Protocol). In: Toll LL, Hurlbut, eds. *Poisindex System*. Vol 113. Greenwood Village, CO: Micromedex, 2002.
- Brown MJ, Salmon D, Rendell M. Clonidine hallucinations. *Ann Intern Med* 1980;93:456-7.
- Lavin P, Alexander CP. Dementia associated with clonidine therapy. *BMJ* 1975;1:628.
- Enoch MD, Hammad GEM. Acute hallucinosis due to clonidine. *Curr Med Res Opin* 1977;4:670-1.
- Holroyd S. Visual hallucinations in a geriatric psychiatry clinic: prevalence and associated diagnoses. *J Geriatr Psychiatry Neurol* 1996;9:171-5.

Table 1 Clinical characteristics

Age	Sex	VA	Visual fields	Visual hallucinations
79	F	RE 20/20 LE 20/25	Humphrey 24-2; constriction to 15 degrees; MD -16.68 dB Humphrey 24-2; complete loss of inferior nasal field; MD -12.61 dB	"like dreaming while awake . . . water dripping from the ceiling"
82	F	RE 20/80 LE FC	Humphrey 81-3 zone; 51/81 points not seen Confrontation; FC ability in all but inferior nasal field	"A changing visual panorama . . . halls green with diamond-like pattern . . . blue flowers covering the bathroom . . . small red and grey tiles on the carpet . . . the walls looked like they were made of brick"
78	M	RE 20/25 LE 5/200	Humphrey 81-3 zone; 55/81 points not seen Humphrey 81-3 zone; 50/81 points not seen	"I saw images of my bedroom wallpaper all over my house . . ."
89	F	RE 20/40 LE 20/40	Humphrey 24-2; MD -3.14 Humphrey 24-2; MD -11.66 Dense inferior field defect	People in the room that were not there . . . people or shadows standing near the elevator

VA = visual acuity; MD = mean deviation; FC = finger counting.

Trends in squint surgical activity

It has recently been reported that there has been a trend in the United Kingdom towards fewer children requiring strabismus surgery.¹ Unless there has been a change in the incidence of childhood strabismus, it may reflect a change in the clinical practices of ophthalmologists, optometrists, and orthoptists. One such practice is the correction of associated refractive errors. The correction of a hypermetropic refractive error is an important aspect in the management of esotropia.¹⁻⁴ Although the full hypermetropic correction is usually prescribed for children with an esotropia, it is unclear whether this is, or has been, uniform in practice. Indeed, certain texts suggest a reduction in the hypermetropic correction following a cycloplegic refraction, to take into account so called accommodative tonus.⁴ Because of the effect of an undercorrection of a hypermetropic refractive error on the angle of esotropia, we were interested to determine whether a change in spectacle prescribing practice had had any effect on the number of patients undergoing squint surgery.

Methods

Data were collected from the computerised hospital attendance statistics and operations at the Royal Liverpool Children's NHS Trust Hospital, which were available from the financial year 1988-9 onwards. The annual number of ophthalmic referrals and operations, were collected within two time periods: a 4 year period from 1988-9 to 1991-2 (period 1) and a 7 year period from 1994-5 to 2000-1 (period 2). Before 1992, it had been the practice to prescribe spectacles with a 0.5-1 dioptre reduction in the spherical component of the cycloplegic refractive error. From the period 1994 onwards, it was the practice of the consultant for the full cycloplegic hypermetropic error to be prescribed. Data were not collected between 1992 and 1994 to allow for a possible washout period for those patients who had previously been prescribed an undercorrected hypermetropic correction and were undergoing surgery between 1992 and 1994. The total number of eye and squint operations performed per 100 patient referrals, and the ratio between the squint and non-squint operations performed were calculated. The difference between the two periods was compared using the Fisher's exact test and confidence intervals calculated by the Miettinen approximation method.

Results

During periods 1 and 2, 4514 and 10 314 new patients were seen, of whom 23.9% and 23.6% underwent some form of ophthalmic surgery ($p > 0.5$). There was a significant difference between the mean number of squint operations per 100 patients in period 1 compared to period 2 (14.8% and 9.3%, $p < 0.0001$, proportion difference 0.060, 95% CI 0.047 to 0.073). There was also a significant difference in the mean number of squint operations per 100 total operations performed in period 1 compared to period 2 (61.9% and 38.2%, $p < 0.0001$, proportion difference 0.243, 95% CI 0.203 to 0.283).

Comment

Although it was not possible to examine the population profiles in the time periods studied, there had been no known change in the population profile or referring practices. The hospital data retrieval system, unfortunately, did not permit us to differentiate between a

new patient seen with a squint and another seen with a non-squint problem. While the proportion of children who required surgery had remained constant, there had been, similar to a recent report,¹ a reduction in the number of squint operations being performed, with a corresponding increase in the proportion of non-squint operations. We agree that there were likely to have been a variety of other factors contributing to the reduction in strabismus surgery. However, this trend may reflect in part, a change in practice whereby children with strabismus who had a hypermetropic refractive error were, during the latter period, prescribed their full hypermetropic correction.

J Shankar, S Kaye

St Paul's Eye Unit, 8Z Link, Royal Liverpool University Hospital, Prescot Street, Liverpool L7 8XP, UK

Correspondence to: Stephen Kaye, St Paul's Eye Unit, 8Z Link, Royal Liverpool University Hospital, Prescot Street, Liverpool L7 8XP, UK; stephen.kaye@rlbuh-tr.nwest.nhs.uk

Accepted for publication 13 November 2002

References

- 1 **Carney CV**, Lysons DA, Tapley JV. Is the incidence of constant esotropia in childhood reducing? *Eye* 1995;9:40-1.
- 2 **Abrams D**. Binocular muscle anomalies—heterotropia. *Duke-Elder's practice of refraction*. 9th ed. London: Churchill Livingstone, 1978:90.
- 3 **Elkington A**, Frank H. *Practical clinical refraction. Clinical optics*. 2nd ed. Oxford: Blackwell Science, 1991:181.
- 4 **Bennett AC**, Rabbets RB. *Clinical visual optics*. 2nd ed. Oxford: Butterworth-Heinemann, 1984:133.

Botulinum toxin treatment of "one and a half syndrome"

Complex forms of nystagmus and conjugate eye movement deficits are generated if the pontine paramedian structures are damaged. These can cause troublesome and occasionally disabling symptoms. The combination of one sided horizontal gaze palsy and ipsilateral internuclear ophthalmoplegia (INO), known

as "one and a half syndrome," is most commonly caused by demyelination, vascular disease or tumours.^{1,2} Ophthalmological symptoms include diplopia, oscillopsia or blurred vision and are often remarkably challenging to manage.³ Since the introduction of botulinum toxin A (BTA)⁴ for ocular motility disorders and nystagmus⁵ there have been a number of reports that establish the use of BTA as a treatment option in the management of complex ocular motility disorders.

We report the use of BTA in a patient with one and a half syndrome.

Case report

A 52 year old white male patient was admitted to our institution with dysarthria and right arm weakness of sudden onset. Three years before he had suffered a post-coital subarachnoid haemorrhage from a right middle cerebral artery aneurysm. He had had his aneurysm clipped and had managed an almost complete recovery. He was overweight and hypertensive.

When he was admitted it was noted that he had right facial weakness and his right eye was abducted. Cranial imaging showed considerable volume loss and gliosis in the right frontoparietal region and a possible small infarct in the right side of pons. A few days after the incident and when the patient regained consciousness he complained of oscillopsia from his right eye and an ophthalmological opinion was requested.

Examination of this patient was hampered by his poor mobility and severe dysarthria. He was found to have a complete left gaze palsy and a left INO. He was divergent in the primary position with an angle of approximately 45 prism dioptres (Krimsky). Vertical eye movements were preserved, although he was reluctant to elevate or depress his eyes and the examination of convergence was inconclusive (Fig 1). His main symptom was oscillopsia due to the abducting nystagmus of his non-paretic right eye, which was only relieved with occlusion of the eye with a patch.

A clinical diagnosis of one and a half syndrome secondary to a cerebrovascular event was made. His concurrent exotropia is a well described, even if uncommon feature of

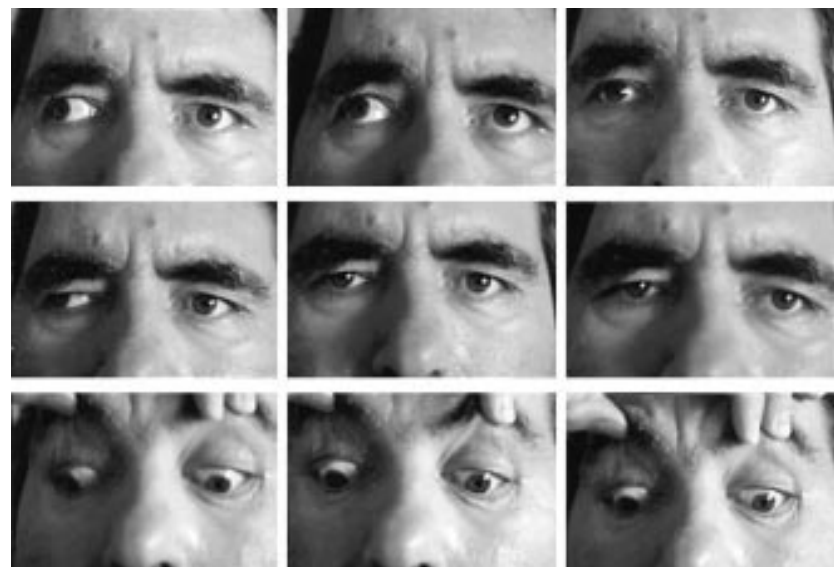

Figure 1 Still photographs of eye movements before botulinum toxin. Permission for photograph given by patient.

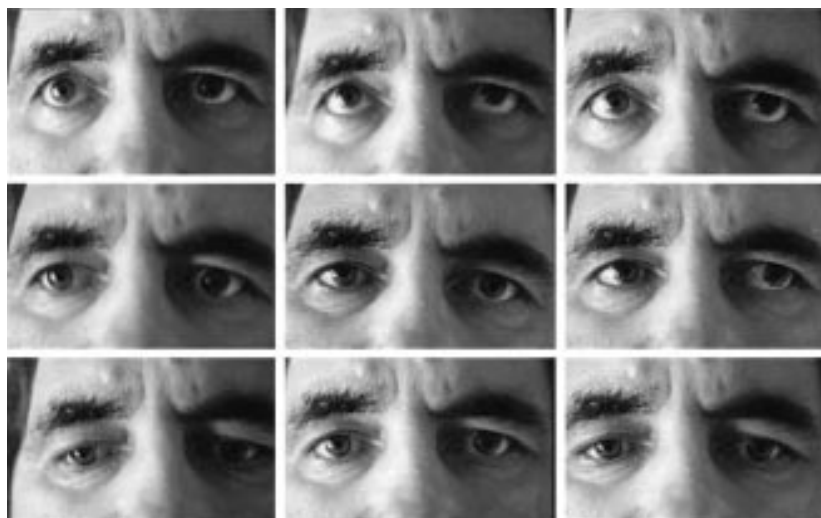

Figure 2 Still photographs of eye movements 3 weeks after injection of botulinum toxin. Permission for photograph given by patient.

this syndrome and is explained by a tendency of the contralateral eye to drift in the opposite direction due to the horizontal gaze palsy.² Thus, one and a half syndrome has also been called paralytic pontine exotropia.

Botulinum toxin was injected into the right lateral rectus muscle under EMG control. Three weeks after the injection the patient's symptoms had improved. In the primary position he showed only a very small amount of divergence. He had disposed of the patch as he had no oscillopsia. There was an abduction deficit in the right eye, presumably as a result of the BTA injection with elimination of the abducting nystagmus (Fig 2).

Three months after BTA injection he remained symptom free. He was still very slightly divergent in the primary position. His left gaze palsy showed some mild improvement without abducting nystagmus of the right eye. He did not report diplopia or oscillopsia.

Comment

Eye symptoms following damage to pontine structures have been shown to fluctuate with time and often spontaneously resolve.² However, persistent symptoms can also occur. Intractable diplopia or oscillopsia of even a few months' duration can prove functionally disabling to the patients especially when bed bound.⁵ The transient nature of the BTA therapeutic effect makes it the most suitable management for these complex ocular motility problems.

In our patient, although his one and a half syndrome was associated with exotropia, the main disturbance was caused by his acquired abducting nystagmus. It could be argued that the duration of symptoms between presentation and administration of the toxin was not sufficient to ensure that the condition would not have resolved spontaneously. However, the timing of symptom resolution despite the persistence of INO features suggest that the improvement was more probably due to the effect of the toxin. What is more, because of the severe general disability following his stroke, this patient was the ideal subject for such treatment: by injecting his last working muscle we produced an artificial impairment of the vestibulo-ocular reflex, which generates eye movements to compensate for head perturbations. Paralysing eye movements

with BTA may abolish oscillopsia from nystagmus but can cause oscillopsia during head movements.⁷ Our patient was so severely immobilised that this was not an issue, both because of limited head movement and the fact that the vestibulo-ocular reflex is less essential in bed bound patients. There was a definite subjective improvement in the quality of life with the abolishment of his abducting nystagmus. We have not been able to explain the absence of diplopia after treatment, in spite of a small residual divergence.

There has been a previous report of a patient with one and a half syndrome treated with BTA⁸ but on that occasion the toxin was administered into the retrobulbar space of the eye ipsilateral to the INO. To our knowledge this is the first report of one and a half syndrome treated with a BTA injection in a selected extraocular muscle.

In conclusion, injection of botulinum toxin to selected extraocular muscles can provide a useful alternative to occlusion, drug, or surgical therapies for patients with complex ataxic nystagmus resulting from pontine lesions. Patients suffering from oscillopsia due to ataxic disconjugate nystagmus may benefit from this approach as most other treatments are unsuitable for such cases. There does not seem to be any particular benefit in waiting for stabilisation of symptoms and signs. Selected toxin injection may improve the quality of life during the rehabilitation period.

A Kipioti, R H Taylor

York District Hospital, Wigginton Road, York YO3 7HE, UK

Correspondence to: Miss Tina Kipioti, Eye Department, Clarendon Wing, Leeds General Infirmary, Leeds LS2 9NS, UK; tinakipioti@doctors.org.uk

Accepted for publication 16 November 2002

References

- 1 **Kataoka S**, Hori A, Shirakawa T, *et al*. Paramedian pontine infarction. Neurological/topographical correlation. *Stroke* 1997;**28**:809–15.
- 2 **Miller NR**. Topical diagnosis of neuropathic ocular motility disorders. In: Miller NR, ed. *Walsh and Hoyt's clinical neuro-ophthalmology*. 4th ed. Baltimore: Williams & Wilkins, 1985;2:712–15.

- 3 **De Seze J**, Lucas C, Leclerc X, *et al*. One-and-a-half syndrome in pontine infarcts: MRI correlates. *Neuroradiology* 1999;**41**:666–9.
- 4 **Scott AB**, Rosenbaum A, Collins CC. Pharmacologic weakening of extraocular muscles. *Invest Ophthalmol* 1973;**12**:924–7.
- 5 **Helveston EM**, Pogrebnik AE. Treatment of acquired nystagmus with botulinum A toxin. *Am J Ophthalmol* 1988;**106**:584–6.
- 6 **Kosmin AS**, Marsh JB, Batterbury M. The use of botulinum toxin injections in the management of acquired nystagmus and oscillopsia. *Clinical Rehabilitation* 1996;**10**:205–9.
- 7 **Tomsak RL**, Remler BF, Averbuch-Heller L, *et al*. Unsatisfactory treatment of acquired nystagmus with retrobulbar injection of botulinum toxin. *Am J Ophthalmol* 1995;**119**:489–96.
- 8 **Ruben ST**, Lee JP, O'Neil D, *et al*. The use of botulinum toxin for treatment of acquired nystagmus and oscillopsia. *Ophthalmology* 1994;**101**:783–7.

Retinal and subdural haemorrhages: Aoki revisited

In the United States and much of the English speaking world, the combination of retinal and subdural haemorrhages in a very young child is highly suggestive of non-accidental injury and felt to be incompatible with a history of a minor fall. Thus, when Aoki *et al*¹ published 26 cases of infants, age 3–14 months, with this combination following minimal falls, even though they stated in their article "in this series, none of the patients had a significant medical history or were subjects of child abuse before the trauma," there was immediate concern² that these may have been undiagnosed cases of shaken baby syndrome (SBS). Aoki responded to this by saying "we do not believe the injuries were caused by battering or shaking" although noting their "series might include some injuries caused by abuse." In 1987, Ikeda *et al*³ added cases to the Japanese experience noting these were "usually caused by a simple domestic head injury" and indicating they were aware of the battered child syndrome.

A comparison of the age distributions of the Aoki and Ikeda series shows them to be very similar (a simple *t* test not being able to rule they are different with even a 20% probability). However, if either Japanese series or a combination of the two are compared to Kivlin's⁴ SBS series in the United States, it is apparent these are not the same (the probability by a simple *t* test shows there to be between less than one chance in 400 and a chance in a million that these age distributions are the same) (Tables 1 and 2).

Recent articles^{5,6} have again brought into question the assumption that a history of a minimal fall is incompatible with the finding of subdural haematoma and retinal haemorrhage in an infant. However, even if some of the Japanese cases are from abuse, some of the American cases may be from minimal falls. The United States assumption would require all the Japanese cases to be misdiagnoses and all 26–40 independent stories in Japan (which are similar to many of the United States stories) to be similar prevarications. Instead of discarding the Japanese experience, an inquiry as to why the age distributions are so different seems appropriate.

H B Gardner

Manitou Springs, CO, USA; horacebgardner@yahoo.com

Accepted for publication 17 November 2002

Table 1 Age distributions

		Age (months)															
		1	2	3	4	5	6	7	8	9	10	11	12	13	14	15	16
Number of cases	Kivlin	9	13	18	15	6	10	7	4	1	6	3	3	3	1	2	1
	Aoki	0	0	1	1	1	1	6	6	2	5	2	0	1	0	0	0
	Ikeda	0	0	0	0	0	0	3	1	3	3	1	1	0	0	1	1

Table 2 Probabilities

	t value	Degrees of freedom	Probability
Aoki = Ikeda	0.79	13	>0.200
Ikeda = Kivlin	3.43	13	<0.0025
Aoki = Kivlin	4.66	25	<0.0005
A + I = Kivlin	6.09	39	<0.000001

References

- 1 **Aoki N**, Masuzawa H. Infantile acute subdural hematoma. Clinical analysis of 26 cases. *J Neurosurg* 1984;**61**:273-80.
- 2 **Rekate HL**. Subdural hematomas in Infants. *J Neurosurg*. 1985;**62**:316-17.
- 3 **Ikeda A**, Sato O, Tsugane R, et al. Infantile acute subdural hematoma. *Child's Nerve Syst* 1987;**3**:19-22.
- 4 **Kivlin JD**. A 12-Year ophthalmologic experience with the shaken baby syndrome at a regional children's hospital. *Trans Am Ophthalmol Soc* 1999;**97**:545-581.
- 5 **Ommaya AK**, Goldsmith W, Thibault L. Biomechanics and neuropathology of adult and paediatric head injury. *Br J Neurosurg* 2002;**16**:220-42.
- 6 **Uscinski R**. Shaken baby syndrome: fundamental questions. *Br J Neurosurg* 2002;**16**:217-19.

Treatment of vascular tufts at the pupillary margin before cataract surgery

Iris vascular tufts or microhaemangiomas are an infrequent finding on ophthalmic evaluation. Previous reports have attributed vascular tufts at the pupillary margin of the iris to diabetes, myotonic dystrophy,¹ in association with Sturge-Weber syndrome,² or in association with haemangioma of the orbit or eyelid. We describe a patient with multiple cutaneous and iris margin haemangiomas who had a history of recurrent hyphaema and underwent successful argon laser treatment of pupillary margin haemangiomas before extracapsular cataract extraction with intraocular lens implantation.

Case report

The patient is a 75 year old man first seen 2 years earlier by the retinovascular service at the Wilmer Eye Institute, Baltimore, MD, USA, for recurrent hyphaema in the left eye. He was noted to have multiple haemangiomas on the pupillary border of both eyes as well as numerous cutaneous haemangiomas on his trunk. A small hyphaema was appreciated inferiorly in the left eye with no active bleeding. Gonioscopic examination was normal except for blood in the inferior angle and the intraocular pressure was 16 mm Hg in each eye. There was no corneal endothelial blood staining. He was treated with homatropine hydrobromide ophthalmic solution 5% (Ciba Vision, Duluth, GA, USA) twice a day and

prednisolone acetate 1% (Falcon Pharmaceuticals, Fort Worth, TX, USA) four times a day for 1 week to decrease light sensitivity and to prevent intraocular inflammation. The hyphaema subsequently resolved without sequelae. It was suggested that if he suffered a rare occasional haemorrhage he would be treated symptomatically, but multiple repeat haemorrhages would be treated with laser coagulation or surgical excision.

He now presents to the cornea, cataract, and refractive service at the Wilmer Eye Institute for reduced visual acuity primarily in the right eye. On examination, Snellen visual acuity measured 20/400 in the right eye with an intraocular pressure measuring 15 mm Hg. Pupils were round and reactive without an afferent pupillary defect. External examination was significant for multiple 1-2 mm raised cutaneous haemangiomas on the chest, neck, and back (Fig 1). The lesions were painless to touch, and according to the patient, have been increasing in number since childhood yet hadn't increased in size, changed colour, nor caused bleeding. Slit lamp biomicroscopic examination was significant for multiple small vascular loops along the pupillary margin of the iris in each eye (Fig 2). Gonioscopic examination showed no neovascularisation of the anterior chamber angle. After dilatation, there was no active bleeding

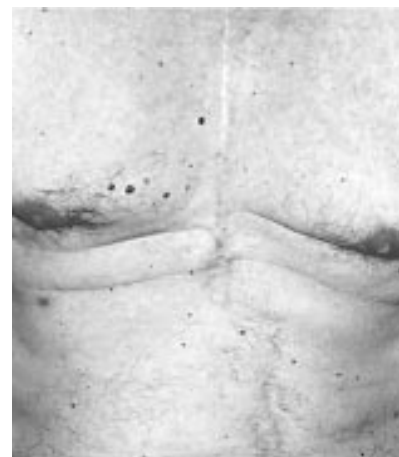

Figure 1 Multiple cutaneous haemangiomas on the trunk.

but evidence of pigment clumps on the anterior capsule in each eye. The right crystalline lens showed dense nuclear sclerosis and posterior subcapsular cataractous change. Fundoscopic examination demonstrated a cup to disc ratio of 0.7 in the right eye. The disc, macula, and vessels were normal except for mild arteriolar narrowing. The examination of the left eye was significant for venous congestion with a small superficial nerve fibre layer haemorrhage on the inferior border of the disc. This possibly represented an impending vein occlusion.

Although it was believed that cataract surgery could be done safely without addressing the management of the angiomas, the risk of lasering the angiomas was low and if closure of the vascular loops was achieved, the intraoperative risk for bleeding might be reduced. The patient was taken off aspirin before the laser treatment and an iris angiogram was performed to guide treatment in order not to miss any subclinical leaking vascular tufts (Fig 3). Argon laser was used with 200 µm spot size, power of 200 mW for 0.1 second duration. A total of 50 spots were administered to close all tufts appreciated clinically and angiographically. No bleeding was noted during the procedure. The patient subsequently underwent uncomplicated extracapsular cataract extraction through a clear corneal incision under topical anaesthesia. Upon insertion of the intraocular lens, a small amount of blood was noticed in the anterior chamber, most probably secondary to iris trauma during the manoeuvre. This was washed out with balanced salt solution. No blood was noticed in the anterior chamber on the first postoperative day nor during a 10 month postoperative follow up period.

Comment

Vascular anomalies of the pupillary margin are rarely seen but have been previously implicated as a possible cause of spontaneous hyphaema.³ More unusual are iris haemangiomas associated with cutaneous haemangiomas. Generalised cutaneous and visceral

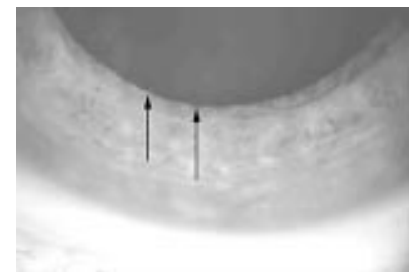


Figure 2 Slit lamp biomicroscopic image of pupillary margin vascular loops (arrows).

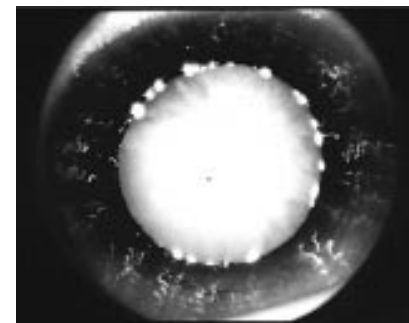


Figure 3 Iris angiogram showing multiple leaking vascular tufts at the pupillary margin.

haemangiomas have been described as diffuse congenital haemangiomas in neonates,⁴ but iris and cutaneous haemangiomas in adults are infrequently described.

Vascular tufts at the pupillary margins are usually asymptomatic and if hyphaema does occur, recurrence is unlikely.⁵ Past treatment had been reserved for patients with recurrent hyphaema or bleeds recalcitrant to medical management. Argon laser treatment of a bleeding iris vascular tuft has been described twice previously for active bleeding resulting in hyphaema with increased intraocular pressure. In both case reports, few laser applications easily stopped the haemorrhaging.^{6,7} Our patient suffered recurrent hyphaemas in one eye and presented with a mature cataract in the other. Surgical decompression of the globe, surgical manipulation causing trauma to the fragile vascular loops, hypotony, and frequent postoperative use of mydriatics causing pupillary "gymnastics" can all cause haemorrhage in patients with otherwise asymptomatic vascular tufts.⁸ Although no previous study demonstrated bleeding of the fragile vascular tufts with surgical decompression, it was theorised that closure of the haemangiomas would reduce the intraoperative risk of bleeding during cataract surgery. The major risk of the laser was bleeding during the procedure, but this was considered low compared to a possible bleeding process during surgery because a closed eye procedure would allow for a more rapid tamponade of any bleeding process. Another risk was the possible damage to the lens that would be extracted in any case. Other laser risks were intraocular inflammation due to iris or lens damage and glaucoma, which can be caused by an inflammatory process or the result of hyphaema.

We observed only minimal bleeding from the iris during cataract surgery and no further hyphaema in the postoperative period and therefore recommend considering argon laser treatment to pupillary margin vascular tufts before surgery to decrease the possibility of intraoperative and well as postoperative complications of uncontrolled haemorrhaging.

Financial interest: none.

M Winnick, E Margalit, A P Schachat, W J Stark

Cornea, Cataract and Refractive Service and the Retinal Vascular Center, Wilmer Eye Institute, Johns Hopkins University School of Medicine, Baltimore, MD, USA

Correspondence to: Walter J Stark, MD, Corneal and Cataract Services, Wilmer Eye Institute, 327 Maumenee Building, 600 N. Wolfe Street, Baltimore, MD 21287-9238, USA; wstark@jhmi.edu

Accepted for publication 19 November 2002

References

- 1 **Cobb B**, Shilling JS, Chisholm IH. Vascular tufts at the pupillary margin in myotonic dystrophy. *Am J Ophthalmol* 1970;**69**:573-82.
- 2 **Reese AB**. *Tumors of the eye*. 3rd ed. New York: Harper & Row, 1976:282.
- 3 **Dahlmann AH**, Benson MT. Spontaneous hyphema secondary to iris vascular tufts. *Arch Ophthalmol* 2001;**119**:1728.
- 4 **Naidoff MA**, Kenyon KR, Green WR. Iris hemangioma and abnormal retinal vasculature in a case of diffuse congenital hemangiomas. *Am J Ophthalmol* 1971;**72**:633-44.
- 5 **Podolsky M**, Srinivasan BD. Spontaneous hyphema secondary to vascular tuft of pupillary margin of the iris. *Arch Ophthalmol* 1979;**97**:301-2.
- 6 **Coleman SL**, Green WR, Patz A. Vascular tufts of pupillary margin of iris. *Am J Ophthalmol* 1977;**83**:881-3.

7 **Hagen AP**, Williams GA. Argon laser treatment of a bleeding iris vascular tuft. *Am J Ophthalmol* 1986;**101**:379-80.

8 **Maner RS**, Sachs W. Spontaneous hyphema. *Am J Ophthalmol* 1972;**74**:293-5.

Treatment of retinal folds using a modified macula relocation technique with perfluoro-hexyloctane tamponade

Retinal folds are a relatively uncommon complication of retinal surgery. Macula involvement can produce poor acuity and disturbing metamorphopsia. We report a novel treatment for macula fold using the surgical techniques of foveal translocation and perfluoro-hexyloctane (F_6H_8), a new heavier than water agent licensed for long term internal tamponade.^{1,2}

Case report

A 51 year old man with Terson's syndrome was found to have retinal detachment on B-scan ultrasonography. He underwent vitrectomy and lensectomy with C_2F_6 gas tamponade for a superior, macula off retinal detachment. He was postured face down overnight. A retinal fold crossing the macula was noted on the first postoperative day (Fig 1A). At 3 months the best corrected acuity was 6/24. The patient described the image in the affected eye as being split diagonally, with the two half images separated. He was referred to our unit for further management.

We used a 41 gauge needle to detach approximately one quarter of the retina by saline infusion into the subretinal space.³ F_6H_8 was injected displacing subretinal fluid (SRF) anteriorly, opening up the retinal fold and reapposing the photoreceptors to the pigment epithelium. No direct retinal manipulation was required. The SRF was left in situ and the patient postured on his back to allow the retina to "iron out" slowly as the SRF resorbed. The F_6H_8 was removed after 5 days. The retina remained flat, without folds (Fig 1B). Seven weeks after surgery his metamorphopsia had resolved with a best corrected acuity of 6/18+2.

Electroretinography was performed before and 10 weeks after surgery using ISCEV standard protocol. The ERG responses showed no evidence of diminution following redetachment and subsequent removal of F_6H_8 tamponade. (Standard flash in dark adapted state gave a-wave amplitudes of 195 μV before surgery and 219 μV after; b-wave amplitudes of 367 μV before and 453 μV after.)

Comment

Retinal folds through the macula have been reported following both vitrectomy⁴ and conventional surgery for retinal detachment.⁵ Van Meurs *et al* report the incidence as 2.8% with conventional surgery.⁶ Risk factors for retinal

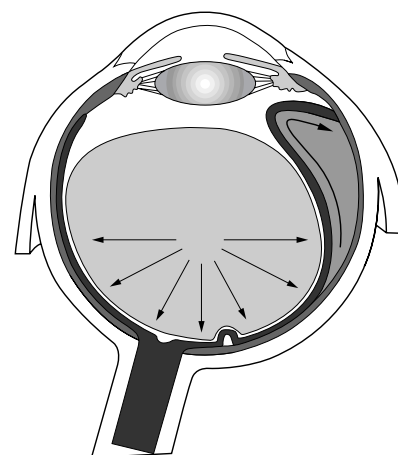


Figure 2 Perfluoro-hexyloctane displaces subretinal fluid anteriorly, putting the retina on stretch, and ironing out the fold.

folds include superior bullous detachment, gas tamponade (bubble large in relation to detachment), circumferential buckles, and incomplete drainage of SRF. When gas tamponade is used in the presence of residual SRF starting the posturing with the break dependent and slowly rolling the patient to the desired posture may reduce the risk of macula folds. Larrison *et al*⁴ reported that out of 15 cases with folds involving the macula one third had postoperative acuity of 6/60 or worse and only one third managed 6/18 or better (mean follow up 25 months). Recent data from a dog model of macula relocation⁷ suggest that macula folds may be associated with progressive visual deterioration. Hayashi *et al* demonstrated progressive loss of photoreceptors and thinning of the outer nuclear layer within retinal folds. TUNEL assay showed apoptotic cells in the outer and inner nuclear layers of the folds.

Perfluoro-hexyloctane is a semi-fluorinated alkane with a specific gravity of 1.35, and a high interfacial tension to water (49 mN/m). Its use in complicated retinal detachment surgery and the histology of associated epiretinal membranes have been reported.^{2,8}

We have previously demonstrated that the retina can be stretched by brushing, a phenomenon we referred to as redistribution of neurosensory retina.³ Macular translocation can be achieved without sclera imbrication to generate redundancy,⁹ by introducing a gas bubble in the presence of a bullous retinal detachment. The bubble occupies the top half of the vitreous cavity. The SRF is displaced inferiorly and, confined by the anterior attachment of retina, puts the macula on stretch.

Similarly, in our patient, we induced a bullous retinal detachment, used a bubble of

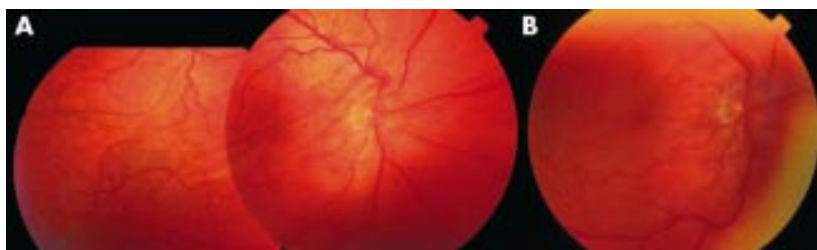

Figure 1 Fundus photograph showing macula fold before surgical correction (A), and 7 weeks after correction (B).

heavy liquid and postured the patient supine. The F_4H_8 occupied the dependent part of the vitreous cavity and displaced the SRF peripherally and anteriorly. The SRF is confined by the attachment of the retina at the ora serrata. This effectively put the retina on stretch and "ironed out" the macular fold (Fig 2).

Kertes and Peyman¹⁰ reported treatment of retinal folds in two patients having surgery for tractional retinal detachment (one diabetic, one toxocara granuloma). They used per-operative perfluoro-perhydrophenanthrene tamponade and direct retinal manipulation with a silicone tipped cannula. No significant visual improvement was noted as the folds were outside the macula. Our technique involves no direct instrumental manipulation of the central retina. We have been able to effectively treat the macular fold by exploiting the specific gravity of the tamponade agent. Avoidance of macula folds by addressing causative factors is obviously preferable to treatment. We have been impressed with the complete disappearance of the fold in this case. In selected cases surgery may be appropriate to alleviate troublesome metamorphopsia and possibly reduce the risk of permanent and progressive reduction in vision resulting from the macular fold.

E N Herbert, C Groenewald, D Wong

Royal Liverpool University Hospital, Prescott Street, Liverpool L8 7NP, UK

Correspondence to: Edward N Herbert, Royal Liverpool University Hospital, Prescott Street, Liverpool L8 7NP, UK; enherbert@doctors.org.uk

Accepted for publication 4 December 2002

References

- 1 Zeana D, Becker J, Kuckelkorn R, *et al*. Perfluorohexyloctane: a long term vitreous tamponade in the experimental animal. *Int Ophthalmol* 1999;**23**:17–24.
- 2 Kirhhof B, Wong D, van Meurs J, *et al*. Use of perfluorohexyloctane as a long-term internal tamponade agent in complicated retinal detachment surgery. *Am J Ophthalmol* 2002;**133**:95–101.
- 3 Wong D, Lois N. Foveal relocation by redistribution of the neurosensory retina. *Br J Ophthalmol* 2000;**84**:352–7.
- 4 Larrison WI, Frederick AR Jr, Peterson TJ, *et al*. Posterior retinal folds following vitreoretinal surgery. *Arch Ophthalmol* 1993;**111**:621–5.
- 5 Pavan PR. Retinal fold in macula following intraocular gas. *Arch Ophthalmol* 1984;**102**:83–4.
- 6 Van Meurs JC, Humalda D, Mertens DA, *et al*. Retinal folds through the macula. *Doc Ophthalmol* 1991;**78**:335–40.
- 7 Hayashi A, Usui S, Kawaguchi K, *et al*. Retinal changes after retinal translocation surgery with scleral imbrication in dog eyes. *Invest Ophthalmol Vis Sci* 2000;**41**:4288–92.
- 8 Hiscott P, Magee RM, Colthurst M, *et al*. Clinicopathological correlation of epiretinal membranes and posterior lens opacification following perfluorohexyloctane. *Br J Ophthalmol* 2001;**85**:179–83.
- 9 De Juan E Jr, Vander JF. Effective macula translocation without scleral imbrication. *Am J Ophthalmol* 1999;**128**:380–2.
- 10 Kertes PJ, Peyman GA. Management of dry retinal folds. *Int Ophthalmol* 1997;**21**:53–5.

Is hyaline degeneration of the cornea a precursor of Salzmann's corneal degeneration?

Hyaline degeneration of the cornea has been described by Smolin and Thoft¹ as a specific and rare pathological entity. Other authors have used the term hyaline degeneration of the cornea synonymous with climatic droplet

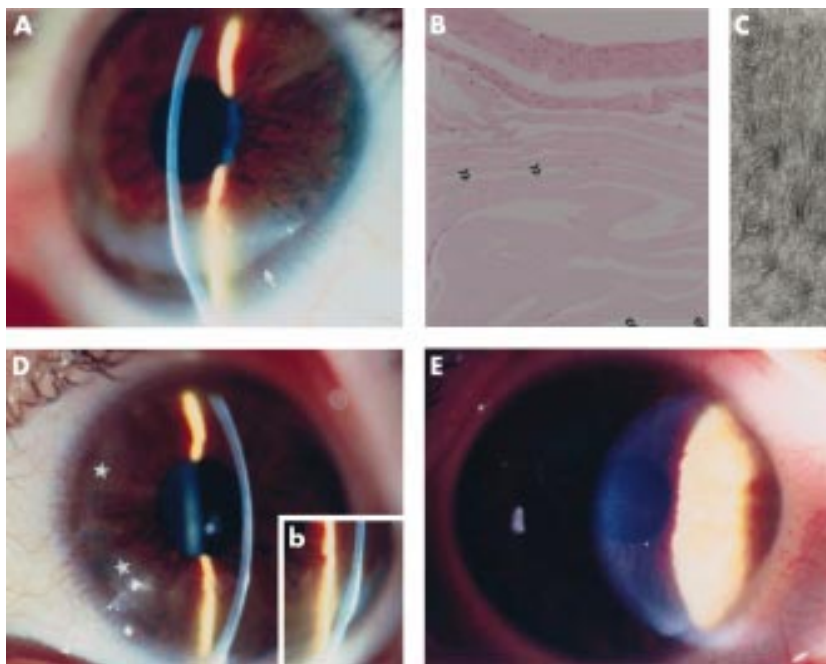


Figure 1 (A) Lower third of the left cornea showing a slightly elevated, yellowish, subepithelial and sharply demarcated opacity. Note the separation of the opacity from the limbus (arrow), attenuated by pronounced vessels. (B) Histological section of the superficial cornea, showing a diffuse hyalinosis of the stroma (zone of marked hyalinosis denoted by arrowheads; haematoxylin and eosin). (C) Electron micrograph of the removed corneal stroma showing many fibrillar structures, partly arranged in bundles, representing collagen tissue. (D) Recurrent corneal opacity with characteristic nodular lesions (b), showing an extension along the nasal limbus with the start of corneal vascularisation (asterisk). Note significant increase in limbal involvement in comparison with (A). (E) Cornea of the right eye showing a punctiform, superficial opacity in paracentral location.

keratopathy, or spheroidal degeneration of the cornea.² A literature search failed to reveal any cases of initially diagnosed hyaline degeneration of the cornea as a precursor of Salzmann's corneal degeneration. We present the first case known to us of initially diagnosed hyaline degeneration of the cornea, assumed to be a precursor of Salzmann's corneal degeneration.

Case report

A 34 year old woman was referred to our department in April 1998 with increasing opacity of the left cornea. Her medical and ophthalmological history was uneventful. The lower third of the left cornea showed a slightly elevated, yellowish, subepithelial opacity, sharply demarcated and separated from the limbus by a marked interspace (Fig 1A). The right eye was without pathological findings. The corneal opacity was removed by a scarifier both because of persistent foreign body sensation and for diagnostic purposes.

The histological examination of the removed corneal tissue revealed marked, diffuse hyalinosis of the stroma (Fig 1B), and focal degenerations of the overlying corneal epithelium. The presence of amyloid substance was excluded by Congo red staining. Electron microscopy demonstrated the described hyaline areas to represent collagenous tissue (Fig 1C). The assessment of the clinical and histological appearance of the corneal changes led to the diagnosis of hyaline degeneration of the cornea, according to the classification of Smolin and Thoft.¹

After a period of 2 years the patient presented with recurrent corneal opacity extending beyond the initial pathological area. The clinical appearance of the opacity

was markedly different, consisting of several, peripheral, subepithelial, white, slightly prominent lesions. The corresponding juxtalimbal cornea was characterised by cloudy opacification and the start of vascularisation (Fig 1D). The cornea of the right eye, which was without pathological findings 2 years earlier, now exhibited a circumscribed injection of limbal vessels as well as a punctiform, superficial opacity at a paracentral location (Fig 1E). The described findings were unchanged at the time of the most recent examination of the patient in August 2002. The clinical aspect of the left eye and the bilateral occurrence of corneal disease enabled the diagnosis of Salzmann's corneal degeneration.

Comment

The diagnosis of Salzmann's corneal degeneration is made clinically, with subepithelial, prominent corneal lesions representing the most important sign of this disease.³

We believe that the initial corneal alteration, clinically diagnosed as hyaline degeneration of the cornea, represents a precursor of Salzmann's corneal degeneration. This assumption is based on the fact that the respective histological findings already indicated the presence of this pathology.^{4–6} In the region of nodular thickening the superficial stromal tissue consists of collagen fibrils which are hyalinised and arranged in an irregular fashion in the absence of inflammatory changes or vascularisation. The corneal epithelium shows focal degenerations, while Bowman's membrane is not identified at its usual subepithelial location.

This case gives rise to the question as to whether hyaline degeneration may exist as a

separate entity. Furthermore, if hyaline degeneration of the cornea is considered to be a precursor of Salzmann's corneal degeneration, the apparently spontaneous development of this condition in this case does not conform to this description. The published cases of Salzmann's corneal degeneration are almost without exception associated with a history of chronic or recurrent keratoconjunctivitis^{3,4,7} and, less frequently, with repeated surgical trauma⁵ or corneal dystrophy.^{8,9} The spontaneous occurrence of Salzmann's corneal degeneration we report has only rarely been described.^{3,5,8} A possible explanation for this may be that two variants of Salzmann's corneal degeneration exist: a secondary variant, associated with different corneal pathologies, and a primary one. Further work is required to determine whether the aetiology of the primary variant might be related to limbal insufficiency, which eventually causes both eyes to be affected, as is suggested by the onset of clinical signs of corneal conjunctivalisation in our patient.¹⁰

M Frising, S Pitz, D Olbert

Department of Ophthalmology, Johannes Gutenberg-University, Langenbeckstrasse 1, D-55101 Mainz, Germany

J Kriegsmann

Institute of Pathology, Moltkestrasse 32, D-54292 Trier, Germany

W Lisch

Municipal Hospital Hanau, Leimenstrasse 20, D-63450 Hanau, Germany

Correspondence to: M Frising; frising@augen.klinik.uni-mainz.de

Accepted for publication 4 December 2002

References

- 1 **Smolin G.** Corneal dystrophies and degenerations. In: Smolin G, Thoft RA, eds *The cornea*. 3rd ed. Boston, New York, Toronto, London: Little, Brown, 1994:503.
- 2 **Gray RH, Johnson GJ, Freedman A.** Climatic droplet keratopathy. *Surv Ophthalmol* 1992;**36**:241–53.
- 3 **Salzmann M.** Über eine Abart der knötchenförmigen Hornhautdystrophie. *Ztschr Augenheilkd* 1925;**57**:92–9.
- 4 **Vannas A, Hogan M, Wood I.** Salzmann's nodular degeneration of the cornea. *Am J Ophthalmol* 1975;**79**:211–19.
- 5 **Muir E.** Salzmann's nodular corneal dystrophy (report of a case). *Am J Ophthalmol* 1940;**23**:138–44.
- 6 **Bischler V.** Dystrophie cornéenne nodulaire de Salzmann. *Ophthalmologica* 1946;**111**:111–19.
- 7 **Hanselmayer H.** Knötchenförmige Hornhautdystrophie nach Salzmann. *Klin Monatsbl Augenheilkd* 1968;**153**:833–7.
- 8 **Wood TO.** Salzmann's nodular degeneration. *Cornea* 1990;**9**:17–22.
- 9 **Werner Leonardo P, Issid K, Werner Liliana P, et al.** Salzmann's corneal degeneration associated with epithelial basement membrane dystrophy. *Cornea* 2000;**19**:121–3.
- 10 **Kruse FE, Völcker HE.** Die Stammzellen des Hornhautepithels am Limbus. Physiologie und Bedeutung für Hornhauterkrankungen. In: Kampik A, Grehn F, eds. *Das äussere Auge*. Stuttgart: Enke, 1996:70.

Hospital acquired aspergillus keratitis

Aspergillus fumigatus is a ubiquitous mould that rarely causes ocular pathology. Aspergillus keratitis may be seen following trauma or surgery¹ to the eye and has recently been reported following laser in situ

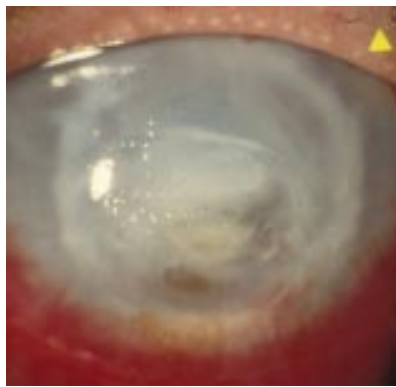


Figure 1 Corneal ulcer with hypopyon.

keratomileusis.^{2,3} Endophthalmitis is also a rare event after trauma or surgery. Endogenous aspergillus endophthalmitis is seen in patients who are immunocompromised, have endocarditis, or a history of injecting drug use. An outbreak of ocular aspergilliosis following cataract surgery has been reported in association with building a new hospital in the Middle East.⁴ We report a case of aspergillus keratitis associated with hospital construction in the United Kingdom.

Case report

A 43 year old man presented with a right sided corneal ulcer and a vision of hand movements (Fig 1). He had a past history of bilateral herpes simplex keratitis, rosacea related keratopathy, bilateral corneal grafts, and cataract surgery. The right corneal ulcer was treated with intensive topical ofloxacin and prednisolone acetate 1%. Alpha haemolytic streptococci and coagulase negative staphylococci were cultured from the corneal scrape. The central cornea thinned and a hypopyon became visible. The cornea then perforated and a bandage contact lens and glue was placed on the cornea while graft material was being obtained. A penetrating keratoplasty was performed with a 9 mm donor placed into an 8.5 mm recipient bed with interrupted sutures (Fig 2). Soon after surgery the microbiology laboratory grew *Aspergillus fumigatus* from two plates from the corneal scrape. The patient was taken back to theatre for intravitreal amphotericin B injection and topical amphotericin was commenced. The patient made an excellent recovery and has maintained a vision of 6/9 in the right eye with a refraction of $-3.25/+3.00 \times 105$.

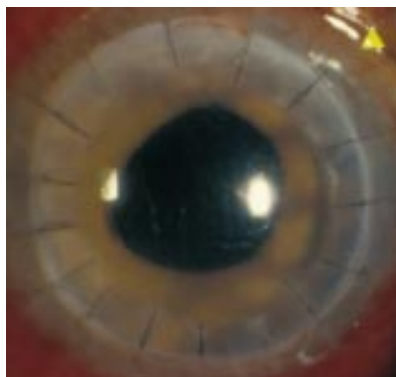


Figure 2 Corneal graft 1 month after surgery.

Comment

This patient has unfortunately had infection of the cornea with virus, bacteria, and fungus. The previous herpetic and rosacea related keratopathy resulted in his original corneal grafts and were a risk factor for the development of bacterial keratitis. Considerable demolition and construction work was taking place at the time the patient was admitted to the Royal Devon and Exeter Hospital. The old hospital tower block was being pulled down and the aspergillus infection was probably due to contamination from fungal spores released during the demolition work.

Penetrating keratoplasty is a recognised treatment for fungal keratitis,⁵ although the graft was performed for the corneal perforation and the fungal infection was only noted after the graft. We believe this is the first documented combined bacterial and fungal keratitis in the United Kingdom that may be attributed to contamination by fungal spores released by hospital demolition work.

B Burt, G Pappas, P Simcock

West of England Eye Unit, Royal Devon and Exeter Hospital, Exeter EX2 5DW, UK

Correspondence to: Peter Simcock, West of England Eye Unit, Royal Devon and Exeter Hospital, Barrack Road, Exeter EX2 5DW, UK; psimcock@hotmail.com

Accepted for publication 4 December 2002

References

- 1 **Mendicutte J, Orbegozo J, Ruiz M, et al.** Keratomycosis after cataract surgery. *J Cataract Refract Surg* 2000;**26**:1660–6.
- 2 **Kuo IC, Margolis TP, Cevallos V, et al.** Aspergillus fumigatus keratitis after laser in situ keratomileusis. *Cornea* 2001;**20**:342–4.
- 3 **Ritterband D, Kelly J, McNamara T, et al.** Delayed-onset multifocal polymicrobial keratitis after laser in situ keratomileusis. *J Cataract Refract Surg* 2002;**28**:898–9.
- 4 **Tabbara KF, Al Jabarti A.** Hospital construction-associated outbreak of ocular Aspergillus after cataract surgery. *Ophthalmology* 1998;**105**:522–6.
- 5 **Xie L, Dong X, Shi W.** Treatment of fungal keratitis by penetrating keratoplasty. *Br J Ophthalmol* 2001;**85**:1070–4.

Thyroid eye disease: an unusual presentation

Viagra (Sildenafil) is an oral preparation for the treatment of male erectile dysfunction. Although the drug is marketed solely for its therapeutic purposes, it has high potential for abuse owing to its ability to intensify and prolong erectile response. We describe here an ocular side effect following its use as a recreational drug, which led to the diagnosis of thyroid eye disease.

Case report

A 30 year old white man was referred to the eye clinic, with a history of waking up one morning with a left ptosis, having had no ocular signs or symptoms the previous day. The patient did not have any subjective symptoms of pain, redness, change in visual acuity, double vision, or of hearing any sounds. There was no history of direct or indirect trauma. He gave a history of having acquired a tablet of Viagra from a friend at a Christmas party. He ingested half and gave half to his partner. The exact dosage strength was unknown. His partner noticed increased visibility of the white of the eye under the left upper lid. He was otherwise healthy and was taking no medication.

Visual acuity was 6/5 unaided in each eye. Ocular examination showed a 3 mm axial non-pulsatile left proptosis. He was orthophoric and ocular movements were unrestricted. Anterior segment examination showed generalised conjunctival engorgement on both sides, more on the left than the right. Pupils were normally reacting and fundus examination was unremarkable. Intraocular pressure was normal with no significant difference between straight gaze and up gaze. Auscultation over the globe revealed no bruit.

The clinical findings along with the acute onset history led us to suspect superior ophthalmic vein thrombosis as a possible cause. An magnetic resonance imaging (MRI) scan was ordered with a specific request to comment on the calibre of the superior ophthalmic veins. The MRI scans showed normal superior ophthalmic veins bilaterally but thickening of all extraocular muscles, particularly the inferior recti on both sides. The inferior rectus was intensely white on T2 weighted scans. Biochemical tests for thyroid function showed him to have high T3 and T4 levels and very low TSH levels.

Comment

Sildenafil citrate has been in use since early 1998 for the treatment of male erectile dysfunction. It is a selective cyclic guanosine monophosphate dependent phosphodiesterase type 5 (PDE5) inhibitor. It potentiates the smooth muscle relaxant effect of nitric oxide and leads to engorgement of the sinusoids of the corpus cavernosa with a resultant penile erection. At the time of orgasm, emission, and ejaculation sympathomimetic substances—adrenaline (epinephrine) and noradrenaline (norepinephrine)—are released with consequent sinusoidal smooth muscle contraction and rapid loss of penile rigidity.¹

As with any new drug, clinical information and known side effects with regard to sildenafil are limited. Ocular side effects are few. Although sildenafil was developed as a selective PDE5 inhibitor, it has about 10% effect against PDE6—an enzyme localised in retinal photoreceptors. This results in various visual symptoms like a blue tinge to vision, impaired colour vision, increased light sensitivity, and blurred vision. Symptoms are transient and occur between 2–4 hours after ingestion. Results of ocular electrophysiological tests have been variable.^{2,3} A recent study showed no effect of sildenafil on mean blood pressure, intraocular pressure, perfusion pressure, or choroidal and optic nerve head blood flow,⁴ but there have been isolated reports of anterior ischaemic optic neuropathy,⁵ vascular third nerve palsy,⁶ and retinal vascular occlusions.

Lid retraction following ingestion of Viagra has not been reported before. We believe that the release of sympathomimetic substances may have produced a supranormal response in the form of noticeable lid retraction in a sensitised individual with thyroid dysfunction. We speculate, based on the close temporal relation between ingestion of this recreational drug and the presentation to our department, that Viagra therapy was responsible for the unmasking of latent thyroid eye disease in a sensitised individual.

J Shankar

Royal Liverpool University Hospital, Prescott Street, Liverpool L7 8XP, UK

C P Noonan, P Mathew, S Hanif

Warrington General Hospital, Warrington, UK

Correspondence to: Jai Shankar, Royal Liverpool University Hospital, Prescott Street, Liverpool L7 8XP, UK; jai.shankar@tesco.net

Accepted for publication 9 December 2002

References

- 1 Marmor MF, Kessler R. Sildenafil (Viagra) and ophthalmology. *Surv Ophthalmol* 1999;**123**:153–62.
- 2 Gabrieli CB, Regine F, Vingolo EM, et al. Subjective visual haloes after sildenafil: electroretinographic evaluation. *Ophthalmology* 2001;**108**:877–81.
- 3 Vobig MA, Klotz T, Staak M, et al. Retinal side effects of sildenafil (Letter). *Lancet* 1999;**353**:375.
- 4 Grunwald JE, Siu KK, Jacob SS, et al. Effect of sildenafil citrate (Viagra) on the ocular circulation. *Am J Ophthalmol* 2001;**131**:751–5.
- 5 Egan R, Pomeranz H. Sildenafil (Viagra) associated anterior ischaemic optic neuropathy. *Arch Ophthalmol* 2000;**118**:291–2.
- 6 Donahue SP, Taylor RJ. Pupil-sparing third nerve palsy associated with sildenafil citrate (Viagra). *Am J Ophthalmol* 1998;**126**:476–7.

Mooren's ulcer resolved with campath-1H

Mooren's ulcer is a rare idiopathic peripheral ulcerative keratitis. The diagnosis is usually based on characteristic clinical features and absence of other causes of peripheral keratitis. The clinical course can be unremitting, particularly in bilateral disease, occasionally leading to total loss of stroma.^{1,2}

An autoimmune process is recognised as being central to the pathogenesis.

Calgranulin-C (CaGC), produced by granulocytes and also expressed by keratocytes, appears to be the target protein for the autoimmune response that leads to Mooren's ulcer. Previous corneal trauma³ and a higher prevalence of HLA class II subtypes have been associated with Mooren's ulcer.

The disease responds to immunosuppression with variable success. Surgical treatments such as conjunctival recession have been proposed. Campath-1H is a humanised lymphocytotoxic monoclonal antibody (mAb) that targets the CD52 antigen on T lymphocytes. Successful mAb therapy using campath-1H has been reported in serious ophthalmic inflammatory conditions that were unresponsive to maximum conventional immunosuppression.^{1–5}

Case report

A 36 year old man presented to the eye department with a severe alkaline burn in both eyes. The right eye had severe stromal opacity and 360 degree limbal ischaemia, and was enucleated 2.5 years later after multiple surgical treatments. The left eye had partial epithelial loss and inferior limbal ischaemia (four clock hours), healing completely. Visual acuity was 20/30 a year after injury, when the patient developed an inferior-nasal gutter of 160 degrees with deep and superficial vascularisation, with progressive discomfort and photophobia, characteristic of Mooren's ulcer. Autoantibodies, hepatitis titres, and tests for anti-filarial serology were negative. The patient's HLA (DR) profile was DR15(2), DR17(3), DQ6(1), DQ 2. Serum anti-calgranulin C determined by western blot was not elevated.

Initial systemic and topical prednisolone with cyclosporin A failed to control the process. In spite of conjunctival recession, maximum dose triple oral immunosuppression

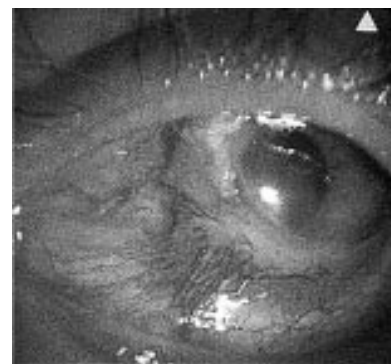


Figure 1 External photograph of the left eye before treatment with campath-1H. Note the severe injection and the glue applied nasally.

with prednisolone, cyclosporin A and mycophenolate mofetil, topical prednisolone and cyclosporin A, and oral doxycycline, the inflammation and corneal melting continued to advance. Corneal microperforations were treated with two consecutive applications of histoacrylic glue (see Fig 1).

A 5 day course of campath intravenously was then administered. After the first week, there was marked decrease of the corneal inflammation, with epithelial healing and improvement of pain and photophobia. Immunosuppression was reduced to a low dose of oral and topical prednisolone. Two months later, a minor recurrence was treated with oral mycophenolate mofetil and topical cyclosporin A. The cornea healed within a week with no further corneal inflammation and loss of stroma.

The patient had a transient anaemia, reduction in both T and B cell counts and reversal of CD4:CD8 ratio. A posterior subcapsular cataract developed, operated on 10 months after campath-1H treatment. Fourteen months later, the eye remained quiet with a stable ocular surface and corneal stroma, and visual acuity of 20/25. His immunosuppression was being tapered gradually.

Comment

In this patient with severe Mooren's ulcer standard treatments including conjunctival recession and aggressive triple immunosuppression did not control the disease. Treatment with campath-1H was successful. Although medium term tolerance appears to be excellent, long term risks of infection and malignancy are still to be determined. Campath-1H may be considered a last resort drug for use in those patients with Mooren's ulcer in whom other treatments have failed.

The authors have no commercial interests related to the products described in the article.

J van der Hoek, A Azuara-Blanco, K Greiner, J V Forrester

Department of Ophthalmology, Aberdeen Royal Infirmary, Aberdeen, UK

Correspondence to: Augusto Azuara Blanco, MD PhD, Ophthalmology Department, Aberdeen Royal Infirmary, The Eye Clinic, Foresterhill, Aberdeen AB25 2ZN, UK; aazblanco@aol.com

Accepted for publication 13 December 2002

References

- 1 Watson PG. Management of Mooren's ulceration. *Eye* 1997;**11**:349–56.

- 2 **Gottsch JD**, Liu SH, Minkovitz JB, *et al.* Autoimmunity to a cornea-associated stromal antigen in patients with Mooren's ulcer. *Invest Ophthalmol Vis Sci* 1995;**36**:1541-7.
- 3 **Taylor CJ**, Smith SI, Morgan CH, *et al.* HLA and Mooren's ulceration. *Br J Ophthalmol* 2000;**84**:72-5.
- 4 **Newman DK**, Isaacs JD, Watson PG, *et al.* Prevention of immune-mediated corneal graft destruction with the anti-lymphocyte monoclonal antibody, Campath-1H. *Eye* 1995;**9**:564-9.
- 5 **Dick AD**, Meyer P, James T. Campath-1H therapy in refractory ocular inflammatory disease. *Br J Ophthalmol* 2000;**84**:107-9.

Does etanercept induce uveitis?

Etanercept (Enbrel) is a fusion protein of the extracellular ligand binding portion of the human tumour necrosis factor (TNF) receptor p75 and the Fc portion of human IgG1. This agent inhibits the action of both TNF α and TNF γ (important pro-inflammatory cytokines). It is being increasingly used in the management of rheumatoid arthritis, psoriatic arthritis, and ankylosing spondylitis with a good outcome in both open label and randomised controlled trials.¹⁻³ Potentially serious but uncommon adverse effects of sepsis, reactivation of tuberculosis, worsening of congestive cardiac failure, exacerbation of multiple sclerosis, and reports of less serious skin reactions, lymphoma, autoantibodies have been published.⁴ Isolated case reports of the development of rheumatoid nodules and leucocytoclastic vasculitis with etanercept also exist.⁵⁻⁶ We report a case of uveitis following etanercept treatment for ankylosing spondylitis.

Case report

A 44 year old HLA B27+ve woman taking methotrexate (15 mg weekly) and phenylbutazone for resistant ankylosing spondylitis of 23 years' duration developed worsening of arthritic symptoms. She had never suffered from uveitis in the past. She was started on a 6 month trial of Enbrel (Immunex Corporation, Seattle, WA, USA) 25 mg subcutaneous injections twice a week. Three weeks later she presented with anterior non-granulomatous uveitis in the right eye, which settled in about 8 weeks with intensive topical steroids. Her arthritic symptoms showed a very good response to Enbrel. A severe flare up of joint disease 8 weeks after stopping the treatment necessitated restarting Enbrel. Three weeks later she presented with severe bilateral anterior non-granulomatous uveitis. Oral prednisolone was needed to control the uveitis. Enbrel was stopped and the uveitis resolved. A complicated cataract developed a few months later and was successfully treated with IOL implantation. Cystoid macular oedema in the operated eye has left her with a vision of 6/18.

Comment

The close temporal association of the start of Enbrel treatment and the onset of uveitis and "challenge-rechallenge" scenario observed in this patient's uveitis suggests that Enbrel provoked anterior uveitis in this patient. Exacerbation of endotoxin induced uveitis with systemic antitumour necrosis factor antibody treatment has been demonstrated in rats.⁷ In a study of the efficacy of etanercept for treatment resistant juvenile idiopathic arthritic uveitis in 14 children, the uveitis got worse in one child.⁸ Smith *et al* in a retrospective analysis reported three cases of bilateral scleritis and one case of uveitis in patients with rheumatoid arthritis and one case of uveitis in a

patient with psoriatic spondyloarthropathy after the initiation of etanercept therapy. Interestingly, the articular symptoms improved in all of these five patients.⁹

Peripheral TNF α blockade by these drugs leading to an increase the population of autoreactive T cells that may be myelin specific is the proposed mechanism of exacerbation of multiple sclerosis in some patients.¹⁰ A similar pathogenesis may explain the uveitis noted here. Recent research demonstrates unique cell adhesion molecules and cytokine profiles in autoimmune inflammation occurring in different sites in the body.¹¹

This case report aims to create an awareness of the possibility of exacerbation of uveitis and may warrant us to specifically look out for uveitis in patients receiving anti-TNF α therapy.

A R Reddy, O C Backhouse
Leeds General Infirmary, Leeds, UK

Correspondence to: Aravind R Reddy, Leeds General Infirmary, Leeds, UK; aravind_1971@yahoo.com

Accepted for publication 13 December 2002

References

- 1 **Braun J**, Sieper J, *et al.* Anti-TNF α therapy for ankylosing spondylitis: international experience. *Ann Rheum Dis* 2002;**61**(Suppl):51-60.
- 2 **Moreland LW**, Schiff MH, Baumgartner SW, *et al.* Etanercept therapy in rheumatoid arthritis. A randomised controlled trial. *Ann Intern Med* 1999;**130**:478-86.
- 3 **Gorman JD**, Sack KE, Davis JC Jr. Treatment of ankylosing spondylitis by inhibition of tumor necrosis factor alpha. *N Engl J Med* 2002;**346**:1349-56.
- 4 **Fleischmann R**, Iqbal I, Nandeshwar P, *et al.* Safety and efficacy of disease-modifying anti-rheumatic agents: focus on the benefits and risks of etanercept. *Drug Safety* 2002;**25**:173-97.
- 5 **Kekow J**, Welle T, Kellner U, *et al.* Development of rheumatoid nodules during anti-TNF α therapy with etanercept. *Arthritis Rheum* 2002;**46**:843-4.
- 6 **Galaria NA**, Werth VP, Schumacher HR. Leukocytoclastic vasculitis due to etanercept. *J Rheumatol* 2000;**27**:2041-4.
- 7 **De Vos AF**, Van Haren MAC, Verhagen C, *et al.* Systemic anti-tumour necrosis factor antibody treatment exacerbates endotoxin-induced uveitis in the rat. *Exp Eye Res* 1995;**61**:667-75.
- 8 **Reiff A**, Takei S, Sadeghi S, *et al.* Etanercept therapy in children with treatment-resistant uveitis. *Arthritis Rheum* 2001;**44**:1411-5.
- 9 **Smith JR**, Levinson RD, Holland GN, *et al.* Differential efficacy of tumour necrosis factor inhibition in the management of inflammatory eye disease and associated rheumatic disease. *Arthritis Care Res* 2001;**45**:252-7.
- 10 **Cope A**, Ettinger R, *et al.* The role of TNF α and related cytokines in the development and function of the autoreactive T-cell repertoire. *Res Immunol* 1997;**148**:307-12.
- 11 **Von Andrian UH**, Mackay CR. T-cell function and migration: two sides of the same coin. *N Engl J Med* 2000;**343**:1020-34.

Photodynamic therapy: a treatment option in choroidal neovascularisation secondary to punctate inner choroidopathy

Punctate inner choroidopathy is an idiopathic inflammatory ocular disorder characteristically seen in young myopic women. Visual prognosis is generally good but sight threatening choroidal neovascularisation may develop in up to 40% patients.¹ We discuss verteporfin photodynamic therapy in subfoveal

choroidal neovascularisation secondary to punctate inner choroidopathy that failed to respond to oral corticosteroids and had poor results with submacular surgery in the contralateral eye.

Case report

A 40 year old white female patient with punctate inner choroidopathy was referred to our macular clinic with rapidly deteriorating vision in her left eye secondary to a subfoveal choroidal neovascularisation. She had a history of poor vision in the right eye following submacular surgery to remove a subfoveal choroidal neovascular membrane. Best corrected vision was hand movements in the right eye and 6/18 in the left eye. The logMAR acuity in the left eye was 0.46 (38 letters misread). The anterior segments and intraocular pressures were normal. Both fundi showed characteristic multiple pigmented atrophic scars in the posterior pole and mid-periphery in the absence of vitreous cells. There was a macular scar in the right eye (Fig 1). In the left eye there was an elevated grey lesion with subretinal fluid and intraretinal haemorrhages (Fig 2A). Fluorescein angiography confirmed a predominantly classic subfoveal choroidal neovascular membrane (Fig 2B and C). Argon laser photocoagulation was contraindicated because of the subfoveal location. Despite a 4 week course of oral prednisolone (40 mg a day for 1 week then reduced by 10 mg every week) the vision in the patient's only useful eye continued to worsen. The patient refused submacular surgery because of the poor postoperative result in her right eye. Photodynamic therapy was offered as a treatment option.

After obtaining informed consent we performed five sessions of photodynamic therapy at 3 monthly intervals according to a standard protocol. Baseline and 3 monthly post-treatment logMAR visual acuities were recorded and clinical and angiographic assessment was performed. After 15 months the Snellen acuity in her left eye has stabilised at 6/18 and her logMAR acuity is 0.2 (25 letters misread). She has gained eight letters on the logMAR chart and subjectively there is less distortion. Clinically, there is resolution of the subretinal fluid and intraretinal haemorrhages and formation of a flat scar-like lesion (Fig 3A). Angiographically, despite some early leakage, the findings are consistent with reduced activity and fibrosis of the choroidal neovascularisation (Fig 3B and C). An indocyanine green angiography confirmed the

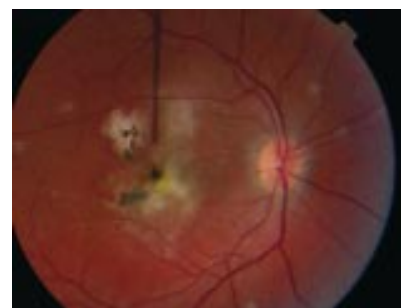

Figure 1 Right eye. The photograph shows the large central macular scar with retinal pigment hypertrophy and atrophy following surgical removal of a choroidal neovascularisation. Smaller circumscribed pigmented atrophic scars characteristic of punctate inner choroidopathy are seen in the mid-periphery.

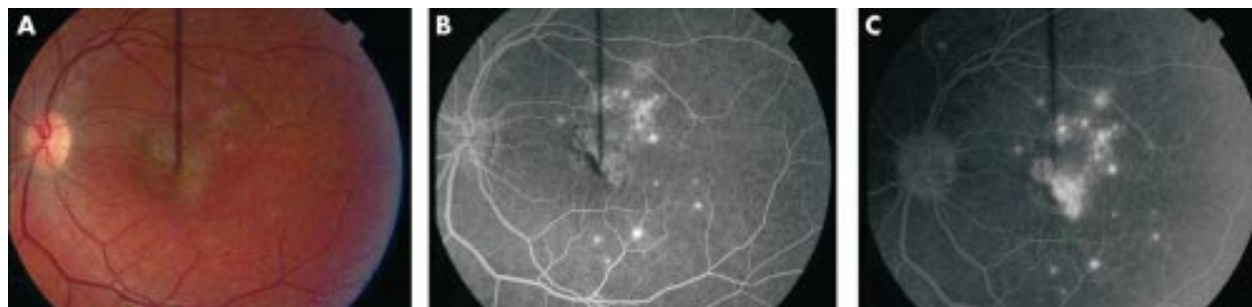

Figure 2 Left eye at presentation. (A) The colour photograph shows a grey elevated subfoveal lesion associated with intraretinal haemorrhages and subretinal fluid and surrounding smaller atrophic pigmented lesions characteristic of punctate inner choroidopathy. (B) The arteriovenous phase of the fluorescein angiogram at 28.2 seconds shows a hyperfluorescent subfoveal choroidal neovascularisation with a typical lacy pattern and smaller punctate hyperfluorescent lesions of punctate inner choroidopathy. The area of blocked fluorescence is consistent with the intraretinal haemorrhage. (C) The late arteriovenous phase of the fluorescein angiogram at 2.09 minutes shows increased hyperfluorescence and active leakage of dye from the subfoveal choroidal neovascularisation.

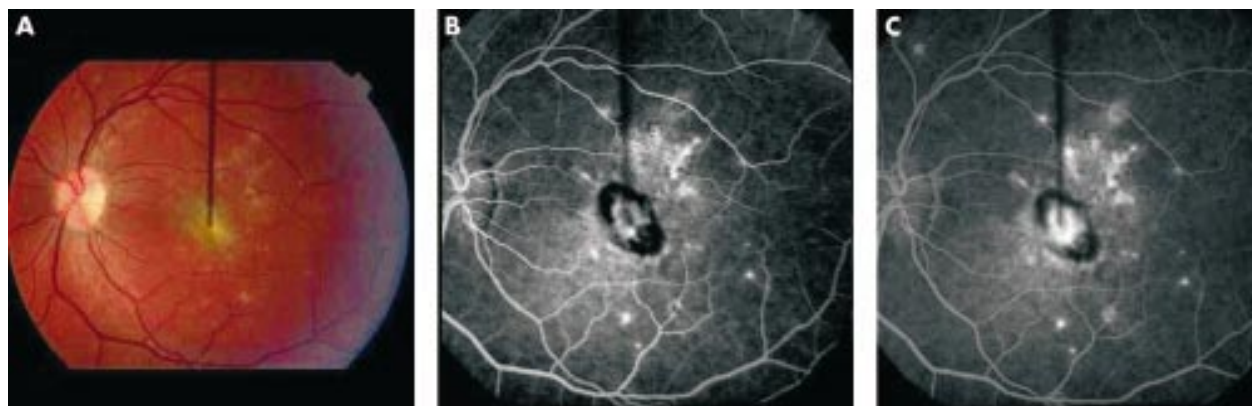


Figure 3 Left eye after five verteporfin photodynamic sessions. (A) The colour photograph shows a flat subfoveal scar-like lesion with resolution of subretinal fluid and intraretinal haemorrhages. (B) The arteriovenous phase of the fluorescein angiogram at 21 seconds shows some early hyperfluorescence with reduced activity and size of the lesion. (C) The late arteriovenous phase of the fluorescein angiogram at 1.05 minute shows mainly staining of fibrosis and no active leakage.

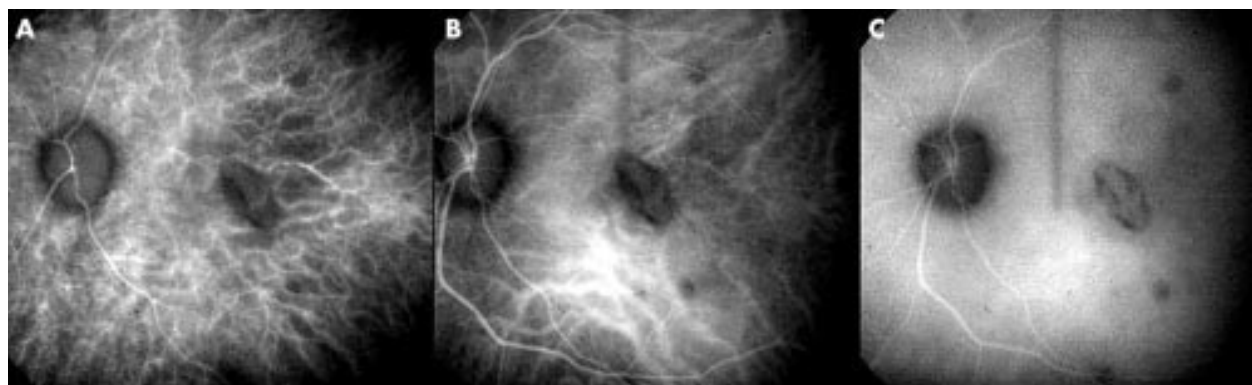


Figure 4 (A–C) Indocyanine green angiography of the left eye after five verteporfin photodynamic sessions at 11 seconds, 55.2 seconds, and 9.35 minutes showing no active choroidal neovascularisation and no feeder vessels.

findings of the fluorescein angiography and excluded the presence of choroidal feeder vessels that could lead to a recurrence of the neovascularisation (Fig 4).

Comment

Punctate inner choroidopathy is an idiopathic inflammatory disorder that usually occurs in young, myopic women.² Both eyes are commonly affected. Symptoms include blurred or distorted vision, light flashes, or paracentral scotomas.² The acute, multiple, yellow-white lesions of the inner choroid and retina of the posterior pole evolve into atrophic pigmented

scars.² Vitritis and anterior uveitis are absent.² Visual prognosis is good in most patients and significant visual loss is usually due to formation of choroidal neovascularisation.¹ Choroidal neovascularisation if smaller than 100 μm in diameter may resolve spontaneously.¹ However, subfoveal choroidal neovascularisation occurs in 40% of the patients.¹ Argon laser photocoagulation is contraindicated for subfoveal lesions.¹ Although good results have been reported with 1 mg/kg per day of oral prednisolone,³ the response to oral steroids is variable if more than 200 μm in diameter.¹ Submacular sur-

gery has shown promising results but recurrence is common.⁴

Photodynamic therapy using verteporfin is safe and effective for subfoveal choroidal neovascularisation in age related macular degeneration and high myopia.^{5,6} The verteporfin guidelines suggested photodynamic therapy for other aetiologies if outcome without treatment was likely to be poor.⁷ Preliminary success in ocular histoplasmosis syndrome, angioid streaks, idiopathic and other conditions has been reported.^{8–15} The recommended protocol for treatment included clinical and

angiographic review every 3 months.^{5,7} Retreatment was indicated if there was any fluorescein leakage from the choroidal neovascularisation.^{5,7} Retreatment was deferred if the visual acuity remained stable or improved and the lesion fulfilled all the following criteria: (1) minimal or no subretinal fluid on biomicroscopic examination; (2) flat scar-like appearance; (3) minimal fluorescein leakage without progression beyond the boundaries of the previous treatment or involvement of the fovea.

Photodynamic therapy in this case of subfoveal choroidal neovascularisation secondary to punctate inner choroidopathy was indicated after a poor surgical result in the first eye and the deterioration of vision in the fellow eye despite oral corticosteroid treatment. Five treatment sessions over 15 months produced subjective and visual (logMAR) improvement. Clinically there was resolution of intraretinal haemorrhages and subretinal fluid with formation of a flat scar-like lesion. The angiogram confirmed a stable lesion with minimal fluorescein leakage, no progression beyond the boundaries of the previous treatment and staining of the scar tissue. This case demonstrates that verteporfin photodynamic therapy may be a useful treatment option in choroidal neovascularisation due to punctate inner choroidopathy. Further studies are needed to confirm and support this observation.

S Chatterjee, J M Gibson

Birmingham and Midland Eye Centre, City Hospital
NHS Trust, Birmingham B3 2NS

Correspondence to: Dr Jonathan Gibson;
doctorjmg@hotmail.com

Accepted for publication 2 December 2002

References

- Brown J Jr**, Folk JC, Reddy CV, *et al*. Visual prognosis of multifocal choroiditis, punctate inner choroidopathy, and the diffuse subretinal fibrosis syndrome. *Ophthalmology* 1996;**103**:1100–5.
- Gass JDM**. In: *Stereoscopic atlas of macular disease diagnosis and treatment*. Vol 2. St Louis: Mosby 1997:692–3.
- Flaxel CJ**, Owens SL, Mulholland B, *et al*. The use of corticosteroids for choroidal neovascularisation in young patients. *Eye* 1998;**12**(Pt 2):266–72.
- Olsen TW**, Capone A Jr, Sternberg P Jr, *et al*. Subfoveal choroidal neovascularization in punctate inner choroidopathy. Surgical management and pathologic findings. *Ophthalmology* 1996;**103**:2061–9.
- Bressler NM**. Photodynamic therapy of subfoveal choroidal neovascularization in age-related macular degeneration with verteporfin: two-year results of 2 randomized clinical trials-TAP report 2. *Arch Ophthalmol* 2001;**119**:198–207.
- Verteporfin in Photodynamic Therapy Study Group**. Photodynamic therapy of subfoveal choroidal neovascularization in pathologic myopia with verteporfin. 1-year results of a randomized clinical trial—VIP report no 1. *Ophthalmology* 2001;**108**:841–52.
- Anon**. Guidelines for using verteporfin (Visudyne) in photodynamic therapy to treat choroidal neovascularization due to age-related macular degeneration and other causes. *Retina* 2002;**22**:6–18.
- Sickenberg M**, Schmidt-Erfurth U, Miller JW, *et al*. A preliminary study of photodynamic therapy using verteporfin for choroidal neovascularization in pathologic myopia, ocular histoplasmosis syndrome, angioid streaks, and idiopathic causes. *Arch Ophthalmol* 2000;**118**:327–36.
- Karacorlu M**, Karacorlu S, Ozdemir H, *et al*. Photodynamic therapy with verteporfin for choroidal neovascularization in patients with angioid streaks(1). *Am J Ophthalmol* 2002;**134**:360.
- Saperstein DA**, Rosenfeld PJ, Bressler NM, *et al*. Verteporfin in Ocular Histoplasmosis (VOH) Study Group. Photodynamic therapy of subfoveal choroidal neovascularization with verteporfin in the ocular histoplasmosis syndrome: one-year results of an uncontrolled, prospective case series. *Ophthalmology* 2002;**109**:1499–505.
- Spaide RF**, Martin ML, Slakter J, *et al*. Treatment of idiopathic subfoveal choroidal neovascular lesions using photodynamic therapy with verteporfin. *Am J Ophthalmol* 2002;**134**:62–8.
- Dantas MA**, Slakter JS, Negrao S, *et al*. Photodynamic therapy with verteporfin in mulleria leventinense. *Ophthalmology* 2002;**109**:296–301.
- Valmaggia C**, Niederberger H, Helbig H. Photodynamic therapy for choroidal neovascularization in fundus flavimaculatus. *Retina* 2002;**22**:111–13.
- Potter MJ**, Szabo SM, Chan EY, *et al*. Photodynamic therapy of a subretinal neovascular membrane in type 2A idiopathic juxtafoveal retinal telangiectasis. *Am J Ophthalmol* 2002;**133**:149–51.
- Battaglia Parodi M**, Da Pozzo S, Toto L, *et al*. Photodynamic therapy for choroidal neovascularization associated with choroidal osteoma. *Retina* 2001;**21**:660–1.

MAILBOX

If you have a burning desire to respond to a paper published in the *BJO*, why not make use of our "rapid response" option? Log on to our website (www.bjophthalmol.com), find the paper that interests you, and send your response via email by clicking on the "eLetters" option in the box at the top right hand corner.

Providing it isn't libellous or obscene, it will be posted within seven days. You can retrieve it by clicking on "read eLetters" on our homepage.

The editors will decide as before whether to also publish it in a future paper issue.

Non-invasive volumetric blood flow measurement in the orbit

We read with great interest the article of Orge and co-workers¹ who claim a first ever solution to the problem of non-invasive volumetric blood flow measurement in the ophthalmic artery. This is a very important topic both from the clinical and scientific point of view, since blood supply is an important factor, for example, in glaucoma studies. However, to date for the orbital circulation only the blood velocity has been measurable; from this the resistivity indices can be calculated, but the volumetric flow cannot be determined because the small diameter of the orbital vessels does not allow the vessel diameter measurement, which is indispensable for such calculation.

In spite of the novelty of the report and the extensive analysis of the authors on the possible sources of high variability of volumetric flow measurements, it appears to us that there are several points which need further consideration; some of these were analysed in the editorial by Hedges,² but we would like to highlight two additional questions.

For us, a weak point of the study protocol of Orge and colleagues is their method for the

determination of the diameter of the ophthalmic artery. They assume the boundaries of the vessel to be where detected movement starts and ends along the m-mode line; or in other words the vessel boundaries are taken to be the positions where the grey pixels and colour pixels touch on this Doppler image. However, we are doubtful whether this definition is relevant for the required quantitative measurement. The first point is that for small vessels the width of the colour area (indicating blood motion) is unfortunately relatively independent of the true vessel diameter. The width of the superimposed colour area is greatly influenced by the actual technical parameters used in colour Doppler imaging (pulse repetition frequency, lateral dimension of the ultrasound beam, colour priority, motion discriminator setting, colour saturation, brightness, contrast, etc). Our second doubt is that, even on the grey scale part of the image shown by Orge *et al* in their Figure 1, no vessel wall is seen, unlike the case for typical images of large vessels like the carotid arteries.

We think that because of these difficulties regarding the determination of the vessel wall position, Orge and co-workers overestimate the ophthalmic artery diameter. Their diameter estimate is 2.02 mm on average; but this figure is significantly larger than is suggested by other evidence. During conventional 10 MHz B-scan diagnostic examination, the ophthalmic artery is never visible. However for the dilated ophthalmic vein, in exceptional cases such as in a patient with carotidocavernous sinus fistula, or in a small baby in a bout of strenuous crying, the vein is then well outlined with a diameter of 1 mm or above. Thus, we would expect a 2 mm diameter artery to be clearly visible. As we demonstrated some years ago,^{3,4} patients with a pathologically dilated ophthalmic vein are good candidates for non-invasive volumetric blood flow measurement. We were able to measure volumetric blood flow in the orbit of patients with a high flow fistula (vein diameter around 3–4 mm) using the CVI-Q technique (Fig 1). Possibly future improvements in spatial resolution may resolve this difficulty.

In a vessel like the ophthalmic artery there is a further problem in determination of the average velocity, because the laminar flow in such small vessels causes a very wide velocity variation within the lumen, as can be seen from our Figure 1. In contrast, we note that the colour spectrum in the figure presented by the authors is almost completely uniform and does not show higher speed in the centre of the lumen compared to that close to the vessel wall. This might imply a relative insensitivity of velocity discrimination within a small vessel lumen, which in addition may be of irregular cross sectional shape (that is, not circular) but is only measured in one longitudinal plane. We agree with the authors that the analysis software is of great importance and may be a key factor in dealing with this complex situation. In spite of our reservations we, and many other workers concerned with orbital circulation, are in urgent need of a reliable solution for volumetric blood flow determination in the orbit. The results of Orge and co-workers show that we are probably not far from a definitive solution.

Acknowledgement

Supported by the Hungarian Scientific Research Fund (OTKA T 034483).

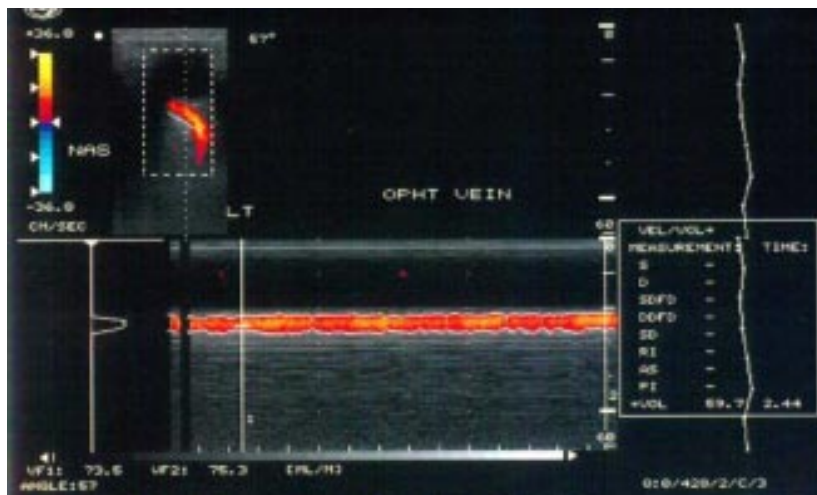


Figure 1. CVI flowmetry of the dilated superior ophthalmic vein in a 70 year old patient with direct carotidcavernosus sinus fistula. In the upper left image the thin white line indicates the sonic beam-flow angle, for volume-flow calculation. The functional lumen of the vessel is displayed in the left side of the M-mode image. Note the variation in the colour according to the arterialisiation of the circulation and the higher flow velocity in the centre of the vessel than close to the wall of the vessel. The average calculated flow volume was 59.7 ml/min.

J Németh

1st Department of Ophthalmology, Semmelweis University, Budapest, Hungary

Z Harkányi, F Humml

Department of Radiology, Heim Pal Children Hospital, Budapest, Hungary

Correspondence to: Dr János Németh, 1st Department of Ophthalmology, Semmelweis University, Tömö u 25-29, H-1083, Budapest, Hungary; nj@szem1.sote.hu

References

- 1 Orge F, Harris A, Kagemann L, *et al.* The first technique for non-invasive measurements of volumetric ophthalmic artery blood flow in humans. *Br J Ophthalmol* 2002;**86**:1216-9.
- 2 Hedges TR. Ophthalmic artery blood flow in humans. The tortuosity and the variable course of the ophthalmic artery remain a problem. *Br J Ophthalmol* 2002;**86**:1197.
- 3 Németh J, Harkányi Z. Color Doppler and color velocity imaging of the orbital vessels. In: Süveges I, Follmann P, eds. *XIth Congress of the European Society of Ophthalmology*. Bologna: Monduzzi, 1997:593-6.
- 4 Németh J, Süveges I, Harkányi Z. Color velocity imaging of orbital blood circulation. In: Hasenfratz G, ed. *Ultrasound in ophthalmology. Proceedings of the 16th SIDUO Congress Munich, Germany 1996*. Regensburg: Roderer Verlag, 2000:31-3.

“Compliance” with treatment in amblyopia is an important factor affecting the final visual outcome

We discussed the article by Cobb *et al*¹ with great interest in our journal club meeting. We would like to highlight some of the issues we discussed.

Evidence in the literature^{2,3} suggests anisometropia is a difference of 1 DS between both eyes but the authors use a difference of 2 DS. Also the minimum criteria for diagnosing amblyopia on a test of visual acuity are accepted to be two lines difference between the eyes on linear tests. However, the authors use these criteria for the single optotype test and do not take into account the crowding effect. A two line difference on Sheridan Gardiner may actually equate to a three line

difference on a linear test.³ The Royal College of Ophthalmologists³ also state that on repeated testing a difference of one line can also be included—that is, 6/9 6/6. Therefore a one line difference on Sheridan Gardiner may actually fulfil the linear criteria.

The authors stated that part time occlusion was the method of treatment. Part time occlusion can vary from as much as 6 hours to 10 minutes yet the authors did not state the amount of occlusion to the level of vision. Methods of occlusion have varied greatly between 1972 and 1995, so were the guidelines for occlusion treatment the same throughout the study period?

Furthermore, “compliance” with treatment is recognised as an important factor affecting the final visual outcome in amblyopia³ and that compliance varies with age.⁴ The authors have not analysed if compliance varied significantly with age of presentation.

It has been shown that anisometropic amblyopes can have improvement in vision after a period of spectacle correction and refractive adaptation is considered an important component of amblyopia treatment.⁵ The authors did not state if occlusion was started at the first, second, or third visit after spectacle correction. We do not know if treatment had been initiated prematurely and resulted in falsely increased occlusion dose, thereby giving poorer compliance. This could have skewed the figures. So, we recommend exercising caution in interpreting the results and in concluding that time at which screening is carried out, not critical in this group.

P R Sankari, V Henshall, K O'Regan

Royal Albert Edward Infirmary, Christopher Home, Wigan Lane, Wigan WN1 2NN, UK

Correspondence to: Mrs Perumal Sankari, Royal Albert Edward Infirmary, Christopher Home, Wigan Lane, Wigan WN1 2NN, UK; beepsrs@yahoo.co.uk

References

- 1 Cobb CJ, Russell K, Cox A, *et al.* Factors influencing visual outcome in anisometropic amblyopes. *Br J Ophthalmol* 2002;**86**:1278-81.
- 2 Ansons AM, Davies H. Amblyopia. In: *Diagnosis and management of ocular motility disorders*. 3rd ed. Oxford: Blackwell Science, 2001:214.

3 <http://www.rcophth.ac.uk/publications/guidelines/strabismus.html#ambly>

4 Nucci P, Alfarano R, Piantanida A, *et al.* Compliance in antiamblyopia occlusion therapy. *Acta Ophthalmol Copenh* 1992;**70**:128-31.

5 Stewart CE, Fielder AR, Stephens DA, *et al.* Design of the Monitored Occlusion Treatment of Amblyopia Study (MOTAS). *Br J Ophthalmol* 2002;**86**:915-19.

Authors' reply

We thank Sankari and colleagues for their helpful and interesting comments regarding our paper. We accept that the literature suggests a difference of 1 D as a definition of anisometropia but felt the stringent definition we applied would more accurately represent a degree of anisometropia that could potentially lead to amblyopia, and therefore makes the findings more robust. The average age of the cohort was 5½ years and as such the majority of tests were linear. Pure anisometropic amblyopia does not tend to cause as significant crowding as strabismic. We therefore felt that it was not necessary to equate one line of difference with Sheridan Gardiner to a two or three line difference on a linear test. Occlusion regimes and compliance are always problematic especially in retrospective studies.¹ All parents of children were given the same advice and support regarding therapy and the outcomes, therefore the findings of our study reflect a real clinical situation. Compliance does vary with age as shown by Nucci *et al.*,² but this was significant only in the 1-2 year old age group. There were no children of this age in our study. More importantly, the effect of occlusion is inversely related to age, so the younger the child the more rapid the response. Most children were commenced on occlusion at their first visit after refractive correction, which was within 2 months of receiving glasses. We agree that anisometropic amblyopes may have a continuing improvement in their vision with just spectacle correction for some months.³ Depending on the response to spectacle correction, this department will now delay occlusion for up to 4 months. To suggest that initiating occlusion earlier than may have been necessary would result in a worse outcome because of poor compliance must be considered speculative. In any case, failure to comply with occlusion would result in the now recommended treatment—that of spectacle correction alone. While there may be some debate as to the efficacy of occlusion therapy,⁴ there is currently no evidence that it is detrimental to the final visual acuity achieved in anisometropes.

C J Cobb, K Russell, A Cox, C J MacEwen

Department of Ophthalmology, Ninewells Hospital, Dundee DD1 9SY, UK

Correspondence to: Dr Alan Cox, Department of Ophthalmology, Ninewells Hospital, Dundee DD1 9SY, UK; alan.cox@iuhnt.scot.nhs.uk

References

- 1 Fielder AR, Irwin M, Auld R, *et al.* Compliance in amblyopia therapy: objective monitoring of occlusion. *Br J Ophthalmol* 1995;**79**:585-9.
- 2 Nucci P, Alfarano R, Piantanida A, *et al.* Compliance in antiamblyopia occlusion therapy. *Acta Ophthalmol Copenh* 1992;**70**:128-31.
- 3 Stewart CE, Fielder AR, Stephens DA, *et al.* Design of the Monitored Occlusion Treatment of Amblyopia Study (MOTAS). *Br J Ophthalmol* 2002;**86**:915-19.
- 4 Snowdon SK, Stewart-Brown SL. *Preschool vision screening: results of a systematic review*. York: NHS Centre for Reviews, 1997 (CRD Report 9).

Can a cilio-retinal artery influence diabetic retinopathy?

Knudsen and Lervang published an interesting article in the *BJO* recently.¹ The authors concluded that a cilio-retinal artery tends to worsen diabetic maculopathy but I believe there is an alternative interpretation of the data provided. The authors mentioned that 26/29 patients had a cilio-retinal artery in the eye with worse maculopathy, which was a statistically significant result. In the results section the authors did not report whether a unilateral cilio-retinal artery was present in the 75 subjects with identical maculopathy in the right and left eyes but they stated that this was true in all 75 subjects in the first sentence of the discussion. Therefore, in 75 patients the cilio-retinal artery had not caused worsening of the maculopathy compared to the contralateral eye. Taken together with the 29 subjects with asymmetrical maculopathy, the proportion of subjects in whom the unilateral cilio-retinal artery did not worsen maculopathy would be $(75 + 3)/104$ or 0.75 (95% CI 0.654 to 0.827). The proportion of cases in whom maculopathy was *not* worsened by a cilio-retinal artery was therefore significantly more than 50%.

Table 1 The relation between the presence of a cilio-retinal artery and clinically significant macular oedema (CSMO)

	No CSMO	CSMO	Total
No cilio-retinal artery	324	38	362
Cilio-retinal artery	106	13	119
Total	430	51	481

The authors also reported that 51 eyes had clinically significant macular oedema (CSMO), in the group of 94 subjects with maculopathy. However, the χ^2 analysis should not have been performed using each eye as a case ($n=962$), as it is well known that the right and left eyes of each patient are not independent (that is, if the right eye has maculopathy, the left eye has a greater chance of having maculopathy than the contralateral eye of a non-affected eye in another patient). One possible approach would be to look at all the right eyes only or to randomly look at one of the two eyes of each subject and reduce n to 481. The reader of this article will not know the outcome of this analysis without more information from the authors; however,

assuming all the 51 eyes with CSMO were from different subjects, the 2×2 table may look like Table 1. This table assumes that all the 104 eyes with unilateral cilio-retinal artery and the 15 eyes from bilateral cilio-retinal cases are included, making a total of 119 subjects with cilio-retinal arteries for analysis. In the above case clearly the result is not statistically significant ($\chi^2 = 0.017$; $p > 0.9$).

L Tong

Singapore National Eye Centre, 11, 3rd Hospital Avenue, Singapore 168751; Louistong@hotmail.com

Reference

- 1 Knudsen LL, Lervang HH. Can a cilio-retinal artery influence diabetic maculopathy? *Br J Ophthalmol* 2002;**86**:1252–5.



Photodynamic therapy: a treatment option in choroidal neovascularisation secondary to punctate inner choroidopathy

S Chatterjee and J M Gibson

Br J Ophthalmol 2003 87: 925-927

doi: 10.1136/bjo.87.7.925-a

Updated information and services can be found at:

<http://bjo.bmj.com/content/87/7/925.2.full.html>

These include:

References

This article cites 14 articles, 2 of which can be accessed free at:

<http://bjo.bmj.com/content/87/7/925.2.full.html#ref-list-1>

Article cited in:

<http://bjo.bmj.com/content/87/7/925.2.full.html#related-urls>

Email alerting service

Receive free email alerts when new articles cite this article. Sign up in the box at the top right corner of the online article.

Notes

To request permissions go to:

<http://group.bmj.com/group/rights-licensing/permissions>

To order reprints go to:

<http://journals.bmj.com/cgi/reprintform>

To subscribe to BMJ go to:

<http://group.bmj.com/subscribe/>