

## EXTENDED REPORT

## Pars plana vitrectomy assisted by triamcinolone acetonide for refractory uveitis: a case series study

K-H Sonoda, H Enaida, A Ueno, T Nakamura, Y-I Kawano, T Kubota, T Sakamoto, T Ishibashi

*Br J Ophthalmol* 2003;**87**:1010-1014

See end of article for authors' affiliations

Correspondence to:  
Koh-Hei Sonoda, MD, PhD,  
Department of  
Ophthalmology, Graduate  
School of Medical  
Sciences, Kyushu  
University, 3-1-1 Maidashi,  
Higashi-Ku, Fukuoka,  
812-8582, Japan;  
[sonodak@med.kyushu-u.ac.jp](mailto:sonodak@med.kyushu-u.ac.jp)

Accepted for publication  
11 December 2002

**Aim:** To examine the outcome of a triamcinolone acetonide (TA) assisted pars plana vitrectomy (PPV) for refractory uveitis.

**Methods:** Six patients suffering from proliferative vitreoretinopathy (PVR) with refractory uveitis underwent a TA assisted PPV. The patients consisted of one with Vogt-Koyanagi-Harada disease, one with acute retinal necrosis, one with Behçet's disease, and three with sarcoidosis. TA was inoculated into the vitreous cavity to visualise the vitreous. In four of six patients, 4 mg of TA were intentionally left in the vitreous cavity to reduce the degree of postoperative inflammation.

**Results:** The vitreous body was clearly seen using TA during surgery, which greatly helped us to perform a posterior hyaloid resection safely and thoroughly. As we previously observed in other disease, TA allowed us to visualise the transparent vitreous and thus was helpful in removing the vitreous cortex from the retina completely in uveitis. One patient (Behçet's disease, in whom TA was intentionally left) showed an elevated intraocular pressure (IOP) transiently after surgery which was controllable by topical eye drops. The remaining TA diminished day by day and had almost completely disappeared within a month from operation.

**Conclusion:** TA improved the visibility of the hyaloid and the safety of the surgical procedures and no serious complications were observed after TA assisted PPV in uveitis. Although the long term effects are still unknown, this method appears to be potentially useful as an improved treatment for PVR associated with refractory uveitis.

In some types of refractory drug uncontrollable uveitis, inflammatory cells are exudated into the vitreous cavity. Ocular inflammation induces retinal gliosis and the activation of pigment epithelial cells, which sometimes causes subsequent proliferative vitreoretinopathy (PVR) which is directly related to the loss of vision in patients with uveitis.<sup>1,2</sup> In such cases, a pars plana vitrectomy (PPV) is the only way to maintain the visual functions. Owing to advances in the technical development of pars plana vitrectomy (PPV), the indications for a PPV in uveitis has continued to increase.<sup>1,3</sup>

In general, PPV in uveitis is more difficult to perform than in other diseases. Postoperative complications, such as cataract, high ocular pressure, and recurrence of PVR, are frequently induced by prolonged ocular inflammation. In fact, infiltrating macrophages have been shown to play a major part in the formation of the epiretinal membrane in an animal study.<sup>4</sup> It is therefore important to establish an effective ways to prevent and manage postoperative ocular inflammation in patients with uveitis. Although various surgical techniques and instruments have been developed in PPV, the removal of the residual vitreous cortex remains an uncertain procedure because of the transparency of the vitreous and also because inappropriate procedures can sometimes result in severe complications.

Triamcinolone acetonide (TA) is a water insoluble steroid that inhibits various inflammatory reactions. Peyman *et al* originally described the intravitreal injection of TA during a vitrectomy.<sup>5</sup> TA granules twine around the vitreous body and thus allow the transparent vitreous to be visualised and therefore helps surgeons to achieve a complete removal of the vitreous from the retina. We previously reported that TA assisted PPV improves the effectiveness of such surgical procedures, tends to obtain better visual outcome, and decreases the postoperative blood-ocular barrier breakdown.<sup>6</sup> TA actually improved the visibility of the vitreous body during PPV, which

ensured the safety of the surgical manoeuvres.<sup>6</sup> Thus far, TA assisted vitrectomy did not have any apparent adverse effects on postoperative findings or visual outcome.<sup>6</sup>

In the present study, we performed TA assisted PPV for the treatment of several kinds of refractory uveitis and examined the postoperative outcome. In some cases, 4 mg of TA was intentionally left after a vitrectomy to reduce the degree of postoperative inflammation.

## PATIENTS AND METHODS

### Patient selection

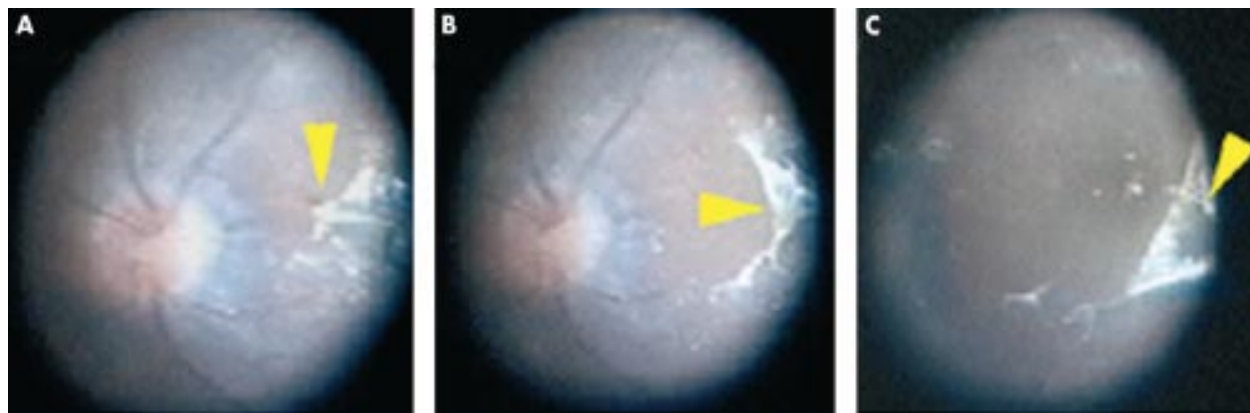
The patients with uveitis were included in the present study, which was carried out with the approval of the appropriate institutional review board and was performed in accordance with the ethical standards laid down in the 1989 Declaration of Helsinki. The possible merits and risks of the present treatment were explained to the patients before surgery and informed consent was obtained from all patients.

Patients who underwent TA assisted PPV at Kyushu University Hospital from April 2000 to June 2001 were enrolled in this study. All cases were examined postoperatively for 2 months or longer.

### Surgical procedures

A TA aqueous suspension was left standing for 30 minutes and the vehicle of TA (Kenakol-A, Bristol Pharmaceuticals KK, Tokyo, Japan) was discarded according to a previously described method.<sup>6</sup> The remaining TA (40 mg) suspension was mixed with 5 ml balanced salt solution (BSS, Santen, Osaka, Japan) and this procedure was repeated twice. Thereafter, the final suspension was used for the following procedure as a TA suspension.

Firstly, the standard phacoemulsification was performed when needed. The standard PPV using three sclerotomies,



**Figure 1** Intraoperative findings regarding the removal of the residual vitreous cortex (case 1). (A) A thin hyaloid membrane (arrow) is left on the posterior retina even after the surgical posterior hyaloid separation. The edge of this hyaloid is held with a surgical forceps (arrowhead). (B) The membrane is gradually removed. (C) The macular area (arrow) is then free from the residual vitreous cortex.

removing the vitreous up to the vitreous base, was performed and the following procedures were added. A core vitrectomy was performed and 0.5–1.0 ml of TA solution was injected with a 27 gauge needle into the mid-vitreous cavity. The TA granules were trapped in the gel structure of the vitreous. Thereafter, the posterior cortical vitreous appeared as a white gel and a break of the posterior hyaloid cortex appeared on the retinal surface. After the vitrectomy was sufficiently performed, the residual vitreous cortex which trapped TA was removed either by a silicone tipped needle or ILM forceps. Some eyes underwent retinal endolaser photocoagulation when needed. Finally, an intraocular lens was inserted and silicone or SF<sub>6</sub> gas tamponade was performed in some cases. After the conjunctiva was closed, gentamicin was injected subconjunctivally.

In addition, aciclovir (40 mg/ml) was dissolved in the infusion solution during PPV and silicone oil tamponade was performed in case 5.

#### Intentional TA leaving

Basically, we remove the TA granules from the eye using a silicone tipped needle after PPV. A small amount of TA granules were usually left on the inferior retina; however, the exact amount of TA left in the eye was not measured. To control ocular inflammation post-surgery, four of six patients had 4 mg of TA intentionally left in the vitreous cavity after the complete removal of the vitreous.

#### Postoperative examination

The patients were clinically examined for more than 4 months after surgery. Postoperatively, we carefully checked the best corrected visual acuity, while also identifying any elevation or symptoms of intraocular pressure (IOP), ocular inflammation, infection, or a need for reoperation. Ocular inflammation was scored based on the number of cells in the anterior chamber and vitreous cavity under slit lamp microscopy as described previously.<sup>7</sup> These examinations were performed by physicians without any information regarding the patients' surgical history. Therefore, these examinations were done in a masked manner.

## RESULTS

#### The individual preoperative conditions

Three female patients had had uveitis associated with sarcoidosis (cases 1–3). Although all three patients had already been treated by systemic and topical steroids, their condition did not improve. Thereafter, severe vitreous opacity and partial tractional retinal detachment occurred. A patient with Behçet's disease and underwent PPV because of retinal detachment induced by the traction of proliferative tissues in

the vitreous that was confirmed by the examination of B-mode ultrasound examination (case 4). A patient with Vogt-Koyanagi-Harada (VKH) disease (case 5) underwent PPV because of her rhegmatogenous retinal detachment. Although the correlation between VKH and the retinal detachment was not clear, she actually had prolonged ocular inflammation due to a relapse of VKH disease when she had PPV. Another patient (case 6) had acute retinal necrosis induced by an infection of herpes simplex virus type 1 (HSV-1), which was diagnosed based on virus DNA amplifications by polymerase chain reaction (PCR) in the aqueous humour. At the time of PPV, the peripheral retina became necrotic and multiple retinal holes existed at the necrotic portion.

#### During surgical procedures

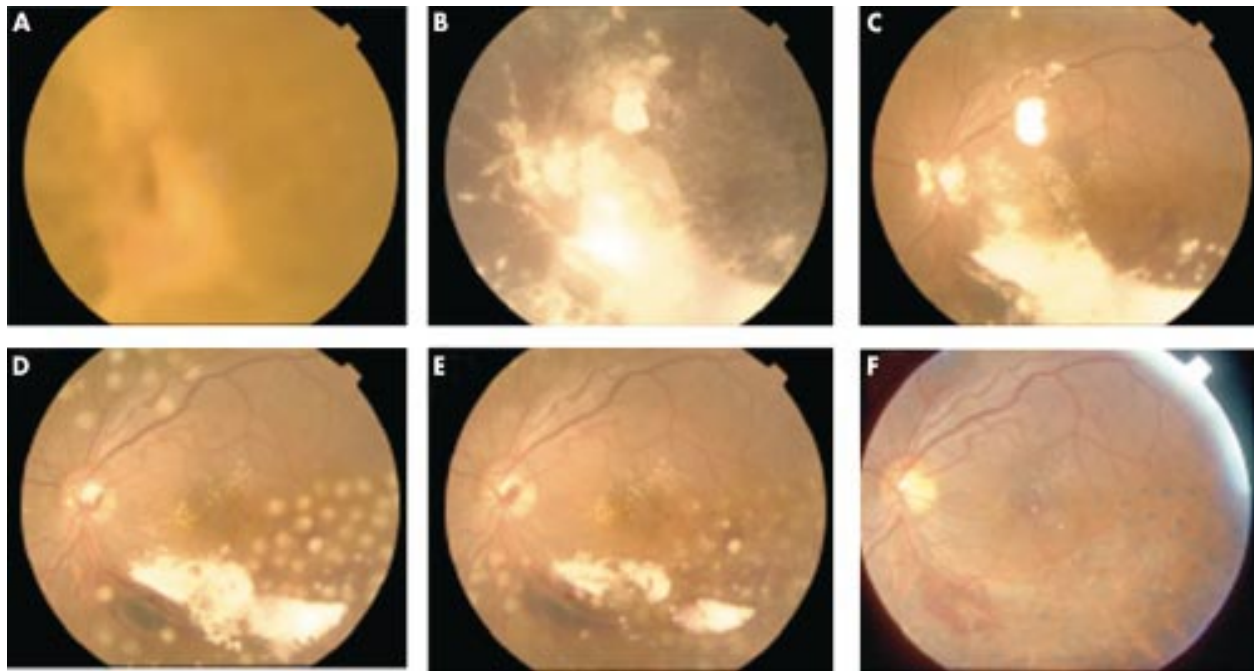
During the surgery, the posterior hyaloid was clearly seen as a white powdery gel after the injection of TA suspension. In most cases, the posterior hyaloid could be separated from the retina by the gentle aspiration of a vitrectomy probe or silicone tipped needle; thus no iatrogenic retinal tear was formed during this procedure.<sup>6</sup> Of note, the islands of the thin posterior hyaloid membrane (residual vitreous cortex) were scatteringly observed on the retinal surface even after the surgical posterior vitreous detachment was completed by the routine method (Fig 1). It is very difficult to recognise the island of the hyaloid membrane without the aid of TA solution. TA also greatly improved the visibility of the obscure peripheral vitreous.

#### Postoperative evaluation

At the end of the follow up period, the retina was attached in all six cases. No eye required additional PPV, filtering surgery, or cataract surgery. After surgery, the intentionally left TA gradually disappeared within a month in the vitreous cavity (Fig 2).

In five of six cases, the visual acuities were improved after TA assisted PPV (Table 1). Case 4 did not show an improvement in the visual acuity. Her optic disc had been seriously damaged by Behçet's disease, and we could not even observe her fundus before operation because of a dense cataract.

As shown in Table 2, ocular inflammation in both the anterior chamber and anterior vitreous cavity was reduced in all cases post-TA assisted PPV. This tendency became apparent in the vitreous cavity compared to the inflammations in the anterior chamber. To confirm the conditions of posterior segment of the eye, fluorescein angiography (FAG) was performed after TA assisted PPV. In all six cases, the condition of the retinal vessels was generally fair. Figure 3 showed the representative photographs of FAG (cases 3, 4, and 6). There were



**Figure 2** A series of fundus photographs before and after TA assisted PPV (case 2, in whom 4 mg of TA was intentionally left post-PPV). (A) The fundus photograph on 17 April 2002 (before PPV). The details of the fundus were completely obscure. PPV was performed on 23 April and 4 mg of TA was intentionally left to control postoperative inflammation. (B–F) The fundus photographs post-PPV. (B) 24 April (the day after PPV), (C) 28 April, (D) 5 May, (E) 10 May, (F) 15 July. The details of the ocular fundus including laser photocoagulation spots can be observed. In addition, the remaining amount of TA (white material) gradually decreased until it had almost disappeared by 10 May (23 days after PPV) and thereafter completely disappeared before 15 July.

**Table 1** Patients' demography and treatment outcome

Patient No	Sex	Age (years)	Kind of uveitis	Preoperative visual acuity	Postoperative visual acuity	Combined surgery	TA leave	Follow up (month)	Complication
1	F	27	sarcoidosis	HB	20/20	PEA+IOL implantation	+	7	none
2	F	30	sarcoidosis	HB	20/20	PEA+IOL implantation	+	7	none
3	F	61	sarcoidosis	20/50	20/30	PEA+IOL implantation	+	4	none
4	F	36	Behcet disease	HB	HB	PEA+IOL implantation	+	6	IOP elevation
5	F	58	VKH	HB	20/200	none	–	8	none
6	F	36	ARN	20/50	20/30	PEA	–	10	none

HM = hand movement, PEA = phacoemulsification and aspiration, IOL = intraocular lens.

no inflamed lesions such as a severe hyperfluorescein area, non-perfusion area because of vessel occlusion or oedema. Collectively, we can conclude that the TA used during PPV reduced the degree of postoperative ocular inflammation effectively.

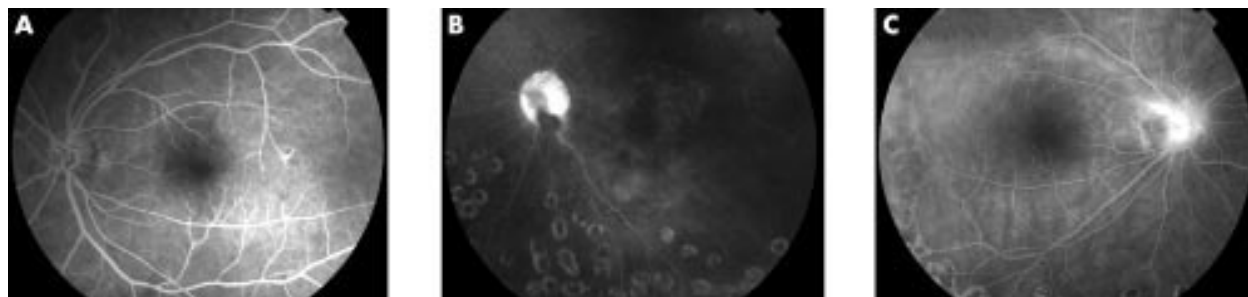
An IOP elevation is a common complication of treatment involving ocular TA injection.<sup>8–11</sup> In a previous study, 25% of the eyes with an intraocular injection of TA experienced an IOP elevation and as much as 4 mg of triamcinolone was injected into the eyes of the patients.<sup>9</sup> One patient transiently showed

an elevated IOP after surgery (case 4). However, she also had partial goniosynechia and complete posterior synechia of the iris as a result of Behçet's disease, thus her IOP was elevated (45 mm Hg) and uncontrollable by topical and systemic antiglaucoma drugs by the time she was referred to our clinic. We assume that her postoperative IOP elevation was due to the pre-existing goniosynechia rather than to the side effects of TA.

The intraoperative use of steroids might also increase the risk of postoperative infection. In this series of examinations,

**Table 2** Preoperative and Postoperative inflammation

Patient No	Anterior chamber			Anterior vitreous cavity		
	Preoperative	1 month	2 month	Preoperative	1 month	2 month
1	+++	+	+	++	+	+
2	+	–	–	+++	–	–
3	+	–	–	++	–	–
4	+	±	–	invisible	±	–
5	+	+	+	++	±	±
6	++	±	–	+++	±	–



**Figure 3** The representative photographs of fluorescein angiography after TA assisted PPV (cases 3 (A), 4 (B), and 6 (C)). All photographs were taken 2 months after PPV.

we did not see any infections even in the patient with acute retinal necrosis caused by an infection of HSV-1. In addition, cataract formation is another complication of ocular steroid treatment. All patients underwent lens extraction before PPV (case 5 had already undergone cataract surgery before PPV), and thus the effect of TA assisted PPV on cataracts could not be determined.

## DISCUSSION

In this study, TA assisted PPV was performed in patients with refractory uveitis. TA actually improved the visibility of the vitreous body and residual vitreous cortex during PPV, which thus ensured the safety of the surgical manoeuvres. In addition, the TA assisted vitrectomy did not have any apparent adverse effects on the postoperative findings in uveitis patients. After surgery, the intentionally left TA gradually disappeared within a month in the vitreous cavity (Fig 2). Since the clearance time of triamcinolone in the vitreous is much longer than that of water soluble steroids,<sup>12,13</sup> the anti-inflammatory effect lasts for a long time. The remaining TA effectively suppressed the postoperative intraocular inflammation that tends to be associated with uveitis (Table 2). On the other hand, we should be aware of the side effects caused by steroids and infection for approximately 1 month after surgery.

In uveitis patients, ocular inflammation after PPV tends to induce various complications. Inflammatory cells can secrete various chemical mediators and cytokines, which can induce the intravitreal migration of secondary inflammatory cells, such as glial cells and retinal pigment epithelial (RPE) cells.<sup>14</sup> In the most serious cases, these cells can proliferate, produce an extracellular matrix, and contract the residual vitreous cortex, thus leading to secondary tractional retinal detachment. Therefore, reducing postoperative inflammation by the administration of TA appears to be an effective method of PPV for uveitis patients. In fact, the intravitreal injection of TA has been successfully shown to inhibit experimental PVR in rabbits and optic disc neovascularisation of pigs.<sup>15,16</sup> In addition, in a clinical study, Jonas *et al* reported that the intravitreal inoculation of steroids clearly reduced the incidence of PVR after a vitrectomy.<sup>17,18</sup>

It is notable that we could achieve a complete removal of residual vitreous cortex safely and easily by the assistance of TA (Fig 1). The remnant vitreous on the retina can be a scaffold of pathological cells, such as hyalocytes and glial cells, which can eventually cause macular pucker or secondary retinal detachment. As shown in Figure 1, the TA visualised residual vitreous cortex was frequently left on the macula, because it is the firmest area of vitreoretinal adhesion. It is therefore understandable that the remaining vitreous cortex tends to form macular oedema and a premacular membrane. The complete removal of the vitreous is effective for the treatment of macular oedema associated with refractory uveitis.<sup>19–21</sup>

We did not experience any severe side effects caused by the administration of TA including infections in this study series. In previous clinical reports, the intraocular injection of TA has been applied in age related macular degeneration<sup>8,9</sup> and as an adjuvant therapy of PPV for diabetic retinopathy.<sup>17,18</sup> Although the toxicity of TA itself on the human retinal function have not yet been determined,<sup>13</sup> several side effects of TA have been reported.<sup>8,9,17,18</sup> It is true that TA assisted PPV can potentially increase the risk of ocular side effects and infections, especially in our series in which TA was intentionally left after surgery. However, the anti-inflammatory effects of TA are more important than its potentially harmful effects in patients with severe uveitis.

There are clear limitations in this study. It is a case series, not a case-controlled study. In addition, the number of patients and the follow up period are limited. However, there was a perceived benefit regarding the ease in detecting and removing the attached posterior hyaloid during vitrectomy. Furthermore, we would like to emphasise that the anti-inflammatory effects of TA assisted vitrectomy were obvious (as shown in Table 2). Not only did our method improve the visibility during PPV, it had a great potential to reduce postoperative inflammation both in the anterior and posterior segment of the eye without any side effects. If future randomised studies can show the beneficial effects on visual and surgical outcome, TA assisted vitrectomy should thus become accepted as a new method for performing a vitrectomy in uveitis patients.

## ACKNOWLEDGEMENTS

This work was supported in part by grant in aid No 09671804 for scientific research from the Ministry of Education, Science, Sports and Culture of the Japanese Government, the Japan National Society for the Prevention of Blindness (Tokyo).

## Authors' affiliations

**K-H Sonoda, H Enaida, A Ueno, T Nakamura, Y-I Kawano, T Kubota, T Ishibashi**, Department of Ophthalmology, Kyushu University Graduate School of Medicine, Fukuoka, Japan  
**T Sakamoto**, Department of Ophthalmology, Kagoshima University, Kagoshima, Japan

## REFERENCES

- 1 Bovey EH, Herbert CP. Vitrectomy in the management of uveitis. *Ocul Immunol Inflamm* 2000;**8**:285–91.
- 2 Nagasaki H, Shinagawa K, Mochizuki M. Risk factors for proliferative vitreoretinopathy. *Prog Retin Eye Res* 1998;**17**:77–98.
- 3 Verbraeken H. Therapeutic pars plana vitrectomy for chronic uveitis: a retrospective study of the long-term results. *Graefes Arch Clin Exp Ophthalmol* 1996;**234**:288–93.
- 4 Miller B, Miller H, Patterson R, *et al*. Retinal wound healing. Cellular activity at the vitreoretinal interface. *Arch Ophthalmol* 1986;**104**:281–5.
- 5 Peyman GA, Cheema R, Conway MD, *et al*. Triamcinolone acetate as an aid to visualization of the vitreous and the posterior hyaloid during pars plana vitrectomy. *Retina* 2000;**20**:554–5.
- 6 Sakamoto T, Miyazaki M, Hisatomi T, *et al*. Triamcinolone-assisted pars plana vitrectomy improves the surgical procedures and decreases the

- postoperative blood-ocular barrier breakdown. *Graefes Arch Clin Exp Ophthalmol* 2002;**240**:423-9.
- 7 **Hogan MJ**, Kimura SJ, Thygeson P. Signs and symptoms of uveitis. 1. Anterior uveitis. *Am J Ophthalmol* 1959;**47**:155-70.
  - 8 **Challa JK**, Gillies MC, Penfold PL, et al. Exudative macular degeneration and intravitreal triamcinolone: 18 month follow up. *Aust N Z J Ophthalmol* 1998;**26**:277-81.
  - 9 **Danis RP**, Ciulla TA, Pratt LM, et al. Intravitreal triamcinolone acetonide in exudative age-related macular degeneration. *Retina* 2000;**20**:244-50.
  - 10 **Riordan-Eva P**, Lightman S. Orbital floor steroid injections in the treatment of uveitis. *Eye* 1994;**8**:66-9.
  - 11 **Wingate RJ**, Beaumont PE. Intravitreal triamcinolone and elevated intraocular pressure. *Aust N Z J Ophthalmol* 1999;**27**:431-2.
  - 12 **Schindler RH**, Chandler D, Thresher R, et al. The clearance of intravitreal triamcinolone acetonide. *Am J Ophthalmol* 1982;**93**:415-7.
  - 13 **Scholes GN**, O'Brien WJ, Abrams GW, et al. Clearance of triamcinolone from vitreous. *Arch Ophthalmol* 1985;**103**:1567-9.
  - 14 **Wiedemann P**. Growth factors in retinal diseases: proliferative vitreoretinopathy, proliferative diabetic retinopathy, and retinal degeneration. *Surv Ophthalmol* 1992;**36**:373-84.
  - 15 **Tano Y**, Chandler D, Machermer R. Treatment of intraocular proliferation with intravitreal injection of triamcinolone acetonide. *Am J Ophthalmol* 1980;**90**:810-6.
  - 16 **Tano Y**, Chandler DB, McCuen BW, et al. Glucocorticosteroid inhibition of intraocular proliferation after injury. *Am J Ophthalmol* 1981;**91**:184-9.
  - 17 **Jonas JB**, Hayler JK, Panda-Jonas S. Intravitreal injection of crystalline cortisone as adjunctive treatment of proliferative vitreoretinopathy. *Br J Ophthalmol* 2000;**84**:1064-7.
  - 18 **Jonas JB**, Hayler JK, Sofker A, et al. Intravitreal injection of crystalline cortisone as adjunctive treatment of proliferative diabetic retinopathy. *Am J Ophthalmol* 2001;**131**:468-71.
  - 19 **Stavrou P**, Baltatzis S, Letko E, et al. Pars plana vitrectomy in patients with intermediate uveitis. *Ocul Immunol Inflamm* 2001;**9**:141-51.
  - 20 **Dugel PU**, Rao NA, Ozler S, et al. Pars plana vitrectomy for intraocular inflammation-related cystoid macular edema unresponsive to corticosteroids. A preliminary study. *Ophthalmology* 1992;**99**:1535-41.
  - 21 **Kiryu J**, Kita M, Tanabe T, et al. Pars plana vitrectomy for cystoid macular edema secondary to sarcoid uveitis. *Ophthalmology* 2001;**108**:1140-4.

Find out what's in the latest issue  
the moment it's published

### Email Alerts

Sign up to receive the table of contents by email every month. You can select from three alerts: Table of Contents (full), TOC Awareness (notice only); *British Journal of Ophthalmology* related announcements.

[www.bjophthalmol.com](http://www.bjophthalmol.com)



## Pars plana vitrectomy assisted by triamcinolone acetonide for refractory uveitis: a case series study

K-H Sonoda, H Enaida, A Ueno, et al.

*Br J Ophthalmol* 2003 87: 1010-1014

doi: 10.1136/bjo.87.8.1010

---

Updated information and services can be found at:

<http://bjo.bmj.com/content/87/8/1010.full.html>

---

*These include:*

### References

This article cites 20 articles, 3 of which can be accessed free at:

<http://bjo.bmj.com/content/87/8/1010.full.html#ref-list-1>

Article cited in:

<http://bjo.bmj.com/content/87/8/1010.full.html#related-urls>

### Email alerting service

Receive free email alerts when new articles cite this article. Sign up in the box at the top right corner of the online article.

---

### Topic Collections

Articles on similar topics can be found in the following collections

[Ophthalmologic surgical procedures](#) (962 articles)

[Retina](#) (1207 articles)

[Vitreous](#) (124 articles)

[Choroid](#) (434 articles)

[Neurology](#) (1036 articles)

---

### Notes

---

To request permissions go to:

<http://group.bmj.com/group/rights-licensing/permissions>

To order reprints go to:

<http://journals.bmj.com/cgi/reprintform>

To subscribe to BMJ go to:

<http://group.bmj.com/subscribe/>