

## SCIENTIFIC REPORT

## Central retinal artery and vein collapse pressure in eyes with chronic open angle glaucoma

J B Jonas

*Br J Ophthalmol* 2003;**87**:949–951

**Aims:** To determine central retinal vessel collapse pressure in chronic open angle glaucoma.

**Methods:** For 19 eyes with chronic open angle glaucoma and 27 eyes of a control group, central retinal vessel collapse pressure was measured by a Goldmann contact lens fitted with a pressure sensor in its holding grip.

**Results:** Central retinal vein collapse pressure was significantly ( $p=0.001$ ) higher in the glaucoma group than in the control group (26.1 (SD 26.4) relative units versus 6.1 (8.4) relative units).

**Conclusions:** Measured by a new ophthalmodynamometer, central retinal vein collapse pressure measurements may be abnormally high in eyes with chronic open angle glaucoma.

In eyes with chronic open angle glaucoma as well as for eyes with non-glaucomatous optic nerve damage, a reduction in the diameter of the retinal arteries has been described.<sup>1–5</sup> In eyes with non-glaucomatous optic nerve damage, an additional decrease in the diameter of the retinal veins has been found.<sup>6</sup> It is in contrast with eyes with chronic open angle glaucoma which showed a less marked reduction in the calibre of retinal veins than eyes with non-glaucomatous optic nerve damage.<sup>2–6,7</sup> The less pronounced change in the retinal vein diameter despite the marked reduction in the retinal arterial diameter is paralleled by an increased frequency of retinal vein occlusions in eyes with chronic open angle glaucoma.<sup>8</sup> Since the diameter of retinal veins may depend on the blood pressure in the retinal veins, and because the development of retinal vein occlusions may also be associated with the retinal vein pressure, it was the purpose of the present study to evaluate the retinal vein collapse pressure as indirect measure of the retinal vein pressure in eyes with chronic open angle glaucoma.

## PATIENTS AND METHODS

The study included 19 eyes of patients with primary or secondary chronic open angle glaucoma with a mean age of 67.8 (SD 11.3) years (median 66.1 years; range 50.0–87.5 years), and 27 eyes of an age matched control group attending the hospital because of cataract or refractive problems. In the control group, mean age was 69.6 (12.5) years (median, 69.1 years; range 44.1–95.1 years). The methods applied in the study adhered to the tenets of the declaration of Helsinki for the use of human subjects in biomedical research. Informed consent was obtained from each subject before enrolment.

In the glaucoma group, all patients had an open anterior chamber angle, history of elevated intraocular pressure higher than 21 mm Hg, glaucomatous changes of the optic nerve head, and glaucomatous visual field defects. The glaucomatous group was additionally divided into eyes with primary open angle glaucoma ( $n=11$  eyes) in which no obvious reason

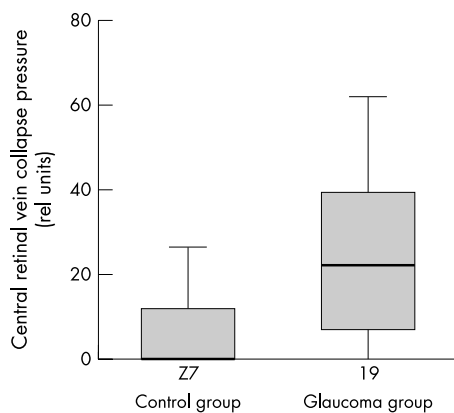
for the elevated intraocular pressure could be detected, and eyes with secondary open angle glaucoma for reasons such as pseudoexfoliation or primary melanin pigment dispersion syndrome ( $n=8$ ). Glaucoma patients with history of filtering surgery were excluded. In subjects in the control group, intraocular pressure was lower than 22 mm Hg without medication. The ophthalmoscopic appearance of the optic nerve head, including the visibility of the retinal nerve fibre layer, was unremarkable with no signs of glaucomatous optic neuropathy or non-glaucomatous optic nerve damage. The subjects in the control group attended the hospital for cataract or refractive problems. Intraocular pressure measured in the eyes of the control group was 16.3 (2.0) mm Hg. In the eyes of the glaucoma group, mean intraocular pressure was 22.9 (11.4) mm Hg at the time of the ophthalmodynamometric examination.

The pupil was dilated using tropicamide 0.5% and phenylephrine 5%. With topical anaesthesia (oxybuprocaine 0.4%), a conventional Goldmann contact lens fitted with a pressure sensor mounted into its holding ring was put onto the cornea. Pressure was applied onto the globe by slightly pressing the contact lens, and the pressure values at the time when the central retinal vein or central retinal artery started to pulsate were noted. The measurements were repeated nine times, and the mean of the 10 values was taken for further statistical analysis. All readings were performed with the examiner holding the Goldmann contact lens and performing ophthalmodynamometry, and an assistant recording the sensor reading. The method has already been described in detail.<sup>9,10</sup> The reproducibility of the technique determined as mean coefficient of variation was 16.3% (11.4%) for re-determinations of the central retinal vein collapse pressure, and 8.5% (4.1%) for re-measurements of the central retinal artery collapse pressure.<sup>11</sup> The technique is partially similar to other ophthalmodynamometric tests or other variations of ophthalmodynamometry in which the operator visualised the disc through an applanation tonometer.<sup>12</sup>

## RESULTS

In the glaucoma group, the collapse pressure of the central retinal artery measured 75.7 (SD 19.4) relative units. It was not significantly ( $p=0.89$ ) different from the value in the control group (78.0 (19.2) relative units). In the central retinal vein, the diastolic collapse pressure measured in the glaucoma group was 26.1 (26.4) relative units. It was significantly ( $p=0.001$ ) higher than the value in the control group (6.1 (8.4) relative units) (Fig 1).

Within the study control group and within the glaucoma group, the central retinal vein collapse pressure was statistically independent of the intraocular pressure ( $p=0.52$  for the control group; 0.24 for the glaucoma group). Correspondingly, a regression analysis including the parameters study group and intraocular pressure showed that the central retinal vein collapse pressure was statistically independent ( $p=0.12$ ) of the intraocular pressure.



**Figure 1** Box plots showing the central retinal vein collapse pressure in the study group of patients with chronic open angle glaucoma and in the control group.

## DISCUSSION

Examination of the collapse pressure of the central retinal artery and central retinal vein can have importance for the diagnosis of diseases involving the lamina cribrosa, the retrobulbar part of the optic nerve, the cerebrospinal fluid space, the orbit, and the brain. The reason is that both vessels pass through the lamina cribrosa, and originate from, or drain into, structures that are located in the orbit or inside of the cranium. The collapse pressure of the central retinal vessels may be determined by ophthalmodynamometry, which was popular in the 1960s and 1970s. Because of limitations of the cumbersome methodology, such as problems with a standardised indenting of the globe and difficulties in detailed observing the optic nerve head and detecting the pulsating changes of the retinal vessels, the old technique of ophthalmodynamometry was almost completely abandoned when Doppler sonography allowed measurements of the blood velocity in the carotid arteries.<sup>13 14</sup>

The new ophthalmodynamometric technique, which consists of a Goldmann contact lens for biomicroscopic observation of the optic nerve head, may overcome some of the disadvantages of the previous technique of ophthalmodynamometry. Recent studies have suggested that the new ophthalmodynamometric technique may be helpful to detect ischaemic ophthalmopathy, and to measure the cerebrospinal fluid pressure in patients with increased brain pressure.<sup>9 10</sup> Other studies including normal subjects and patients with various diseases such as retinal vein occlusions, endocrine orbitopathy, chronic open angle glaucoma, carotid artery stenosis, and giant cell arteritis showed that the coefficient of variation for the re-determination of the central retinal vein collapse pressure was 15.9% (11.9%), and that the coefficient of variation for the re-determination of the central retinal artery collapse pressure was 9.1% (4.2%).<sup>11</sup> In a group of normal subjects, the central retinal artery collapse pressure was significantly correlated with the brachial diastolic arterial pressure, suggesting that some kind of arterial blood pressure estimation may be performed by the ophthalmologist during a routine ophthalmoscopic examination (own data). Other studies demonstrated that the assessment of the central retinal vein collapse pressure may be useful to estimate the tissue pressure in the orbit in the diagnosis and follow up of patients suffering from endocrine orbitopathy (own data); that the central retinal vein collapse pressure may be higher in eyes with central retinal vein occlusion than in eyes with branch retinal vein occlusion or eyes with retinal venous stasis, in which the central retinal vein collapse pressure may be higher than in normal eyes<sup>15</sup>; and that the new ophthalmodynamometric technique may be useful for detecting intracranial arterio-venous fistulation<sup>16</sup> and secondary open angle glaucoma.<sup>17</sup>

The results of the present study suggest that the central retinal vein collapse pressure may be higher in eyes with chronic open angle glaucoma than in normal subjects (Fig 1). It fits with the increased frequency of retinal vein occlusions in eyes with chronic open angle glaucoma,<sup>8</sup> and with the finding that eyes with central retinal vein occlusions have a higher central retinal vein collapse pressure than normal eyes.<sup>15</sup> It is also in agreement with biomorphometric examinations which showed a higher ratio of retinal vein to artery diameter in eyes with chronic open angle glaucoma than in normal eyes.<sup>2 7</sup> Additionally, angiographic studies have demonstrated that the intraretinal transit time is prolonged in patients with glaucoma.<sup>12</sup> The reason why the central retinal vein pressure was raised in the glaucomatous eyes may be an obstruction of the outflow system in the level of the lamina cribrosa, caused by a mechanical distortion of the lamina cribrosa. Future studies may examine whether the shape and depth of the optic cup as a measure of the glaucoma induced change in the inner structure of the lamina cribrosa and whether the stage of glaucomatous optic nerve damage may be related to central retinal vein collapse pressure in eyes with glaucoma.

There are limitations of the investigation. Only a relatively small number of individuals who may not have been representative of patients with glaucoma were included in the study. Additionally, the various types of chronic open angle glaucoma summarised in a single study group in the present investigation may differ in the central retinal vein collapse pressure, so that there may be a wide spectrum of involvement of the venous circulation in the different types and stages of glaucoma. This has already been pointed out by Hitchings and others.<sup>8</sup> To cite an example, it is unclear whether the elastic properties of the lamina cribrosa, which may be different in pseudoexfoliative eyes compared with non-pseudoexfoliative eyes may influence central retinal vein collapse pressure. Another limitation may be that because of the small sample size, a correlation between the central retinal vessel collapse pressure to the level of intraocular pressure was not found, although clinical observations may suggest that a change in intraocular pressure may result in an alteration in the central retinal vein collapse pressure. Since the moment of the first vessel wall movement was taken as a measurement point of an early collapse, it was not clear whether the venous collapse pressure differed between the upper or lower hemisphere of the fundus. Future studies may address the question whether the venous collapse pressure differs between the superior and inferior hemisphere in eyes with a marked hemispheric asymmetry in the degree of glaucomatous optic nerve damage.

In conclusion, central retinal vein collapse pressure as measured by a new ophthalmodynamometer may be abnormally high in eyes with chronic open angle glaucoma. Future studies may show whether determination of central retinal vein collapse pressure in eyes with chronic open angle glaucoma is suitable for predicting which eyes have a higher risk for eventual retinal vein occlusion and need a more intensive intraocular pressure lowering therapy than eyes with chronic open angle glaucoma that do not show an elevated risk for eventual retinal vein occlusion.

Proprietary interest: none.

## Author's affiliations

**J B Jonas**, Department of Ophthalmology, Faculty of Clinical Medicine Mannheim, University of Heidelberg, 68167 Mannheim, Germany

Correspondence to: Dr J Jonas, Universitäts-Augenklinik, Theodor-Kutzer-Ufer 1-3, 68167 Mannheim, Germany; [Jost.Jonas@augen.ma.uni-heidelberg.de](mailto:Jost.Jonas@augen.ma.uni-heidelberg.de)

Accepted for publication 15 December 2002

## REFERENCES

- 1 Frisén L, Claesson M. Narrowing of the retinal arterioles in descending optic atrophy. A quantitative clinical study. *Ophthalmology* 1984;**91**:1342-6.

- 2 **Jonas JB**, Nguyen XN, Naumann GOH. Parapapillary retinal vessel diameter in normal and glaucoma eyes. I. Morphometric data. *Invest Ophthalmol Vis Sci* 1989;**30**:1599–603.
- 3 **Rader J**, Feuer J, Anderson DR. Peripapillary vasoconstriction in the glaucomas and the anterior ischemic optic neuropathy. *Am J Ophthalmol* 1994;**117**:72–80.
- 4 **Papastathopoulos K I**, Jonas JB. Focal narrowing of retinal arterioles in optic nerve atrophy. *Ophthalmology* 1995;**102**:1706–11.
- 5 **Ratkin SJA**, Drance SM. Peripapillary focal retinal arteriolar narrowing in open angle glaucoma. *J Glaucoma* 1996;**5**:22–8.
- 6 **Jonas JB**, Xu L. Optic disc morphology in eyes after nonarteritic anterior ischemic optic neuropathy. *Invest Ophthalmol Vis Sci* 1993;**34**:2260–5.
- 7 **Jonas JB**, Naumann GOH. Parapapillary retinal vessel diameter in normal and glaucoma eyes. II. Correlations. *Invest Ophthalmol Vis Sci* 1989;**30**:1604–11.
- 8 **Hitchings RA**, Spaeth GL. Chronic retinal vein occlusion in glaucoma. *Br J Ophthalmol* 1976;**60**:694–9.
- 9 **Jonas JB**, Niessen A. Ophthalmodynamometric diagnosis of unilateral ischemic ophthalmopathy. *Am J Ophthalmol* 2002;**134**:911–12.
- 10 **Jonas JB**, Harder B. Ophthalmodynamometric estimation of cerebrospinal fluid pressure in pseudotumour cerebri. *Br J Ophthalmol* 2003;**87**:361–2.
- 11 **Jonas JB**. Reproducibility of ophthalmodynamometric measurements of the central retinal artery and vein collapse pressure. *Br J Ophthalmol* 2003;**87**:577–9.
- 12 **Spaeth GL**. *Pathogenesis of visual loss in glaucoma: contributions and indications for fluorescein angiography*. New York: Grune and Stratton, 1977.
- 13 **Wunsh SE**. Ophthalmodynamometry. *N Engl J Med* 1969;**281**:446.
- 14 **Kriegelstein GK**, da Silva FA. Comparative measurements of the ophthalmic arterial pressure using the Mikuni dynamometer and the Stephanik-arteriotonomograph. *Albrecht Von Graefes Arch Klin Exp Ophthalmol* 1979;**212**:77–91.
- 15 **Jonas JB**. Ophthalmodynamometric assessment of the central retinal vein collapse pressure in eyes with retinal vein stasis or occlusion. *Graefes Arch Clin Exp Ophthalmol* 2003; (in press).
- 16 **Jonas JB**, Groden C. Carotid-cavernous sinus fistula diagnosed by ophthalmodynamometry. *Acta Ophthalmol* 2003; (in press).
- 17 **Jonas JB**. Ophthalmodynamometry in eyes with dilated episcleral veins. *J Glaucoma* 2003; (in press).



**3rd Asia Pacific Forum on Quality Improvement in Health Care**  
**3–5 September 2003, Auckland, New Zealand**



We are delighted to announce this forthcoming conference in Auckland, New Zealand.

The themes of the 3rd Asia Pacific Forum on Quality Improvement in Health Care are:

- Agenda for quality: Improving equity in health care delivery
- Improving safety
- Leadership for improvement
- Measuring quality and benchmarking for change
- Evidence based knowledge and education for quality improvement
- Improving health systems
- Patient/consumer centred quality improvement

Presented to you by the BMJ Publishing Group (London, UK) and Institute for Healthcare Improvement (Boston, USA), supported by the New Zealand Ministry of Health, ACC, and Standards New Zealand.

For more information about the Forum or to register contact: [quality@bma.org.uk](mailto:quality@bma.org.uk) or go to:

**[www.quality.bmjpg.com](http://www.quality.bmjpg.com)**

Tel: +44 (0)20 7383 6409 Fax: +44 (0)20 7383 6869



## Central retinal artery and vein collapse pressure in eyes with chronic open angle glaucoma

J B Jonas

*Br J Ophthalmol* 2003 87: 949-951  
doi: 10.1136/bjo.87.8.949

---

Updated information and services can be found at:  
<http://bjo.bmj.com/content/87/8/949.full.html>

- 
- References** *These include:*  
This article cites 13 articles, 6 of which can be accessed free at:  
<http://bjo.bmj.com/content/87/8/949.full.html#ref-list-1>
- Article cited in:  
<http://bjo.bmj.com/content/87/8/949.full.html#related-urls>
- Email alerting service** Receive free email alerts when new articles cite this article. Sign up in the box at the top right corner of the online article.

- 
- Topic Collections** Articles on similar topics can be found in the following collections
- [Angle](#) (788 articles)
  - [Glaucoma](#) (776 articles)
  - [Intraocular pressure](#) (786 articles)

---

### Notes

---

To request permissions go to:  
<http://group.bmj.com/group/rights-licensing/permissions>

To order reprints go to:  
<http://journals.bmj.com/cgi/reprintform>

To subscribe to BMJ go to:  
<http://group.bmj.com/subscribe/>