

SCIENTIFIC CORRESPONDENCE

Optical coherence tomography in malignant glaucoma following filtration surgery

C Wirbelauer, A Karandish, H Häberle, D T Pham

Br J Ophthalmol 2003;**87**:952–955

Aim: To assess the value of slit lamp adapted optical coherence tomography (OCT) for the management of malignant glaucoma following filtration surgery.

Methods: Two patients (three eyes) developed malignant glaucoma following filtration surgery for primary open angle glaucoma (POAG). With slit lamp adapted OCT it was possible to image non-invasively the anterior chamber angle structures during the malignant glaucoma episode, and after pars plana vitrectomy (PPV) with anterior chamber reformation.

Results: OCT revealed in both patients a markedly decreased anterior chamber angle with extreme shallowing of the anterior chamber depth during the acute malignant glaucoma phase. This critical closure of the anterior chamber angle resolved after PPV and deepening of the anterior chamber with viscoelastic. After PPV the quantitative values of the anterior chamber angle (ACA) and the anterior chamber opening distance (AOD) increased from 0 to an ACA of 35° (SD 14°) and an AOD of 426 (SD 162) µm.

Conclusions: Non-contact slit lamp adapted OCT was helpful to evaluate the anterior chamber structures in malignant glaucoma, and thus could improve management of this serious clinical disorder.

Malignant glaucoma following filtration surgery remains one of the most challenging complications in terms of diagnosis and management faced by glaucoma surgeons with possible deleterious effects for the patient. It refers to a shallow or flat central and peripheral anterior chamber caused by the forward movement of the lens-iris and iris-hyaloid diaphragm accompanied by elevated IOP, in the presence of a patent peripheral iridectomy.¹ The precise mechanism in the pathogenesis of this potentially devastating complication is probably related to an abnormal anatomical relation between lens, zonules, anterior vitreous face, and ciliary body. This leads to misdirection of aqueous fluid into the vitreous cavity with subsequent increase in vitreous volume, anterior displacement of central and peripheral anterior segment structures, and increase in intraocular pressure (IOP).^{1–6}

We describe two patients who developed malignant glaucoma following filtration surgery, and were treated with pars plana vitrectomy (PPV) and anterior chamber reformation with viscoelastics. Slit lamp adapted optical coherence tomography (OCT),^{7–9} a new non-invasive high resolution imaging technique, was used to objectively image the anterior chamber angle structures qualitatively and quantitatively.

PATIENTS

Two phakic women (three eyes) developed malignant glaucoma following filtration surgery for uncontrolled primary

open angle glaucoma (POAG) with narrow angles (Table 1). Examination included best corrected visual acuity (decimal fractions), slit lamp biomicroscopy, applanation tonometry, gonioscopy, indirect ophthalmoscopy, and A-scan ultrasonography. Visual fields (HFA II, Zeiss-Humphrey, Jena) were full with mild to moderate glaucomatous defects.

Serial slit lamp adapted OCT examinations were performed (AS-OCT, 4Optics AG, Lübeck, Germany). To enhance the OCT image for the anterior eye segment (Fig 1A) a light source using a superluminescent diode (SLD-561, Superlum, Moscow, Russian Federation) operating at a wavelength of $\lambda=1310$ nm with a bandwidth of 50 nm and an intensity of the incident light of less than 200 µW was used.^{7–9} The determination of the anterior chamber angle (ACA) and the anterior chamber opening distance (AOD) were adapted from ultrasound biomicroscopy to the OCT method.¹⁰ Furthermore, the scleral thickness at the optical scleral spur, the central corneal thickness, and the central anterior chamber depth during the acute malignant glaucoma phase were recorded (OCTeval, Version 1.1, 4Optics AG, Lübeck). Several optical sections were taken, and the average value of these measurements was then converted to geometric distances. All results were presented as mean (SD) in Table 1.

Both patients had uneventful filtration surgery with a fornix based conjunctival flap. Peripheral iridectomy was patent, a filtration bleb was present, and no choroidal effusions were found. The eyes developed malignant glaucoma with an extremely shallow anterior chamber after 2 days, 6 days, and 6 weeks following the primary surgical intervention. Slit lamp adapted OCT revealed in both patients a markedly narrow anterior chamber angle with extreme shallowing of the anterior chamber depth during the acute malignant glaucoma phase (Figs 1B, C and 2A, B). In both patients, marked displacement of the anterior segment structures was observed. Peripheral iris-corneal touch was noted, and the lens was displaced forward immediately beneath the iris in all eyes (Figs 1B, C and 2A, B). The mean central anterior chamber depth was 481 µm and 658 µm confirming marked shallowing (Figs 1C and 2B). The mean central corneal thickness in the acute phase was 546 µm and 610 µm (Figs 1C and 2B). One patient developed diffuse corneal oedema with increased central corneal thickness (Fig 2B). The mean scleral thickness at the scleral spur was 858 (57) µm (range 797–935 µm). Intensive medical therapy was initiated with cycloplegia, topical aqueous suppressants, vitreous dehydration with intravenous hyperosmotic agents, and oral carbonic anhydrase inhibitors,^{1 3 6} but the intraocular pressure was persistently elevated with values of 28 mm Hg or greater. Surgery consisted of a standard three port PPV combined with anterior chamber reformation with viscoelastic through a paracentesis (Healon, Pharmacia, Stockholm, Sweden). In these phakic eyes not undergoing lensectomy, an attempt was made to disrupt the anterior vitreous face and perform a complete posterior vitrectomy with preservation of the integrity of the lens. The PPV was continued until the anterior chamber deepened and the peripheral iridectomy site appeared clear. On slit lamp

Table 1 Clinical and OCT findings of two patients (three eyes) with malignant glaucoma

| Eye | Patient 1 | | Patient 2 | |
|---|-----------|-----------|-----------|-----------|
| | Left eye | Right eye | Left eye | Right eye |
| Age (years)/sex | 60/female | 65/female | 65/female | |
| Best corrected visual acuity (decimal fraction) | | | | |
| Preoperatively | 1.0 | 0.9 | 0.6 | |
| Last follow up | 1.0 | 0.7 | 0.5 | |
| Gonioscopic anterior chamber angle (Shaffer) | 2 | 1 | 1 | |
| Cup:disc ratio | 0.9 | 0.5 | 0.8 | |
| Mean visual field defect depth (dB) | -3.83 | -4.14 | -8.11 | |
| Axial eye length (mm) | 23.07 | 22.69 | 23.13 | |
| Intraocular pressure (mm Hg) | | | | |
| Preoperatively | 30 | 21 | 30 | |
| Malignant glaucoma phase | 35 | 36 | 28 | |
| Last follow up | 12 | 11 | 11 | |
| OCT values* | | | | |
| Malignant glaucoma phase | | | | |
| ACA | 0 | 0 | 0 | |
| AOD | 0 | 0 | 0 | |
| ACD | 481 (18) | 658 (20) | NA | |
| CCT | 546 (18) | 610 (9) | NA | |
| SS | 797 (4) | 842 (6) | 935 (4) | |
| After PPV | | | | |
| ACA | 17 (0.6) | 37 (2) | 52 (2.7) | |
| AOD | 244 (15) | 397 (8) | 638 (13) | |
| After cataract extraction | | | | |
| ACA | 37 (2) | 56 (1.5) | 41 (4) | |
| AOD | 471 (7) | 549 (22) | 369 (7) | |

*OCT = slit lamp adapted optical coherence tomography; PPV = pars plana vitrectomy; ACA = anterior chamber angle (°); AOD = anterior chamber opening distance (µm); ACD = anterior chamber depth (µm); CCT = central corneal thickness (µm); SS = scleral thickness at the scleral spur (µm), NA = not available.

adapted OCT the critical closure of the anterior chamber angle resolved after PPV and anterior chamber reformation with a viscoelastic (Figs 1D and 2C). The quantitative values of the ACA and AOD increased from 0 to 35° (SD 14°) (range 17–52°) and 426 (SD 62) µm (range 244–638 µm), respectively. In the further postoperative period both patients underwent clear corneal phacoemulsification and implantation of a foldable acrylic intraocular lens in topical anaesthesia for complicated cataracts 3–5 months after the acute malignant glaucoma event. Following cataract surgery further deepening with an ACA of 45° (SD 8°) (range 37–56°) and an AOD of 463 (SD 74) µm (range 369–549 µm) could be noted on slit lamp adapted OCT (Fig 1E). At last follow up the best corrected visual acuity was 0.7 (SD 0.2) (range 0.5–1.0) with a controlled IOP of 12 (SD 0.5) mm Hg (range 11–12 mm Hg), and no significant increase of visual field defects.

DISCUSSION

In this study we present the first OCT findings of anterior segment structures and quantitative changes of the ACA, AOD, corneal or scleral thickness in phakic patients with malignant glaucoma. Slit lamp adapted OCT is a high resolution technology that can create precise cross sectional images of the anterior eye segment and cornea.^{7,8} It has a high reproducibility with a coefficient of variation of 5.4% for the determination of the ACA and 4.5% for the AOD (unpublished results), and was helpful to objectively evaluate the anterior chamber structures or monitor anterior segment changes after glaucoma surgery.

Recently, using ultrasound biomicroscopy (UBM) the configuration of the anterior segment structures has also been visualised during the malignant glaucoma process.^{3,4,11,12} Our OCT findings were very similar to the acoustic features including irido-corneal touch, anterior displacement of the iris root, and appositional angle closure. However, although OCT has a higher resolution than UBM, the visualisation of lens, ciliary body, or anterior vitreous structures was limited because of absorption of infrared light by deeper scleral tissues and the pigment epithelium of the iris. This precluded

imaging of anterior rotation of the ciliary body with apposition to the iris found with UBM.^{3,4,12} However, the UBM method has not yet been shown to be useful in the management of the condition,³ and requires a coupling medium in an immersion bath, which restricts examinations in the immediate postoperative period.

Slit lamp adapted OCT allowed a noninvasive monitoring of the anterior chamber angle region for critical shallowing, and prompt initiation of medical or surgical treatment. The goal of the treatment for malignant glaucoma has been directed to restore the normal aqueous flow into the anterior chamber with resultant deepening. Initial intensive medical management is the treatment of choice in patients with malignant glaucoma.^{1,3,6,13} Although approximately 50% of patients will respond to this form of therapy,^{3,6} patients with refractory glaucoma often require PPV to reduce the vitreous volume, normalise aqueous flow, and achieve sustained control of IOP. Thus, surgical intervention is crucial as prolonged shallowing of the anterior chamber will lead to the formation of peripheral anterior synechiae, posterior synechiae, cataract, and damage to the corneal endothelium.³ OCT has revealed to be helpful for the objective assessment of the therapeutic effects, and to recognise eyes that are unresponsive to medical or surgical management with a recurrent flat anterior chamber postoperatively. More importantly, since an important risk to develop malignant glaucoma is a chronic glaucoma with a narrow irido-corneal angle^{2,4,5} and an increased scleral thickness,³ OCT could be helpful in recognising non-invasively the early stages of a ciliolenticular block monitoring central and peripheral shallowing of the anterior chamber to improve therapeutic management and prevent progression. Since the presence of corneal oedema is an indication of prompt surgical intervention and some authors have even suggested that additional lensectomy may be considered in eyes with substantial corneal oedema,¹³ slit lamp adapted OCT would be also helpful to assess this parameter in a non-contact fashion.⁸

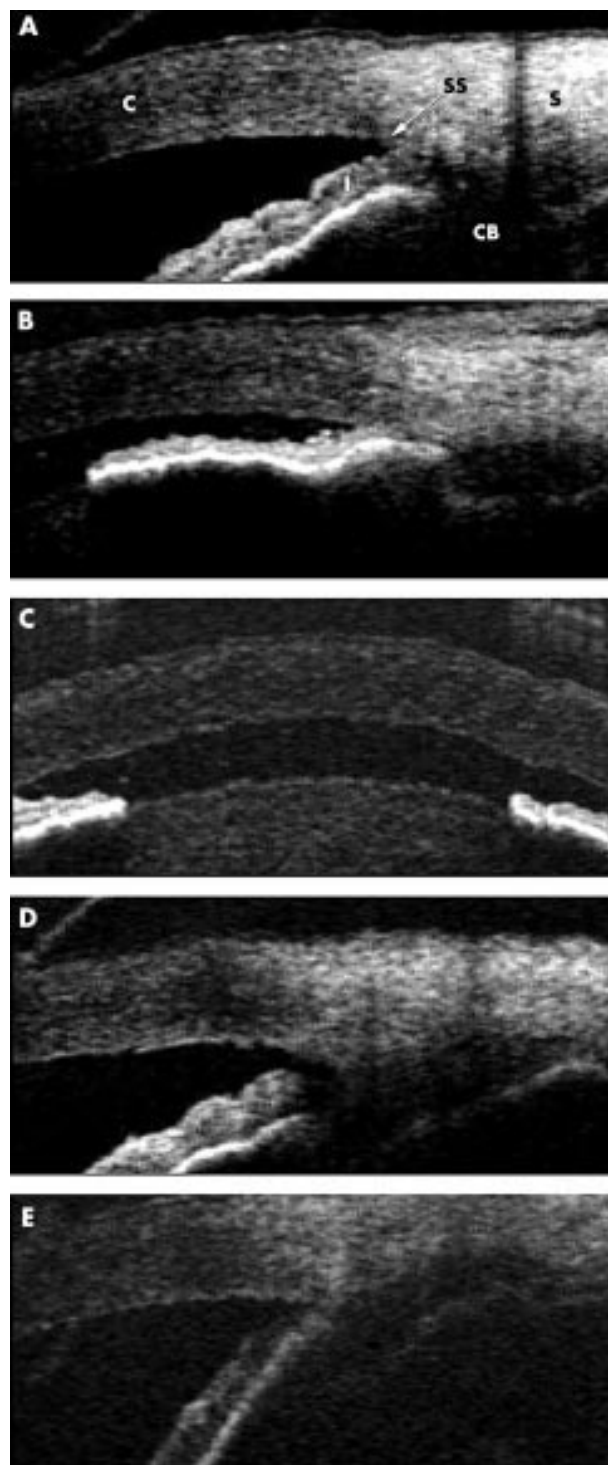


Figure 1 (A) Slit lamp adapted OCT (grey scale) of the anterior chamber angle region in patient 1 preoperatively (ACA 25°, AOD 248 μm). (C = cornea, S = sclera, SS = scleral spur, I = iris, CB = ciliary body). (B) During the acute phase of malignant glaucoma with shallowing of the anterior chamber angle and peripheral iris-corneal touch (ACA 0°, AOD 0 μm). (C) Central corneal (546 μm) and anterior chamber (481 μm) region with marked forward displacement of the iris-lens diaphragm. (D) Following pars plana vitrectomy and anterior chamber reformation with viscoelastic substances (ACA 17°, AOD 244 μm). (E) Further deepening of the anterior chamber angle 4 months postoperatively after phacoemulsification and intraocular lens implantation for complicated cataract (ACA 37°, AOD 471 μm).

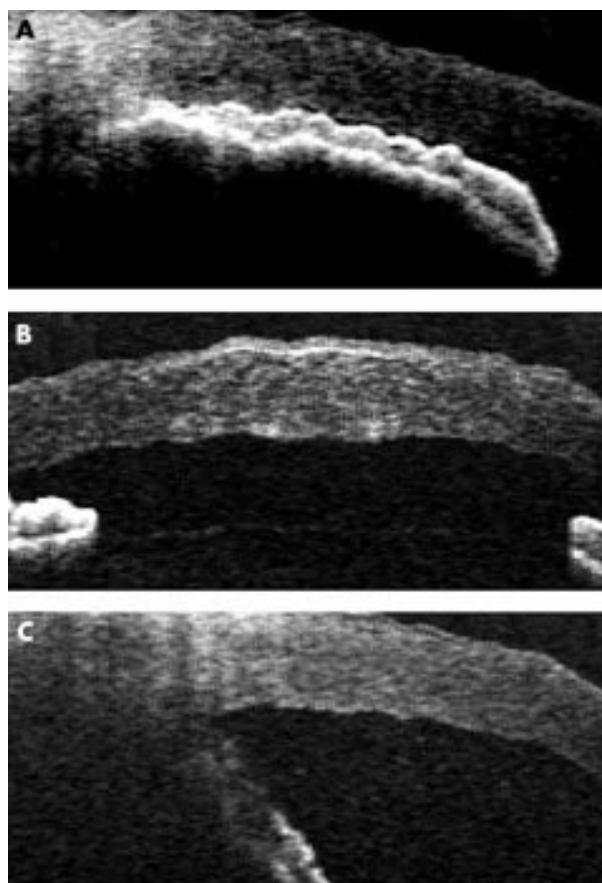


Figure 2 (A) Slit lamp adapted OCT (grey scale) of patient 2 during acute phase of malignant glaucoma with extreme shallowing of the anterior chamber angle and marked iris-corneal touch (ACA 0°, AOD 0 μm). (B) Central corneal thickening (610 μm) and anterior chamber flattening (658 μm) with marked forward displacement of the iris-lens diaphragm. (C) Following pars plana vitrectomy and anterior chamber reformation with a viscoelastic substance (ACA 52°, AOD 638 μm).

In summary, our results confirmed the potential of slit lamp adapted OCT for a non-contact, cross sectional, and high resolution representation of the anterior chamber angle structures in malignant glaucoma following filtration surgery. Thus, there is a strong evidence that OCT at 1310 nm with improved resolution and imaging provides useful objective information in the management of critical situations after glaucoma surgery.

ACKNOWLEDGEMENTS

Supported by the "Herbert Funke-Stiftung," Berlin, Germany.

The authors have no commercial, proprietary or financial interest in any research or devices described in this study.

Authors' affiliations

C Wirbelauer, A Karandish, H Häberle, D T Pham, Klinik für Augenheilkunde, Vivantes Klinikum Neukölln, Rudower Strasse 48, D-12351 Berlin

Correspondence to: Dr Christopher Wirbelauer, Klinik für Augenheilkunde, Vivantes Klinikum Neukölln, Rudower Strasse 48, D-12351 Berlin, Germany; knk.augen@vivantes.de

Accepted for publication 12 November 2002

REFERENCES

- 1 **Johnson DH**. Options in management of malignant glaucoma. *Arch Ophthalmol* 1998;**116**:799–800.
- 2 **Pham DT**, Wollensak J. Ciliary block (malignant) glaucoma following posterior chamber lens implantation. *Ophthalmic Surg* 1987;**18**:741–4.
- 3 **Ruben S**, Tsai J, Hitchings R. Malignant glaucoma and its management. *Br J Ophthalmol* 1997;**81**:163–7.
- 4 **Trope GE**, Pavlin CJ, Bauman CR, *et al*. Malignant glaucoma-clinical and ultrasound biomicroscopic features. *Ophthalmology* 1994;**101**:1030–5.
- 5 **Wollensak J**, Pham DT, Anders N. Ziliolentikulärer Block als Spätkomplikation bei Pseudophakie. *Ophthalmologe* 1995;**92**:280–3.
- 6 **Byrnes GA**, Leen MM, Wong TP, *et al*. Vitrectomy for ciliary block (malignant) glaucoma. *Ophthalmology* 1995;**102**:1308–11.
- 7 **Wirbelauer C**, Scholz C, Hoerauf H, *et al*. Corneal optical coherence tomography before and immediately after excimer laser photorefractive keratectomy. *Am J Ophthalmol* 2000;**130**:693–9.
- 8 **Wirbelauer C**, Scholz C, Hoerauf H, *et al*. Noncontact corneal pachymetry with slit lamp adapted optical coherence tomography. *Am J Ophthalmol* 2002;**133**:444–50.
- 9 **Hoerauf H**, Winkler J, Scholz C, *et al*. Transscleral optical coherence tomography—an experimental study in ex-vivo human eyes. *Lasers Surg Med* 2002;**30**:209–15.
- 10 **Pavlin CJ**, Harasiewicz K, Foster FS. Ultrasound biomicroscopy of anterior segment structures in normal and glaucomatous eyes. *Am J Ophthalmol* 1992;**113**:381–9.
- 11 **Park M**, Unigame K, Kiryu J, *et al*. Management of a patient with pseudophakic malignant glaucoma; role of ultrasound biomicroscopy. *Br J Ophthalmol* 1996;**80**:676–7.
- 12 **Schroeder W**, Fischer K, Erdmann I, *et al*. Ultraschallbiomikroskopie und Therapie des malignen Glaukoms. *Klin Monatsbl Augenheilkd* 1999;**215**:19–27.
- 13 **Harbour JW**, Rubsamen PE, Palmberg P. Pars plana vitrectomy in the management of phakic and pseudophakic malignant glaucoma. *Arch Ophthalmol* 1996;**114**:1073–8.



Direct Access to Medline

Medline

Link to Medline from the homepage and get straight into the National Library of Medicine's premier bibliographic database. Medline allows you to search across 9 million records of bibliographic citations and author abstracts from approximately 3,900 current biomedical journals.

www.bjophthalmol.com



Optical coherence tomography in malignant glaucoma following filtration surgery

C Wirbelauer, A Karandish, H Häberle, et al.

Br J Ophthalmol 2003 87: 952-955

doi: 10.1136/bjo.87.8.952

Updated information and services can be found at:

<http://bjo.bmj.com/content/87/8/952.full.html>

These include:

References

This article cites 13 articles, 2 of which can be accessed free at:

<http://bjo.bmj.com/content/87/8/952.full.html#ref-list-1>

Email alerting service

Receive free email alerts when new articles cite this article. Sign up in the box at the top right corner of the online article.

Topic Collections

Articles on similar topics can be found in the following collections

[Angle](#) (809 articles)

[Glaucoma](#) (797 articles)

[Intraocular pressure](#) (807 articles)

[Ophthalmologic surgical procedures](#) (982 articles)

Notes

To request permissions go to:

<http://group.bmj.com/group/rights-licensing/permissions>

To order reprints go to:

<http://journals.bmj.com/cgi/reprintform>

To subscribe to BMJ go to:

<http://group.bmj.com/subscribe/>